

Biologic Perspectives in Restorative Treatment

Anupama Savadi · V. Rangarajan · Ravindra C. Savadi ·
Preeti Satheesh

Received: 29 June 2011 / Accepted: 18 August 2011 / Published online: 9 September 2011
© Indian Prosthodontic Society 2011

Abstract One of the primary goals of a long term successful restorative therapy is to establish a physiologic periodontal climate that facilitates the maintenance of periodontal health. The contemporary clinician has a host of alternatives for the restoration of teeth. It is now possible to mimic nature and provide restorations that defy detection but the most challenging procedure in clinical dentistry is fabricating a restoration in gingival harmony. Periodontal health is the basis of all restorative dentistry. Because periodontal disease is a major cause of tooth loss in adults, the clinician must be aware of the biological variables relevant to restorative therapy, basic concepts and clinical modes of therapy available, to be able to develop an appropriate diagnosis and treatment plan. A natural looking prosthesis within a healthy periodontium should represent the ultimate goal. This article addresses the interactions between periodontal tissues and restorative procedures. It reviews the essentials of soft tissue management inherent in restorative dentistry that will increase the probability of a successful restoration.

Keywords Biologic width · Gingival biotypes · Periodontium · Restorative dentistry

Introduction

It has been stated that successful restorative dentistry must have as its basis a healthy foundation. Stated in another

way; we may say that periodontal health is the basis of all restorative dentistry [1]. The relation between restorative dentistry and periodontics is interdependent. Often we hear the concept that restorative dentistry is as good as its foundation, the periodontium. Bryan [2] stated that, “We must keep constantly in mind that the dental restorations we make have a twofold purpose; the restoration of the tooth or teeth to function and the protection of the supporting tissues from injury.” It is clear then that restorative procedures must be based not only mechanical specifications but must also fulfill biologic requirement [3].

The cause of vast amounts of periodontal disease is directly related to the failure to meet periodontal specifications. Therefore it is essential that

1. A thorough periodontal evaluation is indicated in the planning stages prior to fabrication of the prosthesis.
2. Definitive periodontal treatment should be completed, including correction of the gingival architecture.
3. Periodontal maintenance during treatment and interim periods.

Prerequisite criteria for eliminating periodontal disease prior to instituting restorative procedures [4, 5].

- 1) Margins of restorations covered by inflamed gingiva shrinks after periodontal treatment. To locate and determine the gingival margins of restorations properly, the position of the healthy and stable gingival margin must be established prior to tooth preparation.
- 2) Inflammation of the periodontium impairs the capacity of abutment teeth to meet the functional demands made on them.
- 3) Partial prosthesis constructed on casts made from impressions of diseased gingiva and edentulous mucosa do not fit properly when periodontal health

A. Savadi · V. Rangarajan · R. C. Savadi · P. Satheesh (✉)
Department of Prosthodontics, The Oxford Dental College,
Hospital & Research Institute, Bommanhalli, Hosur Road,
Bangalore 560068, India
e-mail: to_preeti@yahoo.co.uk

is restored. When the inflammation is eliminated, the contour of the gingiva and adjacent mucosa is altered. Shrinkage creates spaces beneath the pontics of FPD and the saddle area of RPD. Resultant plaque accumulation leads to inflammation of mucosa and gingiva of abutment teeth.

- 4) Discomfort from tooth mobility interferes with mastication and function. Periodontal treatment can reduce mobility with the elimination of edema in PDL and regeneration of bone.

The concept of biologic width has been widely described. An adequate understanding of relationship between periodontal tissues and restorative dentistry is paramount to ensure adequate form, function, esthetics, and comfort of the dentition. While most clinicians are aware of this important relationship, uncertainty remains regarding specific concepts such as violations of biologic width which leads to complications like gingival inflammation, alveolar bone loss and improper fit of the restorative component.

Alterations of Biological Width

Direct or indirect restorations of defects with margins located in the biological width area induce gingival inflammation, loss of connective tissue attachment and unpredictable bone loss. Clinically it could manifest as gingival bleeding and periodontal pocket formation. Histological and clinical investigations of periodontal tissues response to restorations with margins altering gingival biological width confirmed these statements [6–14]. It is established that minimal width of 2 mm is needed for gingiva to attach to the bone. Gingival biological width would be altered if there is less than 2 mm from restoration margin to alveolar bone. In that case gingival inflammation (gingivitis) starts. Human body tries to repair this dimension of 2 mm by resorbing bone as much as needed to create the space for gingival attachment between restoration and alveolar bone (Table 1) [4, 6].

The consequences of this change could be various. It depends on biotype of individual periodontium. There are two biotypes of periodontium and intermediate variants [6, 15].

Gingival Biotypes

It is important to identify the patient's biotype so as to predict the type of tissue changes which will occur in various situations. The human tissue biotype is classified as thin, normal or thick.

In individuals with thick labial alveolar bone overlying the roots, the overlying gingival tissues will be thick. In such areas, inflammation from plaque accumulation will lead to pocketing rather than recession as the manifestation of attachment loss. This tissue architecture, is termed a 'thick biotype'.

In contrast, in other individuals, the labial alveolar bone is thin. Labial dehiscences and fenestrations may be present, or the teeth may be positioned labially in the alveolus. In such situations, the overlying attached gingival tissues may be very thin, the so-called 'thin biotype'. When inflammation develops from the accumulation of dental plaque, or when the gingival tissues are subjected to repeated trauma from tooth brushing or restorative procedures, the end result for this thin tissue type will be recession, leading to exposure of the cemento-enamel junction and root surface.

In patients with a thin biotype, attachment loss on the labial and buccal aspects will be manifested primarily as recession rather than as pocketing. In contrast, a patient with a 'thick biotype' has thick buccal alveolar bone and so will develop pocketing (rather than recession) as attachment loss occurs. The thick biotype with its flattened gingival soft tissue form tends to be more frequent with it occurring in 85% of the population than the thin biotype with its scalloped tissue form (15% of the population).

Because of the tendency to undergo recession with inflammation, the labial gingiva in individuals with a thin biotype must be handled with particular care during surgery, impression taking, and restorative procedures. This is particularly significant for full coverage crowns for the following reasons. Firstly, the thin gingival margins allow visibility of a metal substructure (either porcelain fused to a metal crown or implant abutment), thereby compromising aesthetics in the anterior regions of the mouth. Secondly, placement of margins subgingivally in the thin biotype situation often leads to exposure of these margins as violation of the biological width triggers recession. If a subgingival margin is placed in a patient with a thick biotype, the inflammation elicited will tend to induce pocketing. The vascular changes which accompany chronic inflammation in the tissues may manifest as a deep magenta or purple colouration in the marginal tissues. Arguably, this is as cosmetically undesirable as recession [1, 6, 16–18].

1. Thin periodontium—thickness of attached gingival less than 1 mm, width—3.5–5 mm, thin marginal bone (Table 2).
2. Thick periodontium—thickness of attached gingival to 1.3 mm, width 5–6 mm and more, thick marginal bone (Table 3) [1, 6].

Table 1 Periodontal tissues response and possible reaction to the biological width alterations [6]

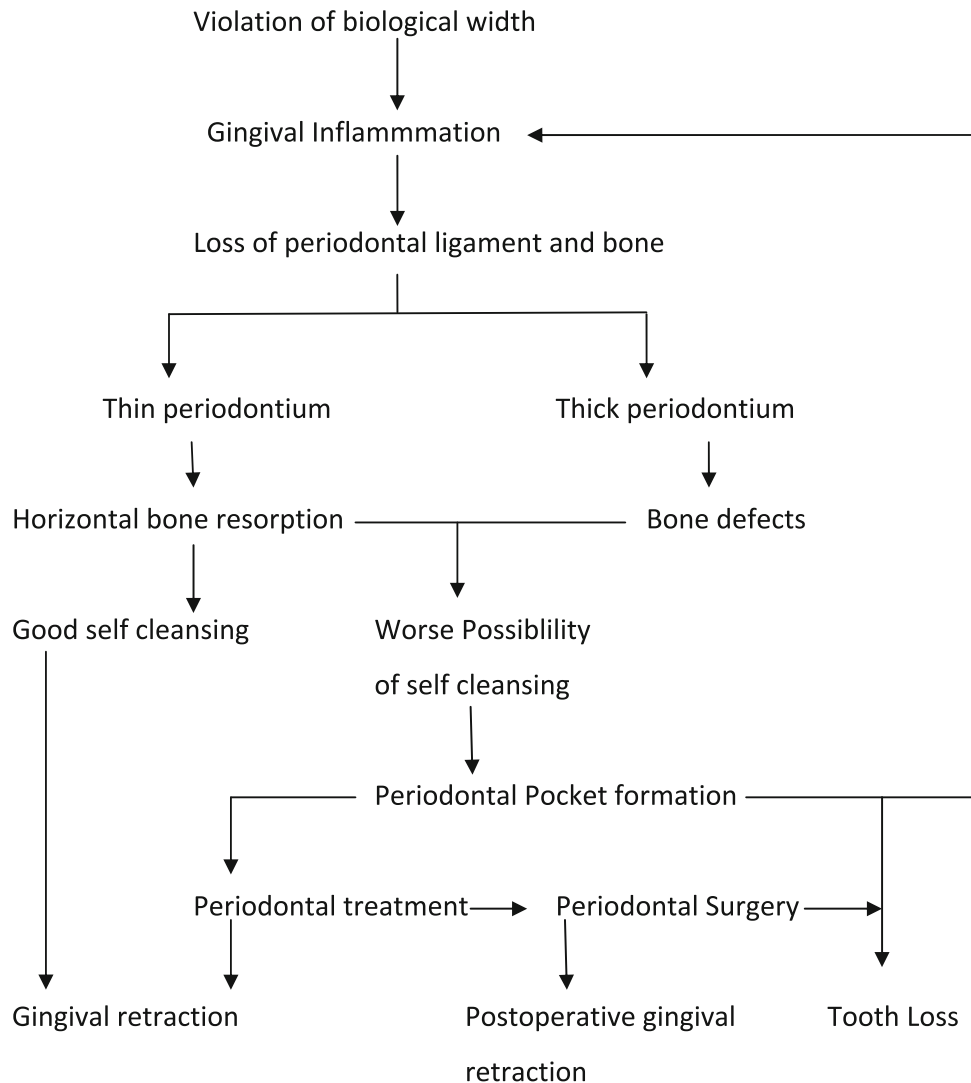


Table 2 Characteristics of thin gingiva [20]

- (a) Highly scalloped soft tissue and bony architecture
- (b) Delicate friable soft tissue
- (c) Minimal amount of attached gingiva
- (d) Thin underlying bone characterized by bony dehiscence and fenestration
- (e) Reacts to insults and disease with gingival recession

Table 3 Characteristics of thick gingiva [20]

- (a) Relatively flat soft tissue and bony architecture
- (b) Dense fibrotic soft tissue
- (c) Relatively large amount of attached gingiva
- (d) Thick underlying osseous form
- (e) Relatively resistant to acute trauma
- (f) Reacts to disease with pocket formation and infrabony defect formation

Relationship between restorative margin location and periodontium

Tooth preparations for fixed prosthodontics requires a decision regarding the marginal configurations. Margins

are one of the most important and weakest links in the success of any fixed restorations. The design dictates the shape and bulk of the casting and influences the fit at the margin. Although many factors such as materials, esthetics and access influence this selection, most dentists probably

have a preferred design. However, there is disagreement about what constitutes ideal margin, geometry and width.

It would be ideal for periodontium to keep margins of restoration supragingivally [6, 13]. Inaccuracy between restoration margin and preparation step influences the biological width and alters the periodontium. Injury to biological width, caused, for example, by a subgingival preparation placed too deeply, will irritate the marginal periodontium. As a general rule, this is followed either by recession or by persisting gingivitis/periodontitis [19]. For this reason, it is desirable to always place restoration margins supragingivally [20].

However this is frequently not possible due to defective morphology as well as for aesthetic reasons particularly in the anterior region. The subgingival placement of a restoration margin required in such situations must therefore be carried out as a traumatically as possible taking into consideration the biological width. The depth of gingival sulcus, the bottom of it (which is epithelial attachment) should be the reference point to avoid gingival biological width from injury. Before tooth restoration the gingiva should be healthy without any sign of inflammation. Then these rules could be followed [13]:

- If gingival sulcus is 1.5 mm or less, then place the margin one half the depth of the sulcus below the tissue crest. Thus the margin is far enough below the tissue so that it still is covered if the patient is at higher risk of recession.
- If gingival sulcus is greater than 2 mm, then margins of restoration is prepared 0.7 mm subgingivally. This places the margin far enough below the tissue so that it still is covered if the patient is at higher risk of recession.
- If gingival sulcus is more than 2 mm, especially in an esthetic zone from vestibular side then gingivectomy is recommended and margins of restoration is prepared 0.5 mm subgingivally [4, 6, 13].

In order to avoid pathological changes and to predict treatment results more precisely, it is necessary to keep gingival biological width unaltered during teeth restoration [13]. Biologic mechanisms operate in the periodontal environment, therefore it is important to:

Evaluation of Biologic Width Radiographic interpretation can identify interproximal violations of biologic width. If a patient experiences tissue discomfort when the restoration margin levels are being assessed with periodontal probe, it is a good indicator that the margin extends into the attachment. A more positive assessment can be made clinically by measuring the distance between the bone and restoration margin using periodontal probe. If this distance is less than 2 mm at one or more locations, a diagnosis of biologic width violation can be confirmed.

Correction of Biologic Width Violations If there is less than 2 mm from restoration's margin to marginal bone, clinical crown lengthening should be considered in the treatment plan. The choice depends on relationship of crown-root-alveolar bone and esthetic expectations. The clinical tooth crown could be lengthened surgically removing bone away from proximity to the restoration margin or combining methods of orthodontic eruption and surgery [21].

If interproximal bone is removed, there is high likelihood of papillary recession and the creation of an unesthetic triangle of space below the interproximal contacts. If the biologic width violation is on the interproximal, or if the violation is across the facial surface and the gingival tissue level is correct, then orthodontic extrusions is indicated. Extrusion can be done in two ways. By applying low orthodontic extrusion force, the tooth is erupted slowly bringing the alveolar bone and gingival tissue with it. The tooth is extruded until the bone level has been carried coronal to the ideal level by the amount that needs to be removed surgically to correct the violation.

Another option is to carry out rapid orthodontic extrusion whereby the tooth is erupted to the desired amount over several weeks. During this period, supracrestal fibrotomy is performed weekly in an effort to prevent the tissue and bone from following the tooth. The tooth is then stabilized for at least 12 weeks to confirm the position of the tissue and bone, and any coronal creep can be corrected surgically [22–24].

Margin Adaptation

The junction between a cemented restoration and the tooth is always a potential site for recurrent caries because of the dissolution of the luting agent. Rough or irregular junctions greatly increase the length of the margins and reduce the possibility of obtaining a good fitting restoration. Therefore smooth margins are critical. Time spent obtaining a smooth margin will make the subsequent steps of tissue displacement, impression making, die formation, waxing and finishing, much easier and ultimately will provide the patient with a longer lasting restoration [8, 25].

Crown Contour

Is another important parameter for the maintenance of periodontal health. Ideal contour provide access for hygiene and has the fullness to create the desired gingival form and a pleasing visual tooth contour in esthetic areas. There is a direct relationship between overcontouring and gingival inflammation, however undercontouring produce

no adverse periodontal effect. The most frequent cause of overcontoured restoration is inadequate tooth preparation so that the technician is left with no other choice except to place an excessive amount of restorative material into the inter proximal space.

Four guidelines to contouring crowns are:

- (a) *Buccal and lingual contours—flat, not fat* Plaque retention on the buccal and lingual surfaces occurs primarily at the infrabulge of the tooth. Reduction or elimination of infrabulge would reduce plaque retention.
- (b) *Open embrasures* Every effort must be made to allow easy access to interproximal area for plaque control. An over contoured embrasure will reduce the space intended for the gingival papilla.
- (c) *Location of contacts* Contacts should be directed incisally or occlusally and buccally in relation to the central fossa, except between maxillary first and second molars. This creates a large lingual embrasure space for optimum health of lingual papilla.
- (d) *Furcation involvement* Furcations that have been exposed owing to loss of periodontal attachment should be ‘fluted’ or ‘barreled out’. It is based on the concept of eliminating plaque traps [26].

Embrasures

The teeth touch in area called proximal contact, the spaces below the contact are known as embrasures. Embrasures protect the gingiva from food impaction and deflect the food, to massage the gingival surface. They provide spillways for food during mastication and relieve occlusal forces when resistant food is chewed. The proximal surfaces of crowns should taper away from the contact area on all surfaces. Excessively broad proximal contact areas and inadequate contour in the cervical areas suppress the gingival papillae. These prominent papillae trap food debris, leading to gingival inflammation.

Proximal contacts that are too narrow buccolingually create enlarged embrasures without sufficient protection against interdental food impaction. The interdental brush (proxia brush) and dental floss are effective in deplaquing the tooth surface at the gingival margin. The proximal contact should be such that the brush snugly fits in the embrasure areas [27].

Cementation

Retained cement particles irritate the gingiva and should be removed. It is important that the restoration be sealed as

close to the tooth preparation as possible. After cementation it is very important that no cement is left in the interproximal spaces. Oral hygiene procedures become a problem if the cement is left behind. Hence floss should be passed along the interproximal margins to ensure that no cement is left back and the margins are free of debris [25].

Lastly the surface of restorations should be as smooth as possible to limit plaque accumulation. But eventually after taking all these precautions, patient education and motivation towards plaque control and healthy oral habits is the secret of every treatment success.

Healing After Periodontal Therapy

The time elapsed after completion of the periodontal treatment is crucial when intra crevicular margins are anticipated. Healing of extensive periodontal surgery usually requires at least 3 months and often more to establish a new biologic width crevice and stable position of gingival margin and papilla. Even areas treated by scaling, root planning and plaque control may take more than 1 or 2 months for their gingival margins to stabilize. Gingival margins after surgery migrate coronally but recede apically after scaling and root planning. Margins prematurely placed intracrevicularly in the second situation often becomes exposed as healing progresses and the result may be unesthetic [27]. The ideal approach is to delay final margin location determination until after the gingival tissues have attained a state of optimum health [28].

Conclusion

One of the primary goals of long term successful restorative therapy is to establish a physiologic periodontal environment and facilitate the maintenance of periodontal health. Alterations in biological width, the finish lines, especially subgingival preparation, marginal seal, crown contour, embrasures, residual cement, host factors as well as easy hygienic maintenance of the reconstruction are all deciding factors contributing to the health or disease of the gingiva and the periodontal supporting tissue.

In order to minimize the damage to the periodontium, special attention has to be paid to understanding the nature of the tissue biotype, so that the practitioner can employ appropriate procedures to provide a more favourable tissue environment for fabrication of a prosthesis. Because periodontal disease is a major cause of tooth loss in adults, the clinician must be aware of the biological variables relevant to restorative therapy, basic concepts and clinical modes of therapy available, to be able to develop an appropriate diagnosis and treatment plan.

References

1. Gracis S, Fradeani M, Celletti R, Brachhetti G (2001) Biological integration of aesthetic restorations: factors influencing appearance and long term success. *Periodontol* 2000 27:29–44
2. Bryan AW (1927) Restorations contributing to the injury of the supporting structures. *JADA* 14:1486
3. Ivancied GP (1958) Interrelationship between restorative dentistry and periodontics. *J Prosth Dent* 8:819–830
4. Newman MG, Takei H, Carranza FA (2003) Carranza's clinical periodontology, 9th edn. Saunders, Philadelphia
5. Freilich MA, Niekrash CE, Katz RV, Simonsen RJ (1992) Periodontal effects of fixed partial denture retainer margins: configuration and location. *J Prosthet Dent* 67(2):184–190
6. Planciunas L, Puriene A, Mackeviciene G (2006) Surgical lengthening of the clinical tooth crown stomatologija. *Baltic Dental Maxillofac J* 8:88–95
7. Block PL (1987) Restorative margins and periodontal health. A new look at an old perspective. *J Prosthet Dent* 57:683–689
8. Dragoo MR, Williams GB (1981) Periodontal tissue reaction to restorative procedures, part I. *Int J Periodontics Restor Dent* 2:8–29
9. Dragoo MR, Williams GB (1981) Periodontal tissue reaction to restorative procedures, part II. *Int J Periodontics Restor Dent* 2:34–42
10. Newins M, Skurow HM (1984) The intracrevicular restorative margin, the biologic width, and the maintenance of the gingival margin. *Int J Periodontics Restor Dent* 3:31–49
11. Orkin DA, Reddy J, Bradshaw D (1987) The relationship of the position of crown margins to gingival health. *J Prosthet Dent* 57:421–442
12. Wang HL, Burgett FG, Shyr Y (1993) The relationship between restoration and furcation involvement on molar teeth. *J Periodontol* 64:302–305
13. Padbury A Jr, Eber R, Wang HL (2003) Interactions between the gingival and the margin of restorations. *J Clin Periodontol* 30:379–385
14. Lanning SK, Waldrop TC, Gunsolley JC, Maynard JG (2003) Surgical crown lengthening: evaluation of the biological width. *J Periodontol* 74:468–474
15. Müller HP, Eger T (2002) Masticatory mucosa and periodontal phenotype: a review. *Int J Periodontics Restor Dent* 2:173–183
16. Ahmad I (2005) Anterior dental aesthetics: gingival perspective. *Br Dent J* 199(4):195–202
17. Sanavi F, Weisgold AS, Rose LF (1998) Biologic width and its relation to periodontal biotypes. *J Esthet Dent* 10:157–163
18. Kao RT, Fagan MC, Conte GJ (2008) Thick vs. thin gingival biotypes: a key determinant in treatment planning for dental implants. *Calif Dent J* 36(3):193–198
19. Günay H (2007) Tooth preparation using guide pin instruments and the biological width. *Int Dent SA* 9(3):76–82
20. Reeves W (1991) Restorative margin placement and periodontal health. *J Prosthet Dent* 66:733–736
21. Sharma N (2007) Precautions to be taken to avoid violation of biologic width: clinical tips in full veneer tooth preparation. *J Prosthodont* 7(3):137–142
22. Felipe LA, Monteiro S Jr, Vieira LC, Araujo E (2003) Reestablishing biologic width with forced eruption. *Quintessence Int* 34:733–738
23. Schwimer CW, Rosenberg ES, Schwimer DH (1990) Rapid extrusion with fiberotomy. *J Esthet Dent* 2:82–88
24. Bensimon GC (1999) Surgical crown-lengthening procedure to enhance esthetics. *Int J Periodontics Restor Dent* 19:332–341
25. Pilo R et al (1988) Incomplete seating of cemented crowns. *J Prosthet Dent* 59(4):429–433
26. Curtis MB (1981) Current theories of crown contour, margin placement, pontic design. *J Prosthet Dent* 45:268
27. Donovan C (2001) Predictable aesthetics with metal ceramic and all ceramic crowns: the critical importance of soft tissue management. *Periodontol* 2000 27:121–130
28. Dayton K (1973) Periodontal considerations for prosthetic patients. *J Prosthet Dent* 30(1):15–18