

Utility of the computed tomography indices on cone beam computed tomography images in the diagnosis of osteoporosis in women

Kwang-Joon Koh, Kyoung-A Kim

Department of Oral and Maxillofacial Radiology, School of Dentistry, and Institute of Oral Bio Science, Chonbuk National University, Jeonju, Korea

ABSTRACT

Purpose : This study evaluated the potential use of the computed tomography indices (CTI) on cone beam CT (CBCT) images for an assessment of the bone mineral density (BMD) in postmenopausal osteoporotic women.

Materials and Methods : Twenty-one postmenopausal osteoporotic women and 21 postmenopausal healthy women were enrolled as the subjects. The BMD of the lumbar vertebrae and femur were calculated by dual energy X-ray absorptiometry (DXA) using a DXA scanner. The CBCT images were obtained from the unilateral mental foramen region using a PSR-9000N™ Dental CT system. The axial, sagittal, and coronal images were reconstructed from the block images using OnDemend3D™. The new term “CTI” on CBCT images was proposed. The relationship between the CT measurements and BMDs were assessed and the intra-observer agreement was determined.

Results : There were significant differences between the normal and osteoporotic groups in the computed tomography mandibular index superior (CTI(S)), computed tomography mandibular index inferior (CTI(I)), and computed tomography cortical index (CTCI). On the other hand, there was no difference between the groups in the computed tomography mental index (CTMI: inferior cortical width).

Conclusion : CTI(S), CTI(I), and CTCI on the CBCT images can be used to assess the osteoporotic women. (*Imaging Sci Dent 2011; 41 : 101-6*)

KEY WORDS : Cone-Beam Computed Tomography; Osteoporosis; Bone Density

Introduction

Osteoporosis is a systemic disease characterized by a low bone mass, deterioration of the bone structure and increased bone fragility.¹ Bone loss occurs with aging after approximately 30 years. In particular, the rate of bone loss increases after menopause in women. In women there is a period of bone loss for 5-10 years post menopause. After this period the rate of bone loss declines at a more gradual rate.²

Dental radiographs are used widely in the adult population. Therefore, dental radiographs may offer an opportu-

nity as a screening tool for osteoporosis.^{1,3,4} Jaw bone density can be assessed using intraoral radiographs,³ panoramic radiographs,^{4,5} cone beam CT (CBCT),⁶ quantitative CT (QCT),^{7,8} and dual energy X-ray absorptiometry (DXA).⁹⁻¹¹

DXA is known as the most accurate clinical method for identifying those with low bone mineral density (BMD).⁹⁻¹¹ BMD in the mandible is positively correlated with that in the lumbar spine and femoral neck in osteoporosis.^{10,11} Taguchi et al¹² observed a significant correlation between the mandibular cortical measurements and vertebral BMD measured by DXA.

Panoramic mandibular index (PMI) on panoramic radiograph has been used to assess the mandibular bone quality.^{4,5} Measurement of the cortical width and a subjective assessment of cortical porosity on panoramic radiographs are methods used previously to diagnose osteoporosis.^{5,12} Kle-

Received February 9, 2011; Revised March 10, 2011; Accepted May 12, 2011
Correspondence to : Prof. Kwang-Joon Koh
Department of Oral and Maxillofacial Radiology, School of Dentistry, Chonbuk National University, 634-18 Keumam-dong, Duckjin-gu, Jeonju 561-712, Korea
Tel) 82-63-250-2023, Fax) 82-63-250-2081, E-mail) kkj1512@jbnu.ac.kr

metti et al⁵ reported that the linear correlation of the PMI with the BMD values was weak. Drozdowska¹³ demonstrated that the efficacy of the panoramic-based mandibular indices in the diagnosis of osteoporosis was low to moderate. On the other hand, Horner and Devlin¹⁴ and Taguchi et al^{12,15} reported that the mandibular cortical index (MCI) was a useful method for osteoporosis screening.

On the other hand, there was no report on the use of the computed tomography indices (CTI) on CBCT images to evaluate the mandibular bone quality. This study was examined the potential use of CTI on the CBCT images for an assessment of the BMD in postmenopausal osteoporotic women.

Materials and Methods

Twenty-one postmenopausal osteoporotic Korean women between the ages of 55 and 72 (mean: 66.0) and 21 postmenopausal healthy women between the ages of 55 and 80 (mean: 60.0) were enrolled as the subjects in this study. The exclusion criteria were metabolic bone diseases such as hyper-, hypoparathyroidism, diabetes, osteomalacia, thyrotoxicosis, and renal disease. Informed consent was obtained from the patients who participated in this study on osteoporosis.

Evaluation of bone mineral density

The BMD (T score, Korean) of the lumbar vertebrae (L1-L3) and femur by DXA using a DXA scanner (Hologic Discovery QDR®, Hologic Inc, Bedford, MA, USA) were calculated. The height and weight were measured at the time of DXA scanning. The subjects with a T score value ≤ -2.5 at both the lumbar and femoral neck were classified as osteoporotic, and a T score value ≥ -1.0 was classified as normal.

CBCT images

CBCT images were obtained from the unilateral mental foramen region using a PSR-9000N™ Dental CT system (Asahi Roentgen Ind Co Ltd, Kyoto, Japan) at 80 kV, 10 mA, 30 seconds, and the pixel size was 0.15 mm. The axial, sagittal, and coronal images were reconstructed from the block images using OnDemend3D™ (Cybermed Inc, Seoul, Korea).

One oral and maxillofacial radiologist with 13 years of experience performed the measurements on a LCD monitor with resolution of 1,280 × 1,024. The measurements were repeated after 2 weeks.

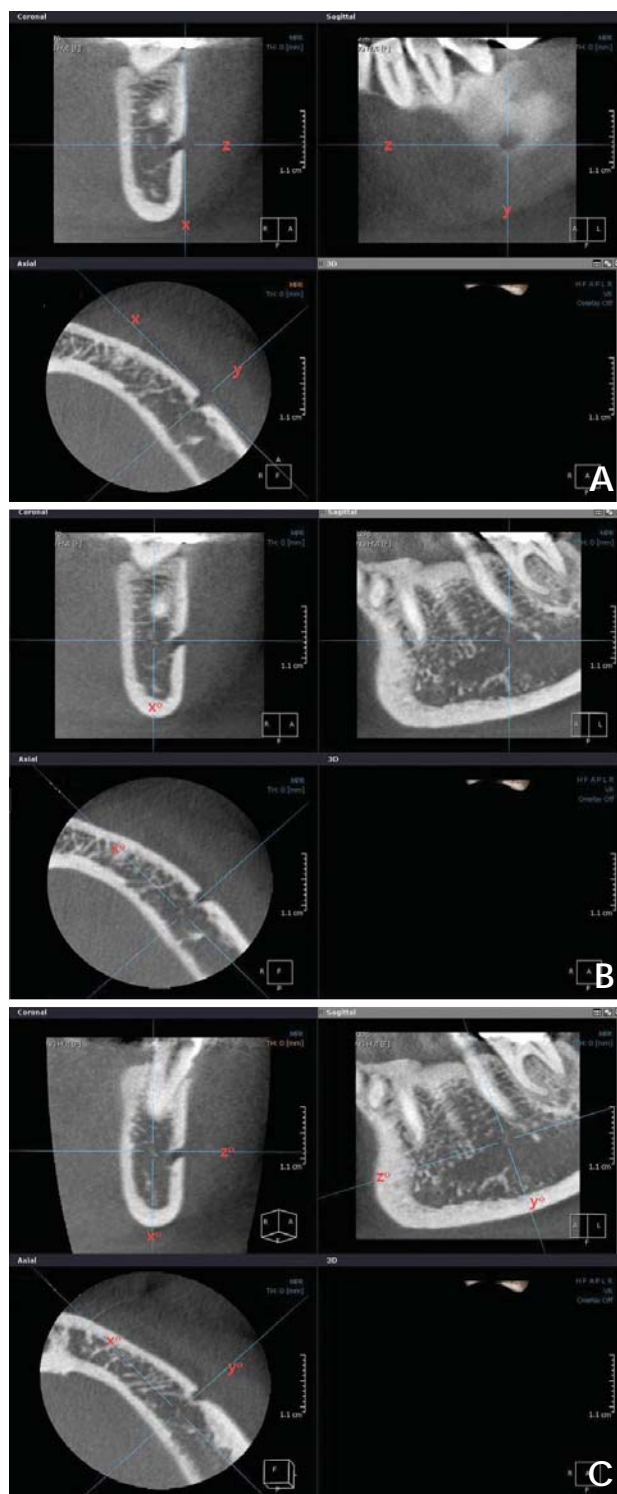


Fig. 1. A. On the axial image, an antero-posterior tangent line “x” is drawn, and line “y” and “z” are drawn perpendicular to line “x” through the center of the mental foramen, then these lines become perpendicular mutually. B. On the coronal image, line “x” is moved to line “x°”, the bisecting position of the bucco-lingual dimension of the mandibular body. C. On the sagittal image, line “z” is moved to line “z°”, parallel position with the mandibular inferior border of the mandible, then line “y” corresponds with line “y°”, perpendicular line “z°” at the same time.

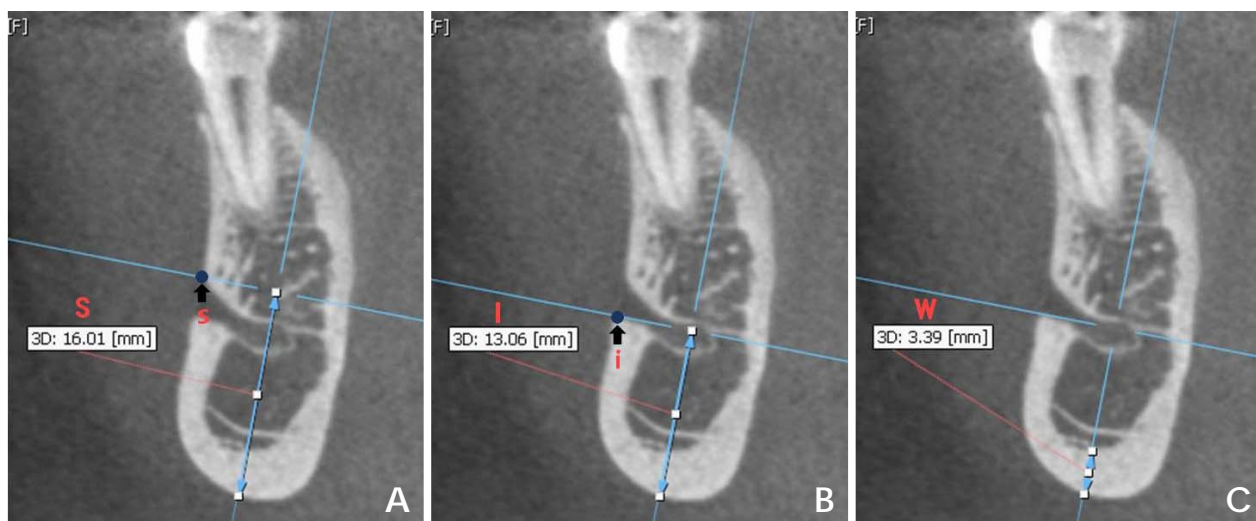


Fig. 2. A. Distance “S” from the superior margin of the mental foramen to the inferior border of the mandible is measured on coronal image. B. Distance “I” is measured from the inferior margin of the mental foramen to the inferior border of the mandible. C. Inferior cortical width (W) of the mandible is measured.

CBCT measurements

The terms “CTI(S)”, “CTI(I)”, “CTMI”, and “CTCI” on CBCT images were used in the present study. They were modified Ledgerton’s classification¹⁶ on panoramic images.

CTI(S): computed tomography mandibular index (superior), which was the ratio of the inferior cortical width to the distance from the superior margin of the mental foramen to the inferior border of the mandible

$$CTI(S)=W/S$$

CTI(I): computed tomography mandibular index (inferior), which was the ratio of the inferior cortical width to the distance from the inferior margin of the mental foramen to the inferior border of the mandible

$$CTI(I)=W/I$$

CTMI: computed tomography mental index, which was the inferior cortical width of the mandible

$$CTMI=W$$

CTCI: computed tomography cortical index, which was the type of the inferior mandibular cortex

$$CTCI : \text{Type 1, 2 and 3}$$

On the axial image, an antero-posterior tangent line “x” was drawn, and line “y” and “z” were drawn perpendicular to line “x” through the center of the mental foramen,

then these lines became perpendicular mutually (Fig. 1A). On the coronal image, line “x” was moved to line “x°”, the bisecting position of the bucco-lingual dimension of the mandibular body (Fig. 1B). On the sagittal image, line “z” was moved to line “z°”, parallel position with the mandibular inferior border of the mandible, then line “y” corresponds with line “y°”, perpendicular line “z°” at the same time (Fig. 1C).

On the coronal image, the distance “S” from the superior margin of the mental foramen to the inferior border of the mandible was measured (Fig. 2A). Distance “I” was measured from the inferior margin of the mental foramen to the inferior border of the mandible (Fig. 2B). And inferior cortical width (W) was measured (Fig. 2C).

The types of the inferior mandibular cortex were subjectively classified as follows:

Type 1: the cortical endosteal margin appears even and regular (Fig. 3A)

Type 2: the endosteal margin shows semilunar defects or 1 to 2 layers of cortical endosteal residues (Fig. 3B)

Type 3: the cortical layer has numerous (>3) endosteal residues and is clearly porous (Fig. 3C)

Statistical analysis

The relationships between the CTI(S), CTI(I), CTMI, and BMDs were assessed using a t-test. The CTMI was determined by linear regression analysis, and the intra-observer agreement was examined using the Pearson’s

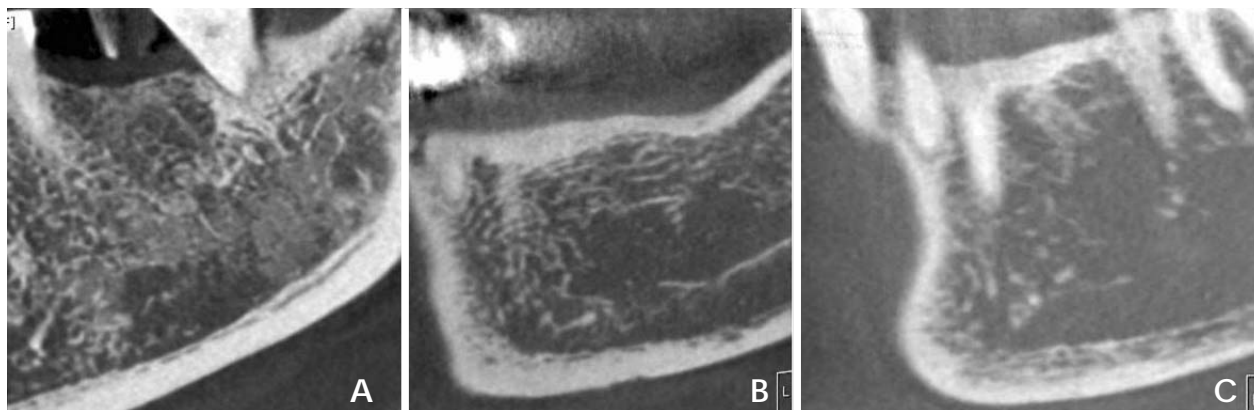


Fig. 3. The types of the inferior mandibular cortex are subjectively classified as follows. A. Type 1: the cortical endosteal margin appears even and regular. B. Type 2: the endosteal margin appears semilunar defects or 1 to 2 layers of cortical endosteal residues. C. Type 3: the cortical layer has numerous (>3) endosteal residues and is clearly porous.

Table 1. Characteristics of the study subjects

Characteristics	Normal	Osteoporosis
	Mean ± SD	Mean ± SD
Number of patients	21	21
Age (years)	60.0 ± 5.7	66.0 ± 6.4
Height (cm)	156.0 ± 4.9	152.2 ± 5.9
Weight (kg)	60.7 ± 6.9	53.6 ± 8.0
BMD (T score: Korean)	≥ -1	≤ -2.5
Lumbar (L1-L3)	-0.24 ± 0.80	-3.02 ± 0.56
Femur	-0.26 ± 0.75	-3.03 ± 0.53

correlation coefficient and Spearman’s rho on SPSS 16.0 (SPSS Inc, Chicago, IL, USA) for Windows.

Results

Table 1 lists the characteristics of the study subjects. A total number of 42 women were enrolled in this study. The mean age of the study population was 60.0 (SD 5.7) years in the normal group and 66.0 (SD 6.4) years in the osteoporosis group. The mean height and weight were 156.0 cm, 60.7 kg in the normal group and 152.2 cm and 53.6 kg in the osteoporosis group. The mean lumbar and femur BMD scores were respectively -0.24 and -0.26 in the normal group and -3.02 and -3.03 in the osteoporosis group.

Table 2 lists the mean values of the computed tomography parameters on the CBCT images. The mean values of the CTI(S) and CTI(I) were 0.21 and 0.25 in the normal group, and 0.14, 0.18 in the osteoporosis group. The mean value of the CTMI was 3.22 in the normal group, and 2.23 in the osteoporosis group. There were significant differences between the normal and osteoporosis groups in the

Table 2. Mean values of the computed tomography parameters on cone beam computed tomography (CBCT) image

CBCT parameter	Normal (n=21)	Osteoporosis (n=21)
	Mean ± SD	Mean ± SD
CTI(S)	0.21 ± 0.05	0.14 ± 0.05*
CTI(I)	0.25 ± 0.07	0.18 ± 0.07*
CTMI	3.22 ± 0.87	2.23 ± 0.85

*: significant at the 0.05 level t-test (2-tailed), CTI(S): computed tomography mandibular index (superior), CTI(I): computed tomography mandibular index (inferior), CTMI: computed tomography mental index (inferior cortical width)

Table 3. Ability of computed tomography cortical index (CTCI) to differentiate osteoporosis from normal on cone beam computed tomography image

CTCI		Number	Mean ± SD	P value
Type 1	Normal	13	0.004 ± 0.54	0.00*
	Osteoporosis	3	-2.85 ± 0.26	
Type 2	Normal	7	-0.64 ± 0.46	0.00*
	Osteoporosis	11	-3.09 ± 0.42	
Type 3	Normal	2	-0.90 ± 0.14	0.00*
	Osteoporosis	7	-3.01 ± 0.37	

*: correlation is significant at the 0.05 level t-test (2-tailed)

CTI(S) and CTI(I) ($P < 0.05$). On the other hand, there was no correlation between the groups in the CTMI ($P > 0.05$).

Table 3 lists the ability of CTCI to differentiate osteoporosis from normal on the CBCT images. The mean values of the Type 1, 2 and 3 were respectively 0.004, -0.64, -0.90 in the normal group, and -2.85, -3.09 and -3.01 in the osteoporosis group. There was a significant difference in the CTCI between the groups ($P < 0.05$).

Table 4 lists the intra-observer agreement in the assess-

Table 4. Intra-observer agreement in the assessment of the computed tomography indices (CTI) by Pearson's correlation coefficient and Spearman's rho

	CTI(S)		CTI(I)		CTMI		CTCI	
	Normal	Osteo	Normal	Osteo	Normal	Osteo	Normal	Osteo
Pearson's correlation	0.92**	0.43*	0.95**	0.45*	0.84**	0.92**		
Significance	0.00	0.02	0.00	0.01	0.00	0.00		
Spearman's rho							0.62**	0.80**
Significance							0.00	0.00

** : correlation is significant at the 0.01 level (2-tailed), * : 0.05 level, Osteo: osteoporosis, CTI(S): computed tomography mandibular index (superior), CTI(I): computed tomography mandibular index (inferior), CTMI: computed tomography mental index (inferior cortical width), CTCI: computed tomography cortical index

ment of the CTI. The Pearson's correlation coefficients were respectively 0.92, 0.95, and 0.84 in the normal group, and 0.43, 0.45, and 0.92 in the osteoporosis group. The value of the Spearman's rho was 0.62 in the normal group, and 0.80 in the osteoporosis group. The intra-observer agreement showed a significant correlation for all parameters ($P < 0.05$).

Discussion

This study examined the potential use of the CTI on CBCT images in diagnosis of osteoporosis in women.

Early diagnosis through bone density measurements allows proper management of osteoporosis to decrease the risk of fracture and disability. Many studies^{3,17,18} have examined the methods for detecting individuals with a low BMD at an early stage. Some investigators have investigated whether dental radiographs could play a role in the detection of individuals with osteoporosis.³⁻⁸ A basic requirement for this would be that the bone mass in the jaw might be related to that of other skeletal sites in which osteoporosis was a significant problem.

DXA, a well-established means of measuring the BMD in the spine and femoral neck, is the most reliable method to examine the bone density in the mandible.⁹⁻¹¹ Adams¹⁹ reported that the precision of DXA of the spine ranged from 0.5 to 1%, whereas DXA of the femoral neck was 2-5%. Horner et al¹¹ demonstrated that BMD measurements of the mandible showed a significant correlation with those of the lumbar vertebra and femoral neck. Taguchi et al⁸ reported the significant correlations between the mandibular BMDs using QCT and lumbar and femoral neck BMDs measured by DXA.

In the present study, DXA was used as the gold standard for the BMD measurements in the lumbar and femoral neck. The World Health Organization (WHO) set the threshold for the diagnosis of osteoporosis at a BMD of

2.5 or more standard deviations below the young normal reference measurements.

Some studies^{18,20,21} regarding the PMI on panoramic radiographs have been performed. Benson et al²⁰ first suggested the PMI on a panoramic image. Watson et al²¹ reported that there was no difference in the mean PMI between normal and osteoporotic women. Klemetti et al²² stated that the PMI should not be used to assess the patient's status regarding osteoporosis.

On the other hand, the results of the present study on the CBCT images showed that the CTI(S) and CTI(I) was significantly different between the normal and osteoporotic groups ($P < 0.05$). This result was contrary to those reported by Watson et al²¹ and Klemetti et al²² on the panoramic images.

Devlin et al²³ demonstrated that the mandibular cortical width had better efficacy in detecting osteoporosis on a panoramic radiograph than the mandibular cortical index. There was no evidence for any benefit associated with combining the two measurements to detect osteoporosis. They insisted that only those with the thinnest mandibular cortices (≤ 3 mm) should be referred for a further osteoporosis investigation, because this group had the highest likelihood of osteoporosis. Horner et al²⁴ found that a thinning of the mandibular cortex below 3 mm at the mental foramen on a panoramic radiograph was associated with a low skeletal mass (or osteopenia) at the spine or femoral neck.

Our results on the CBCT images showed no significant difference in CTMI between the normal and osteoporotic groups, which was contrary to those of earlier studies^{23,24} on the panoramic images.

Taguchi et al¹² demonstrated that the cortical measurements detected on the panoramic images might be useful for identifying younger postmenopausal women with a low BMD or osteoporosis. They found that the sensitivity and specificity for diagnosing the spinal osteoporosis was

86.8% and 63.6%, respectively in normal postmenopausal women with cortical erosion on the panoramic image. They suggested that dentists should be able to refer postmenopausal women with suspected spinal osteoporosis for bone densitometry based on the panoramic radiographs. On the other hand, Drozdowska¹³ reported that the efficacy of the panoramic-based mandibular indices in diagnosing osteopenia/osteoporosis was low to moderate. These results showed a significant relationship between the cortical erosion and the BMD ($P < 0.05$), which corresponded to those reported by Taguchi et al.¹²

The intra-observer agreement of the present study showed a significant correlation in the CTI(S), CTI(I), and CTCI, however there was no correlation in the CTMI on the CBCT images.

The limitations of this study included the small sample size. Further studies with a larger sample and examination of the relationship between the CTI in patients with systemic diseases and BMDs are requested.

In conclusion, this study suggests that CTI(S), CTI(I), and CTCI on CBCT images can be used to assess the osteoporotic women.

References

1. Verheij JG, Geraets WG, van der Stelt PF, Horner K, Lindh C, Nicopoulou-Karayianni K, et al. Prediction of osteoporosis with dental radiographs and age. *Dentomaxillofac Radiol* 2009; 38 : 431-7.
2. White SC. Oral radiographic predictors of osteoporosis. *Dentomaxillofac Radiol* 2002; 31 : 84-92.
3. Nackaerts O, Jacobs R, Devlin H, Pavitt S, Bleyen E, Yan B, et al. Osteoporosis detection using intraoral densitometry. *Dentomaxillofac Radiol* 2008; 37 : 282-7.
4. Kim JY, Nah KS, Jung YH. Comparison of panorama radiomorphometric indices of the mandible in normal and osteoporotic women. *Korean J Oral Maxillofac Radiol* 2004; 34 : 69-74.
5. Klemetti E, Kolmakov S, Heiskanen P, Vainio P, Lassila V. Panoramic mandibular index and bone mineral densities in postmenopausal women. *Oral Surg Oral Med Oral Pathol* 1993; 75 : 774-9.
6. Hua Y, Nackaerts O, Duyck J, Maes F, Jacobs R. Bone quality assessment based on cone beam computed tomography imaging. *Clin Oral Implants Res* 2009; 20 : 767-71.
7. Lindh C, Nilsson M, Klinge B, Petersson A. Quantitative computed tomography of trabecular bone in the mandible. *Dentomaxillofac Radiol* 1996; 25 : 146-50.
8. Taguchi A, Tanimoto K, Suei Y, Ohama K, Wada T. Relationship between the mandibular and lumbar vertebral bone mineral density at different postmenopausal stages. *Dentomaxillofac Radiol* 1996; 25 : 130-5.
9. Horner K, Karayianni K, Mitsea A, Berkas L, Mastoris M, Jacobs R, et al. The mandibular cortex on radiographs as a tool for osteoporosis risk assessment: the OSTEODENT project. *J Clin Densitom* 2007; 10 : 138-46.
10. Karayianni K, Horner K, Mitsea A, Berkas L, Mastoris M, Jacobs R, et al. Accuracy in osteoporosis diagnosis of a combination of mandibular cortical width measurement on dental panoramic radiographs and a clinical risk index (OSIRIS): the OSTEODENT project. *Bone* 2007; 40 : 223-9.
11. Horner K, Devlin H, Alsop CW, Hodgkinson IM, Adams JE. Mandibular bone mineral density as a predictor of skeletal osteoporosis. *Br J Radiol* 1996; 69 : 1019-25.
12. Taguchi A, Tsuda M, Ohtsuka M, Kodama I, Sanada M, Nakamoto T, et al. Use of dental panoramic radiographs in identifying younger postmenopausal women with osteoporosis. *Osteoporos Int* 2006; 17 : 387-94.
13. Drozdowska B, Pluskiewicz W, Tarnawska B. Panoramic-based mandibular indices in relation to mandibular bone mineral density and skeletal status assessed by dual energy X-ray absorptiometry and quantitative ultrasound. *Dentomaxillofac Radiol* 2002; 31 : 361-7.
14. Horner K, Devlin H. The relationship between two indices of mandibular bone quality and bone mineral density measured by dual energy X-ray absorptiometry. *Dentomaxillofac Radiol* 1998; 27 : 17-21.
15. Taguchi A, Suei Y, Ohtsuka M, Otani K, Tanimoto K, Ohtaki M. Usefulness of panoramic radiography in the diagnosis of postmenopausal osteoporosis in women. Width and morphology of inferior cortex of the mandible. *Dentomaxillofac Radiol* 1996; 25 : 263-7.
16. Ledgerton D, Horner K, Devlin H, Worthington H. Panoramic mandibular index as a radiomorphometric tool: an assessment of precision. *Dentomaxillofac Radiol* 1997; 26 : 95-100.
17. Horner K, Allen P, Graham J, Jacobs R, Boonen S, Pavitt S, et al. The relationship between the OSTEODENT index and hip fracture risk assessment using FRAX. *Oral Surg Oral Med Oral Pathol Oral Radiol Endod* 2010; 110 : 243-9.
18. Taguchi A, Suei Y, Sanada M, Ohtsuka M, Nakamoto T, Sumida H, et al. Validation of dental panoramic radiography measures for identifying postmenopausal women with spinal osteoporosis. *AJR Am J Roentgenol* 2004; 183 : 1755-60.
19. Adams JE. Osteoporosis and bone mineral densitometry. *Curr Opin Radiol* 1992; 4 : 11-20.
20. Benson BW, Prihoda TJ, Glass BJ. Variations in adult cortical bone mass as measured by a panoramic mandibular index. *Oral Surg Oral Med Oral Pathol* 1991; 71 : 349-56.
21. Watson EL, Katz RV, Adelezzì R, Gift HC, Dunn SM. The measurement of mandibular cortical bone height in osteoporotic vs. non-osteoporotic postmenopausal women. *Spec Care Dentist* 1995; 15 : 124-8.
22. Klemetti E, Kolmakov S, Kröger H. Pantomography in assessment of the osteoporosis risk group. *Scand J Dent Res* 1994; 102 : 68-72.
23. Devlin H, Karayianni K, Mitsea A, Jacobs R, Lindh C, van der Stelt P, et al. Diagnosing osteoporosis by using dental panoramic radiographs: The OSTEODENT project. *Oral Surg Oral Med Oral Pathol Oral Radiol Endod* 2007; 104 : 821-8.
24. Horner K, Devlin H. The relationship between mandibular bone mineral density and panoramic radiographic measurements. *J Dent* 1998; 26 : 337-43.