

CASE REPORT

Actinomycosis of the Upper Lip

Young Seok Lee, M.D., Hyun Soo Sim, M.D., Sook Kyung Lee, M.D.

Department of Dermatology, Maryknoll Medical Center, Busan, Korea

Actinomycotic infections are known to have an association with difficulties in diagnosis and treatment. These infections usually involve the head, neck, thorax, and abdomen. Actinomycosis of the upper lip is a rare condition and an important one as well, because it can imitate other diseases. As the initial impression, it can easily be mistaken for a mucocele, venous lake, or benign neoplasm. An 82-year-old man presented with an asymptomatic normal skin colored nodule on the upper lip. Histopathologic findings showed an abscess and sulfur granules in the dermis. Gram staining results showed a mesh of branching rods. In this report, we present an unusual case of actinomycosis of the upper lip and discuss its characteristics and therapeutic modalities. (**Ann Dermatol 23(S1) S131 ~ S134, 2011**)

-Keywords-

Actinomycosis, Sulfur granules

INTRODUCTION

Actinomycosis is a chronic, suppurative infection, caused mainly by *Actinomyces israelii*, Gram-positive anaerobic bacilli of which cultivation is difficult¹. In humans, it lives as a commensal organism in the oral cavity and respiratory and digestive tracts². The organism is unable to penetrate intact tissue; therefore, infection is often secondary to local injury or spreading from visceral sites. This

Received September 10, 2010, Revised November 9, 2010, Accepted for publication November 9, 2010

Corresponding author: Sook Kyung Lee, M.D., Department of Dermatology, Maryknoll Medical Center, Daecheong-dong 4-ga Jung-gu, Busan 600-730, Korea. Tel: 82-51-461-2438, Fax: 82-51-467-3232, E-mail: steinwai@naver.com

This is an Open Access article distributed under the terms of the Creative Commons Attribution Non-Commercial License (<http://creativecommons.org/licenses/by-nc/3.0>) which permits unrestricted non-commercial use, distribution, and reproduction in any medium, provided the original work is properly cited.

infection is characterized by localized swelling with suppuration, abscess formation, tissue fibrosis, and sinus drainage³. Oral actinomycosis is rare, compared with occurrence at common sites, which include the cervico-facial, respiratory tract, and gastrointestinal tract. Clinical features of our patient were similar with a mucocele or venous lake; however, the biopsy specimen revealed an abscess and sulfur granules in the dermis. Therefore, we made a diagnosis and report an unusual case of actinomycosis of the upper lip.

CASE REPORT

An 82-year-old man presented to our dermatology department with a subcutaneous nodule on the mucosal aspect of his right upper lip. He noticed the lesion 15 days before the visit and had not taken any treatment for it. Intraoral examination revealed an almost non-tender normal skin colored nodule on the lip, which measured 8-mm, and was covered with normal mucosa (Fig. 1). The

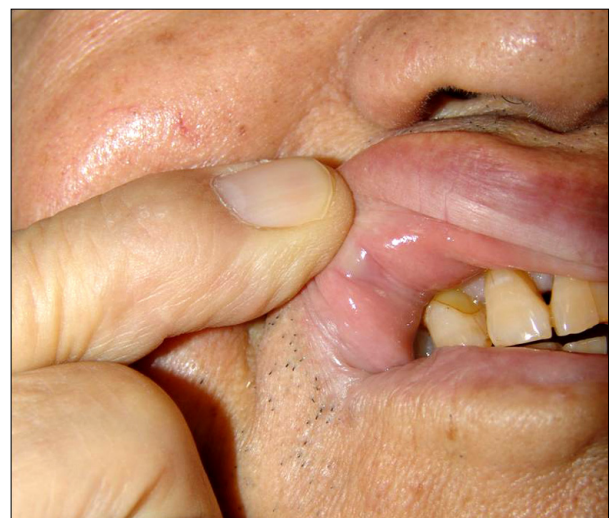

Fig. 1. A normal skin colored subcutaneous nodule measuring 8 mm on the mucosal aspect of the right upper lip.

nodule was smooth on palpation, and no discharge of pus or exudates was observed upon gentle pressure. No cervical lymphadenopathy was noted. Under the impression of a mucocele or venous lake, the lesion was totally excised. The patient's past medical history included hypertension and benign prostate hyperplasia since the age of 72. Antianginal medication had been started 3 months earlier, and there was no recent history of dental manipulation. Histopathological examination showed characteristic basophilic clumps of organism, and sulfur granules with associated suppurative inflammation in the dermis (Fig. 2). Gram staining showed numerous radially oriented, bluish

purple, filamentous bacteria with peripheral clubs at its edge (Fig. 3A). AFB staining showed no acid-fast bacilli (Fig. 3B). Actinomycosis was diagnosed after other diseases that show sulfur granules, like nocardiosis and botryomycosis, had been ruled out. Sulfur granules observed in nocardiosis contain gram-positive, weakly acid-fast bacilli, and those observed in botryomycosis consist of nonfilamentous cocci or bacilli, which may be gram-positive or negative. No pus or other symptoms suggestive of infectious origin were observed; therefore, we did not consider performing bacterial culture or other laboratory methods for identification of a causative

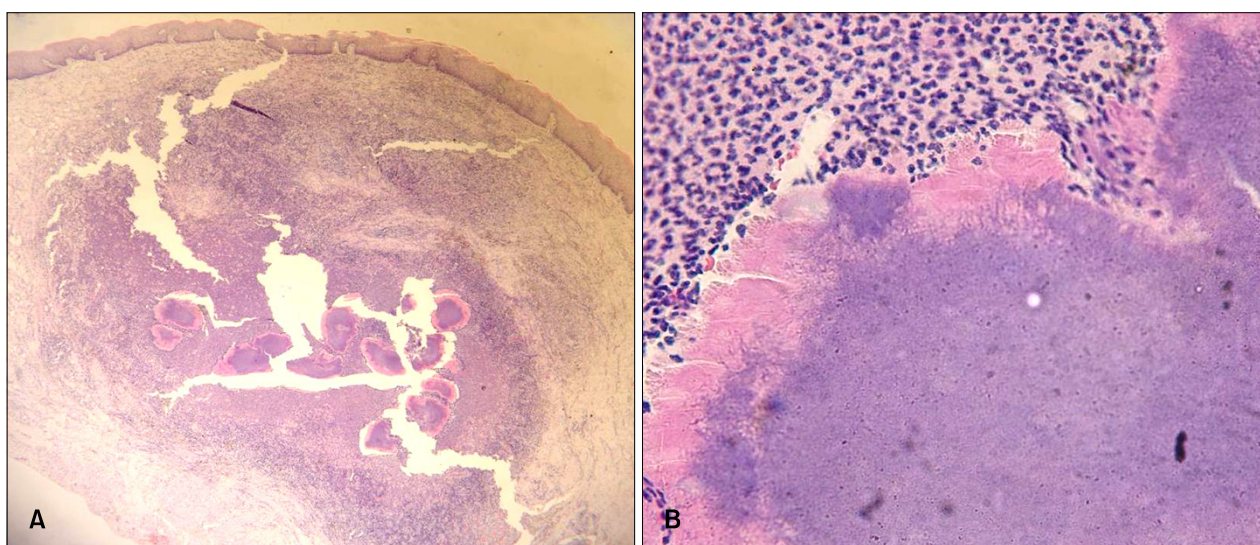


Fig. 2. (A) Sulfur granules associated with suppurative inflammation in the dermis (H&E, $\times 40$). (B) The magnified view shows a group of filamentous bacteria forming a sulfur granule with peripheral Hoepli-Splendore phenomenon (H&E, $\times 400$).

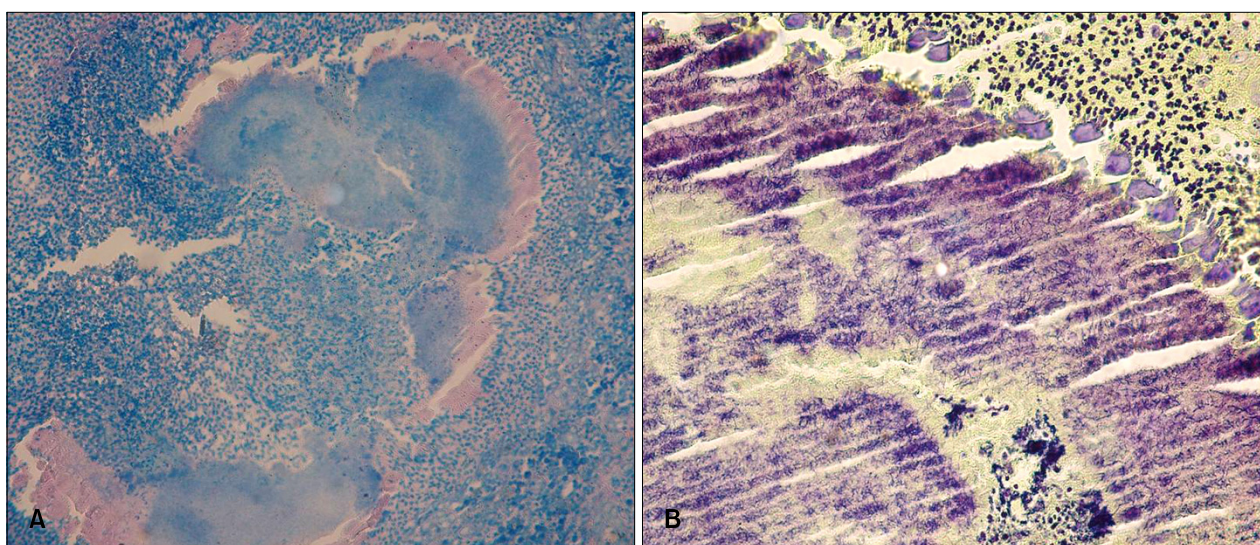


Fig. 3. (A) No acid-fast-bacilli are seen (AFB, $\times 200$). (B) A gram stain demonstrates numerous, radially oriented, gram-positive filamentous bacteria and peripheral clubs at its edge (Gram stain, $\times 400$).

Table 1. Clinical features of actinomyces of the lip

Author	Year	Age	Sex	Site	Size	Duration	Diagnosis
Kikiewicz ¹¹	1978	50	M	Upper lip	Cherry size	5 mo	Infected cyst
Appiah-Apene and Tickle ¹²	1995	32	F	Upper lip	2 cm	2 mo	MSG tumor
Lan et al. ¹³	2007	50	M	Lower lip	1 cm	3 mo	MSG tumor
Sánchez-Estella et al. ¹⁴	2009	69	M	Lower lip	2 cm	1 yr	MSG tumor
Our case	2010	82	M	Upper lip	8 mm	15 d	Mucocele

MSG: minor salivary gland.

organism.

Routine hematological and biochemical tests were conducted on the next visit; however, there were no abnormal findings. ELISA for HIV also showed negative results.

The lesion had already been completely removed, and, on the basis of the above findings, the patient was treated complementarily with a daily oral dose of 300 mg cefditoren pivoxil. After 1 month of treatment, we were unable to contact the patient and follow up assessment was not continued.

DISCUSSION

Actinomyces is a rare, chronic, slowly progressive bacterial infection that induces both suppurative and granulomatous inflammation³. It is caused by anaerobic, gram-positive bacilli, most of which belong to the genus *Actinomyces*. *Actinomyces israelii* is the agent isolated in most cases⁴ and is responsible for cervico-facial (55%), pulmonary (15%), abdomino-pelvic (20%), and mixed organ (10%) infections⁴. *Actinomyces* spp. are non-virulent commensal organisms found in the oral cavity, gastrointestinal tract, and female genitalia⁵.

Disruption of the mucosal barrier and alteration of resident microbial flora are important factors for initiation of infection⁶. Clinical infections are often opportunistic and may result from dental procedures or oral trauma in the cervicofacial region⁷. Our patient had a recent history of a lip bite, and his medical history was generally unremarkable.

The male to female ratio of the disease is 3:1, and it usually presents in the fourth to fifth decade of life⁸. Infection commonly presents as a chronic or subacute painless or painful soft tissue swelling or mass involving the submandibular or paramandibular region³. Chronic lesions may have yellowish purulent discharge containing sulfur granules⁹. Insidious onset of constitutional symptoms, including fever, anorexia, malaise, weight loss, and night sweat may also be observed¹⁰.

Actinomyces of the upper lip is rare, and a review of the English literature found only 4 reported cases of lip

involvement over the last 30 years (Table 1)¹¹⁻¹⁴. The rarity of this condition may be explained by the richly vascular parenchyma and great mobility of the upper lip, which is mechanically cleansed by saliva; therefore, bacteria cannot easily adhere to it and multiply, as in the case of the uncommon lingual actinomyces⁹. Immune-compromised hosts, such as those with HIV infection or diabetes, and those undergoing chemotherapy or taking steroids, are not at greater risk of actinomyces than immunocompetent hosts¹⁵.

Characteristic histopathological findings include an outer zone of granulation around central purulent loculations containing multiple granules¹⁶. These pathognomonic granules are matted colonies of the causative organism and show basophilic, oval masses with distinct eosinophilic clubs radiating from the entire border. Granules contain gram-positive, non-acid-fast bacteria, which are typically branching filaments of diameter $< 1 \mu\text{m}$ ¹. On the basis of these characteristics, actinomyces can be differentiated from nocardiosis, in which granules are gram-positive and partially acid-fast¹⁷. Granules in botryomycosis consist of nonfilamentous cocci or bacilli, which may be gram-positive or negative¹⁷.

Definitive diagnosis is established by culture on brain-heart agar or blood agar in anaerobic media¹⁸. However, culture results are negative in more than 50% of cases¹⁹; therefore, incisional biopsy is often undertaken for diagnosis. Actinomyces can be treated with long-term penicillin therapy⁵. Effective short-term antibiotic therapy has recently been reported in cases with less involvement²⁰. Alternative first-line antibiotics include amoxicillin, cephalosporine, tetracycline, erythromycin, and clindamycin. As actinomyces can recur a few months or years after an apparent cure, antibiotic therapy should be prolonged in order to prevent the chance of recurrence⁹.

Cervicofacial actinomyces is known to be the most common type; however, though rare, localized intraoral lesions can sometimes occur. As the initial impression, it can be easily mistaken for a mucocele, venous lake, or benign neoplasm; as a result, the treatment administered may be inappropriate or inadequate⁹.

Our patient presented with a subcutaneous nodule

measuring almost 8 mm on the mucosal aspect of the upper lip without immunosuppression and specific past history. Previously reported cases of actinomycosis of the lip have also shown tender or non-tender nodular lesions without immunosuppression and there were no past histories of interest¹¹⁻¹⁴. We performed total excision of the lesion and culture was not performed because we did not consider an infectious origin, as in previously reported cases. Infection of minor self-injury might be favored by poor oral hygiene.

In this study, we report on an unusual case of actinomycosis located on the upper lip. On the basis of our findings, we think that actinomycosis should be included in differential diagnosis of neoplasm and chronic suppurative granulomatous lesions of the oral region.

REFERENCES

1. Al-Niaimi F, Patel A, Blessing K, Fox R, Burden AD. Cutaneous actinomycosis presenting as chronic mastitis. *Clin Exp Dermatol* 2010;35:149-151.
2. Belmont MJ, Behar PM, Wax MK. Atypical presentations of actinomycosis. *Head Neck* 1999;21:264-268.
3. Brook I. Actinomycosis: diagnosis and management. *South Med J* 2008;101:1019-1023.
4. Mirza M, Sarwar M. Recurrent cutaneous actinomycosis. *Pak J Medical Sci* 2003;19:230-232.
5. Patil D, Siddaramappa B, Manjunathswamy BS, Pandit AM, Dastikop S, Fernandes C, et al. Primary cutaneous actinomycosis. *Int J Dermatol* 2008;47:1271-1273.
6. Pulverer G, Schütt-Gerowitt H, Schaal KP. Human cervicofacial actinomycoses: microbiological data for 1997 cases. *Clin Infect Dis* 2003;37:490-497.
7. Hermida MD, Della Giovanna P, Lapadula M, García S, Cabrera HN. *Actinomyces meyeri* cutaneous actinomycosis. *Int J Dermatol* 2009;48:154-156.
8. Santos JW, Zambenedetti RM, Mann KC, Cibin LF. Thoracic actinomycosis: report of a patient with advanced-stage disease. *Braz J Infect Dis* 2007;11:157-159.
9. Habibi A, Salehinejad J, Saghafi S, Mellati E, Habibi M. Actinomycosis of the tongue. *Arch Iran Med* 2008;11:566-568.
10. Ngow HA, Wan Khairina WM. Cutaneous actinomycosis: the great mimicker. *J Clin Pathol* 2009;62:766.
11. Kikiewicz D. A case of actinomycosis of the upper lip. *Czas Stomatol* 1978;31:187-189.
12. Appiah-Anane S, Tickle M. Actinomycosis-an unusual presentation. *Br J Oral Maxillofac Surg* 1995;33:248-249.
13. Lan MC, Huang TY, Lin TY, Lan MY. Pathology quiz case 1. Actinomycosis of the lip mimicking minor salivary gland tumor. *Arch Otolaryngol Head Neck Surg* 2007;133:411, 414.
14. Sánchez-Estella J, Bordel-Gómez MT, Cardeñoso-Alvarez E, Garabito-Solovera E. Actinomycosis of the lip: an exceptional site. *Actas Dermosifiliogr* 2009;100:824-826.
15. Kanna B, Soni A. Disseminated actinomycosis with unusual cardiac involvement: case report and review. *Infect Dis Clin Pract* 2002;11:408-413.
16. Belmont MJ, Behar PM, Wax MK. Atypical presentations of actinomycosis. *Head Neck* 1999;21:264-268.
17. Gayraud A, Grosieux-Dauger C, Durlach A, Salmon-Ehr V, Elia A, Grosshans E, et al. Cutaneous actinomycosis in the perianal area and buttocks. *Ann Dermatol Venereol* 2000;127:393-396.
18. Bennhoff DF. Actinomycosis: diagnostic and therapeutic considerations and a review of 32 cases. *Laryngoscope* 1984;94:1198-1217.
19. Tomb RR, Stephan F, Haddad A, Choucair J. Cutaneous granular bacteriosis, a rarely diagnosed infection of the head and the neck. *Clin Exp Dermatol* 2009;34:887-889.
20. Trutnovsky G, Tamussino K, Reich O. Short-term antibiotic treatment of pelvic actinomycosis. *Int J Gynaecol Obstet* 2008;101:203-204.