

# Passive and active middle ear implants

## Abstract

Besides eradication of chronic middle ear disease, the reconstruction of the sound conduction apparatus is a major goal of modern ear microsurgery. The material of choice in cases of partial ossicular replacement prosthesis is the autogenous ossicle. In the event of more extensive destruction of the ossicular chain diverse alloplastic materials, e.g. metals, ceramics, plastics or composites are used for total reconstruction. Their specialised role in conducting sound energy within a half-open implant bed sets high demands on the biocompatibility as well as the acoustic-mechanic properties of the prosthesis. Recently, sophisticated titanium middle ear implants allowing individual adaptation to anatomical variations are widely used for this procedure. However, despite modern developments, hearing restoration with passive implants often faces its limitations due to tubal-middle-ear dysfunction. Here, implantable hearing aids, successfully used in cases of sensorineural hearing loss, offer a promising alternative. This article reviews the actual state of affairs of passive and active middle ear implants.

**Keywords:** middle ear, implantable hearing aids, tympanoplasty, titanium, middle ear implants

Dirk Beutner<sup>1</sup>

Karl-Bernd Hüttenbrink<sup>1</sup>

<sup>1</sup> Universitäts-HNO-Klinik, Köln, Germany

## 1 Introduction

Today, modern surgical techniques almost always allow the cure of once life-threatening inflammatory processes of the middle ear. In addition, restoring of a normal hearing ear is the ultimate objective of tympanoplasty [1], [2], [3], [4]. In a society based upon communication, social hearing is, after all, essential. Unfortunately, in the half a century since the introduction of “tympanoplasty”, the audiological results have all too often been unsatisfactory [5]. Research and modern developments in passive middle ear transplants [6], [7], [8] cannot obscure the fact that factors independent of implants are just as decisive for postoperative hearing results. In many cases, restoration of a normal tubal-middle ear function cannot be influenced surgically [9], [10], and which is necessary for the aeration and proper vibration of the reconstructed middle ear structures. As well as further biological parameters (Table 1), surgeons’ own experience [11], the use of a staged reconstructive procedure [5], as well as the condition of the ossicles (e.g. an existing manubrium of malleus) [10] are all relevant factors for the prognosis for hearing recovery. If audiological rehabilitation following passive tympanoplasty is not satisfactory, conventional air conduction hearing devices are an alternative therapy. In particular in mixed hearing loss patients with their high air conduction thresholds, and problems of the auditory canal the capacity of conventional hearing aids is severely limited. Modern approaches via bone conduction might be one solution: for the past 25 years, partially implantable bone-anchored hearing aids such as the BAHA<sup>®</sup> (Bone Anchored Hearing Aid, Cochlear Company, Sydney, Australia) have been used for the rehabilitation of con-

ductive and combined hearing loss [8], [12], [13]. A further development in product technology in recent years has led to a broader range of indications [14]. Sounds are transmitted directly onto the cranial bone via an easily maintained transcutaneous connection screw, and reach the cochlea by way of bone conduction. An even more targeted stimulation of the inner ear has recently been made possible by active middle ear implants, where a variety of different connecting possibilities for implantable hearing aids are described.

## 2 Passive middle ear implants

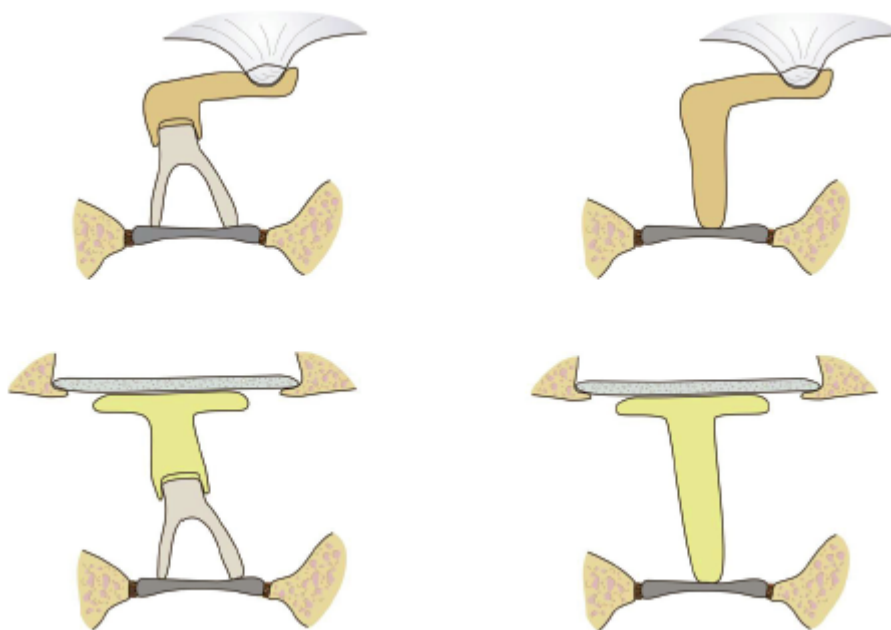
A characteristic feature of passive middle ear implants is the non-reinforced transmission of incident sound waves. Depending upon the defects to be reconstructed, the classification of tympanoplasty types formulated by Wullstein is used [1]. Figure 1 reproduces schematically the principal forms of passive middle ear implants. Here there is a differentiation made between the presence or the defectiveness of the manubrium of malleus and/or the stapes superstructure with continuingly preserved stapes footplate. In the case of the classic tympanoplasty type III, a distinction is made between the partial, short reconstruction form (PORP-Reconstruction; “Partial Ossicular Replacement Prosthesis”) mounted upon the intact stapes, and a total, long reconstruction with no stapes superstructure (TORP-Reconstruction; “Total Ossicular Replacement Prosthesis”). On the lateral side, i.e. the “receiving end”, the moulding is designed on an existing manubrium of malleus (L-form) or on the connection directly at the ear drum.

**Table 1: Implant-independent factors of postoperative hearing**

Cause	Factors
1. Resonance of the auditory canal	Canal wall down
	Canal wall up
2. Condition of the middle ear	Aeration and volume of the middle ear
	Ossicle residue
	Tympanic membrane quality
	Mucosal condition
	Scarring
3. Inner ear function	Lack of cochlea reserve
4. Individual accompanying diseases	Cleft lip plate
	Diabetes mellitus
6. Follow-up period	

**Table 2: Alloplastic materials for the production of passive middle ear implants**

Metals	Ceramics	Plastics	Ionomer cement	Carbon
Titanium	Aluminium oxide ceramic	Polyethylene		
Gold	Glass ceramic	Teflon		
Platinum	Hydroxyapatite ceramic			
Steel	Bioverit			
Tantalum	Macor			
Nickel/Titanium	Ceravital			
	Bio-glass			

**Figure 1: The classic reconstruction forms of tympanoplasty type III differentiate between either the presence or absence of a stapes superstructure (short = partial or long = total prosthesis), and also the manubrium of malleus (L or T shape).**

As well as the appropriate form, the prosthesis material is crucial for the ultimate success of the procedure: if there is intolerance, no satisfactory acoustic function can be expected.

From a biological point of view, there can be no match for the body's own material. However, the body's own ossicle residue is not always available for the required reconstruction form, or suitable for a long columella in the case of a missing stapes superstructure. Therefore in the early years of tympanoplasty, allogeneic (homologous) ossicles, usually after Cialit or formalin conservation, were referred on in great measure. In Germany at least,

strict legal regulations have managed to do away with this material which for decades has been effective. Instead, diverse alloplastic (exogenic) implant materials experimental in cell culture have been tested as alternatives, both clinically and in animal studies [6], [7]. An overview of alloplastic materials examined for ossicular chain replacement can be found in Table 2.

## 2.1 Material demands of passive middle ear implants

### 2.1.1 Clinical, biological demands

For years the search has been on for an im-plant material which is free of health risks, is cost-effectively available in a variety of forms, and which can be individually adapted intraoperatively without major additional effort. If these implants are tissue-friendly, they can be regarded as biomaterials. However, the special situation of the middle ear must be taken into account. In the case of chronic otitis media, it is contaminated or even completely infected by bacteria. The implants used must therefore not only be biocompatible, but also middle ear compatible, which should qualify them as bio-stable and non-degradable in this semi-open implant bed [6], [7], [15]. For implants to be newly developed, sufficient testing in cell culture and in animal studies is required [16], where not the muscle, but rather the aerated middle ear with its thin coat of mucous membrane must be selected as analogous implant bed. Because of this surrounding area, middle ear implants should be epithelised quickly and demonstrate good wettability. In view of the increase in imaging methods, implants should not only be MRT-compatible in order to avoid damage to the inner ear [17], but also free from any tendency to artifact in radiology. A simple and standardised connection to existing ossicle residue, which is also easily detached in revision operations, is required. Furthermore, cost-effective and standardised implant solutions should be sought in which cost calculations must also be included.

There can be no answer to the question of the ideal prosthesis, however, as it is not the material, but rather the destructive power of the inflamed middle ear which decides the future of the prosthesis (always provided there is a tissue-friendly substance). Bioactive materials such as ossicles, bones, cartilage, but also biodegradable ceramics such as glass ceramics or hydroxyapatite, are dissolved in chronically inflamed tissue layers, whereas bio-inert materials such as metals or the aluminium oxide ceramics remain intact, but are extruded (and thus appear to the patient and surgeon to be unsuitable). The non-irritant, in flammation-free middle ear tolerates almost every material, provided it is a non-toxic and tissue-friendly substance. Even teeth (dentin) [18], [19], [20] or toe nails (keratin) [21] have been successfully used. The search for the ideal prosthesis from a biological point of view invariably develops into a healing condition of the chronic middle ear in flammation: only a non-irritant, in-flammation free middle ear mucosa with unhindered tube function suggests an efficient function of the ossicular replacement due to the air level in the tympanic cavity. If there is an ongoing in flammation, no satisfactory prosthetic function will be arrived at.

### 2.1.2 Acoustic and mechanical demands

Prostheses for the reconstruction of the ossicular chain must exhibit material properties and forms, as well as biological middle ear compatibility, which qualify them for sound transmission. As the publications on clinical audiological results with a variety of materials and by individual surgeons have no great level of evidence, and generally allow no more than a limited statement on acoustic transfer properties [5], in recent years, with the availability of modern measuring techniques (Laser Doppler Vibrometry=LDV), there has been a shift from purely empirical to theoretical and experimental implant development [22], [23], [24]. The decisive acoustic factor clinically usually only recognisable with revision surgery is stable healing and thus the quality of the connection of the implant between the residue of the conductive hearing apparatus [5]. As well as the design of the prosthesis, the mass and rigidity of the material are decisive factors for acoustic transmission quality [8]. Through analyses and impedance calculations on the middle ear model, it is demonstrated that passive implants should have a higher stiffness than the sum of the impedance of stapes and inner ear [25]. In model analyses, the influence of prosthesis stiffness could be ensured on conduction at higher frequencies [26]. With the help of the LDV, which has now become the standard instrument of measurement in middle ear laboratories world-wide, it was possible for a number of research groups to demonstrate experimentally in the temporal bone model that a critical prosthesis mass of 15 mg should not be exceeded in order to allow a loss-free transfer of high frequencies in particular [8], [27]. An overview of the mechanical and acoustic demands on passive middle ear transplants is shown in Table 3.

## 2.2 Materials for passive implants

### 2.2.1 Autogenous transplants

In principal, endogenous ossicles, bone and cartilage are available here. As a relatively low impedance material, cartilage is, from an acoustic point of view, only to be used for reconstruction of the tympanic membrane, and not for procedures in the ossicular chain, since due to resorption processes with consecutive chondromalacia [28], dimensional stability decreases. Autogenous ossicular residue, incus body or malleus head, on the other hand, are regarded as the golden standard for chain reconstruction [29], if an attached cholesteatom matrix, an otitis or extensive destruction do not suggest that they are unsuitable for reuse [30]. The bone of the fitted ossicle prosthesis is replaced over the years mainly by osteoneogenesis [31]. Here the revascularisation takes place via the Havers canals [32].

In cases of inflammatory granulation tissue, on the other hand, there is a degradation of the adjoining bone [33], [34]. One fundamental risk associated with this material is the bony growth on surrounding structures such as the

**Table 3: Acoustic-mechanical demands of passive middle ear prostheses**

Middle ear compatible
Free from carcinogenic, allergenic and tissue damaging characteristics
Bio-stability (high resistance compared to endogenous degradation processes)
Excellent wettability (promotes epithelisation), exception: stapes piston
Missing bone apposition
Low weight
High mechanical rigidity
Simple handling and connection
Functional design
Avoidance of radiological artefacts and MRT compatibility

auditory canal, the promontorium or the bony canal of the facial nerve with resultant loss of transmission. A further disadvantage is the limited size of the ossicle, which means that they often appear to be too short for bridging longer distances, in the case, e.g., of petrous bone fracture or with no stapes superstructure as a long columella. Due to their porous structure with higher risk of resorption and tendency to bony growth on surrounding middle ear structure, the alternative to prostheses made from autogenous cortical bone has not proved successful [35], [36].

## 2.2.2 Allogeneic transplants

If no endogenous ossicles were available, from the 1960s to the 1980s “homogenous corpse” ossicles were the most frequently used prostheses [37], [38], [39]. However, the integration of transplants conserved in formaldehyde and cialit in the organism is evaluated slightly less favourably in comparison with autogenous ossicles [32]. The risk of infection by HIV and the typical germs connected with ear infections as a result of this conservation was negligible [40], the postulated prions of Creutzfeldt Jacob Disease (CJD) were, however, not controllable even by means of an autoclave. For this reason allogeneic ossicles in Germany can practically no longer be used. A reappraisal of the current state of research in the literature [41] was not able to verify any cases of infection with HIV or CJD following an ossicle transplant. In the two otological cases with CJD infection, in the first dura mater, and in the second pericardium were used as replacements for the tympanic membrane. In some countries, therefore, allogeneic ossicles may still be used, based on selection criteria for the donor and special processing methods [42].

Implants made from dentin [18], [19], [20] which due to their mechanical stability were extremely suitable as ossicle prostheses, can be autoclaved, but a residual risk of CJD still remains.

## 2.2.3 Alloplastic implants

Depending on the body’s reaction, alloplastic materials can basically be divided into 3 implant groups [15], [35]:

1. bio-inert
2. bio-tolerant
3. bio-active

### 2.2.3.1 Bio-inert materials

Bio-inert materials do not react with the body; they are only covered by a thin layer of mucous membrane, and are not degraded by inflammatory processes.

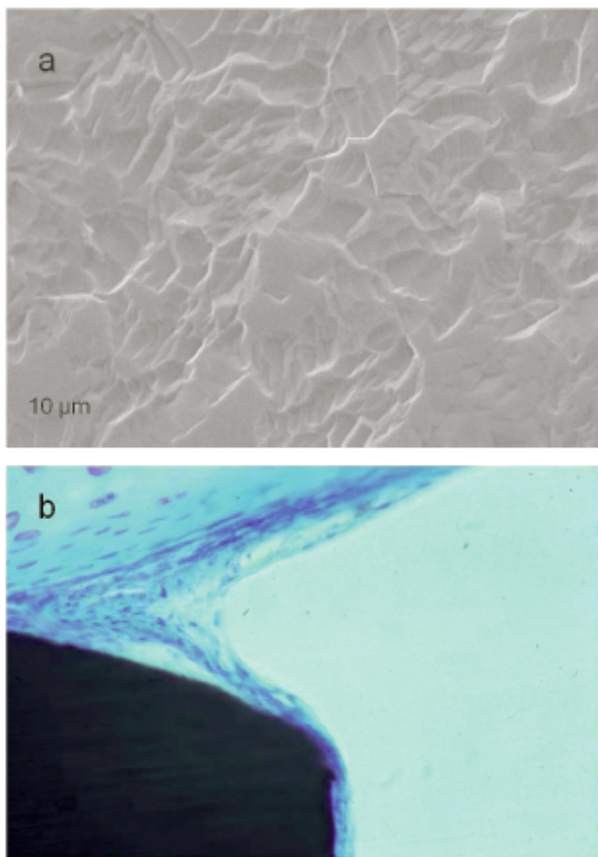
**Prostheses made from stainless steel or tantalum** were popular up into the 1980s as a versatile and cost-effective material in reconstructive middle ear surgery. Tantalum showed a non-irritable coating of mucous in the middle ear and the vestibulum three to six months after the implant [43]. Stainless steel could also be used with good functional results [44] as a combined cartilage-steel-soft tissue prosthesis [45]. The individual adaptation of the “steel prostheses” offers tailored solutions for specific demands such as in the case of malformations or malleo-vestibulopathy.

**Gold** does have a high specific weight at  $19,3 \text{ g/cm}^3$ , but due to the small dimension of a prosthesis in absolute terms, this does not have a large influence on sound transmission (at approx. 50 mg, a typical gold TORP weighs as much as the intact ossicle chain). Due to its plastic deformability, it offers mechanical benefits in intra-operative adjustment, and also has an inhibitory effect on the growth of bacteria [46]. However the compatibility of gold in the middle ear is the subject of controversy: whilst Pusalkar and Steinbach [47] were able to observe in a total of 102 patients only two with an extrusion after 3 years, other research groups reported a considerably higher rate of extrusion of up to 19% [48]. After initially favourable results [49], [50], gold piston implantations in otosclerosis surgery were also seen increasingly critically [51], as material incompatibility with a formation of repair granulomas is assumed [6], [52]. Today, gold plays a subordinate role and has been increasingly replaced by titanium [53].

**Titanium** has for many years now held a prominent place in reconstructive head and neck surgery for the osseo-integrated anchoring of epitheses in bone, thanks to the fundamental research work conducted by Branemark [54] and Tjellström [55]. It is an extremely light (specific weight  $4.5 \text{ g/cm}^3$ ) and rigid material. The high mechanical stability with simultaneous body-compatibility is due to the fact that the surface of pure titanium immediately forms a fine titanium oxide layer on contact with oxygen from air or water. This passive, ceramic layer surrounds the material protectively, makes it resistant to external influences, and represents the essential interface in bio-



logical tissue. It insulates the metal electrical conductor of endogenous electrolytes on which stability against acids and alkalis, as well as corrosion resistance, is based. The material surface area and purity are decisive for biological quality of the titanium implant. Remnants from the production process might produce unwanted reactions on the titanium surface, due to the various cleaning procedures of different manufacturers. Pure titanium is ideal for use in the middle ear, and is classified into grades 1–4, depending upon composition. This classification takes place according to increasing iron and oxygen content, with grade 1 containing the lowest additives. Figure 2a shows a titanium surface (grade 1) after purification. An MRT with a field strength of 1.5 Tesla does not result in a dislocation or rise in temperature [56]. Many titanium implants today are permitted up to 7 Tesla, although the proportion of ferromagnetic material can be limiting.



**Figure 2:** Pure titanium surface after purification (a). (Source: Kurz, Dusslingen). Irritation-free mucosa and sub-mucosa on the surface of a titanium implant in the middle ear of a rabbit (84 days, Giemsa, 288x) (b). (Source: Prof. Dr. med. Schwager, Fulda).

In the semi-open and partially inflammatory altered implant area of the middle ear, animal trials demonstrated the complete epithelisation of titanium (Figure 2b). Due to the lack of macrophages and giant cells, as well as the lack of signs of degradation on the implant [57], [58], titanium recommended itself from a biological point of view as ossicle replacement material. Osteoneogenesis

could be registered on the material, however osseointegration was proven neither in animal experiments [59], nor on explanted prostheses from the human middle ear [60]. Even before these animal studies, titanium had been clinically used as a passive implant in a large number of cases with good results [61]. This good bio-acceptability was confirmed by a number of authors [62], [63]. The acoustic advantage of titanium implants lies in their mechanical stiffness combined with low weight which allows a fine form design [64], [65], [66]. In this way anatomically unfavourable situations, such as a prolapsed facial nerve in the oval niche, are not an obstacle to implantation for the 0.2 mm thin prosthetic shafts. The design of an open prosthetic plate made possible by the mechanical characteristics allows the visualisation of the prosthetic foot during insertion. Due to the elastic characteristics of titanium, there is also the possibility of a clip mechanism for a standardised and simple connection to existing ossicles [67], [68], [69].

**Nitinol** is a nickel-titanium alloy which is covered by a layer of titanium oxide. The particular feature of this material consists of its ability to take on a shape imposed during manufacture at a temperature of 45 °C. This shape memory has been used in recent years to secure stapes prostheses to the long process of the incus in order to avoid the difficult step of manual connection. It is possible that new design ideas will be developed for future ossicle replacement prostheses. Up until now, however, the risk of distortion due to heat action, for example for the end of the eyelet at the periosteum of the incus, is not fully understood; for this reason necroses of the long process of the incus cannot be ruled out in the future. During the first postoperative months, no signs of nitinol prosthetic loosening have yet occurred [70], [71]. However, critical topics such as nickel-induced allergy development, ferromagnetic safety during future nuclear spin examinations, as well as the contradictory results in animal studies on biocompatibility must continue to be studied experimentally [72], [73], [74].

As a precious metal with a density of 21.45 g/cm<sup>3</sup>, **platinum** is characterised by extreme resilience to oxidation and corrosion. Since the introduction of the platinum-Teflon prosthesis in stapes surgery, it has been widely used for securing the piston to the long process of the incus [75]. Necroses are reported in only 0.7% [49], although it remains inconclusive whether these results are due to the material or not. The good acoustic results continue to be confirmed today [76].

**Aluminium oxide ceramic** consists of 3–5 µm large corundum crystals which are sintered into a pore-free, polycrystalline form [77]. After implantation in an animal model, a delicate coating of mucosa can be evidenced without indication of foreign body reactions [78]. The hardness of the material is responsible for the good acoustic transmission, also, however, for its quality of breaking quickly. Ceramic prostheses with diamond burs can be attached intraoperatively to individual implant situations [79]. Only after a follow-up period of four years

were very low numbers (3%) of extrusions with good functional results noted [80], [81].

### 2.2.3.2 Bio-tolerant materials

Bio-tolerant materials are initially recognised by the body as foreign substances; however, a strong capsule soon forms upon which endogenous proteins attach themselves, thus concealing the implant from the immune system [82]. Well-known examples of bio-tolerant materials are the synthetics which were introduced by Wullstein in 1949 with Paladon<sup>®</sup> as place holder in window surgery for the treatment of otosclerosis [83]. In 1952 he utilised the material vinyl resin Palavit<sup>®</sup> from dental medicine for the first time [84]. It was, however, not sufficiently compatible with the middle ear, and was rejected at an early stage.

Polyethylene was also in use as early as the 1950s in the USA [85]. As a semi-flexible, spongy substance with a pore size of 30 µm, Plastipore<sup>®</sup> (high density polyethylene sponge) is used as ossicle replacement material [86]. At first there were only histological studies on explanted prostheses, as animal experiments were not possible before clinical use. These showed a chronic inflammatory reaction with accumulations of exogenous giant cells, macrophages, cell deposits and vacuole-containing cells, which was also confirmed in later animal studies [87], [88], [89]. The extrusion rate of these prostheses is given in clinical reports as up to 38% [6]. Due to the unfavourable long-term results, the use of Plastipore<sup>®</sup> is advised against [90]. The large number of patients with rejected prostheses, and the resulting necessary follow-up operations, underlines the need for a sufficient biocompatibility test in animal studies prior to clinical application.

**Polytetrafluorethylene (Teflon)** is a plastic which has hydrophobic characteristics with low surface energy [91]. These material properties qualify Teflon particularly for stapes surgery, where Teflon is the longest and most frequently used material [92], [93]. After the first description of Shea's implantation of Teflon into the open oval window in 1956 [94], numerous publications confirmed the excellent audiological long-term stable results in the context of stapes surgery using Teflon pistons [75], [92]. Histopathological post-mortem reconditioning of stapes prostheses in temporal bones shows that after years, Teflon is covered by a thin fibrous layer without any signs of foreign body reaction [95].

**Teflon with carbon** was used as Proplast<sup>®</sup>. It is up to 90% porous and has an interconnecting pore system (100–500 µm) [96]. With human explants, multi-nuclear giant cells containing foreign bodies were found, which are regarded a foreign body reaction with degradation of the implant [97]. Due to strong foreign body reaction with consecutive rejection in animal studies, pure vitreous carbon cannot be recommended as an implant material [98], [99].

**Flex H/A<sup>®</sup>** is a composite consisting of hydroxyapatite and silastic in equal proportion. With the addition of soft silastic, treatment with the diamond drill has been con-

siderably improved in comparison to easily splintering hydroxyapatite. With the many implant variations, the prosthesis head often consists of hydroxyapatite, whilst the Flex H/A<sup>®</sup> prostheses stem is connected via a flexible titanium pin. After 3 years, an extrusion rate of approx. 5% was described alongside the excellent audiological results [100].

**HAPEX<sup>®</sup>** consists of a composition of 40% hydroxyapatite and 60% polyethylene, which should also provided the simplest surgical workability of the prosthesis shaft. The prosthesis head of these hybrid prostheses consists of hydroxyapatite, which provides good middle ear compatibility. The functional results are good [101], [102]; foreign body reactions with induction of resorption processes have not been proven [103].

### 2.2.3.3 Bio-active materials

Bio-active materials are integrated into the organism without capsule formation and develop a permanent bond. With inflammatory processes their resorption rate is raised.

**Glass ceramics** which are created by melting bio-active glass consist mainly of SiO<sub>2</sub>. On contact with surrounding endogenous substances, a layer of calcium phosphate forms on the surface from which a connection to the adjoining bone arises. The basis for the development of bio-active ceramics such as Bioglass<sup>®</sup>, which although bio-acceptable [104], was quickly degraded in the middle ear. The bio-active ceramic Macor<sup>®</sup> was introduced in 1980. In the middle ear of rabbits, these implants did exhibit a non-irritable mucosal coating, but with exogenous giant cells in sub-mucosal tissue. Ossification with the surrounding area was frequently described, and made the material appear to be unsuitable in the long-term [105]. Ceravital<sup>®</sup> was introduced into clinical otology after animal studies had shown a non-irritable healing process [106]. It cannot dissolve completely in an inflamed middle ear, however [107]. Bioverit<sup>®</sup> was developed by Beleites in Jena. It consists of a mica and a vitreous phase. The mica content determines the fact that this glass ceramic can be drilled, turned and milled. The phlogopit crystals are responsible for the easy operative workability using grinding, and the apatite crystals for bio-acceptance. Animal studies were able to show a coating of the implant with single and multi-layer epithelium. Not with bone, however [108]. A further advantage of Bioverit<sup>®</sup> in the contaminated middle ear is the inhibited growth of gram negative bacteria [109].

**Hydroxyapatite** is a natural component of bone and with a pore size of 2 µm is used as a ceramic implant, which explains the fragility and splintering tendency. Animal studies confirm the good bio-acceptance [110], but with high biodegradability [111]. The good audiological results with a low extrusion rate have been confirmed by several authors [112], [113].

**Glass ionomer cement** is produced in an exothermic reaction brought on by calcium aluminium fluorosilicate glass and the watery solution of a polyalkenoic acid which

harden on contact. In animal studies [114], as well as in clinical use [15], implants were coated with mucosa within a short time and assessed as bio-stable and middle ear compatible. It can be processed exactly with a diamond drill without splintering [115]. Glass ionomer cement was also used in liquid form as a twocomponent material for the bridging of defects of the long process of the incus [116]. Due to lethal aluminium intoxication when using the liquid material with liquor contact, it was removed from the market for use in the middle ear in 1995 [117].

## 2.2.4 Which materials are used?

At the present time there are a vast number of the aforementioned materials for ossicle chain replacement registered and commercially available. 10 years ago in the USA, a survey on the frequency of use of biomaterials revealed that hydroxyapatite was then used 82%, Plasti-pore® 59% and titanium 12% of the time [118]. Current data has shown that in recent years, in Europe at least, titanium has gone beyond the field of ceramics. Here titanium is used as a biomaterial in 68% of cases, hydroxyapatite only in 24% [119]. Plasti-pore®, on the other hand, is only used by a few centres. The delicate, light yet solid titanium implants are, according to current knowledge, easier to work with for many otologists than the relatively ungainly and voluminous ceramic prostheses with similar middle ear acceptance, where the intra-operative adjustment requires additional grinding. In a comparative clinical study, however, acoustic advantages for titanium could not be presented as significant [120] as a number of other factors influence postoperative hearing. With the selection of the implant material, individual preferences and the related experience of individual surgeons also plays an important role, so that hybrid prostheses such as HAPEX® or Flex H/A® continue to be used justifiably, based on clinical data.

## 2.3 Techniques of ossicle chain reconstruction

### 2.3.1 Reconstruction with defects of the long process of the incus

The long process of the incus is most frequently involved in defects in the ossicle chain [121]. In the past, many different materials were used to try and bridge the defect and reconstruct an intact ossicle chain. Amongst these were autogenic bones [122] or bone implants, adhesives or cements [116], [123], as well as angle prostheses made from metal [116], more recently also equipped with a clip mechanism for a stable connection to the stapes head. From an acoustic point of view, the use of adhesives and cements, if they remain fixed, is a particularly elegant solution. The sonically rigid connection then promises excellent acoustic results which are hard to achieve with cartilage and bone interposition. Cartilage

is too soft and thus only to be recommended as an implant for very small defects, e.g. in the incudostapedial joint. Bones, e.g. as a rectangular implant, may be harder, however a fixed connection is hard to achieve. One further possibility is the use of cartilage in the sense of a tympanoplasty type III, which has a recess for receiving the long process of the incus, and which is attached directly to the stapes head. The disadvantage of this reconstruction with the connection of the stapes to the rear tympanic membrane is the disabling of the functioning tympanic membrane-malleus complex which corresponds to an “acoustic short circuit”. In the case of larger defects of the long process of the incus, the endogenous incus is reformed and placed as an implant between the stapes head and the tympanic membrane, or rather the manubrium of malleus.

### 2.3.2 Connection to the manubrium of the malleus

The contact to the manubrium of the malleus has proved to be optimally suitable both in temporal bone trials [124] and in finite element calculations [125] for transmitting acoustic energy as efficiently as possible to the implant. The presence of the manubrium of the malleus also represents an important clinical audiological prognostic factor for successful ossiculoplasty [9], [10]. A further advantage of anchoring of an implant at the manubrium of the malleus is better stabilisation and higher protection from extrusion. However, bonding should not always be forced, for example in the case of badly aerated middle ear with vertical malleus or with a large distance between the manubrium of the malleus and the stapes. The required inclined angle of the prosthesis carries the post-operative risk of tipping over onto the promontorium with consecutive conductive hearing block. With a tilt of more than 45° the annular ligament is placed under tension [27], which develops into acoustic transmission loss. New prosthetic forms with a “notch” attempt to combine a flat titanium prosthesis plate with the manubrium of the malleus [126] (Figure 3a).

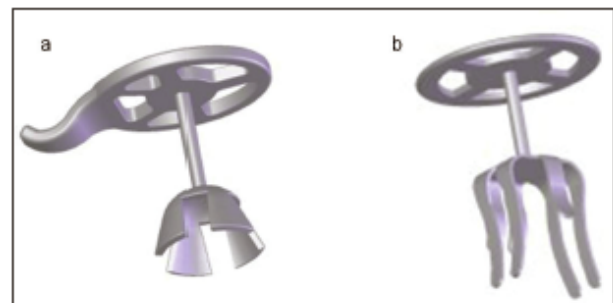
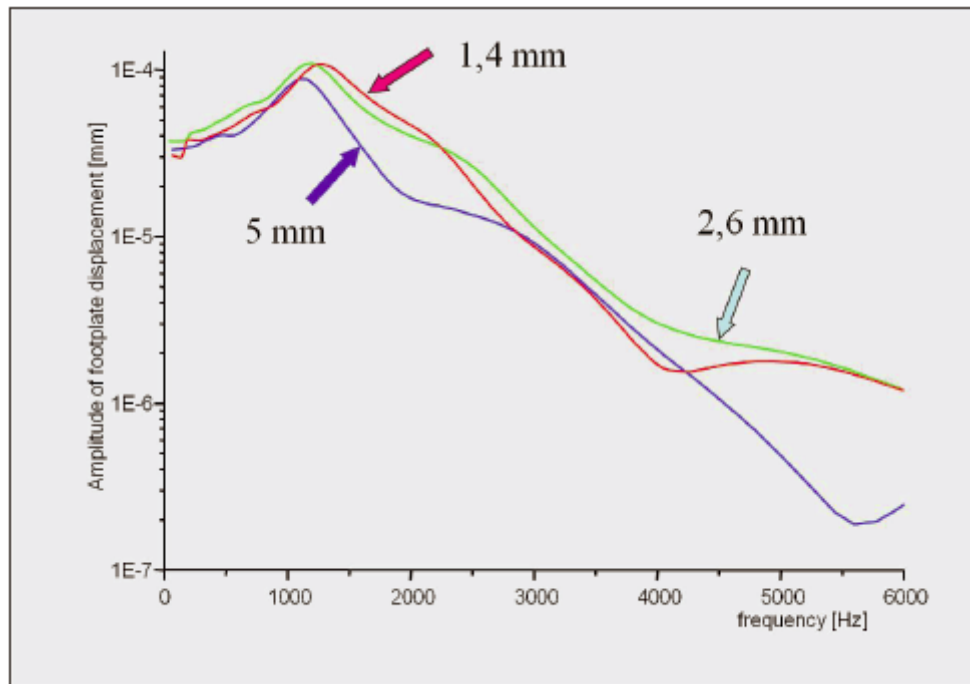


Figure 3: MNP – Malleus Notch Prosthesis partial (a) and CliP® partial prosthesis type Dresden (b). (Source: Kurz, Dusslingen).

### 2.3.3 Connection to the tympanic membrane

In the case of a missing or unusable manubrium of the malleus, implants are brought into direct contact with the



**Figure 4:** Finite element calculation of the influence of the size of the prosthetic plate on transmission behaviour in the middle ear. The frequency is plotted as a function of the amplitude of the footplate displacement for prosthetic plates of 1.4 mm, 2.6 mm and 5 mm in size.

tympanic membrane. According to its own FEM analysis, the size of the contact zone (diameter of the prosthetic plate) should be approx. 3 mm: any enlargement would raise the hydraulic amplification factor, but the hard surface increases the reflection of incident sound on the tympanic membrane, and thus worsens impedance conversion (Figure 4). With prostheses made from alloplastic materials, a cartilage covering is usually placed on the prosthetic plate in order to prevent a protrusion through the tympanic membrane, although some authors do not regard this as a necessary step using their titanium implants [127]. The thickness of the cartilage should decrease peripherally from the plate, in order to keep the attachment of the prosthesis to adjoining osseous structures, such as the auditory canal wall or the lateral semicircular canal, as small as possible in an open procedure. LDV measurements in a temporal bone laboratory confirm the acoustic superiority of smaller cartilage coverings [128]. For a stable connection between the cartilage covering and the prosthetic plate, in the case of the TTP®-VARIO prosthesis (Kurz, Dusslingen Germany) a “monospike” can be cut from the projecting shaft, or the plate has already been provided with 0.33 mm high spikes by the manufacturer [129].

### 2.3.4 Connection to the stapes superstructure

For a solid anchoring of the prosthesis to the stapes, both from an acoustic point of view as well as to avoid tilting on exposure to mechanical stress, the prosthesis should be individually adapted to the form of the stapes head. When forming an endogenous residual incus it is therefore recommended to drill longitudinally oval (in congru-

ence to the stapes head) into the residual ossicle as deeply as possible with a diamond drill for the positioning of the stapes head. With alloplastic implants there are a number of design types which establish contact in sleeve, bell or pan shape, or with an elastic clip-mechanism (Figure 3b). In order to avoid loose contacts and resonance, the prosthesis bell should be attached at 50 mN onto the stapes head [130]. An absolutely solid contact, as is achievable, for example, through bony growth or adhesion, would not however be favourable, as the removal of the prosthesis during a revision operation would bring the risk of a stapes luxation. A standardised solid, but at the same time easily resolvable, connection to the stapes superstructure allows for the clip design of a titanium prostheses with seven elastic titanium feet (Figure 3b). After optimising the shape and the spring forces in a temporal bone experiment, there were good clinical and acoustic results, as well as uncomplicated removal in the case of revision procedures [68].

One important factor for the acoustic quality is the tension with which the implants are fitted between the residues of the chain. Amongst other things, it can vary as to the prosthesis length, tilt, and also the thickness of the covering cartilage plate. Experimental investigations of this factor always suffer from the lack of quantification of the statement “loose” or “tight” fit. It was therefore possible to find a better transfer function for “loosely” fitted prostheses, particularly in the low frequency region [124]. If in doubt, however, in clinical use a stable contact with a somewhat larger prosthesis length should be chosen in order to ensure postoperative fixed contact of the prosthesis through the scarring and the resulting low lateral-



isation of the tympanic membrane level, even if there a tightening of the tympanic membrane.

### 2.3.5 Connection to the stapes footplate

In the case of the interposition of a total prosthesis (TORP) as a so-called columella, the secure centring of the foot of the prosthesis in the middle of the plate is absolutely vital. Dislocations of the prosthesis, which is only held in place by water adhesion, are the most common cause of unsatisfying hearing [131], [132]. Two factors are:

1. The diameter of the foot of the prosthesis should be small so that if there is a lateral displacement, it does not come into contact with the bony frame of the oval window. A thicker or even oval-shaped shaft or shoe increases this risk without offering any acoustic advantage. The possible danger of a fracture of the footplate with a thinner shaft diameter has proved unfounded in temporal bone experiments: physiological pressures would also never be able to fracture the stapes footplate, even with a shaft diameter of down to 0.2 mm [133].

2. A number of solutions have been suggested for a stable centring of the foot of the prosthesis, including the controversial perforation of the middle of the footplate with a wire spike at the foot of the prosthesis [127]. Added connective tissue, gelatinous sponges or pieces of cartilage can surround and stabilise the prosthesis in the oval niche. A cartilage shoe with central perforation can be produced simply by punch, and following experimental testing has also shown clinically exceptional acoustic results (Figure 5) [134], [135].

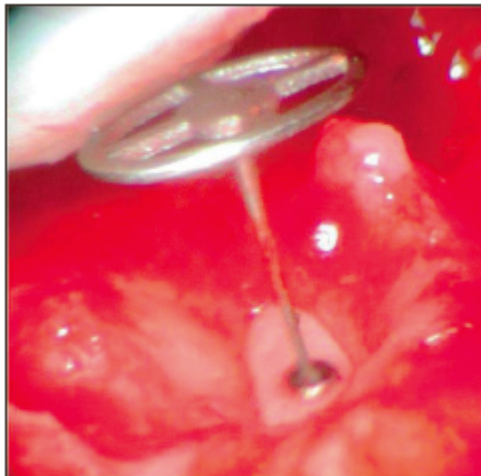


Figure 5: Cartilage shoe in the oval window with a centrally guided titanium total prosthesis.

## 2.4 Outlook

In recent years, biocompatible but partially degradable ceramics have universally been pushed into the background by light-weight and delicate titanium implants. The connection of the prosthesis has become easier and more standardised through the introduction of clip mechanisms. Combined prostheses are being developed for connection to the footplate, where prosthetic anchor-

ing is integrated osteally onto the footplate. In a further step which requires a second operation, a total prosthesis can be inserted [136].

Protection against atmospheric fluctuations in pressure should be integrated into future prostheses. With their straight alignment, these latest types of prosthesis transmit “unchecked” static ambient pressures [137]. Under consideration here is a ball-and-socket type connection between the prosthetic plate and shaft, or the integration of a silicon microjoint into the shaft of the prosthesis. As with a bird columella the shaft is deflected with atmospheric pressure fluctuation, and the risk of a trauma of the inner ear with unrestricted acoustic properties is minimised [138].

## 3 Active middle ear implants

Conventional air conduction hearing devices inserted in the auditory canal are the typical method of treatment with low or medium sensorineural and combined hearing loss. Their acceptance is significantly reduced by undesired effects:

1. Stigmatisation due to the aesthetically unpleasing hearing aid
2. Unsatisfactory hearing due to sound distortion and feedback
3. Occlusion of the auditory canal, sometimes with recurring inflammation

Conventional hearing aids resistant to moisture, and thus suitable for bathing and swimming, remain a vision for the future. However, many of the constraints related to wearing a hearing aid, such as the occlusion effect and the problem of feedback, have been reduced due to recent technological advances [139], [140] such as miniaturisation, cosmetically acceptable aids and the possibility of open or semi-open hearing systems. Along with improved sound quality, this has resulted in higher wearing comfort and higher acceptance. For severe hearing loss or steep drops in high frequency, which up until now have been unsatisfactorily provided for, hybrid cochlea implants with their electro-acoustic simulation [141] represent a completely new technology. For active middle ear implants, the audiological indication spectrum has recently been considerably restricted, and is mostly reducible with pure sensorineural hearing loss to medical (auditory canal problems) or cosmetic reasons. A previously little noticed, but almost exclusive indication for implantable hearing aids which has long been followed in temporal bone experiments [142], seems to be developing for conductive or mixed hearing losses through new operating procedures.

### 3.1 Principle of active middle ear implants

Middle ear implants whose function depends upon external energy supply are classified as active [143]. A distinc-

tion is made between partially implantable (only the transducer is im-plantable) and fully implantable devices, where a microphone and power supply are implanted. Other than with conventional air conduction hearing devices, the enhanced electrical signals are not converted into airborne sound energy, but rather into mechanical vibrations which are either connected to the anatomical structure of the sound conduction apparatus (tympanic membrane or ossicle), or fed directly into the cochlea without occluding the auditory canal [144]. A key role is played here by the electromechanical transducer which is applied with currently approved equipment in electromagnetic or piezoelectric functionality [143], [145].

### Electromagnetic transducer

The basic principle of an electromagnetic transducer is the generation of vibrations through a regulated variable force between an electric coil through which a current flows, and a magnet [146]. Here the magnet can be located either inside or outside the coil.

### Piezoelectric transducer

Piezoelectric crystals are able to carry out a relative change in length with an applied voltage. This characteristic is reversible, in other words a mechanical conformational change (movement), and conversely mechanical movement results in an electrical voltage [147]. Both systems have their specific advantages and disadvantages as electromechanical transducers in active middle ear implants. The efficiency of electromagnetic transducers sinks considerably as the distance increases from the coil and magnet, so that in order to increase efficiency, both should form a single unit. They have higher maximum output amplitude than the piezoelectric transducers, which can, however, be compensated by stringing together several piezo crystals. On the other hand, electromagnetic transducers use more energy with similar acoustic capacity, which can be disadvantageous for use in fully implantable systems. Piezoelectric transducers continue to have advantages due to their low tendency to distortion [148], but they also have disadvantages due to their rigidity with the related rise in resistance of the conductive apparatus on connection to the ossicle. MRT compatibility cannot at present be expected from electromagnetic systems.

## 3.2 Current approved active middle ear implants

The history of implantable hearing devices began as early as 1935, when Wilksa suggested placing small magnets (10 mg) onto the tympanic membrane controlled by a magnetic field generated by a coil in the outer auditory canal [149]. Suzuki and Yanagihara [150], [151] were the first to insert a semi-implantable piezoelectric device in a human with at present more than 10 years' long-term results [152]. Approval for this "rion device E-type" was

at first limited to university institutions in Japan. A further stage in development was the fully implantable system TICA<sup>®</sup> (Total Implantable Cochlear Amplifier) manufactured by the Implex company [153] which is also no longer produced. This piezoelectric system was capable of increasing higher frequencies very effectively. The microphone placed under the skin of the auditory canal led to feedback, however [154], which required an interruption of the ossicle chain. In the Soundtec Direct Drive Systems<sup>®</sup> device, a samarium cobalt magnet with a holding ring was put over the stapes capitulum [155]. It had reached market maturity in the USA and was advertised with the low costs of the implant, as well as the simple ambulatory tympanotomy carried out under local anaesthesia to insert the implant. The necessary severing of the incudostapedial joint and the position of the stimulating coil in the outer auditory canal are unfavourable, however, and do not constitute any improvement over conventional hearing aids. This device is no longer produced although research for the development of a fully implantable system is being undertaken [156].

Recently, several concepts for active middle ear implants, as well as the possibilities of connection them, are being presented in numerous experimental and clinical applications. Due to the brief scope of this paper, reviews are referred to in which the historical development and basic principles are comprehensively presented [143], [145]. In the following, only the current state of the CE-certified, and therefore the active middle ear devices approved for use on the European market, will be described.

### 3.2.1 Vibrant Soundbridge<sup>®</sup> (MedEl, Innsbruck, Austria)

This partially implantable hearing device functions with electromagnetic transducer technology. The external components are contained by the audio processor, the microphone, the battery as well as the transmitter coil and a magnet. It absorbs the acoustic energy, processes it and passes it on transcutaneously to the internal components. Here it is demodulated and transformed into vibration energy by the electromagnetic transducer. The VORP (Vibrating Ossicular Prosthesis) transducer consists of a receiver with coil and processor element, as well as a magnet corresponding to external components. The processor (demodulator) converts the transcutaneously conducted signal into one which is adequate for the electromagnetic transducer. This is then introduced to the Floating Mass Transducer (FMT) via an electrical cable. This actuator uses the rebound force of a moving permanent magnet in a hermetically sealed coil. This stands still whilst the coil vibrates as an outer casing. Since the first implantation in 1996, the Vibrant Soundbridge<sup>®</sup> is the most extensively distributed worldwide, with more than 3,000 implantations.

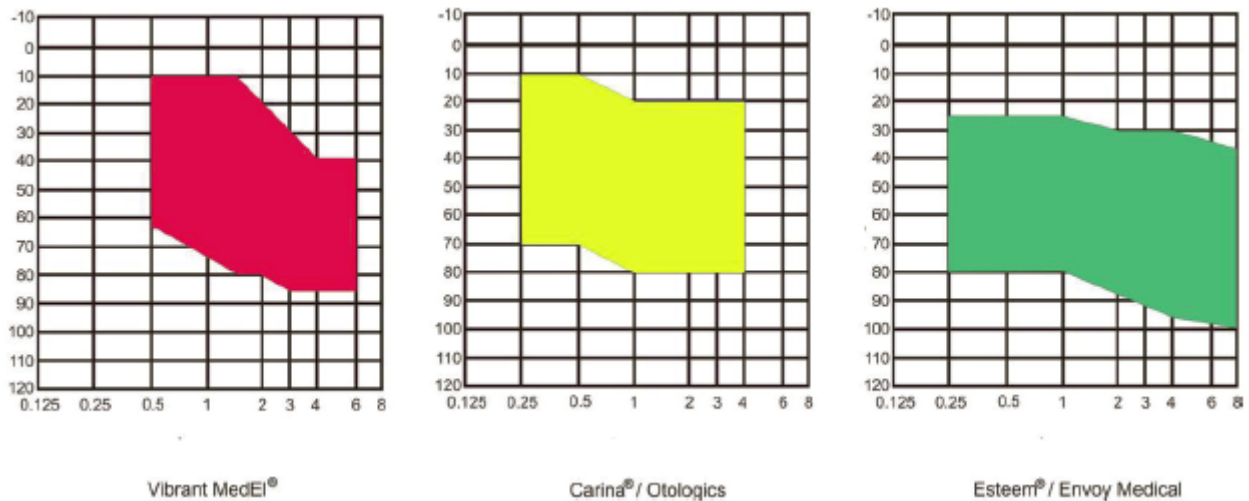


Figure 6: Audiological indication areas of implantable hearing devices, according to manufacturer's data, for the treatment of sensorineural hearing loss.

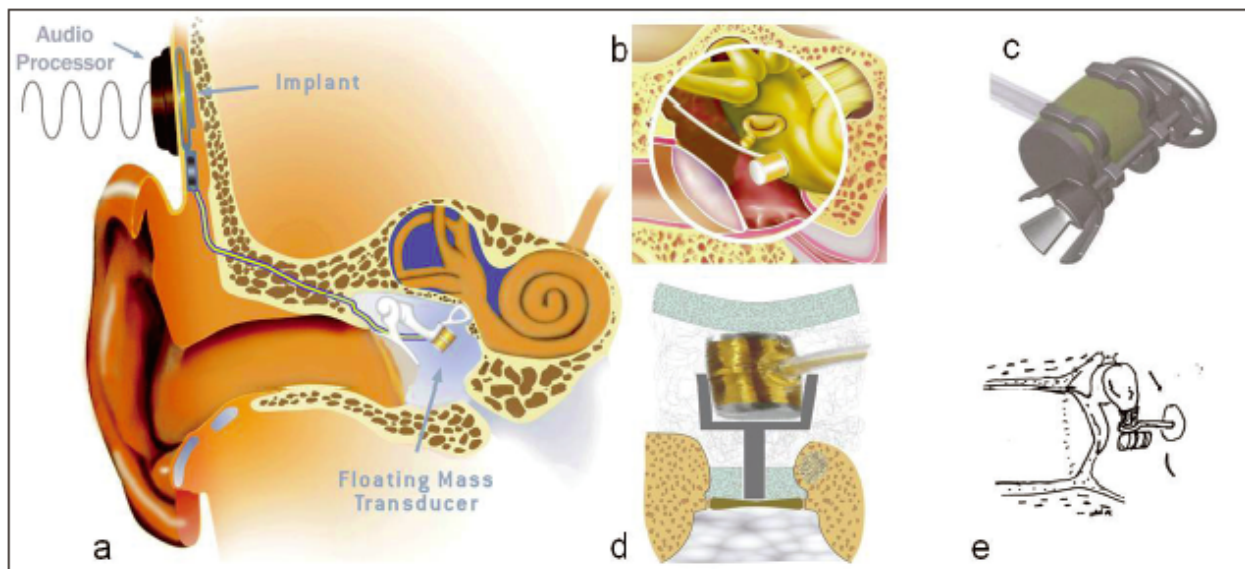


Figure 7: The partially implantable system Vibrant Soundbridge® (MedEl, Innsbruck, Austria). Classic vibroplasty with connection to the long process of the incus (a). Alternative connections of the FMT: to the round window (b), laterally on a Bell prosthesis (c), linearly as a TORP vibroplasty (d) and next to a stapes piston (e) (Source: MedEl, Innsbruck, Austria).

**Vibrant Soundbridge® (VSB) in sensorineural hearing loss**

As an indication, only pure sensorineural hearing loss with the indication area represented in Figure 6 was approved. The surgical approach resembles the CI-operation: transmastoidally the FMT is attached with its titanium clip to the long process of the incus via posterior tympanotomy with a special closing forceps (Figure 7a). A transcanal access is an option [157]. The attachment of the FMT takes place parallel to the vertical axis of the stapes. The VORP is set in an appropriately drilled out bone bed. The audiological indication is mild to moderate hearing loss with low losses of up to 1 kHz, whereas due to the better efficiency of the transducer in a higher frequency range, stronger losses can be compensated [158], [159]. The highest auditory threshold gain is between 1 and 2 kHz between 28–37 dB [160], [161], [162], [163] with

good long-term stability [164]. It is not so much the gain in loudness which is decisive for high patient satisfaction, but rather the clear and undistorted auditory impression based particularly upon good high frequency amplification, which is the weak point of conventional air conduction hearing devices. Several studies compare the audiological results between conventional hearing aids and the VSB [165], [166], [167], [168]. Thus the VSB delivers better results in speech understanding in quiet and with background noise than a conventional air conduction hearing device which uses an identical signal technique from Siemens [166]. In further studies with conventional hearing aids from other manufacturers, however, this superiority could not be confirmed either for speech understanding in quiet or with background noise. In view of the operative risks and the potentially associated side-effects such as haematoma, gustatory disorders, MRT



incompatibility, as well as reports of technical implant failures [160], [168], [169], application at present is to be recommended only if it is medically necessary [167], [168].

### Vibrant Soundbridge® in mixed hearing loss

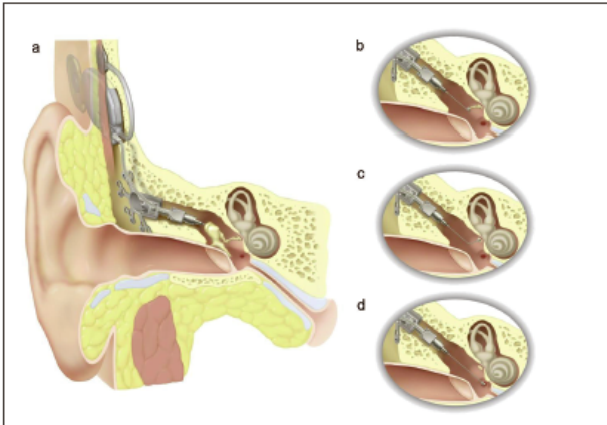
Conductive hearing loss represents a new indication for implantable hearing devices, also combined with an inner ear disorder, as occurs with an operatively no longer correctable functional disorder of the middle ear as a result of a chronic inflammation of the middle ear or with malformations of the outer and middle ear. Here the FMT is connected to the membrane of the round window [170], [171], [172] (Figure 7b). This positioning, however, is not always unproblematic as considerable anatomical variations of the only tangentially visible round window niche and mucosal folds or scar tissue are present over the actual membrane. For the required large surface contact between FMT (2 mm<sup>2</sup>) and the generally much smaller round window membrane (on average 1.4 mm<sup>2</sup> [173]), the bony lip of the round window niche must always be drilled. This drilling requires great care without touching the membrane with the drill, considering the confined, tilted access through the posterior tympanotomy and the sound level being potentially damaging to the middle ear. For an improvement of contact to the membrane and to avoid touching the surrounding bone, coating the FMT with connective tissue is recommended. These incalculable contact problems, along with the threat of atrophy of the contact tissue coating with weakening contact, might explain the large variability in hearing with the round window application [170], [171], [174].

An integration of the transducer into the physiological direction of sound, i.e. via the oval window, might avoid these problems. Through a combination of a Bell titanium prosthesis (Bellvibroplasty) with the FMT, a passive implant is turned into an "active middle ear prosthesis" (Figure 7c) [175]. The selected lateral fastening of the FMT to the prosthetic shaft can, however, encourage tilting of the prosthesis. A linear integration of the FMT in a titanium column with fastening in a clip mechanism avoids this disadvantage. This construction is familiar to otological surgeons as, like a TORP, it is placed on the footplate and secured there with a cartilage shoe (Figure 7d) [176]. The first clinical results of this standardised connection confirm the high amplification level demonstrated in the previous temporal bone experiment. With an intact stapes superstructure, attachment with a clip mechanism is also possible. One further promising indication area of the VSB is otosclerosis surgery where the FMT is attached next to a stapes piston on the long process of the incus, e.g. in order to rehabilitate associated perception hearing impairment (Figure 7e) [177], [178].

### 3.2.2 Middle Ear Transducer® (MET) (Otologics, Boulder, USA)

The MET was initially conceived as a semi-implantable hearing aid [179] which is currently still available on request, as the CARINA® offers a fully implantable available version [180] (Figure 8). It consists of a transducer, a receiver element, power source (rechargeable battery), sound processor and microphone. The electromagnetic transducer is attached to the cortex of the opened mastoid with at least 3 bone screws via retro-auricular access, and connected with the body of the incus via antrotomy, guided by a linking rod (Figure 8a). For this, a 1 mm deep trough is first formed in the body of the incus to house the rod using a fibre-coupled diode laser [181]. After installing the transducer, the exact position of the linking rod to the incus has to be adapted using a micromanipulator. The ossicle chain may not be displaced too much from its central position by the bone-mounted transducer in order not to cause a tension of the hanging ligaments, and thus a transmission deficit. The electromagnetic transducer element where force on the ossicle is not based upon the "actio=reactio" principle of an accelerated mass, as is the case with the VSB, but rather where the reactive power is absorbed by a fixation of the implant on the mastoid bone, makes effective use of the energy expended. This will help to achieve somewhat higher amplification than the VSB, which is why the MET is particularly suitable for patients with moderate to severe sensorineural hearing loss with an increase in auditory threshold of 40 dB between 1–3 kHz [182]. The subcutaneous microphone is situated behind the auricle and thus cannot make use of the directivity and amplification properties of the outer ear. It has to be placed in such a way that movement of the adjacent temporal muscle does not cause any undesirable artefacts. The advantage of the full implantation is that the patients are able to use it without restriction (e.g. even when swimming). A disadvantage is the surgically performed replacement of the accumulator battery which has a functioning life guaranteed by the manufacturer of 5 years. With an average use of 16 hours a day, a daily charge cycle of 60 minutes is required. The MET has been CE approved since 2000, and has been used world-wide in several hundred patients. The indication limits have now also been extended to combined and conductive hearing loss. For this purpose, manufacturer offers coupling devices for the stapes superstructure, the footplate and the membrane of the round window (Figure 8b–d). Initial operative successes in the context of malformations of the ear [183] as well as in otosclerosis surgery [178] have been reported.



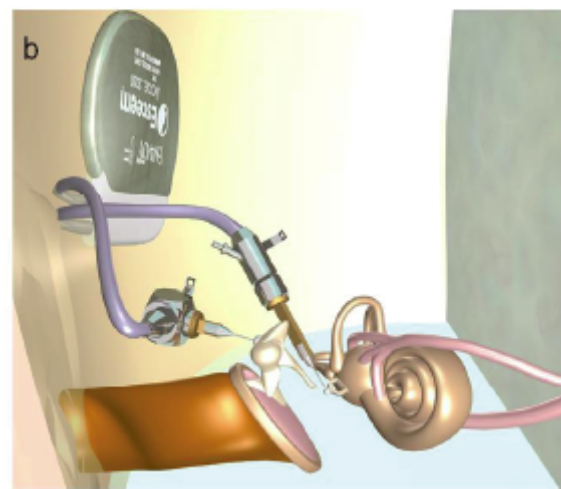


**Figure 8:** The fully implantable hearing device Carina® (Otologics, Boulder, USA). Classic connection to the incus body (a). Alternative connections: to the stapes superstructure (b), footplate (c) and the round window membrane (d). (Source: Otologics, Boulder, USA).

### 3.2.3 Esteem® (Envoy Medical Corporation, Saint Paul, USA)

This fully implantable device (Figure 9a) has had CE approval since May 2006. A piezoelectric rod functions as a microphone and taps the vibrations of the incus body whereby the tympanic membrane as well as the polar pattern and amplification function of the outer ear are used. The stapes is also powered by rod-like piezo-crystal (Figure 9b). As this construction would not function due to the feedback from the ossicle chain, a CO<sub>2</sub> laser is used to interrupt the continuity of the ossicle chain on the long process of the incus. The piezoelectric sensory and actuating elements are fixed in the mastoid, on the incus body and the stapes head using cement. The fixing of the sensor should not be rigid, but rather an articulated gap between incus and sensor should pick up system stress on atmospheric pressure change. The piezoelectric driver is firmly cemented at the stapes head. Sensor and driver are connected to the processor battery element, which is found in a parietal bone bed. The electric signals of the vibrations picked up by the incus sensor are, after filtering and amplification by the processor, transferred to the stapes driver. The implanted battery must be surgically replaced at regular intervals (actual durability according to the manufacturer: up to 9 years). As well as the energy-saving piezo-transducer, digital technology has also been ignored in favour of analog, energy-effective components. This system in the illustrated induction area (Figure 6) is approved for sensorineural hearing loss. First results of the phase I study [184] showed functional implants in 3 out of 7 cases after a follow-up period of 10 months. Compared to conventional hearing devices, the Esteem® implant produced worse results after 10 months, in both sound and speech audiometric results, on consecutive fall in amplification power over the follow-up period. More recent clinical data with improved instrument technology are unfortunately not available. The obligatory chain destruction is both clinically and ethically questionable. The

iatrogenic air-bone gap is added to sensorineural hearing loss resulting in a mixed hearing impairment. Whether in the case of a failure of individual components (long-term stability of the cemented contacts, etc.), not yet adequately tested, a conventional hearing device can then allow the patient social hearing ability via the substantially increased air conduction threshold, is questionable.



**Figure 9:** The fully implantable system Esteem® (Envoy Medical, St. Paul, USA) Implant with sensor and actuator (a). Positioning of the implant with connection of the sensor to the body of the incus, and the actuator at the stapes head after interrupting the ossicular chain at the long process of the incus (b). (Source: Envoy Medical, St. Paul, USA).

## Acknowledgement

We would like to thank Dipl. Ing. M. Bornitz, Technical University Dresden, for the finite element calculation. Mrs Koch-Metge for her support with creating the graphics, and also the Kurz company in Dusslingen; Prof. Dr. Schwager, Fulda; Medel company, Innsbruck, Austria; Otologics, Boulder, USA; Envoy Medical, St. Paul, USA for kindly supplying the images.

## References

1. Wullstein H. Operationen zur Verbesserung des Gehöres. Stuttgart: Thieme; 1968.
2. Zöllner F. The principles of plastic surgery of the sound-conducting apparatus. *J Laryngol Otol.* 1955;69(10):637-52.

3. Hildmann H, Sudhoff H, Jahnke K. Grundzüge einer differenzierten Cholesteatomchirurgie. *Laryngo-Rhino-Otol.* 2000;79:373-95. DOI: 10.1055/s-2000-15919
4. Zahnert T. Gestörtes Hören. Chirurgische Verfahren. *Laryngo-Rhino-Otol.* 2005;84(Suppl 1):S37-50. DOI: 10.1055/s-2005-861139
5. Hüttenbrink KB. Zur Rekonstruktion des Schalleitungsapparates unter biomechanischen Gesichtspunkten. *Laryngo-Rhino-Otol.* 2000;79:23-51. DOI: 10.1055/s-2000-15917
6. Dost P. Biomaterialien in der rekonstruktiven Mittelohrchirurgie. *Laryngol Rhinol Otol.* 2000;79:53-72. DOI: 10.1055/s-2000-15918
7. Geyer G. Materialien zur Rekonstruktion des Schalleitungsapparats. *HNO.* 1999;47(2):77-91.
8. Zahnert T. Laser in der Ohrforschung. *Laryngo-Rhino-Otol.* 2003;82(Suppl 1):S157-S80. DOI: 10.1055/s-2003-38931
9. De Vos C, Gersdorff M, Gerard JM. Prognostic factors in ossiculoplasty. *Otol Neurotol.* 2007;28(1):61-7. DOI: 10.1097/O1.mao.0000231598.33585.8f
10. Yung M, Vowler SL. Long-term results in ossiculoplasty: an analysis of prognostic factors. *Otol Neurotol.* 2006;27(6):874-81. DOI: 10.1097/O1.mao.0000226305.43951.13
11. Charlett SD, Scott AR, Richardson H, Hawthorne MR, Banerjee A. Audiometric outcomes of tympanoplasty with hydroxylapatite prosthesis: consultant versus trainees. *Otol Neurotol.* 2007;28(5):678-81.
12. Tjellstrom A, Hakansson B. The bone-anchored hearing aid. Design principles, indications, and long-term clinical results. *Otolaryngol Clin North Am.* 1995;28(1):53-72.
13. Tjellstrom A, Hakansson B, Granstrom G. Bone-anchored hearing aids: current status in adults and children. *Otolaryngol Clin North Am.* 2001;34(2):337-64. DOI: 10.1016/S0030-6665(05)70335-2
14. Snik AF, Mylanus EA, Proops DW, Wolfaardt JF, Hodgetts WE, Somers T et al. Consensus statements on the BAHA system: where do we stand at present? *Ann Otol Rhinol Laryngol Suppl.* 2005;195:2-12.
15. Geyer G. Implantate in der Mittelohrchirurgie. *Eur Arch Otorhinolaryngol Suppl.* 1992;1:185-221.
16. Jahnke K. Fortschritte in der Mikrochirurgie des Mittelohres. *HNO.* 1987;35(1):1-13.
17. Hüttenbrink KB. Verschiebung einer Schuknecht-Prothese bei Schädel-MRT. *HNO.* 1997;45(5):401.
18. Hüttenbrink KB, Lindorfer HW. Zähne als Prothesenmaterial zur Rekonstruktion der zerstörten Ossikelkette. *HNO.* 1993;41(9):440-5.
19. Hartwein J, Donath K, Koch U. Erste Erfahrungen mit der Dentin-Ossikel-Prothese. *Laryngo-Rhino-Otol.* 1989;68(4):204-8. DOI: 10.1055/s-2007-998318
20. Stewart IA, Kuijpers WJ, Gibb AG. Dentine as a material for ossicular reconstruction. *J Laryngol Otol.* 1976;90(2):153-5. DOI: 10.1017/S0022215100081901
21. Misurya VK, Kirtane MV, Gutpa KR, Shrivastava PK, Varshney P. Secondary neotympanic membrane and total ossicular chain reconstruction. A preliminary report. *Arch Otolaryngol.* 1980;106(9):557-9.
22. Goode RL, Nishihara S. Experimental models of ossiculoplasty. *Otolaryngol Clin North Am.* 1994;27(4):663-75.
23. Hüttenbrink KB. Akustisch optimierte Mittelohrprothesen. Neue Techniken zur zukünftigen Erforschung und Entwicklung verbesserter Implantate. *HNO.* 1997;45(7):509-11.
24. Rosowski JJ, Merchant SN. Mechanical and acoustic analysis of middle ear reconstruction. *Am J Otol.* 1995;16(4):486-97.
25. Merchant SN, McKenna MJ, Rosowski JJ. Current status and future challenges of tympanoplasty. *Eur Arch Otorhinolaryngol.* 1998;255(5):221-8. DOI: 10.1007/s004050050047
26. Meister H, Walger M, Mickenhagen A, Stennert E. Messung der Schwingungseigenschaften von Mittelohrimplantaten mit einem mechanischen Mittelohrmodell. *HNO.* 1998;46(3):241-5.
27. Nishihara S, Goode RL. Experimental study of the acoustic properties of incus replacement prostheses in a human temporal bone model. *Am J Otol.* 1994;15(4):485-94.
28. Bahmad F Jr, Merchant SN. Histopathology of ossicular grafts and implants in chronic otitis media. *Ann Otol Rhinol Laryngol.* 2007;116(3):181-91.
29. Geyer G, Rucker J. Ergebnisse der Tympanoplastik Typ III mit autogenem Amboß sowie Ionomerzement und Titanimplantaten. *Laryngorhinootologie.* 2002;81(3):164-70. DOI: 10.1055/s-2002-25031
30. Stankovic M. Applicability of autologous incus: the influence of age and localization of cholesteatoma. *Eur Arch Otorhinolaryngol.* 2007;264(9):995-8. DOI: 10.1007/s00405-007-0293-1
31. Lang J, Kerr AG, Smyth GD. Transplanted ossicles after two decades. *J Laryngol Otol.* 1989;103(5):471-2. DOI: 10.1017/S0022215100156658
32. Hildmann H, Karger B, Steinbach E. Ossikeltransplantate zur Rekonstruktion der Schallübertragung im Mittelohr. Eine histologische Langzeituntersuchung. *Laryngo-Rhino-Otol.* 1992;71(1):5-10. DOI: 10.1055/s-2007-997235
33. Eitschberger E. Gefäßentwicklung in Ossikulatransplantaten und -implantaten. *Laryngol Rhinol Otol.* 1980;59(4):238-43. DOI: 10.1055/s-2007-1008849
34. Steinbach E. Zur Bedeutung der unveränderten Gehörknöchelchenform bei Transplantationen im menschlichen Mittelohr. *Arch Klin Exp Ohren Nasen Kehlkopfheilkd.* 1973;205(2):146-9. DOI: 10.1007/BF02412525
35. Hüttenbrink KB. Die Chirurgische Therapie der chronischen Otitis media. III: Mittelohrrekonstruktion. *HNO.* 1994;42(11):701-18.
36. Kley W, Draf W. Histologische Untersuchungen über autotransplantierte Gehörknöchelchen und Knochenstückchen im Mittelohr beim Menschen. *Acta Otolaryngol.* 1965;59:593-603.
37. Chiossone E. Homograft ossiculoplasty: long-term results. *Am J Otol.* 1987;8(6):545-50.
38. Silverstein H, McDaniel AB, Lichtenstein R. A comparison of PORP, TORP, and incus homograft for ossicular reconstruction in chronic ear surgery. *Laryngoscope.* 1986;96(2):159-65. DOI: 10.1288/00005537-198602000-00006
39. Wehrs RE. Homograft ossicles in tympanoplasty. *Laryngoscope.* 1982;92(5):540-6. DOI: 10.1288/00005537-198205000-00015
40. Hüttenbrink KB, Weidenfeller P. Sind Cialitkonservierte Ossikel als Mittelohrimplantate bakteriologisch noch vetretbar? *Laryngo-Rhino-Otol.* 1990;69(6):327-32. DOI: 10.1055/s-2007-998202
41. Lubbe D, Fagan JJ. Revisiting the risks involved in using homograft ossicles in otological surgery. *J Laryngol Otol.* 2008;122(2):111-5. DOI: 10.1017/S0022215107000795
42. Romualdez JA, Stauffer E, Hasler R, Hotz MA. A new ossicle homograft inactivation/preservation procedure: clinical results. *ORL J Otorhinolaryngol Relat Spec.* 2005;67(1):34-8. DOI: 10.1159/000084297
43. Schuknecht HF, Oleksiuk S. The metal prosthesis for stapes ankylosis. *AMA Arch Otolaryngol.* 1960;71:287-95.

44. Plester D. Die Anwendung prothetischen Materials im Mittelohr. *Monatsschr Ohrenheilkd Laryngorhinol.* 1968;102(2):105-9.
45. Gerhardt HJ. Die komminierte Knorpel-Draht-Bindegewebeprotthese in der Tympanoplastik. *Z Laryngol Rhinol Otol.* 1969;48(3):227-33.
46. Heumann H, Steinbach E, Seuffer R. Über die Anwendbarkeit von Paukenröhrchen aus Edelmetall. *Laryngo-Rhino-Otol.* 1982;61(1):17-9. DOI: 10.1055/s-2007-1008511
47. Pusalkar A, Steinbach E. Gold implants in middle ear reconstructive surgery. In: Yanagihara N, Suzuki J, eds. *Transplants and Implants in Otolology II.* Matsuyama, Japan; 1992. p. 111-113.
48. Gjuric M, Schagerl S. Gold prostheses for ossiculoplasty. *Am J Otol.* 1998;19(3):273-6.
49. Schimanski G. Die Arrosion und Nekrose des langen Ambossschenkels nach Otoskleroseoperation. *HNO.* 1997;45(9):682-9.
50. Tange RA, de Bruijn AJ, Grolman W. Experience with a new pure gold piston in stapedotomy for cases of otosclerosis. *Auris Nasus Larynx.* 1998;25(3):249-53. DOI: 10.1016/S0385-8146(98)00008-X
51. Jahnke K, Dost P, Missfeldt N. Revisionen nach Stapes-Chirurgie. *HNO.* 1999;47(47):427.
52. Tange RA, Schimanski G, van Lange JW, Grolman W, Zuur LC. Reparative granuloma seen in cases of gold piston implantation after stapes surgery for otosclerosis. *Auris Nasus Larynx.* 2002;29(1):7-10. DOI: 10.1016/S0385-8146(01)00106-7
53. Schneider K, Hagen R. Sind die Titan-Implantate dem Gold im Mittelohr überlegen? *Laryngo-Rhino-Otol.* 2003;82(7):486-9. DOI: 10.1055/s-2003-40900
54. Branemark PI. Osseointegration and its experimental background. *J Prosthet Dent.* 1983; 50(3):399-410. DOI: 10.1016/S0022-3913(83)80101-2
55. Tjellstrom A, Hakansson B, Lindstrom J, Branemark PI, Hallen O, Rosenhall U et al. Analysis of the mechanical impedance of bone-anchored hearing aids. *Acta Otolaryngol.* 1980;89(1-2):85-92.
56. Kwok P, Waldeck A, Strutz J. Wie verhalten sich metallhaltige Mittelohrimplantate in der Kernspintomographie? *Laryngo-Rhino-Otol.* 2003;82(1):13-8. DOI: 10.1055/s-2003-36905
57. Schwager K. Titanium as an ossicular replacement material: results after 336 days of implantation in the rabbit. *Am J Otol.* 1998;19(5):569-73.
58. Schwager K, Geyer G. Titanium and glassionomer cement as ossicular replacement materials: biocompatibility results after implantation in the rabbit. *ORL J Otorhinolaryngol Relat Spec.* 1998;60(6):322-8. DOI: 10.1159/000027618
59. Schwager K. Titanium as a biomaterial for ossicular replacement: results after implantation in the middle ear of the rabbit. *Eur Arch Otorhinolaryngol.* 1998;255(8):396-401. DOI: 10.1007/s004050050086
60. Schwager K. Titan als Material zum Gehörknöchelchenerersatz - Grundlagen und klinische Anwendung. *Laryngo-Rhino-Otol.* 2002;81(3):178-83. DOI: 10.1055/s-2002-25037
61. Stupp CH, Stupp HF, Grün D. Gehörknöchelchenerersatz mit Titan-Prothesen. *Laryngol Rhinol Otol.* 1996;75(6):335-7. DOI: 10.1055/s-2007-997590
62. Böhm F, Eisenacher S, Büter JSM. Titanimplantate im Mittelohr - Ergebnisse einer klinischen Kontrolle. *HNO.* 1999;47:430.
63. Elies W, Lenz E, Dalchow C. Ein neuer TORP aus Rein-Titan - Design und klinische Ergebnisse. *HNO.* 1999;47:431.
64. Begall K, Zimmerman H. Rekonstruktion der Gehörknöchelchenkette mit Titan-Implantaten. *Laryngo-Rhino-Otol.* 2000;79(3):139-45. DOI: 10.1055/s-2000-298
65. Maassen MM, Lowenheim H, Pfister M, Herberhold S, Jorge JR, Baumann I et al. Surgical-handling properties of the titanium prosthesis in ossiculoplasty. *Ear Nose Throat J.* 2005;84(3):142-9.
66. Yung M. Long-term results of ossiculoplasty: reasons for surgical failure. *Otol Neurotol.* 2006;27(1):20-6. DOI: 10.1097/01.mao.0000176173.94764.f5
67. Hausler R, Steinhart U. A new self-fixing and articulated malleus grip stapedectomy prosthesis. *Adv Otorhinolaryngol.* 2007;65:197-201. DOI: 10.1159/000098807
68. Hüttenbrink KB, Zahnert T, Wustenberg EG, Hofmann G. Titanium clip prosthesis. *Otol Neurotol.* 2004;25(4):436-42. DOI: 10.1097/00129492-200407000-00006
69. Wengen DF. A new self-retaining titanium clip stapes prosthesis. *Adv Otorhinolaryngol.* 2007;65:184-9. DOI: 10.1159/000098805
70. Hornung J, Zenk J, Schick B, Wurm J, Iro H. Einsatz eines Nickel-Titan Pistons mit Memory Eigenschaften. *HNO.* 2007;55(2):104-8. DOI: 10.1007/s00106-006-1432-5
71. Rajan GP, Diaz J, Blackham R, Eikelboom RH, Atlas MD, Shelton C et al. Eliminating the limitations of manual crimping in stapes surgery: mid-term results of 90 patients in the Nitinol stapes piston multicenter trial. *Laryngoscope.* 2007;117(7):1236-9. DOI: 10.1097/MLG.0b013e31805c9a5c
72. Beutner D, Huttenbrink KB. Einsatz eines Nickel-Titan Pistons mit Memory Eigenschaften. *HNO.* 2007;55(11):848-9. DOI: 10.1007/s00106-007-1609-6
73. Enatsu K. Utilization of Ni-Ti shape memory alloy for ossicular prosthesis and its biocompatibility with the incus of cats. *Otologia Fukuoka.* 1986;32:256-69.
74. Kasano F, Morimitsu T. Utilization of nickel-titanium shape memory alloy for stapes prosthesis. *Auris Nasus Larynx.* 1997;24(2):137-42. DOI: 10.1016/S0385-8146(96)00026-0
75. Plester D, Cousins VC. Otosclerosis: its modern surgical management. *Br J Clin Pract.* 1986;40(10):401-3.
76. Mangham CA Jr. Titanium CliP piston versus platinum-ribbon Teflon piston: piston and fenestra size affect air-bone gap. *Otol Neurotol.* 2008;29(1):8-12. DOI: 10.1097/mao.0b013e31815c2575
77. Heimke G, Griss P. Ceramic implant materials. *Med Biol Eng Comput.* 1980;18(4):503-10. DOI: 10.1007/BF02443328
78. Jahnke K, Plester D. Aluminium oxide ceramic implants in middle ear surgery. *Clin Otolaryngol Allied Sci.* 1981;6(3):193-5. DOI: 10.1111/j.1365-2273.1981.tb01531.x
79. Jahnke K, Plester D, Heimke G. Aluminiumoxid-Keramik, ein bioniertes Material für die Mittelohrchirurgie. *Eur Arch Otorhinolaryngol.* 1979;223:373-6. DOI: 10.1007/BF01109587
80. Yamamoto E. Aluminum oxide ceramic ossicular replacement prosthesis. *Ann Otol Rhinol Laryngol.* 1985;94(2 Pt 1):149-52.
81. Jahnke K, Plester D, Heimke G. Experiences with Al2O3-ceramic middle ear implants. *Biomaterials.* 1983;4(2):137-8. DOI: 10.1016/0142-9612(83)90056-X
82. Shea JJ, Moretz WH. Peg-tip fixation of Plasti-Pore TORP. *Otolaryngol Head Neck Surg.* 1985;93(2):279-80.
83. Wullstein H. Operationsmethoden zur Hörverbesserung und Prophylaxe bei Otosklerose und Adhäsivprozess und ihre vorläufigen Ergebnisse. *Arch Ohren Nasen Kehlkopfheilkd.* 1949;(166):252-69.



84. Wullstein H. Funktionelle Operationen im Mittelohr mit Hilfe des freien Spalthaut-Transplantates. *Arch Ohren Nasen Kehlkopfheilkd.* 1952;(161):422-35. DOI: 10.1007/BF02129204
85. House HP. Polyethylene in middle ear surgery. *AMA Arch Otolaryngol.* 1960;71:926-31.
86. Shea J. Plastipore total ossicular replacement prosthesis. *Laryngoscope.* 1976;86(2):239-40. DOI: 10.1288/00005537-197602000-00015
87. Gjuric M, Mladina R, Koscak J. Die Plastipore-Prothese im Tierexperiment. *Laryngo-Rhino-Otol.* 1987;66(10):522-5. DOI: 10.1055/s-2007-998723
88. Teichgraber JF, Spector M, Per-Lee JH, Jackson RT. Tissue response to Plasti-Pore and Proplast otologic implants in the middle ears of cats. *Am J Otol.* 1983;5(2):127-36.
89. Galic M, Jahnke K. Über die Reaktion der menschlichen Mittelohrschleimhaut nach Implantation von Kunststoffen. *Laryngo-Rhino-Otol.* 1982;61(1):30-4. DOI: 10.1055/s-2007-1008514
90. Smyth GD. Five-year report on partial ossicular replacement prostheses and total ossicular replacement prostheses. *Otolaryngol Head Neck Surg.* 1982;90(3 Pt 1):343-6.
91. Kelly GL, Eiseman B. Development of a new vascular prosthetic: lessons learned. *Arch Surg.* 1982;117(10):1367-70.
92. Shea JJ. Thirty years of stapes surgery. *J Laryngol Otol.* 1988;102(1):14-9. DOI: 10.1017/S0022215100103846
93. Slattery WH, III, House JW. Prostheses for stapes surgery. *Otolaryngol Clin North Am.* 1995;28(2):253-64.
94. Shea JJ Jr. A personal history of stapedectomy. *Am J Otol.* 1998;19(5 Suppl):S2-12.
95. Himi T, Igarashi M, Kataura A. Temporal bone histopathology over 15 years post-stapedectomy. *Acta Otolaryngol Suppl.* 1988;447:126-34.
96. Shea JJ, Homsy CA. The use of Proplast TM in otologic surgery. *Laryngoscope.* 1974;84(10):1835-45. DOI: 10.1288/00005537-197410000-00014
97. Kerr AG. Proplast and Plastipore. *Clin Otolaryngol Allied Sci.* 1981;6(3):187-91. DOI: 10.1111/j.1365-2273.1981.tb01530.x
98. Blayney AW, Romero Rio JA, Williams KR, Guilhaume A, Bagot DM, Portmann M. Experimental and clinical aspects of carbon as a middle ear prosthesis. *Clin Otolaryngol Allied Sci.* 1986;11(3):189-97.
99. Krummel FJ, Reck R, Meyer A. Verträglichkeit von Glaskohlenstoffimplantaten im Mittelohr - tierexperimentelle Ergebnisse. *Laryngo-Rhino-Otol.* 1987;66(8):409-11. DOI: 10.1055/s-2007-998691
100. Vincent R, Gratacap B, Vandeventer G. Ossiculoplasty with J.B. Causse composite prostheses: our experience with 500 cases. *Rev Laryngol Otol Rhinol (Bord).* 1995;116(1):13-7.
101. Dornhoffer JL. Hearing results with the Dornhoffer ossicular replacement prostheses. *Laryngoscope.* 1998;108(4 Pt 1):531-6. DOI: 10.1097/00005537-199804000-00013
102. Neugebauer P. Tympanoplastik mit Hybridprothesen. *Laryngo-Rhino-Otol.* 2004;83(4):226-31. DOI: 10.1055/s-2004-814245
103. Meijer AG, Segenhout HM, Albers FW, van de Want HJ. Histopathology of biocompatible hydroxylapatite-polyethylene composite in ossiculoplasty. *ORL J Otorhinolaryngol Relat Spec.* 2002;64(3):173-9. DOI: 10.1159/000058021
104. Merwin GE, Atkins JS, Wilson J, Hench LL. Comparison of ossicular replacement materials in a mouse ear model. *Otolaryngol Head Neck Surg.* 1982;90(4):461-9.
105. Jahnke K, Schmidt C. Histological studies on the suitability of Macor-ceramic middle ear implants. In: Grote JJ, ed. *Biomaterials in Otolaryngology.* Boston: Martinus Nijhoff Publishers; 1984. p. 74-79.
106. Reck R. Erste tierexperimentelle und klinische Erfahrungen mit bioaktiver Glaskeramik in der rekonstruktiven Mittelohrchirurgie. *Eur Arch Otorhinolaryngol.* 1979;(223):369-71.
107. Reck R, Storkel S, Meyer A. Bioactive glassceramics in middle ear surgery. An 8-year review. *Ann N Y Acad Sci.* 1988;523:100-6. DOI: 10.1111/j.1749-6632.1988.tb38504.x
108. Beleites E, Neupert G, Augsten G, Vogel W, Schubert H. Rasterelektronenmikroskopische Untersuchungen des Zellwachstums auf maschinell bearbeitbarer Biovitrokeramik und Glaskohlenstoff in vitro und in vivo. *Laryngo-Rhino-Otol.* 1985;64(4):217-20. DOI: 10.1055/s-2007-1008123
109. Koscielny S, Beleites E. Untersuchungen zum Einfluss von Biokeramiken auf biologische Leistungen von Mikroorganismen. *HNO.* 2001;49(5):367-71.
110. Grote JJ, van Blitterswijk CA, Kuijpers W. Hydroxyapatite ceramic as middle ear implant material: animal experimental results. *Ann Otol Rhinol Laryngol Suppl.* 1986;123:1-5.
111. van Blitterswijk CA, Grote JJ, Kuypers W, Blok-van Hoek CJ, Daems WT. Bioreactions at the tissue/hydroxyapatite interface. *Biomaterials.* 1985;6(4):243-51. DOI: 10.1016/0142-9612(85)90020-1
112. Grote JJ. Reconstruction of the middle ear with hydroxylapatite implants: long-term results. *Ann Otol Rhinol Laryngol Suppl.* 1990;144:12-6.
113. Wehrs RE. Hearing results with incus and incus stapes prostheses of hydroxylapatite. *Laryngoscope.* 1991;101(5):555-6. DOI: 10.1288/00005537-199105000-00018
114. Geyer G. Ionomerzement als Knochenersatzmaterial im Mittelohr des Kaninchens. *HNO.* 1997;45(4):222-6.
115. Geyer G, Helms J. Ionomerzementprothesen in der rekonstruktiven Mittelohrchirurgie. *HNO.* 1997;45(6):442-7.
116. Maassen MM, Zenner HP. Tympanoplasty type II with ionomeric cement and titaniumgold-angle prostheses. *Am J Otol.* 1998;19(6):693-9.
117. Hantson P, Mahieu P, Gersdorff M, Sindic CJ, Lauwerys R. Encephalopathy with seizures after use of aluminium-containing bone cement. *Lancet.* 1994;344(8937):1647. DOI: 10.1016/S0140-6736(94)90446-4
118. Goldenberg RA, Emmet JR. Current use of implants in middle ear surgery. *Otol Neurotol.* 2001;22(2):145-52. DOI: 10.1097/00129492-200103000-00005
119. Preuss SF, Luers JC, Beutner D, Klusmann JP, Huttenbrink KB. Results of a European survey on current controversies in otology. *Otol Neurotol.* 2007;28(6):774-7. DOI: 10.1097/MAO.0b013e31805c74f1
120. Truy E, Naiman AN, Pavillon C, Abedipour D, Lina-Granade G, Rabilloud M. Hydroxyapatite versus titanium ossiculoplasty. *Otol Neurotol.* 2007;28(4):492-8. DOI: 10.1097/01.mao.0000265203.92743.d1
121. Tos M. Pathology of the ossicular chain in various chronic middle ear diseases. *J Laryngol Otol.* 1979;93(8):769-80. DOI: 10.1017/S0022215100087703
122. Mills RP. Physiological reconstruction of defects of the incus long process. *Clin Otolaryngol Allied Sci.* 1996;21(6):499-503. DOI: 10.1111/j.1365-2273.1996.tb01099.x
123. Babighian G. Use of a glass ionomer cement in otological surgery. A preliminary report. *J Laryngol Otol.* 1992;106(11):954-9. DOI: 10.1017/S0022215100121450



124. Bance M, Morris DP, Vanwijhe RG, Kieft M, Funnell WR. Comparison of the mechanical performance of ossiculoplasty using a prosthetic malleus-to-stapes head with a tympanic membrane-to-stapes head assembly in a human cadaveric middle ear model. *Otol Neurotol*. 2004;25(6):903-9. DOI: 10.1097/00129492-200411000-00008
125. Koike T, Wada H, Kobayashi T. Modeling of the human middle ear using the finite element method. *J Acoust Soc Am*. 2002;111(3):1306-17. DOI: 10.1121/1.1451073
126. Yung M. Titanium prosthesis with malleus notch: a study of its "user-friendliness". *J Laryngol Otol*. 2007;121(10):938-42. DOI: 10.1017/S0022215107005944
127. Fisch U, May J, Linder T, Naumann IC. A new L-shaped titanium prosthesis for total reconstruction of the ossicular chain. *Otol Neurotol*. 2004;25(6):891-902. DOI: 10.1097/00129492-200411000-00007
128. Morris DP, Bance M, Van Wijhe RG. How do cartilage and other material overlay over a prosthesis affect its vibration transmission properties in ossiculoplasty? *Otolaryngol Head Neck Surg*. 2004;131(4):423-8. DOI: 10.1016/j.otohns.2004.02.055
129. Beutner D, Mickenhagen A, Hüttenbrink KB. Experimentelle Untersuchungen eines modifizierten Prothesentellers für Mittelohrtitanprothesen. In: 77. Jahresversammlung der Deutschen Gesellschaft für Hals-Nasen-Ohren-Heilkunde, Kopf- und Hals-Chirurgie e.V. Mannheim, 24.-28.05.2006. Düsseldorf: German Medical Science GMS Publishing House; 2006. Doc06hnod240. Available from: <http://www.egms.de/de/meetings/hnod2006/06hnod240.shtml>
130. Eiber A, Freitag HG, Schimanski G, Zenner HP. On the coupling of prostheses to the middle ear structure and its influence on sound transfer. In: Second international Symposium on Middle Ear Mechanics in Research and Otolaryngology. Boston, 1999. p. 297-308.
131. Katzke D, Pusalkar A, Steinbach E. The effects of fibrin tissue adhesive on the middle ear. *J Laryngol Otol*. 1983;97(2):141-7. DOI: 10.1017/S0022215100093919
132. Smyth GD. TORPs - how have they fared after five years? *J Laryngol Otol*. 1983;97(11):991-3. DOI: 10.1017/S0022215100095876
133. Beutner D, Stumpf R, Preuss SF, Zahnert T, Hüttenbrink KB. Zur Gefahr einer Fraktur der Fußplatte durch unterschiedlich große TORP-Prothesenfüße. *Laryngo-Rhino-Otol*. 2007;86(2):112-6. DOI: 10.1055/s-2006-945031
134. Beutner D, Luers JC, Huttenbrink KB. Cartilage "shoe": a new technique for stabilisation of titanium total ossicular replacement prosthesis at centre of stapes footplate. *J Laryngol Otol*. 2008;118(5):411-5. DOI: 10.1017/S0022215108002545
135. Hüttenbrink KB, Zahnert T, Beutner D, Hofmann G. Der Knorpelschuh zur Stabilisierung einer Columella-Prothese auf der Fußplatte. *Laryngo-Rhino-Otol*. 2004;83(7):450-6. DOI: 10.1055/s-2004-814447
136. Neudert M, Berner M, Bornitz M, Beleites T, Ney M, Zahnert T. Osseointegration of prostheses on the stapes footplate: evaluation of the biomechanical feasibility by using a finite element model. *J Assoc Res Otolaryngol*. 2007;8(4):411-21. DOI: 10.1007/s10162-007-0094-7
137. Huttenbrink KB. The mechanics of the middle-ear at static air pressures: the role of the ossicular joints, the function of the middle-ear muscles and the behaviour of stapled prostheses. *Acta Otolaryngol Suppl*. 1988;451:1-35.
138. Beleites T, Bornitz M, Offergeld C, Neudert M, Hüttenbrink KB, Zahnert T. Experimentelle Untersuchungen zu Mittelohrimplantaten mit integriertem mikromechanischem Gelenk. *Laryngo-Rhino-Otol*. 2007;86(9):649-54. DOI: 10.1055/s-2007-966514
139. Kiessling J. Neue Aspekte zur Hörgeräteversorgung bei Lärmschwerhörigkeit. *HNO*. 2006;54(7):573-82. DOI: 10.1007/s00106-006-1423-6
140. Leuwer R. Gestörtes Hören. Die apparative Versorgung der Schwerhörigkeit: Konventionelle und implantierbare Geräte. *Laryngo-Rhino-Otol*. 2005;84(Suppl 1):S51-9. DOI: 10.1055/s-2005-861131
141. Kiefer J, Pok M, Adunka O, Sturzebecher E, Baumgartner W, Schmidt M et al. Combined electric and acoustic stimulation of the auditory system: results of a clinical study. *Audiol Neurootol*. 2005;10(3):134-44. DOI: 10.1159/000084023
142. Huttenbrink KB, Zahnert TH, Bornitz M, Hofmann G. Biomechanical aspects in implantable microphones and hearing aids and development of a concept with a hydroacoustical transmission. *Acta Otolaryngol*. 2001;121(2):185-89.
143. Zenner HP. Implantierbare Hörgeräte - aktueller Stand. In: Jahnke K, ed. *Middle Ear Surgery*. Stuttgart: Thieme; 2000. p. 141-161.
144. Magnan J, Manrique M, Dillier N, Snik A, Hausler R. International consensus on middle ear implants. *Acta Otolaryngol*. 2005;125(9):920-1.
145. Huttenbrink KB. Current status and critical reflections on implantable hearing aids. *Am J Otol*. 1999;20(4):409-15.
146. Stieger C, Wackerlin D, Bernhard H, Stahel A, Kompis M, Hausler R et al. Computer assisted optimization of an electromagnetic transducer design for implantable hearing aids. *Comput Biol Med*. 2004;34(2):141-52. DOI: 10.1016/S0010-4825(03)00042-8
147. Javel E, Grant IL, Kroll K. In vivo characterization of piezoelectric transducers for implantable hearing AIDs. *Otol Neurotol*. 2003;24(5):784-95. DOI: 10.1097/00129492-200309000-00016
148. Zenner HP, Leysieffer H, Maassen M, Lehner R, Lenarz T, Baumann J et al. Human studies of a piezoelectric transducer and a microphone for a totally implantable electronic hearing device. *Am J Otol*. 2000;21(2):196-204.
149. Wilska A. Eine Methode zur Bestimmung der Hörschwellenamplituden des Trommelfells bei verschiedenen Frequenzen. *Scand Arch Physiol*. 1935;7(2):161-5.
150. Suzuki J, Kodera K, Yanagihara N. Middle ear implant for humans. *Acta Otolaryngol*. 1985;99(3-4):313-7.
151. Yanagihara N, Aritomo H, Yamanaka E, Gyo K. Implantable hearing aid. Report of the first human applications. *Arch Otolaryngol Head Neck Surg*. 1987;113(8):869-72.
152. Yanagihara N, Sato H, Hinohira Y, Gyo K, Hori K. Long-term results using a piezoelectric semi-implantable middle ear hearing device: the Rion Device E-type. *Otolaryngol Clin North Am*. 2001;34(2):389-400. DOI: 10.1016/S0030-6665(05)70338-8
153. Zenner HP, Leysieffer H. Totally implantable hearing device for sensorineural hearing loss. *Lancet*. 1998;352(9142):1751. DOI: 10.1016/S0140-6736(98)00076-2
154. Zenner HP, Leysieffer H. Total implantation of the Implex TICA hearing amplifier implant for high frequency sensorineural hearing loss: the Tübingen University experience. *Otolaryngol Clin North Am*. 2001;34(2):417-46. DOI: 10.1016/S0030-6665(05)70340-6
155. Hough JV, Dyer RK Jr, Matthews P, Wood MW. Early clinical results: SOUNDTEC implantable hearing device phase II study. *Laryngoscope*. 2001;111(1):1-8. DOI: 10.1097/00005537-200101000-00001
156. Backous DD, Duke W. Implantable middle ear hearing devices: current state of technology and market challenges. *Curr Opin Otolaryngol Head Neck Surg*. 2006;14(5):314-8. DOI: 10.1097/01.moo.0000244187.66807.30

157. Truy E, Eshraghi AA, Balkany TJ, Telishi FF, Van De Water TR, Lavielle JP. Vibrant soundbridge surgery: evaluation of transcanal surgical approaches. *Otol Neurotol*. 2006;27(6):887-95. DOI: 10.1097/01.mao.0000227905.32236.9f
158. Uziel A, Mondain M, Hagen P, Dejean F, Doucet G. Rehabilitation for high-frequency sensorineural hearing impairment in adults with the symphonix vibrant soundbridge: a comparative study. *Otol Neurotol*. 2003;24(5):775-83. DOI: 10.1097/00129492-200309000-00015
159. Böhme K, Nahler A, Schlogel M. Rehabilitation der Hochtoninnenohrschwerhörigkeit. *HNO*. 2007;55(9):690-5. DOI: 10.1007/s00106-006-1506-4
160. Sterkers O, Boucarra D, Labassi S, Bebear JP, Dubreuil C, Frachet B et al. A middle ear implant, the Symphonix Vibrant Soundbridge: retrospective study of the first 125 patients implanted in France. *Otol Neurotol*. 2003;24(3):427-36. DOI: 10.1097/00129492-200305000-00013
161. Fraysse B, Lavielle JP, Schmerber S, Enee V, Truy E, Vincent C et al. A multicenter study of the Vibrant Soundbridge middle ear implant: early clinical results and experience. *Otol Neurotol*. 2001;22(6):952-61. DOI: 10.1097/00129492-200111000-00041
162. Snik AF, Cremers CW. Vibrant semi-implantable hearing device with digital sound processing: effective gain and speech perception. *Arch Otolaryngol Head Neck Surg*. 2001;127(12):1433-7.
163. Luetje CM, Brackman D, Balkany TJ, Maw J, Baker RS, Kelsall D et al. Phase III clinical trial results with the Vibrant Sound-bridge implantable middle ear hearing device: a prospective controlled multicenter study. *Otolaryngol Head Neck Surg*. 2002;126(2):97-107. DOI: 10.1067/mhn.2002.122182
164. Mosnier I, Sterkers O, Boucarra D, Labassi S, Bebear JP, Bordure P et al. Benefit of the Vibrant Soundbridge device in patients implanted for 5 to 8 years. *Ear Hear*. 2008;29(2):281-4. DOI: 10.1097/AUD.0b013e3181645366
165. Todt I, Seidl RO, Gross M, Ernst A. Comparison of different vibrant soundbridge audioprocessors with conventional hearing aids. *Otol Neurotol*. 2002;23(5):669-73. DOI: 10.1097/00129492-200209000-00012
166. Truy E, Benedicte P, Vesson JF, Labassi S, Collet L. Vibrant Soundbridge Versus Conventional Hearing Aid in Sensorineural High-Frequency Hearing Loss: A Prospective Study. *Otol Neurotol*. 2008;29(5):684-7. DOI: 10.1097/MAO.0b013e31817156df
167. Verhaegen VJ, Mylanus EA, Cremers CW, Snik AF. Audiological Application Criteria for Implantable Hearing Aid Devices: A Clinical Experience at the Nijmegen ORL Clinic. *Laryngoscope*. 2008;118(9):1645-9. DOI: 10.1097/MLG.0b013e31817b013a
168. Schmuziger N, Schimmann F, àWengen D, Patscheke J, Probst R. Long-term assessment after implantation of the Vibrant Soundbridge device. *Otol Neurotol*. 2006;27(2):183-8. DOI: 10.1097/01.mao.0000199754.51815.70
169. Fisch U, Cremers CW, Lenarz T, Weber B, Babighian G, Uziel AS et al. Clinical experience with the Vibrant Soundbridge implant device. *Otol Neurotol*. 2001;22(6):962-72. DOI: 10.1097/00129492-200111000-00042
170. Colletti V, Soli SD, Carner M, Colletti L. Treatment of mixed hearing losses via implantation of a vibratory transducer on the round window. *Int J Audiol*. 2006;45(10):600-8. DOI: 10.1080/14992020600840903
171. Kiefer J, Arnold W, Staudenmaier R. Round window stimulation with an implantable hearing aid (Soundbridge) combined with autogenous reconstruction of the auricle - a new approach. *ORL J Otorhinolaryngol Relat Spec*. 2006;68(6):378-85. DOI: 10.1159/000095282
172. Wollenberg B, Beltrame M, Schonweiler R, Gehrking E, Nitsch S, Steffen A et al. Integration des aktiven Mittelohrimplantates in die plastische Ohrmuschelrekonstruktion. *HNO*. 2007;55(5):349-56. DOI: 10.1007/s00106-007-1540-x
173. Roland PS, Wright CG, Isaacson B. Cochlear implant electrode insertion: the round window revisited. *Laryngoscope*. 2007;117(8):1397-402. DOI: 10.1097/MLG.0b013e318064e891
174. Soli S. Comparison of output levels and gains for bone conduction and round window stimulation of the cochlea in patients with conductive hearing loss. In: *Proceedings of the 5th International Symposium on Human Sensibility Recovery Systems*. Kyungpook National University Daegu, Korea, 2007.
175. Huber AM, Ball GR, Veraguth D, Dillier N, Bodmer D, Sequeira D. A new implantable middle ear hearing device for mixed hearing loss: A feasibility study in human temporal bones. *Otol Neurotol*. 2006;27(8):1104-9. DOI: 10.1097/01.mao.0000244352.49824.e6
176. Hüttenbrink KB, Zahnert T, Bornitz M, Beutner D. TORP-Vibroplasty: A new alternative for the chronically disabled middle ear. *Otol Neurotol*. 2008;29(7):965-71. DOI: 10.1097/MAO.0b013e318185fad8
177. Dumon T. Vibrant soundbridge middle ear implant in otosclerosis: technique - indication. *Adv Otorhinolaryngol*. 2007;65:320-2. DOI: 10.1159/000098852
178. Venail F, Lavielle JP, Meller R, Deveze A, Tardivet L, Magnan J. New perspectives for middle ear implants: first results in otosclerosis with mixed hearing loss. *Laryngoscope*. 2007;117(3):552-5. DOI: 10.1097/MLG.0b013e31802dfc59
179. Kasic JF, Fredrickson JM. The Otologics MET ossicular stimulator. *Otolaryngol Clin North Am*. 2001;34(2):501-13. DOI: 10.1016/S0030-6665(05)70345-5
180. Jenkins HA, Atkins JS, Horlbeck D, Hoffer ME, Balough B, Arigo JV et al. U.S. Phase I preliminary results of use of the Otologics MET Fully-Implantable Ossicular Stimulator. *Otolaryngol Head Neck Surg*. 2007;137(2):206-12. DOI: 10.1016/j.otohns.2007.03.012
181. Fredrickson JM, Cotichia JM, Khosla S. Ongoing investigations into an implantable electromagnetic hearing aid for moderate to severe sensorineural hearing loss. *Otolaryngol Clin North Am*. 1995;28(1):107-20.
182. Jenkins HA, Niparko JK, Slattery WH, Neely JG, Fredrickson JM. Otologics Middle Ear Transducer Ossicular Stimulator: performance results with varying degrees of sensorineural hearing loss. *Acta Otolaryngol*. 2004; 124(4):391-4.
183. Siegert R, Mattheis S, Kasic J. Fully implantable hearing aids in patients with congenital auricular atresia. *Laryngoscope*. 2007;117(2):336-40. DOI: 10.1097/MLG.0b013e31802b6561
184. Chen DA, Backous DD, Arriaga MA, Garvin R, Kobylek D, Littman T et al. Phase 1 clinical trial results of the Envoy System: a totally implantable middle ear device for sensorineural hearing loss. *Otolaryngol Head Neck Surg*. 2004;131(6):904-16. DOI: 10.1016/j.otohns.2004.05.027

**Corresponding author:**

Dr. med. Dirk Beutner

Universitäts-HNO-Klinik, Kerpener Str. 62, 50937 Köln, Germany, phone: +49(0)221/4784750

dirk.beutner@uni-koeln.de

**Please cite as**

Beutner D, Hüttenbrink KB. Passive and active middle ear implants. *GMS Curr Top Otorhinolaryngol Head Neck Surg.* 2009;8:Doc09.  
DOI: 10.3205/cto000061, URN: urn:nbn:de:0183-cto0000619

**This article is freely available from**

<http://www.egms.de/en/journals/cto/2011-8/cto000061.shtml>

**Published:** 2011-03-10

**Copyright**

©2011 Beutner et al. This is an Open Access article distributed under the terms of the Creative Commons Attribution License (<http://creativecommons.org/licenses/by-nc-nd/3.0/deed.en>). You are free: to Share — to copy, distribute and transmit the work, provided the original author and source are credited.