

# Nasal packing and stenting

## Abstract

Nasal packs are indispensable in ENT practice. This study reviews current indications, effectiveness and risks of nasal packs and stents. In endoscopic surgery, nasal packs should always have smooth surfaces to minimize mucosal damage, improve wound healing and increase patient comfort. Functional endoscopic endonasal sinus surgery allows the use of modern nasal packs, since pressure is no longer required. So called hemostatic/resorbable materials are a first step in this direction. However, they may lead to adhesions and foreign body reactions in mucosal membranes. Simple occlusion is an effective method for creating a moist milieu for improved wound healing and avoiding dryness. Stenting of the frontal sinus is recommended if surgery fails to produce a wide, physiologically shaped drainage path that is sufficiently covered by intact tissue.

**Keywords:** nasal packing, stenting, wound healing, FESS, occlusive wound care, septoplasty, turbinate surgery, nasal tamponade

**Rainer K. Weber<sup>1</sup>**

<sup>1</sup> Sektion Nasennebenhöhlen- und Schädelbasischirurgie, Traumatologie, HNO-Klinik, Städtisches Klinikum Karlsruhe, Germany

## 1 Introduction

Nasal packs are indispensable for the ENT practitioner. There is an increasing number of products on the market utilizing different materials. This study is designed to give an overview and represents a revision of the prior publications by Weber et al. [1] and Beule et al. [2] from the years 2000 and 2004 respectively. Current literature from 2000 to 2008 has been surveyed to provide a review of indications, effectiveness and risks of nasal packs and stents. Nasal packs are designed to

- Provide hemostasis after Epistaxis or surgery
- Provide support for the cartilaginous and bony nasal structure, nasal conchae or soft tissue (i.e. sliding flaps)
- Prevent adhesions or stenosis, especially following sinus surgery. In this case packs should remain placed for a longer period of time [3], specially formed struts [3], [4], [5] and certain materials [6] are especially advantageous.

There is no generally recognized standard for which types of materials should be used, how long packs should remain placed, or when placement is indicated [1], [2].

Nasal packs

- Apply pressure
- Fill preformed spaces
- Create moist environments to facilitate physiological processes (i.e. by occlusion)
- Function as a barrier
- Induce physiological hemostatic and reparative processes.

Use of nasal packs varies greatly in different countries. In Germany, for example formed nasal packs (Formkörper tamponaden = FKT) are usually rubber

covered sponge packs. In the USA merocel PVA-packs are popular, in England PVA and Telfa packs are used and in China alginate strips are often used. This diversity is most likely the result of local market factors and availability as much as actual differences in the effectiveness of the materials themselves. Large comparative studies are lacking.

In general, however, there is a trend to refrain from applying nasal packs whenever possible to increase patient comfort.

The diversity of materials is great and the following overview can not be exhaustive, but should still prove helpful in giving some general orientation. The following nasal packs are considered to be relevant nationally and internationally by the author.

## 2 Materials for nasal packs

There are two main classes of nasal packs, formed nasal packs (Chpt 2.1), and the new generation of hemostatic/resorbable/biodegradable packs (HT) (Chpt 2.2).

### 2.1.1 Rubber coated sponge packs (Gummifingerlingtamponaden = GFT)

GFT are sponges with latex coverings that are impenetrable for bacteria and viruses. Differences in manufacturing affect the quality of the latex, the firmness and texture of thread anchors. If threads are too smooth, the knot may slip and increase pressure on the columella or alar cartilage. For safety reasons, "home-made" GFT's should not be used. Latex-free GTS's use an inert synthetic cover (RhinoTamp, latex free, Vostra, Aachen) or immerse the sponge in polyurethane (Schaumstoffnasentamponade mit latexfreier Behautung, Spiggle & Theis, Overath).

GFT's are effective and show a favorable risk-benefit ratio and are therefore standard in Germany. They are easy to place and remove, cause little trauma, bleeding and discomfort. The pressure applied to the mucosal membranes can be modified and is usually light to medium.

Two complications warrant further attention:

- Pressure can damage the nasal vestibulum (columella and alar cartilage, see Chpt 3.2)
- Posterior dislocation can lead to aspiration (see Chpt 3.3).

### 2.1.2 Expandable nasal packs (Expandierbare Nasentamponaden = ENT)

ENT are made of Polyvinyl acetal (PVA) derived from viscose and cellulose (Sugomed).

#### 2.1.2.1 PVA nasal packs (= PVA-NT)

PVA-NT are compressed and offered in various forms and sizes. After contact with blood or water, the adhesive dissolves and the pack expands. The packs can absorb up to 20 times their weight in fluid. This makes the packs soft and elastic, allowing them to apply light to moderate pressure in the nasal cavity. Movement of the packs is determined by the smoothness of the surface and size of packs. The smaller the pores, the less likely it is for granulation tissue to grow into the packs and the smoother the surface. This means that bleeding and trauma is reduced during placement or removal and patient comfort is increased. Smaller pores increase the density of the packs and the maximal tensile strength. This also leads to slower absorption of liquids and a decrease in the total amount of liquid that can be absorbed. The classic PVA-NT is Merocel. However, this product (and imitations) has large pores and should therefore not be used.

Recommended PVA-NT

- have small pores, increasing comfort during removal (3.08 versus 5 on a VAS 0–10, series 5000) [7].
- are coated (i.e. Merocel Laminated) and have composite films on the sides, to further minimize tissue trauma. However, large pores and rough surfaces remain on the front and back ends, as well as on top and on the bottom of the packs.
- are antibacterial (presumed to be effective against *E. coli*, *Staphylococcus*, *Yersinia*, *Serratia* and *Bacillus subtilis*)
- The best presently available PVA-NT is Netcell (Vostra GmbH, Aachen) which has the pack wrapped completely in a synthetic film, which avoids all PVA contact with tissue (Figure 1). A recent study has confirmed the usefulness of the complete wrap [8]. In the author's opinion, this product, along with the GFT, are the least traumatic FKT's. Although a confirming study is lacking, comfort during removal of the Netcell pack is similar to the removal of a GFT.

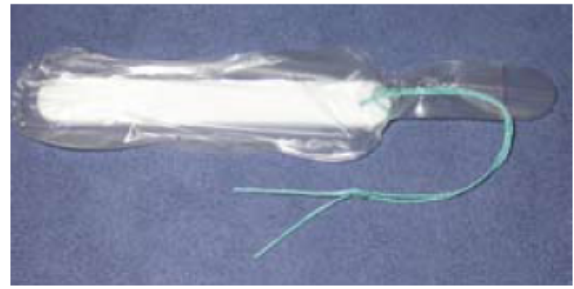


Figure 1: Netcell nasal packing

Newer products utilizing Merocel and micro flocculated cellulose (Merocel hemo X, Medtronic) have not been tested yet.

#### 2.1.2.2 Sugomed

Sugomed is an expandable material available in strips or plates. It consists of cellulose (31.3%) and viscose (68.7%) and, expands upon fluid absorption, although less than PVA-NT. The pores are smaller than classic Merocel, so pack removal is more comfortable than Merocel, but still leads to more trauma than smooth surface packs. The main advantage over Merocel, is the individualized sizing and shaping of the plates or strips. One long strip can be placed in both nasal cavities. However, care should be taken to avoid pressure to the columella.

#### 2.1.3 Rapid Rhino (see 2.2.5)

Rapid Rhino is a nasal pack with a sponge core (models include Riemann, Goodman or Mannheim in different lengths) or a balloon covered by carboxymethylcellulose (CMC). CMC covers both effective agents, the balloon catheter and the sponge core, which apply pressure and fill space in the nasal cavity, making the pack an FKT by definition. Even if CMC induces aggregation of thrombocytes and thus hemostasis, this effect most likely contributes little to the overall effect. Upon contact with water (not saline) a gel is produced that makes the surface very smooth and supports healing of the nasal membranes. This may be important for the sponge core pack, but most likely contributes little to the overall effect of the balloon catheter pack. Nylon threads are stitched into the packs may get caught in the nasal cavity and impair removal. Gel formation, which helps produce occlusive wound healing and supports physiological hemostasis can be achieved using pure CMC in the Sinu-Kit or Stammberger gel (see 2.2.5).

As expected, Rapid Rhino showed better performance than PVA-NT in terms of patient comfort (pain during placement and removal, epistaxis) [9], [10]. Effectivity for use on patients with epistaxis or after sinus surgery was judged to be favorable [9], [10], [11], [12]. The author feels that the sponge core model is comparable to GFT (Rhinotamp Latexrei, Vostra, Aachen) but easier to compress, which makes placement easier and reduces the risk of pressure necrosis. The risk of dislocation is lower

than GFT, the price is considerably higher. The balloon catheter model was not judged favorably (see 2.1.5).

#### 2.1.4 Cotton gauze strips (Baumwollgazestreifen = BWGS)

BWGS differ in width of strips, size of knitting structure and the threads attached. They can be used alone or saturated in medicine. Usually vaseline or antibiotic ointments are used. Ointments help make the strips glide into the nose and prevent crusting. Antibiotics are thought to prevent infections, but this has not yet been demonstrated. Because of the low effectivity, BWGS should not be used after operations on the nasal septum, the conchae or sinuses. The author considers the use of BWGS's for epistaxis or repositioning of nasal fractures possible. However, even in these cases, better alternatives seem available. Although often practiced, BWGS's should not be used after sinus surgery. This is recommended for medicolegal reasons. BWGS's can cause pressure necrosis, epistaxis upon removal, paraffine granulomas, discomfort during placement and removal, discouraging their use.

#### 2.1.5 Balloon packs/balloon catheter (Ballonkatheter = BK)

Perhaps the only indication is serious posterior epistaxis, which can be controlled quickly and effectively using BK's. BK's do not apply pressure directly to branches of the sphenopalatine artery, but can seal off the nasopharynx. If occlusion is achieved in the anterior nasal cavity, pressure may be built up indirectly and lead to compression of bleeding vessels. Simple BK's have one balloon (nasopharynx). Some BK's are equipped with two balloons (nasal cavity and nasopharynx). The author has the following reservations against the use of catheters with two balloons:

- The high pressure built up in the anterior balloon does not lead to direct compression of bleeding vessels and is applied directly to the nasal septum and turbinates and can lead to necrosis. The nasal septum is dislodged to the other side [13]. If the anterior balloon does lead to direct compression of a bleeding vessel, then the author assumes the bleeding can be managed by cautery or less invasive packs.
- The nasal end of the pack can cause damage to the nasal vestibulum, especially if the catheter is not of sufficient length. Therefore longer packs should always be used.

Thus double-balloon catheters of sufficient length can be used, however, only the posterior balloon should be filled. The anterior balloon should be left empty and an additional NT applied.

Arthrocare also provides a new variant with Rapid Rhino 120. The two balloon chambers are connected to each other and are filled together. The author sees no benefit, however, since the balloon still applies pressure in the

nasal cavity. The CMC cover can not hide the fact that a BK is being used and is the effective agent. The author also does not recommend using Rapid Rhino of 5 cm or 7 cm length with balloon, since they also apply high pressure to the nasal cavity and less invasive products are available. In the author's experience heavy bleeding from the sphenopalatine artery is not controlled well with BK's and should be clipped or cauterized endoscopically. The following should be considered:

- Sinsus surgery as such is usually not required, but may be necessary to identify the posterior wall of the maxillary sinus
- Multiple branches may be present [14]
- According to Simmen (personal communication), the branch leading to the anterior wall of the sphenoid sinus is most often affected.

Although commercially available BK's are more sophisticated, simple Foley catheters are more cost efficient. A problem common to all BK's is the difficulty of securing the catheters. A number of recommendations have been made to limit necrosis of the nasal ala:

- Anterior nasal pack with sturdy knot [15]
- Foam coating [16]
- The distal end is cut off and placed 8 cm beyond the proximal end of the dilated balloon and secured with a clamp [17]

Foley catheters should be filled with water, not air, since both latex and silicone catheters leak the air within 24 hours. Latex catheters can leak saline as well [18]. Paraffin can damage the rubber, so paraffin ointments should not be used with Foley catheters [19].

#### 2.1.6 Alginate

Alginate (i.e. Sorbalgon) is made from sea algae. It is a polysaccharide similar to cellulose and produces a gel upon contact with water. In wounds, alginate absorbs high sodium exudate and discharges calcium ions to produce soluble sodium-alginate. This produces a moist gel film on the wound surface. The calcium ions stimulate physiological clotting. The gel that is produced is hydrophile, binds fluid, encases bacteria and cell debris and thus supports wound cleansing. Alginate can bind up to 20 times its weight in fluid. The moist micro-climate also supports granulation and epithelial regeneration.

In 1989 and 1992 Sirimanna first compared GFT's and gauze packs with alginate after surgery of the conchae and found alginate to be less traumatic [1]. In a current randomized clinical study of 50 patients, alginate was compared to Merocel after conchotomy. Following removal (after 2 days), alginate showed less bleeding and was found to be less painful (2.53 versus 5.6 on a VAS of 0-10) [20]. In China alginate is widely used and is judged favorably. A number of reports support this observation, including a number of studies published in Chinese. Alginate is applied as a braided strip, left for a one day and stops epistaxis reliably. In personal communication to

the author in China, it has been pointed out that Chinese are very sensitive about bloody secretions following nasal surgery. If the pack is left in place longer, removal becomes difficult because of the gel production and fragmentation of the alginate strips. Based on their use in China, alginates can be classified as an FKT. If left in the nasal cavity longer than one day, they may be classified as HT. The main benefit in using alginate is the gel production, which leads to higher patient comfort and the hemostatic properties. The main disadvantage is possible development of granulation which can lead to adhesions. The author sees no reason at present to use alginate.

### 2.1.7 Telfa

Telfa is a surgical wound dressing made of cotton fibres enclosed in a sleeve of polyethylene terephthalate that is perforated in a regular pattern, designed to prevent granulation. Telfa is used in Great Britain. The author sees no need to introduce the product in Germany at present.

### 2.1.8 Cellulose-Tabotamp

Tabotamp consists of oxidized regenerated cellulose and is used for hemostasis in deeper regions of the nasal sinuses that are difficult to access (i.e. sphenoid sinus, cavernous sinus) and thus difficult to manage by clipping or cautery or for fixation of dura reconstructions. In cases of diffuse bleeding, a thin layer may be sufficient to support physiological hemostasis. Otherwise, hemostasis is achieved by pressure. In this case it is important to avoid secondary damage to sensitive structures (posterior ethmoid, sphenoid sinus, skull base) by applying only moderate and avoiding excessive pressure. Tabotamp creates an acidic environment with a pH of about 3, which helps avoid infections. However, Tabotamp can lead to granulation, causing adhesions or stenosis, especially in the frontal and ethmoid sinuses. "Resorption" often takes many weeks, since the materials are not actually hydrolysed and reabsorbed. Instead, small particles are transported, suctioned, incorporated in granulations or degraded in air. According to the manufacturer, what happens to tabotamp after application in the nasal sinuses has not been systematically analysed.

## 2.2 Hemostatic/resorbable/biodegradable packs (Hämostatische Tamponaden = HT)

Patients expectations of comfort after sinus surgery have increased. Considering the risks of nasal packs (see Chapter 3), some have abandoned nasal packs altogether, leading to the development of new products, that do not have the same properties (pressure and support) as formed packs. Conventional nasal packs have disadvantages:

- The pressure of the pack and trauma during application or removal can lead to ciliary damage (Chapter 3.2)
- Removal can lead to trauma and bleeding (Chapter 3.2)
- The pressure caused by packing is uncomfortable (Chapter 3.1)
- Nasal packs have further specific risks (see Chapter 3.2 – 3.11)

In nasal septum surgery, nasal packs can be avoided if certain suture techniques and splints are used. In modern conchal and sinus surgery (FESS), nasal packs are often not required. In contrast, aggressive conchal reduction or radical sinus surgery often lead to profuse bleeding that requires formed packs since only these apply sufficient pressure. Using more gentle endoscopic sinus surgical techniques leads not only to comparable or superior surgical results, but also reduces disadvantages like crusting, scarring or osteogenesis following trauma. Finally, more comfortable nasal packs can be used.

In a series of 165 patients, Orlandi and Lanza were able to show that only 11.2% of patients undergoing endoscopic sinus surgery required a nasal pack (Kennedy Sinuspack). 2.4% received FloSeal and in 87% no pack was required at all [21]. In a similar study, Elia Schar et al. showed that 92% of 97 patients did not require a nasal pack or hemostatic materials [22].

HT are designed to avoid the disadvantages of FKT. When applied only to the wound surfaces in the ethmoid and possibly in the entrance to further sinuses, they allow the patient to breathe normally, which significantly increases patient comfort. The materials disappear due to a number of effects that are difficult to quantify: dissolution, suction, drainage etc. Different combinations of materials may lead to different effects:

- Hemostasis
- Placement of tissue through adhesive qualities
- Barrier function
- Improved wound healing
- Sealing surfaces or spaces

A number of materials have been used in the sinuses, the most important of which will be characterized. All materials are applied to the middle nasal space, the ethmoid or possibly the frontal recess. They produce gels, either upon contact with moisture in the nose, or after preparation before placement. In some cases, a thin layer of gel is applied beforehand.

### 2.2.1 Gelatine (Gelfilm, Gelfoam)

American authors have described applying gelatine derived from pig skin into the osteomeatal unit or ethmoid after sinus surgery. This has been done in addition to nasal pack placement. Application in the sinuses led to increased scarring, adhesions and shrinkage of the maxillary meatus [23], [24], [25].

## 2.2.2 Bovine Gelatine + Thrombin (Floseal)

Floseal is a highly viscous gel with hemostatic properties. It adheres to irregular and moist surfaces like the nasal sinuses, even in cases of profuse bleeding [26], and can be used in patients with reduced thrombocyte counts or defective thrombocyte function. Floseal is considered the most effective HT [6], [27]. However, it also has adverse side effects:

- Increased scarring and adhesions [28], [29], [30], [31], [32]
- Foreign body reactions and incorporation in the mucosal membranes, in some instances even after application to healthy mucosa (see Chpt. 3.3) [31], [32]

The latest Studies also confirm that HT not only induce hemostasis, but also have pro-inflammatory properties, cause granulation, adhesions and scarring [6], [32]. In the retrospective study by Shrime et al., patients treated with Floseal were more likely to undergo revision surgery (25% versus 5.1%) [30].

Another potential disadvantage is the fact that it is a bovine thrombin-gelatin derivative and thus potentially transmits BSE, although to date no case of infection has been reported. According to Baumann, approximately 80 cases of immunologically mediated blood clotting disorders have been observed, following 180 million applications [26]. Another factor to consider is the high cost.

## 2.2.3 Hyaluronic acid (i.e. Merogel, esterified hyaluronic acid, Sepragel (crosslinked hyaluronic acid polymers), Seprapack (CMC combined with hyaluronic acid))

Hyaluronic acid is a natural linear polysaccharide (glyco-amino-glycane) made of repetitive disaccharide units of sodium-D-glucuronate and N-acetyl-D-glucosamine, and is found in the basal membranes of cells and soft tissues. It is important for cell proliferation and migration. HA also plays an important role in fetal wound healing, which occurs almost without scarring.

In an early study on HA (supragel) used on 10 patients, the authors described significant improvement in adhesions and stenosis in the middle nasal space in the 2<sup>nd</sup> and 5<sup>th</sup> week after surgery [33]. McIntosh et al. found improvement in re-epithelialisation and ciliary repair in sheep noses (normal mucous membranes without chronic sinusitis) when using Merogel as compared to using no nasal pack [34]. In a later study this effect was no longer observed, when applied to sheep with induced sinusitis [35]. This study discusses the controversial data on effects of Merogel on wound healing in human and animal studies. In 2 comparable, randomized, blinded, prospective studies (42+37 patients), no significant difference between the Merogel and control group was observed following FESS [36], [37].

Study groups around Orlandi have noted that small changes in the chemical composition of HA lead to significant changes in their biomechanical and biological ef-

fects [38], [39]. Proctor also showed increased fibrosis and foreign body reactions when esterified HA (Merogel) was used on a 4 mm rabbit maxillary ostium. Other HA modifications showed no changes in effects [40].

## 2.2.4 CMC

CMC can be applied as CMC-gel (Stammberger-Gel) or as moistened Sinu knit strips. Leunig et. al. compared CMC-gel or Sinu knit with no nasal packs after FESS in a prospective study. There were no differences in

- Patient comfort (nasal obstruction, head ache, pressure, sleep disorders, general comfort) [41].
- Wound healing after endoscopic nasal sinus surgery (crusting, adhesions, granulation, wound closure) [42].
- Hemostasis or postoperative bleeding [43].

Thus, while negative effects were not observed, there were also no observable advantages to using CMC as opposed to not using a nasal pack at all.

## 2.2.5 Other HT

**Fibrin glue** has been used for epistaxis, M. Osler, clotting disorders, nasal septoplasty and sinus surgery [44]. Fibrin glue leads to less swelling, crusting and atrophic scarring, compared to electro coagulation, silver nitrate or nasal packs in treating epistaxis. An appraisal of the effects for sinus surgery is not currently possible.

The concept of using physiological growth factors to improve wound healing led to the development of **platelet gel**. This is gleaned from plasma enriched with autologous thrombocytes by centrifuging erythrocytes out of blood. The remaining sediment has a high concentration of thrombocytes and physiological fibrin, as well as growth factors like PDGF (Platelet Derived Growth Factor) and TGF (Transforming Growth Factor).

Platelet-gel is used in a number of different surgical specialties. Use in the sinuses was first described by Kerner 2001 and later by Pomerantz and Dutton 2005 [45]. The latter instilled 8 ml of gel in the sinuses at end of the surgery. These first studies showed no significant differences between Merocel and platelet-gel, apart from a slight increase in quality of life in the Platelet-gel group. Production of platelet-gel is complex and takes about 30 minutes, requiring a centrifuge and possibly extra personnel. Routine use in sinus surgery does not seem justified in the author's opinion, since the cost-effectiveness ratio seems unfavourable.

**Retinoic acid:** Vitamin A and its metabolites play an important role in the regulation of cell proliferation in the neuro-sensory and airway systems. Mucociliary and secretory dysfunction may result from lack of vitamin A. According to a study by Hwang, application of 0.01% retinoic acid improved ciliogenesis after sinus surgery, as observed 14 days post-op [46].

**Chondroitin sulfate** is a natural, linear polysaccharide. It is one of several extracellular matrix glycosaminoglycans, and has been shown to improve wound healing of skin

**Table 1: Properties of hemostatic packs**

Product	Hemostasis	Stenting of the middle turbinate	Scarring
Gelatine	Good	Good	Medium
FlowSeal	Very good	Poor	High
Avitene *	Good	Poor	High
Merogel	Poor	Poor	Low-medium <sup>+</sup>
Seprapack	Poor	Good	Low
Sepragel	Poor	Poor	Low

\* Micro fibril bovine collagen, not further described since not clinically relevant.

+ Conflicting data: fibrosis and osteoneogenesis in animal experiments after application to denuded bone surfaces.

lesions when compared to HA and a control group. In a study on rabbit maxillary sinuses chondroitin sulfate gel was applied and led to quicker healing (of small surfaces) after 4 days, but not after 6, 10 and 14 days, since the edges of the wounds could no longer be identified [47]. **Nasopore** is a biodegradable polyurethane foam that is made by dry-freezing. According to the manufacturer, the product becomes fragmented in 4–6 days. A study of 30 patients posted on the home page of Poliganics showed Nasopore easy to place and led to healing comparable to the control group. Adverse side effects were not observed. The data is not sufficient to allow an assessment and the author has no personal experience with the product. The video shows application of the product with an undefined gel. This should be avoided.

## 2.2.6 Concluding assessment of HT

Chandra and Kern came to the following conclusion in their review of studies until 2004 [48] (Table 1):

It is currently (2004!) unclear, whether the use of HT in FESS and postoperative care has any advantages. It is unclear, whether the necessity of postoperative care is reduced, when HT are used. They may be useful in achieving hemostasis and may lead to increased postoperative patient comfort for patients requiring stents or placeholders, who do not tolerate conventional NT's. In a review by Weitzel and Wormald in 2008, all English language studies on the use of absorbable materials in nasal surgery were surveyed and 38 studies evaluated [6]. FloSeal was found to be the most effective hemostatic, led, however to granulation and adhesions. To prevent adhesions, FKT are not more effective than HT and HT not more effective than no NT. The effects of Mitomycin C, hyaluronic acid and retinoic acid on scarring and adhesions in chronically inflamed sinuses has yet to be determined. There seem to be indications that this may be the case, but clear evidence is still lacking. HT can hinder wound closure, however, by increasing granulation and adhesions (see above) [49].

Since HT have not yet been shown to improve wound healing or reduce adhesions (in fact the opposite seems to be the case, leading even to foreign body reactions – see Chapter 3.3) the author does not recommend their use in routine sinus surgery. Considering the high costs, use can only be justified, if considerable advantages are

expected. Improved nasal breathing can be achieved by gentle surgical techniques (FESS) or by selective and short application of NT in the ethmoid (GFT, laminated PVA, slender Rapid Rhino) in cases of strong bleeding. It is at present unclear if certain HT materials (i.e. cross-linked) lead to better results.

## 2.2.7 New developments – NT, wound healing and scarring

Scarring and adhesions are determined by an equilibrium between fibrin production and fibrinolysis. If the sinus ostia remain blocked by blood and fibrin, fibroblasts dominate in the proliferative phase of wound healing, producing fibrin nets. If fibrinolysis is not sufficient, granulation occurs and finally collagen is deposited. Remodelling of collagen in the third post operative week leads to scarring on concave surfaces. Circular openings can become concentrically constricted. This process can continue, with decreasing activity, for months or years. Scarring can develop out of fibrin and blood deposits, even if FKT's are used in the ethmoid, i.e. the SHD.

40 years of research have provided conclusive evidence that wound healing in a moist environment is better than in a dry environment [3]. Epithelial regeneration is faster, granulation, scarring and pain are reduced and infections are less common. Superficial necrosis due to dryness is avoided. Although at present not yet completely successful, NT's aim to achieve the following goals:

- Avoid further traumatization during placement or removal, which can lead to inflammation, irritation, toxicity and foreign body reactions by utilizing atraumatic NT's or avoiding them altogether
- Occlusion of the nasal cavity to create a moist environment for wound surfaces
- Increase physiological wound healing processes (epithelial regeneration, restoration of ciliary activity) and inhibition of adverse effects (granulation or scarring)
- Reduce stenosis with scar tissue by acting as a placeholder or minimizing fibrogenesis

Wound healing can be influenced by surgical technique as well. Adhesions can be caused by the following:

- Damage to blood vessels or ischemia by coagulation, pinching tissue or ligations

- Certain materials (glove powder, textile fibers, sutures, debris)
- Blood or bacteria
- Tissue damage by heat and
- Dryness

Therefore surgery should aim to be atraumatic, avoid excessive dryness or ischemia and avoid contact with certain materials [50], [51], [52]. Inflammation (either pre-existing or developing) is also an important factor [6]. On the other hand, wound healing can also be influenced pharmacologically. Once it had been observed that HT not only improve hemostasis, but also lead to scarring, alternative substances were investigated, that can prevent scarring.

In a Cochrane review the current evidence for substances preventing or limiting adhesions in abdominal and gynaecological surgery (>80% adhesions post op) was surveyed [53]. Hyaluronic acid was the only substance which seemed to reduce the incidence of adhesions (odds ratio 0.31; 95% confidence interval 0.19–0.51). However, the authors consider the evidence at present to be tentative, considering the low number of cases described. 2 studies describe a reduction in adhesions in second-look laparoscopies after application of dextran. The authors come to the conclusion, however that the evidence for cortisol, icodextrin (alpha-1,4-glucose polymer), dextran or gel sprays is not sufficient. 3 substances currently used in surgical specialties to reduce adhesions or achieve hemostasis have recently been tested in sinus surgery. First reports have been made, but a final appraisal is pending.

### Gel spray

Synthetic polyethylene gel spray has been used in surgery for a number of years. It is made of two components that polymerise within seconds of application, forming a biocompatible, absorbable flexible hydro-gel barrier that lasts for 5–7 days and is intended to prevent scarring. The gel is hydrolysed to polyethylene-glycol molecules that are absorbed for renal elimination. It is considered non-toxic, bio-degradable, inert synthetic product and shows no risk of allergic reactions or infection. In a Cochrane review in 2006, the evidence for the efficacy of gel sprays in preventing adhesions was not considered adequate [53]. In a current randomised study, spray gel was reported to lead to less peristomal abdominal adhesions [54]. For application during sinus surgery, see chitosan.

### Chitosan

Chitosan is a bio-degradable, non-toxic complex carbohydrate derived from chitin (poly-β-1-4-N-acetyl-D-glucosamine), a natural polysaccharide that resembles hyaluronic acid and therefore presumably shows similar effects. Chitosan is the de-acetylated (at least 70%) form of chitin. If de-acetylation is 20% or less, the polysaccharide is termed chitin. Chitosan is derived from shell fish and squid chitin and shows hemostatic effects, limits adhe-

sions and is considered anti-fungal as well as anti-bacterial. Chitosan-PVP (polyvinylpyrrolidone hydrogel) limits growth of fibroblasts by preventing adherence [49], [55], [56], [57], [58], [59]. Epithelial cell growth is not impaired. In an animal experiment, 3 substances were tested on a sheep with chronic sinusitis: spray gel, recombinant tissue factor (RFT) (considered to be the prime cellular factor for initiating the coagulation cascade) and a combination of 4% dextran and chitosan (CD-gel) [49]. CD-gel led to a significant reduction of adhesions compared to RFT. RFT impaired wound healing. Adhesions in the ethmoid were observed in 40% in the control group, 0% in the CD-gel group, 14% in the gel spray group and 50% in the RFT group. Adhesions in the lateral nasal wall were observed in 15% in the control group, 10% in the CD-gel group, 10% in the gel spray group and 25% in the RFT group. Epithelial regeneration was significantly better using CD-gel and gel spray, compared to RFT. First results with chitosan are promising and encourage further studies.

### Microporous polysaccharide hemispheres (= MPH)

MPH is a bio-degradable substance derived from potato starch and is produced in spheres ranging from 10 to 200 μm. The porous surface absorbs water and small molecules and thus can concentrate thrombocytes and coagulation factors, intensifying and speeding hemostasis [60]. Conglomerations are enzymatically degraded into soluble products. Application of MPH on wounds in rabbit maxillary sinuses showed macroscopic and histological results comparable to the control group, without signs of increased fibrosis or foreign body reactions [32]. MPH are promising substances that warrant further investigation.

## 2.2.8 Important notice

In the author's opinion, many studies, including high quality studies show a **methodical flaw** that carries over into assessments and review articles.

The control for the tested substances is often no nasal pack or Merocel as standard nasal pack. However, the absence of a nasal pack leads to dryness and slows wound healing. Superficial necrosis is considered a risk factor for the development of adhesions and scarring. A dry milieu leads to considerably worse healing than a moist milieu [3], for example simple occlusion of the nose. As described above, Merocel must be considered sub optimal and should not be used. Large pores lead to granulations and increased adhesions. Therefore, the conclusion that Merocel does not influence wound healing (either positively or negatively) [61] is not correct, since "no nasal pack" leads to dryness and impaired wound healing. It would therefore be desirable and necessary to see studies compare new materials to favourable nasal packs (i.e. GFT, coated PVA-NT) or simple occlusion.

### 3 Risks, side effects and complications

Risks must be carefully weighed against benefits when using NT's. Morbidity caused by the general application of NT's as well as specific risks common to certain materials should be considered. Is the NT necessary? Can it be replaced by materials with less risks and greater patient comfort? The author has developed an information and education form which can be downloaded at <http://www.rainerweber.de/> (Nasentamponaden/Wundheilung).

#### 3.1 Patient comfort/discomfort

Patient comfort plays an increasingly important role and must be considered when choosing an NT, even if functional effectivity remains the primary concern. A prospective study by the author showed that detailed explanations about the necessity of NT's increase patient's acceptance. Even if the NT was required for longer periods of time, the discomfort experienced by the patients did not increase. Instead, patients showed increased tolerance [62]. While this requires intensive personal contact on the part of the physician, it allows occlusion treatments to be performed for several weeks. Muluk et al. came to the same conclusion using a fear and depression scale. Patients showed no significant impairment if they were sufficiently informed about the surgical procedure and postoperative NT's beforehand [63]. Discomfort is mainly caused by

- pain (see above)
- reduction in nasal air flow
- impaired sense of smell and increased nasal secretion.

Pain is mainly caused by placement and removal of NT's, but may also develop while placed. Removal of NT's is often remembered as the most uncomfortable part of the surgical procedure. Studies have shown that NT's with smooth and fine pore surfaces, that is those with the least adhesion to tissue, cause the least discomfort during removal. BWG's cause the most discomfort, followed by PVA (non-coated) and finally the rest of NT's. There is no clear order for GFT, Rapid Rhino or coated PVA. Most studies investigating comfort during removal of NT's focus on Merocel with large pores and describe moistening the pack before removal, application of local anesthetics or use of pain medications. The author recommends not using these types (non-coated PVA-NT) at all. Reduced nasal air flow can be alleviated by avoiding nasal packs that fill the nasal space completely or using breathing straws. While impaired sense of smell and increased nasal secretion may be caused by nasal packs, they are also temporarily caused by wound healing.

#### 3.2 Tissue damage – pressure necrosis

Endonasal tissue damage occurs through pressure by nasal packs or during placement and removal. While su-

perfacial tissue damage generally heals well, it may also lead to the development of granulations that bleed easily (pyogenic granuloma). These are most often found in the anterior segment of the nasal septum. Excessive pressure over time can lead to necrosis of the mucous tissues, septal cartilage, and bone in septum or nasal conchae. Balloon catheters are especially susceptible to pressure damage, since the pressure is difficult to judge [64]. Other NT's can also lead to high pressure when applied in multiple numbers. In a study by Shaw et al. pressure damage was investigated after 10 minutes [65]. After application of gauze packs intact ciliated epithelium was found in 32.3%, after use of neurological cotton in 50.4% and in the control group in 85%. There was no significant difference between gauze-strips and neurological cotton. Necrosis of the columella or alar cartilage can be caused by threads being too tightly knotted or by the packs themselves, especially when balloon catheters are used. In treating difficult cases of epistaxis, care is not always taken to assess the length of extra-nasal portions of the nasal pack. Points of increased pressure can cause problems for the thin epithelium in the nasal vestibulum or for the cartilage, which lacks its own blood supply. Thus even materials which initially seem soft can lead to ischemia and pressure damage.

It is important to ensure that the threads used to secure the nasal packs have enough wiggle room. Both the knot and the anteriorly secured threads should not cut into the columella. It is important to remember that swallowing can cause negative pressure in the post-nasal space, which may lead to movement of smooth packs. Pressure damage can be avoided by:

- using threads of sufficient length
- using a guard for the columella
- checking for signs of tissue damage daily.

Pressure damage does not always lead to pain, so patients may not always notice this complication themselves. Damage can lead to lasting scars that may even require revision surgery. Correct placement of all FKT must be monitored regularly.

#### 3.3 Foreign body reactions

Jacob et al. were the first to describe neoosteogenesis in denuded mouse bone in the nasal sinuses after application of Merogel [66]. Maccabee et al. described strong fibrosis of the basal lamina and the propria lamina, loss of superficial epithelium as well as incorporation of Merogel in rabbit maxillary sinuses [31]. Resorption of Merogel was minimal. FloSeal showed similar fibrosis and loss of mucociliary layers as well as incorporation into the regenerating membranes. The studies have been criticized for the application of large amounts of Merogel on denuded bones, which does not reflect clinical practice [37]. Wormald's group found no signs of neoosteogenesis in their studies.

However, current studies by Proctor [40] support the results of Jacoby and Maccabee. The side effects of



FloSeal were also recently confirmed [32]. It seems clear that the type of HA used (esterified, cross-linked) has a major effect on mucosa reactions [38].

### 3.4 Dislocation

Posterior dislocation of nasal packs is the most dreaded complication. Dislocation can occur regardless of the material used, as long as form and size allow passage of the choanae into the nasopharynx. GFT and BWG's seem especially prone to dislocation. Dislocation results in gagging and even obstruction of the larynx or trachea. Cases of lethal asphyxiation have been described and are presumably due to inadequate securing of packs [1]. It is important to recognize symptoms of dislocation and react immediately. If in doubt, the nasal pack should always be removed. If nasal packs show signs of movement, gagging and swallowing usually lead to increased loosening. Therefore the author recommends that problems with nasal packs be treated immediately as an emergency. When placing multiple GFT's it is important to avoid posterior dislocation of the first pack by the second or third packs. Proper positioning can be checked by comparing thread length. The assistant should secure the first pack while the second pack is being placed.

Correct securing of nasal packs (preventing aspiration) is of first importance and seems, in the author's opinion, often to be underestimated. The knot should be placed in front of the columella and the threads secured by two strips of adhesive tape. Multiple packs can be knotted together.

RapidRhino 7.5 cm packs can also be dislocated. In one case this led to intestinal perforation. The pack was removed by laparotomy [67].

Improper placement of nasal packs can even lead to intracranial displacement, as reported for Foley-catheters, choanal stents and frontal sinus stents. Nasal packs should therefore always be checked for proper placement.

### 3.5 Obstructive sleep apnoea syndrome (OSAS)

Although literature is abundant, there is little agreement on the effects of nasal packs on sleep related breathing disorders or oxygen saturation. Induction or worsening of obstructive sleep apnoea syndrome are possible. The risk seems to be increased for elderly patients with pulmonary or cardiac conditions. In these cases nasal packs should be avoided or used only temporarily under nightly monitoring (i.e. pulse oximetry).

### 3.6 Tube dysfunction

Nasal packs may lead to temporary tube dysfunction with negative middle ear pressure (as in the Toynbee maneuver). According to most studies, breathing straws do not alleviate this problem. However, pressure normalizes rapidly when the nasal packs are removed.

### 3.7 Allergies

Allergies are an important factor and a careful inquiry must be made prior to each procedure. The increase of latex allergies has led to the development of latex free GFT's (Rhinotamp Latexfrei, Vostra, Aachen; Schaumstoffnasentamponade mit latexfreier Behautung, Spiggle & Theis, Overath). The author recommends avoiding potential problems by using only latex free materials, even if they are more expensive. It is important to point out that increased IgE antibodies against latex in RAST-tests (about 25% of the general population), do not necessarily correspond to clinically relevant latex allergies. It is advisable to question patients specifically about the use of latex gloves or condoms. If there are no clear signs for allergies, a RAST-test should be avoided, since the results cause more confusion than help.

Anaphylactic allergic reactions to CMC have been reported [68], [69]. Muroi et al. found elevated CMC-specific IgE antibodies in 9% of 387 screened patients [69]. One case of allergic reaction to Merocel has been reported as a rare but possible reaction to polyvinyl chloride [70]. Allergic reactions must be considered for HT as well (i.e. against thrombin).

### 3.8 Toxic shock syndrome

Toxic shock syndrome is a rare, multi system disease characterized by high fever, diffuse erythema, vomiting, diarrhoea and muscle pain at onset and can lead to septic shock. Toxic shock syndrome is a rare complication following staphylococcal infection and is caused by toxic shock syndrome toxin (TSST 1). Some streptococci can cause TSS or severe inflammatory necrosis as well. Usually, TSS develops within 24 hours of nasal surgery and is associated with the placement of nasal packs. On the other hand, there have been reports of patients developing a delayed staphylococcal TSS (within days or up to 5 weeks after nasal sinus surgery or septoplasty) although no nasal pack had been used [1]. So although nasal stents or packs increase the risk for the development of TSS, the exact role they play remains unclear. The development of TSS is not limited to nasal pack or stent placement! It can not be anticipated and can not be avoided by antibiotics. It can develop after all endonasal procedures.

Recognition of the disease and immediate and adequate treatment are imperative. This includes immediate removal of nasal packs (if still in situ), immediate i.v. antibiotic treatment and possibly transfer to an intensive care unit. Second generation cephalosporins are ideal, targeting both staphylococci and streptococci. The author recommends application of the second dose after 4 hours to optimize treatment in the critical early phase.

### 3.9 Nasal packs and antibiotics

A nasal pack is not per se an indication for antibiotic treatment. The nasal pack ensures occlusive wound

healing. This leads to changes in the bacterial milieu (increase in gram negative pathogens with unpleasant odor) but not to increased infection. In fact, occlusion leads to a moist milieu which optimizes physiological defense mechanisms and thus leads to less infections than open wounds. There is no conclusive evidence that the use of nasal packs leads to an increase in infections [71], [72]. The same applies to nasal packs with antibacterial additives. Routine application of antibiotics for patients with nasal packs therefore does not seem necessary. The author's own extensive experience confirms that patients without an antibiotic showed no increase in infections. The typical unpleasant odor that develops after prolonged use of nasal packs is due to colonization of gram negative bacteria [73] and should not be mistaken for an infectious disease requiring treatment. Antibiotics seem advisable in cases of acute bacterial infection (including purulent intraoperative superinfection of chronic inflammation), Diabetes or immune deficiencies, after performance of dura reconstruction or after compression of the Eustachian tube by packing in the nasopharynx. According to the author's knowledge, there are no high quality studies available on this topic.

If swelling in the nose or mid face occur, or the nose becomes tender to touch while a nasal pack is placed, the author recommends immediate removal and application of an antibiotic that is effective for both staphylococci and streptococci, i.e. a second generation cephalosporin. As soon as the inflammatory signs have regressed, the antibiotic treatment can be discontinued. According to the author's experience, continued oral antibiotic treatment is unnecessary.

### 3.10 Paraffin granuloma and spherulocytosis

Paraffin granulomas or paraffinomas develop if the periorbit has been damaged (signaled by a „black eye“) and paraffin ointments are used, for example for nasal pack placement [74]. Paraffinomas have also been described following rhinoplasty when paraffin drenched gauze is used. Paraffin is a common ingredient for ointments but not gels. Paraffin ointments are not degradable and lead to foreign body reactions. If paraffin is injected into tissue, typical paraffinomas or lipo granulomas develop over a time period of weeks or years.

Paraffin granulomas present as slow growing solid masses. Histologically they are characterized by giant cell foreign body granulomas and numerous vacuoles of different sizes. These develop when the tissue is deparaffinized. Surrounding the vacuoles are signs of tissue reaction.

Because paraffinomas are diffuse, complete removal is difficult. Still, surgical removal is the only viable treatment. Since small peri orbital lesions may remain undetected (swelling of the cheeks may develop following diffuse bleeding, dehiscence along the anterior ethmoid artery, or postoperative pressure increases), it is imperative to avoid paraffin based ointments or creams during nasal sinus surgery.

**Spherulocytosis** or **mysospherulosis** is a foreign body reaction occurring after the use of antibiotic ointments in wounds or on muscles [75]. Dilated cystic spaces of varying size surrounded by histiocytes and multi nuclear giant cells are observed in histological examination. The foreign body reaction has been reported for varying antibiotic ointments and seems to be caused by the emulsion of aliphatic materials in blood. Spherulocytosis and paraffin granulomas seem closely related.

### 3.11 Nasal packs as foreign bodies

Nasal packs that are forgotten and left in the nose during or after surgical procedures can lead to inflammatory complications. Gotwald et al. reported about gauze strips left in the ethmoid [76], leading to the recommendation to use only strips with x-ray markings [77]. In the author's opinion it is important to only use packs that can be identified from outside the nose during or after surgery. This is especially recommended for thin gauze strips. Neuro swabs with threads are to be preferred for hemostasis during surgery. If materials (stents, struts etc...) are to be left in the nasal space, this must be carefully documented and discussed with the patient. The foreign bodies must be placed correctly and firmly secured. Follow up must be guaranteed and removal planned.

## 4 Requirements for new products and training

The author urgently recommends that endonasal application of substances without solid evidence for effectivity or benefit be avoided. This is especially the case for substances which have proven negative effects, even if „experience“ might indicate otherwise.

In agreement with Orlandi 2007, the author recommends that nasal pack materials be thoroughly tested prospectively before being used in clinical practice [39]. New materials should not be tested against those already known for their poor performance, making them appear promising. Follow up testing and clinical practice often reveal not only lacking superiority but even new risks (see Mergel, FloSeal, chapter 2.2.6. and 3.3.)

#### Requirements for nasal packs

The following characteristics should be required for nasal packs and stents in endonasal surgery (1):

- non toxic
- non allergenic
- inert (no foreign body reactions)
- non dislocating
- easily placed
- easily removed
- painless (patient comfort)
- adaptable to individual anatomic variations (hemostasis, wound healing)

- apply uniform pressure to the membranes
- support wound healing
- ensure breathing
- preserve smell

Characteristics required for hemostatic packs include:

- achieve hemostasis of arterial, venous or capillary bleeding within 2 minutes
- ready for use without tedious preparation
- easy to apply
- lack tissue side effects
- safe (no risk for the transmission of diseases)
- low-cost
- light and durable, stable at room temperature and keep for at least 2 years, even under extreme temperatures (important for military applications!)

In the future aspects such as interaction between foreign materials, micro organisms and body tissues will need to be considered. Incorporation of granulation tissue, for example, is determined not only by the size of pores in the foreign material used. The cells involved also depend on adhesion, so the absorptive, adhesive or repellent qualities of the material also play a major role. Nasal packs should also allow the release of medications to influence wound healing (i.e. growth factors, cytokines), even if this has not yet been successful (cortisol in hyaluronic acid (Merogel), IGF-1 in HA [78], [79] and cortisol in GMC [80]).

### Training

In Great Britain training the placement of nasal packs on models has been repeatedly recommended [81], [82], [83] (Laerdal Airway Managementtrainer, Laerdal Medical Libited UK, Orpington, Kent, <http://www.laerdal.com/de/>). The author supports this recommendation, which is common for many surgical procedures. Considering how often poorly placed nasal packs lead to „unstoppable“ nose bleeding, training seems more than called for.

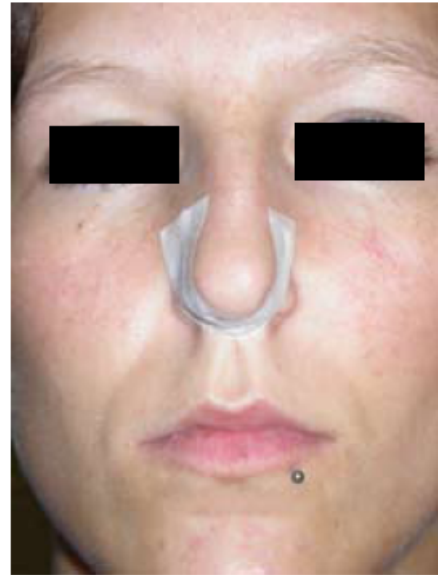A study in Great Britain showed the importance of correct placement of nasal packs for management of epistaxis. When placed by an ENT, nasal packs were more effective (i.e. avoiding further treatment, like cautery) than when placed by an emergency physician [84].

## 5 Nasal packs – summary of current clinical assessment

There is no single nasal pack that is suited to all indications. High quality patient care can only be provided if ENT's have an array of nasal packs at their disposal for different indications.

The prime factor in choice of packing for sinus surgery is the type of procedure performed. Atraumatic, and thus in the author's opinion, predominately endoscopic surgery according to pathophysiological criteria, allows for innovations in nasal packing.

- This type of surgery often does not require nasal packing at all, considerably increasing patient comfort. However, occlusion, and thus a favorable moist milieu, is not achieved either.
- If FKT's are applied after surgery to achieve hemostasis, they should be atraumatic: GFT, coated PVA-NT, Netcell with synthetic coating, possible Rapid Rhino. Depending on individual parameters, the nasal pack can be removed the same day or after one or two days. Longer placement does not seem warranted.
- If occlusion to stimulate wound healing is desired, and no other side effects besides impaired nasal breathing are to be expected, the nasal vestibulum can be closed using soft adhesive tape. This is simple, effective and economical and can be applied to one or both sides (Figure 2). This creates a moist endonasal milieu which prevents dryness and crusting.



**Figure 2: Occlusion of the nose for better intranasal wound healing (moist environment)**

Occlusion can, of course, also be achieved by more elaborate products. However, alternative FKT's may lead to accumulation of blood and fibrin in the ethmoid oder frontal sinus drains, which can lead to scarring. Occlusion is maintained, until wound healing has progressed sufficiently. After „normal“ pan-sinus surgery one week is usually sufficient. In tumor-surgery the author usually chooses longer intervals. During occlusion the application of ointments, nasal irrigation or cleaning is not usually required. Although secretion is increased, infections are not more frequent since physiological defense mechanisms abound in this milieu. The only disadvantage is the complete obstruction of nasal breathing.

- For management of posterior epistaxis that is not endoscopically controlled, an atraumatic variant of a 10 cm PVA-NT (i.e. Netcell) or a BK is recommended.
- Because of their known side effects, HT (especially FloSeal, esterified HA) can not be recommended. Time will tell if cross-linked materials or CMC-gel produce

better results. The high price and lack of data proving effectivity also support this assessment. Nasal air passage may be preserved in some cases, if NT's are placed directly into the ethmoid (GFT, coated PVA, slim Rapid Rhino).

**Economic factors**, including cost-effectiveness ratio, must also be considered when using nasal packs. The primary goal of the physician is to increase patient comfort and safety. Even if new developments are more costly, they should be employed for the benefit of our patients. Politics, administration and controlling should not determine our professional choices.

## 6 Stents/Struts

Stents or struts (synonymous terms in the author's opinion) are used in sinus surgery to prevent scarring and constriction of newly formed sinus openings. At present only stenting of the frontal sinus is indicated.

### 6.1 Maxillary sinus stenting

Maxillary sinus stents for the middle meatus have been described [1], [85] and have led to good results, but are not necessary. The maxillary sinus is easily and atraumatically reached using endoscopic techniques. In revision cases with a narrow middle meatus, an alternative opening can be made under the inferior turbinate. In cases of revision surgery, for example after Caldwell-Luc procedures, the inferior turbinate can be temporarily divided to provide ample maneuvering space. Stents can be placed [86], but seem avoidable if good surgical technique is employed.

### 6.2 Middle turbinate stenting

To prevent adhesions between the middle turbinate and the lateral nasal wall, which would otherwise obstruct passage to the ethmoid, different products have been used. The only currently viable product is a "u"-shaped coat for the middle turbinate, a poly urethane glove, "Boomerang Turbinate Glove" (Medtronic). Aside from atraumatic surgical techniques, leaving portions of the ethmoid bulla to prevent lateral displacement of the middle turbinate, transseptal suture techniques and bolgerisation have proven effective.

### 6.3 Frontal sinus stenting (SHPH)

Constriction of sinus ostia appears to be the result of blood and fibrin deposits, membrane damage, contact between swollen surfaces and circular stricture. Denuded bone surfaces can also show granulation tissue development and even neoosteogenesis. A SHPH is therefore designed to act as a splint to guide epithelial regeneration, prevent filling of spaces with blood and fibrin and reduce granulation. Subepithelial scars consolidate as long while the stent is in place. Therefore effective

stenting seems to require placement for several months, until wound healing is completed [1], [4], [5].

Indications for endonasal surgical approaches can be broadened if combined with stent placement. Especially in cases of a narrow ethmoid space, extensive wound surfaces or scar revision, stenting represents an alternative to Type III drainage or obliteration. A typical indication is revision after Jansen-Ritter procedures with collapsing of lateral frontal sinus drain and development of a mucocele. Local follow up treatment with instruments in the frontal space is not required.

At present, a number of frontal sinus stents are available:

- Rains frontal sinus stent (Gyrus GmbH): the stent is self retaining by a small expandable bulb. This is designed to prevent dislocation and aspiration. The author has had many years of experience with this stent.
- Parrel frontal sinus T-stent (Medtronic - Xomed GmbH): achieves self retention by T-shaped divergent ends.
- Jacobs frontal sinus cannula (Hood Laboratories, Pembroke, MA, USA): uses a cross-shaped anchor.
- Freemann frontal sinus stent (Fahl Medizintechnik, Kerpen): biflanged for retention.
- In Germany silicone or polyethylene tubes (Weber) were used over 10 years ago. These can not be recommended any more, since commercially available stents are made of softer materials and do not require sutures to secure them.
- The author has also given up using U-shaped or H-shaped silicone tubes which were placed transseptally after Type-III drainage.
- First results with **frontal sinus stents** drenched in dexamethasone [87] seem promising, but must be confirmed in larger studies. The use of cytostatic taxol (paclitaxel), which also shows anti-angiogenic and anti-proliferative qualities in animals showed results comparable to uncoated stents 4 weeks after placement (N=4) [88]. Current studies are investigating the use of doxycyclin (Bachert, personal communication 2008), which led to improved results (publication in process).

The opinion that firm frontal sinus stents are inferior to soft materials is based on the results of Neel et al. in 1976, who investigated the influence of stents on the frontal sinus drain in 8 dogs [89]. 2 dogs received surgery apart from the frontal sinus, in 2 cases the frontal sinus ostium was drilled to a size of 1.5 cm diameter without stent placement, in the remaining 4 cases one soft (rolled silicone membrane) and one hard stent (silicone tube) was placed. After 2 months the stents were removed and after another 4 months histological investigation took place. For hard stents 2 of 4 drains were completely obliterated, 2 showed ostia of 1–2 mm diameter. Of the 4 treated with soft stents, 3 showed ostia 4 mm in diameter and one 2 mm in diameter. It is debatable, however, if these results have conclusively demonstrated that **hard** stents lead to inferior results than soft stents. The poor results may also have been the result of

choosing tubes that were too large, leading to pressure necrosis and scarring rather than wound healing. Still criticism of hard stents seems plausible. Flexible SHPH have the advantage of being adaptable to individual anatomic features. It also seems plausible that excessive pressure has a negative effect on wound healing. Common problems for all silicone stents include:

- edema caused by the foreign body. Edema usually regresses within 4 weeks;
- crusting at the nasal end and irritation of the lateral nose wall and septum;
- persisting nasal secretion;
- retention of secretion in the frontal sinus with uncomfortable pressure and even superinfection if drainage past the SHPH is not sufficient.

Removal of the stent (i.e. the Rains SHPH) is also often associated with a short but intense pain and even bleeding, since the stent is not soft enough to be completely atraumatic.

The results of surgery of the frontal sinus with the use of stents are encouraging. Still, advantages and disadvantages must be weighed in each individual case and should be discussed with the patient at length. It is important to allow for placement over sufficiently long intervals. Wound healing should pass stage 3 (reorganisation and scarring). This means a period of about 6 months seems advisable, as recommended by Yamasoba and Schaller [90], [91]. In the author's own prospective study [4], placement of stents for 6 months after Type II drainage surgery led to significantly reduced stenosis of the neo-ostium. After 12–16 months follow up, the ostium was open in 80% of the cases versus 33% treated only endoscopically. Bamhira et al. placed individualized thin silicone membranes that completely covered the drain space for 8 weeks after Type III surgery. After an average of 22 months follow up (6–75 months), stenosis was similar for both stent and non-stented cases: 60% versus 61.5% open, 32% versus 35.9% reduced and 8% versus 2.6% obliterated. Reduction of the neo-ostium occurred within the first 10 months of follow-up. Rains removes stents when the ethmoidal surface of the drain shows epithelial regeneration and there is no purulent secretion or polypoid mucosa [92]. This occurs after an average of 35 (6–39) days (102 patients). Open frontal ostia were reported in 67 patients with a rate of 94% after 8–46 months. Linn and Witerick analyzed 21 frontal sinus stents in 11 patients after placement of stents for over 3 months [93]. At the time 10 stents were still in place, the others had been removed after an average of 16.3 months. Spontaneous dislocation occurred in 14% after an average of 8.8 months. Irreversible obstruction occurred in 5% of the cases.

In summary then, SHPH can be helpful in certain cases. They must remain placed, however, for a sufficient length of time. At present none of the available products are ideal. The main problem is the inadequate forms available (round with a diameter of 4–6 mm), which do not always coincide with individual frontal sinus openings. The author

currently prefers optimizing surgical technique with special instruments for the frontal sinus [94], [95] and uses stents less often than a number of years ago. Wenn SHPH are used, one should:

- use multiple SHPH to avoid a round form and increase the diameter in at least one plain;
- avoid excessive pressure on wound surfaces which can lead to necrosis and impaired healing by employing individualized silicone membranes;
- leave stents in situ for 6 months or until healing is confirmed by endoscopy.

## Abbreviations

BK = Ballonkatheter (balloon catheter)

BWGS = Baumwollgazestreifen (cotton gauze strips)

ENT = Expandierbare Nasentamponade(n) (expandable nasal pack)

FESS = funktionelle endoskopische NNH-OP (functional endoscopic sinus surgery)

FKT = Formkörper tamponade (formed nasal packs)

HA = Hyaluronsäure (hyaluronic acid)

HT = Hämostatische / Resorbierbare / Biologisch abbaubare Tamponaden (hemostatic, resorbable, biodegradable packs)

MPH = mikroporöse Polysaccharidhemisphären (micro pore poly sacharide hemispheres)

NNH = Nasennebenhöhlen (nasal sinuses)

NT = Nasentamponade(n) (nasal pack)

OSAS = Obstruktives Schlafapnoesyndrom (obstructive sleep apnoea syndrome)

PU = Polyurethan (poly urethane)

PVA-NT = Polyvinylacetal-Nasentamponaden (poly vinyl acetal nasal pack)

SHD = Stirnhöhlendrainage (frontal sinus drain)

SHPH = Stirnhöhlenplatzhalter (frontal sinus stent)

TSS = Toxisches Schock Syndrom (toxic shock syndrome)

VAS = Visuelle Analogskala (visual analogue scale)

## References

1. Weber R, Hochapfel F, Leuwer R, Freigang B, Draf W. Tamponaden und Platzhalter in der endonasalen Chirurgie. HNO. 2000; 48: 240-256.
2. Beule A G, Weber R K, Kaftan H, Hosemann W. Übersicht: Art und Wirkung geläufiger Nasentamponaden. Laryngo-Rhino-Otol. 2004; 83: 534-551. DOI: 10.1055/s-2004-825695
3. Weber R, Keerl R. Einsatz moderner Bild-Datenverarbeitung in der klinisch rhinologischen Forschung. Eur Arch Otorhinolaryngol. 1996; Suppl I : 271-296.
4. Weber R, Hosemann W, Draf W, Keerl R, Schick B, Schinzel S. Endonasale Stirnhöhlenchirurgie mit Langzeiteinlage eines Platzhalters. Laryngo-Rhino-Otol. 1997; 76: 728-734. DOI: 10.1055/s-2007-997515
5. Weber R, Mai R, Hosemann W, Draf W, Toffel P H. The success of 6-month stenting in endonasal frontal sinus surgery. ENT Journal. 2000; 79: 930-941.

6. Weitzel E K, Wormald P J. A Scientific Review of Middle Meatal Packing/Stents. *Am J Rhinol.* 2008; 22: 302-307. DOI: 10.2500/ajr.2008.22.3171
7. Bresnihan M, Mehigan A, Curran A. An evaluation of Meroceol and Series 5000 nasal packs in patients following nasal surgery: a prospective randomised trial. *Clin Otolaryngol.* 2007; 32: 352-355. DOI: 10.1111/j.1749-4486.2007.01517.x
8. Titiz A, Zeyrek T, Ozcan M, Sabuncuoglu B, Yilmaz Y F, Unal A. The effects of meroceol and glove finger tampon applications on the nasal septum mucosa of rabbits. *Rhinology.* 2008; 46: 112-115.
9. Badran K, Malik T H, Belloso A, Timms M S. Randomized controlled trial comparing Meroceol and Rapid Rhino packing in the management of anterior epistaxis. *Clin Otolaryngol.* 2005; 30: 333-337. DOI: 10.1111/j.1365-2273.2005.01019.x
10. Singer A J, Blanda M, Cronin K, LoGiudice-Khwaja M, Gulla J, Bradshaw J, Katz A. Comparison of nasal tampons for the treatment of epistaxis in the emergency department: a randomized controlled trial. *Ann Emerg Med.* 2005; 45: 134-139. DOI: 10.1016/j.annemergmed.2004.10.002
11. Cruise A D, Amonoo-Kuofi K, Srouji I, Kanagalingam J, Georgalas C, Patel N N, Baida L, Lund V J. A randomized trial of Rapid Rhino Riemann and telfa nasal packs following endoscopic sinus surgery. *Clin Otolaryngol.* 2006; 31: 25-32. DOI: 10.1111/j.1749-4486.2006.01122.x
12. Gudziol V, Mewes T, Mann W J. Rapid Rhino: A new pneumatic nasal tamponade for posterior epistaxis. *Otolaryngol Head Neck Surg.* 2005; 132: 152-155. DOI: 10.1016/j.otohns.2004.04.005
13. McGarry G W, Aitken D. Intranasal balloon catheters: how do they work?. *Clin Otolaryngol Allied Sci.* 1991; 16: 388-392. DOI: 10.1111/j.1365-2273.1991.tb00955.x
14. Simmen D B, Raghavan U, Briner H R, Manestar M, Groscurth P, Jones N S. The anatomy of the sphenopalatine artery for the endoscopic sinus surgeon. *Am J Rhinol.* 2006; 20: 502-505. DOI: 10.2500/ajr.2006.20.2928
15. Randall D A. Epistaxis packing. Practical pointers for nosebleed control. *Postgrad Med.* 2006; 119: 77-82.
16. Gehrking E, Weerda H. A modified nasal tamponade with foam rubber protection in epistaxis. *Laryngo-Rhino-Otol.* 1995; 74: 463-464. DOI: 10.1055/s-2007-997781
17. Ho E C, Mansell N J. How we do it: a practical approach to Foley catheter posterior nasal packing. *Clin Otolaryngol Allied Sci.* 2004; 29: 754-757. DOI: 10.1111/j.1365-2273.2004.00922.x
18. Almeyda R, Shahzad A, Bleach N. Silicone Foley catheters outperform latex Foley catheters for post-nasal packing: an in vitro study. *Clin Otolaryngol.* 2007; 32: 480-491. DOI: 10.1111/j.1749-4486.2007.01489.x
19. McFerran D J, Edmonds S E. The use of balloon catheters in the treatment of epistaxis. *J Laryngol Otol.* 1993; 107: 197-200. DOI: 10.1017/S0022215100122625
20. Chevillard C, Rugina M, Bonfils P, Bougara A, Castillo L, Crampette L, Pandraud L, Samardzic M, Peynègre R. Evaluation of calcium alginate nasal packing (Algostéril) versus Polyvinyl acetal (Meroceol) for nasal packing after inferior turbinate resection. *Rhinology.* 2006; 44: 58-61.
21. Orlandi R R, Lanza D C. Is nasal packing necessary following endoscopic sinus surgery? *Laryngoscope.* 2004; 114: 1541-1544. DOI: 10.1097/00005537-200409000-00007
22. Eliashar R, Gross M, Wohlgeleerter J, Sichel J Y. Packing in endoscopic sinus surgery: is it really required?. *Otolaryngol Head Neck Surg.* 2006; 134: 276-279. DOI: 10.1016/j.otohns.2005.10.012
23. Catalano P J, Roffman E J. Evaluation of middle meatal stenting after minimally invasive sinus techniques (MIST). *Otolaryngol Head Neck Surg.* 2003; 128: 875-881. DOI: 10.1016/S0194-5998(03)00469-8
24. Rust K R, Stringer S P, Spector B. The effect of absorbable stenting on postoperative stenosis of the surgically enlarged maxillary sinus ostia in a rabbit animal model. *Arch Otolaryngol Head Neck Surg.* 1996; 122: 1395-1397.
25. Tom L W, Palasti S, Potsic W P, Handler S D, Wetmore R F. The effects of gelatin film stents in the middle meatus. *Am J Rhinol.* 1997; 11: 229-232. DOI: 10.2500/105065897781751884
26. Baumann A, Caversaccio M. Hemostasis in endoscopic sinus surgery using a specific gelatin-thrombin based agent (FloSeal). *Rhinology.* 2003; 41: 244-249.
27. Björse K, Holst J. Various Local Hemostatic Agents with Different Modes of Action; an in vivo Comparative Randomized Vascular Surgical Experimental Study. *Eur J Vasc Endovasc Surg.* 2007; 33: 363-370. DOI: 10.1016/j.ejvs.2006.10.011
28. Chandra R K, Conley D B, Kern R C. The effect of FloSeal on mucosal healing after endoscopic sinus surgery: a comparison with thrombin-soaked gelatin foam. *Am J Rhinol.* 2003; 17: 51-55.
29. Chandra R K, Conley D B, Haines 3rd G K, Kern R C. Long-term effects of FloSeal packing after endoscopic sinus surgery. *Am J Rhinol.* 2005; 19: 240-243.
30. Shrimme M G, Tabae A, Hsu A K, Rickert S, Close L G. Synechia formation after endoscopic sinus surgery and middle turbinate medialization with and without FloSeal. *Am J Rhinol.* 2007; 21: 174-179. DOI: 10.2500/ajr.2007.21.2986
31. Maccabee M S, Trune D R, Hwang P H. Effects of topically applied biomaterials on paranasal sinus mucosal healing. *Am J Rhinol.* 2003; 17: 203-207.
32. Antisdel J L, Janney C G, Long J P, Sindwani R. Hemostatic agent microporous polysaccharide hemospheres (MPH) does not affect healing or intact sinus mucosa. *Laryngoscope.* 2008; 118: 1265-1269. DOI: 10.1097/MLG.0b013e31816c7bc9
33. Kimmelman C P, Edelstein D R, Cheng H J. Sepragel sinus (hylan B) as a postsurgical dressing for endoscopic sinus surgery. *Otolaryngol Head Neck Surg.* 2001; 125: 603-608. DOI: 10.1067/mhn.2001.120229
34. McIntosh D, Cowin A, Adams D, Rayner T, Wormald P J. The effect of a dissolvable hyaluronic acid-based pack on the healing of the nasal mucosa of sheep. *Am J Rhinol.* 2002; 16: 85-90.
35. Rajapaksa S P, Cowin A, Adams D, Wormald P J. The effect of a hyaluronic acid-based nasal pack on mucosal healing in a sheep model of sinusitis. *Am J Rhinol.* 2005; 19: 572-576.
36. Miller R S, Steward D L, Tami T A, Sillars M J, Seiden A M, Shete M, Paskowski C, Welge J. The clinical effects of hyaluronic acid ester nasal dressing (Merogel) on intranasal wound healing after functional endoscopic sinus surgery. *Otolaryngol Head Neck Surg.* 2003; 128: 862-869. DOI: 10.1016/S0194-5998(03)00460-1
37. Wormald P J, Boustred R N, Le T, Hawke L, Sacks R. A prospective single-blind randomized controlled study of use of hyaluronic acid nasal packs in patients after endoscopic sinus surgery. *Am J Rhinol.* 2006; 20: 7-10.
38. Orlandi R R, Shu X Z, McGill L, Petersen E, Prestwich G D. Structural variations in a single hyaluronan derivative significantly alter wound-healing effects in the rabbit maxillary sinus. *Laryngoscope.* 2007; 117: 1288-1295. DOI: 10.1097/MLG.0b013e318058a083
39. Orlandi R R. Biomaterials for sinus implantation. *Curr Opin Otolaryngol Head Neck Surg.* 2007; 15: 44-47. DOI: 10.1097/M00.0b013e318011bc9d

40. Proctor M, Proctor K, Shu X Z, McGill L D, Prestwich G D, Orlandi R R. Composition of hyaluronan affects wound healing in the rabbit maxillary sinus. *Am J Rhinol.* 2006; 20: 206-211.
41. Leunig A, Betz CS, Siedek V, Kastl KG. CMC packing in functional endoscopic sinus surgery: does it affect patient comfort? *Rhinology.* 2009 Mar;47(1):36-40.
42. Kastl KG, Betz CS, Siedek V, Leunig A. Control of bleeding following functional endoscopic sinus surgery using carboxymethylated cellulose packing. *Eur Arch Otorhinolaryngol.* 2009 Aug;266(8):1239-43. DOI: 10.1007/s00405-008-0881-8
43. Kastl KG, Betz CS, Siedek V, Leunig A. Effect of carboxymethylcellulose nasal packing on wound healing after functional endoscopic sinus surgery. *Am J Rhinol Allergy.* 2009 Jan-Feb;23(1):80-4. DOI: 10.2500/ajra.2009.23.3267
44. Vaiman M, Eviatar E, Shlamkovich N, Segal S. Use of fibrin glue as a hemostatic in endoscopic sinus surgery. *Ann Otol Rhinol Laryngol.* 2005; 114: 237-241.
45. Pomerantz J, Dutton J M. Platelet gel for endoscopic sinus surgery. *Ann Otol Rhinol Laryngol.* 2005; 114: 699-704.
46. Hwang P H, Chan J M. Retinoic acid improves ciliogenesis after surgery of the maxillary sinus in rabbits. *Laryngoscope.* 2006; 116: 1080-1084. DOI: 10.1097/01.mlg.0000224352.50256.99
47. Gilbert M E, Kirker K R, Gray S D. Chondroitinsulfate hydrogel and wound healing in rabbit maxillary sinus mucosa. *Laryngoscope.* 2004; 114: 1406-1409. DOI: 10.1097/00005537-200408000-00017
48. Chandra R K, Kern R C. Advantages and disadvantages of topical packing in endoscopic sinus surgery. *Curr Opin Otolaryngol Head Neck Surg.* 2004; 12: 21-26. DOI: 10.1097/00020840-200402000-00007
49. Athanasiadis T, Beule A G, Robinson B H, Robinson S R, Shi Z, Wormald P J. Effects of a novel chitosan gel on mucosal wound healing following endoscopic sinus surgery in a sheep model of chronic rhinosinusitis. *Laryngoscope.* 2008; 118: 1088-1094. DOI: 10.1097/MLG.0b013e31816ba576
50. Davey A, Majer P J. Surgical adhesions: A timely update, a great challenge for the future. *J Minimal Inv Gynecol.* 2007; 14: 15-22. DOI: 10.1016/j.jmig.2006.07.013
51. Liakakos T, Thomakos N, Fine R M, Dervenis C, Young R L. Peritoneal adhesions: etiology, pathophysiology, and clinical significance. *Dig Surg.* 2001; 18: 260-273. DOI: 10.1159/000050149
52. Risberg B. Adhesions: preventive strategies. *Eur J Surg.* 1997; Suppl 577: 32-39.
53. Metwally M, Watson A, Lilford R, Vandekerckhove P. Fluid and pharmacological agents for adhesion prevention after gynaecological surgery (review). *Cochrane Database Syst Rev.* 2006; CD001298.
54. Tjandra J J, Chan M K. A sprayable hydrogel adhesion barriere facilitates closure of defunctioning loop ileostomy: a randomized trial. *Dis Colon Rect.* 2008; 51: 956-960. DOI: 10.1007/s10350-007-9181-4
55. Chou T C, Fu E, Wu C J, Yeh J H. Chitosan enhances platelet adhesion and aggregation. *Biochem Biophys Res Comm.* 2003; 302: 480-483. DOI: 10.1016/S0006-291X(03)00173-6
56. Dutkiewicz J K. Superabsorbent Materials from Shellfish Waste - A Review. *Inc J Biomed Mater Res.* 2002; 63: 373-381. DOI: 10.1002/jbm.10231
57. Risbud M, Hardikar A, Bhonde R. Growth modulation of fibroblasts by chitosan-polyvinyl pyrrolidone hydrogel: Implications for wound management?. *J Biosci.* 2000; 25: 25-31. DOI: 10.1007/BF02985178
58. Wedmore I, McManus J G, Pusateri A E, Holcomb J B. A Special Report on the Chitosan-based Hemostatic Dressing: Experience in Current Combat Operations. *J Trauma.* 2006; 60: 655-658. DOI: 10.1097/01.ta.0000199392.91772.44
59. Zhou J, Elson C, Lee T D. Reduction in postoperative adhesion formation and re-formation after an abdominal operation with the use of N, O-carboxymethyl chitosan. *Surgery.* 2004; 135: 307-312. DOI: 10.1016/j.surg.2003.07.005
60. Humphreys M R, Castle E P, Andrews P E, Gettmann M T, Ereth M H. Microporous polysaccharide hemispheres for management of laparoscopic trocar injuries to the spleen. *Am J Surg.* 2008; 195: 99-103. DOI: 10.1016/j.amjsurg.2007.03.006
61. McIntosh D, Cowin A, Adams D, Wormald P J. The effect of an expandable polyvinyl acetate (Merocel) pack on the healing of the nasal mucosa of sheep. *Am J Rhinol.* 2005; 19: 577-581.
62. Weber R, Hay U. Ist die Nasentamponade noch zeitgemäß?. *Laryngo-Rhino-Otol.* 2003; 82: 650-654. DOI: 10.1055/s-2003-42685
63. Muluk N B, Oguztürk O, Ekici A, Koç C. Emotional effects of nasal packing measured by the Hospital Anxiety and Depression Scale in patients following nasal surgery. *J Otolaryngol.* 2005; 34: 172-177. DOI: 10.2310/7070.2005.04009
64. Klinger M, Siegert R. Untersuchungen zur Mikrozirkulation der Nasenschleimhaut bei Verwendung von Ballontamponaden. *Laryngo-Rhino-Otol.* 1997; 76: 127-130. DOI: 10.1055/s-2007-997400
65. Shaw C L, Dymock R B, Cowin A, Wormald P J. Effect of packing on nasal mucosa of sheep. *J Laryngol Otol.* 2000; 114: 506-509. DOI: 10.1258/0022215001906246
66. Jacob A, Faddis B T, Chole R A. Merogel hyaluronic acid sinonasal implants: osteogenic implications. *Laryngoscope.* 2002; 112: 37-42. DOI: 10.1097/00005537-200201000-00007
67. Hashmi S M, Gopaul S R, Prinsley P R, Sansom J R. Swallowed nasal pack: a rare but serious complication of the management of epistaxis. *J Laryngol Otol.* 2004; 118: 372-373. DOI: 10.1258/002221504323086589
68. Patterson D L, Yunginger J W, Dunn W F, Jones R T, Hunt L W. Anaphylaxis induced by the carboxymethylcellulose component of injectable triamcinolone acetonide suspension (Kenalog). *Ann Allerg Asthma Immunol.* 1995; 74: 163-166.
69. Muroi N, Mori S, Ono S, Takahashi H K, Fujii T, Hosoi S, Hemmi K, Nishibori M. Allergy to carboxymethylcellulose. *Allergy.* 2002; 57: 1212-1213. DOI: 10.1034/j.1398-9995.2002.23893\_4.x
70. Dowley A C, Strachan D R. Allergy to Merocel nasal packs causing septal perforation and inferior turbinate necrosis. *J Laryngol Otol.* 2001; 115: 735. DOI: 10.1258/0022215011908784
71. Derkay CS, Hirsch B E, Johnson J T, Wagner R L. Posterior Nasal Packing - Are Intravenous Antibiotics Really Necessary?. *Arch Otolaryngol Head Neck Surg.* 1989; 115: 439-441.
72. Herzon A S. Bacteremia and local infections with nasal packing. *Arch Otolaryngol Head Neck Surg.* 1971; 94: 317-320.
73. Hirsch B E. Antibiotic use with nasal packing. In: Johnson JT, Hrg. *Antibiotic therapy in head and neck surgery.* New York: Marcel Dekker; 1987. pp. 113-123.
74. Weber R, Keerl R, Draf W, Wienke A, Kind M. Zur Begutachtung: Periorbitales Paraffin granulom nach Nasennebenhöhlenoperation. *Otorhinolaryngologia Nova.* 1995; 5: 87-90. DOI: 10.1159/000313185
75. Sindwani R, Cohen J T, Pilch B Z, Metson R B. Myospherulosis following sinus surgery: pathological curiosity or important clinical entity?. *Laryngoscope.* 2003; 113: 1123-1127. DOI: 10.1097/00005537-200307000-00005

76. Gotwald T F, Sprinzi G M, Fischer H, Rettenbacher T. Retained packing gauze in the ethmoidal sinuses after endonasal sinus surgery: CT and surgical appearances. *AJR*. 2001; 177: 1487-1489.
77. Kim M G, Baek R M, Minn K W, Heo C Y, Kwon S S, Park C Y. Nasal packs with X-ray indicators. *Ann Plast Surg*. 2006; 56: 342-343. DOI: 10.1097/01.sap.0000196947.58929.51
78. Rajapaksa S P, McIntosh D, Cowin A, Wormald P J. The effect of insulin-like growth factor 1 incorporated into a hyaluronic acid-based nasal pack on nasal mucosal healing in a healthy sheep model and a sheep model of chronic sinusitis. *Am J Rhinol*. 2005; 19: 251-256.
79. Robinson S, Adams D, Wormald P J. The effect of nasal packing and prednisolone on mucosal healing and reciliation in a sheep model. *Rhinology*. 2004; 42: 68-72.
80. Stammberger H. Role of CMC (Rapidrhino(r)) as a postoperative coating and drug delivery system in patients with polyposis - preliminary results. 3. Conference of Nasal and Polyposis 23. - 25. 4. 2004 in Brussel.
81. Skilbeck C J, Oakley R. The fist model for nasal packing. *Eur J Emerg Med*. 2006; 13: 97-98. DOI: 10.1097/01.mej.0000192050.42847.79
82. Sugarman P M, Alderson D J. Training model for nasal packing. *J Accid Emerg Med*. 1995; 12: 276-278.
83. Thomas S, Pringle M. The use of airway mannequins to improve the teaching of nasal packing. *Clin Otolaryngol*. 2006; 31: 563-564. DOI: 10.1111/j.1365-2273.2006.01328.x
84. Evans A S, Young D, Adamson R. Is the nasal tampon a suitable treatment for epistaxis in Accident & Emergency? A comparison of outcomes for ENT and A&E packed patients. *J Laryngol Otol*. 2004; 118: 12-14.
85. Shikani A H. A new middle meatal antrostomy stent for functional endoscopic surgery. *Laryngoscope*. 1994; 104: 638-640. DOI: 10.1002/lary.5541040520
86. Weber R, Keerl R, Draff W. Endonasale endoskopische Chirurgie von Kieferhöhlenmukozelen nach Caldwell-Luc-Operation. *Laryngo-Rhino-Otol*. 2000; 79: 532-535. DOI: 10.1055/s-2000-6942
87. Hosemann W, Schindler E, Wiegrebe E, Göpferich A. Innovative frontal sinus stent acting as a local drug - releasing system. *Eur Arch Otorhinolaryngol*. 2003; 62: 131-134.
88. Herrmann B W, Citardi M J, Vogler G, Gardner L, Smith G, Javer A R, Burt H M, Jackson J, Kuhn F A. A preliminary report on the effects of paclitaxel-impregnated stents on sheep nasal mucosa. *Am J Rhinol*. 2004; 18: 119-124.
89. Neel H B, Whicker J H, Lake C F. Thin rubber sheeting in frontal sinus surgery: animal and clinical studies. *Laryngoscope*. 1976; 86: 524-536. DOI: 10.1288/00005537-197604000-00008
90. Schaller H. Zur Pathogenese und Therapie der Muco-Pyocoele. *HNO*. 1976; 24: 448-451.
91. Yamasoba T, Kikuchi S, Higo R. Transient positioning of a silicone T tube in frontal sinus surgery. *Otolaryngol Head Neck Surg*. 1994; 111: 776-780. DOI: 10.1016/S0194-5998(94)70567-4
92. Rains 3rd B M. Frontal sinus stenting. *Otolaryngol Clin North Am*. 2001; 34: 101-110. DOI: 10.1016/S0030-6665(05)70298-X
93. Lin D, Witterick I J. Frontal sinus stents: how long can they be kept in?. *J Otolaryngol*. 2008; 37: 119-123.
94. Weber R K. Die endonasale Chirurgie der Stirnhöhle. Teil 1: Stirnhöhlendrainagen Typ I und II. *HNO*. 2009; 57: 739-50.
95. Weber R K. Die endonasale Chirurgie der Stirnhöhle. Teil 2: Stirnhöhlendrainage Typ III. Tipps und Tricks, Nachbehandlung. *HNO*. 2009; 57: 751-62.
96. Boenisch M, Nolst Trenité GJ. Fibrin glue for operative correction of septal deviations. *HNO*. 2004; 52: 963-967.

#### Corresponding author:

Prof. Dr. med. Rainer K. Weber  
Sektion Nasennebenhöhlen- und Schädelbasischirurgie,  
Traumatologie, HNO-Klinik, Städtisches Klinikum  
Karlsruhe, Moltkestr. 90, 76133 Karlsruhe, Germany,  
Phone: +49(0)721 9742516  
rainer.weber@klinikum-karlsruhe.de

#### Please cite as

Weber RK. Nasal packing and stenting. *GMS Curr Top Otorhinolaryngol Head Neck Surg*. 2009;8:Doc02.  
DOI: 10.3205/cto000054, URN: urn:nbn:de:0183-cto0000548

#### This article is freely available from

<http://www.egms.de/en/journals/cto/2011-8/cto000054.shtml>

**Published:** 2011-03-10

#### Copyright

©2011 Weber. This is an Open Access article distributed under the terms of the Creative Commons Attribution License (<http://creativecommons.org/licenses/by-nc-nd/3.0/deed.en>). You are free: to Share – to copy, distribute and transmit the work, provided the original author and source are credited.