

# Duodenal diverticulum with retroperitoneal perforation

Simon Bergman, MD;\* D. Jim Koumanis, MD;\* Lawrence A. Stein, MD;† Jeffrey S. Barkun, MD;\* Steven Paraskevas, MD, PhD\*

Duodenal diverticulum is a common condition, but the rare complication of perforation carries a high mortality, requiring early detection and treatment. We describe a case of a patient with a perforated diverticulum to illustrate the radiologic diagnosis and management.

## Case report

A 62-year-old woman had a 12-hour history of acute-onset epigastric and right upper quadrant pain with radiation to the back. She was febrile, had a diffusely tender abdomen with no peritoneal signs and a leukocytosis of  $14.0 \times 10^9/L$ . An abdominal series did not show evidence of free air. CT of the abdomen revealed peri-

pancreatic fat stranding and retroperitoneal gas bubbles at the third and fourth stages of the duodenum (Fig. 1). Ruptured diverticulum of the distal duodenum was diagnosed.

At operation, the duodenum was Kocherized. Bile-stained fluid was found around a large, friable, perforated duodenal diverticulum, the neck of which was immediately distal to the ampulla of Vater, extending posteromedially behind the head of the pancreas. A feeding catheter introduced via the ampulla of Vater through an anterolateral longitudinal duodenotomy. The diverticulum was inverted within the lumen of the duodenum and stapled off. The duodenotomy was closed in 2 layers and a closed-suction drain placed lateral to the duodenotomy. The patient's recovery was uncomplicated.

## Discussion

Duodenal diverticula are found in up to 22% of the population.<sup>1</sup> Of these, only 1%–2% of patients are symptomatic and require surgery. The rarest, most severe complication is perforation, which carries a death rate of up to 30%. Although the signs and symptoms of perforated duodenal diverticulitis are often nonspecific, and the radiologic findings subtle, a correct preoperative diagnosis is essential and may significantly lower this rate.<sup>2</sup> CT is the modality of choice. Findings consist of a thickened bowel wall, mesenteric fat stranding and an extraluminal collection of air or fluid, often retroperitoneal.<sup>3</sup> In 60% of cases, a duodenal diverticulum is identified in the juxtampillary position.

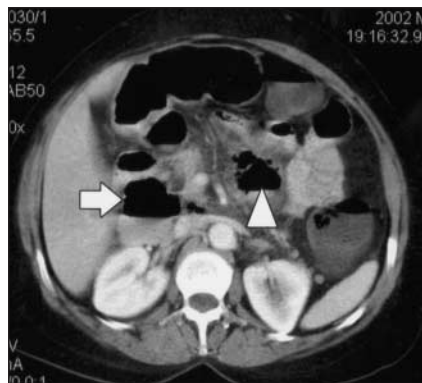
Because of the intimate relationship of the duodenum to adjacent structures, the most appropriate procedure may be a tube duodenostomy and feeding jejunostomy.<sup>4</sup> Despite reports such as this, and those advocating combined percutaneous and endoscopic management, or a laparoscopic approach, the treatment of choice for perforated duodenal diverticula remains transduodenal diverticulectomy and 2-layer closure.<sup>2</sup> Injury to the common bile duct and pancreatic duct is prevented by inserting a feeding tube into the ampulla of Vater before beginning dissection of the diverticulum. Other potential complications of this procedure are duodenal fistula, sepsis, intra-abdominal abscess and pancreatitis.

This case highlights the importance of early, correct radiologic diagnosis and the safety of diverticulectomy and 2-layer closure because of the high morbidity and mortality still associated with this condition.

**Competing interests:** None declared.

## References

1. Ackerman W. Diverticula and variations of the duodenum. *Ann Surg* 1943;117:403-13.
2. Duarte B, Nagy KK, Cintron J. Perforated duodenal diverticulum. *Br J Surg* 1992; 79:877-81.
3. Van Beers B, Trigaux JP, De Ronde T, Melange M. CT findings of perforated duodenal diverticulitis. *J Comput Assist Tomogr* 1989;13:528-30.
4. Scudamore CH, Harrison RC, White TT. Management of duodenal diverticula. *Can J Surg* 1982;25:311-4.



**Fig. 1.** CT suggests a diverticulum in the fourth stage of the duodenum (arrowhead) with surrounding fat stranding and a contained perforation. There also seems to be an uninfamed diverticulum in the second stage of the duodenum (arrow), which most likely represents the neck of a single large diverticulum.

From the Departments of \*Surgery and †Radiology, McGill University, Montréal, Que.

Accepted for publication Nov. 15, 2004.

**Correspondence to:** Dr. Steven Paraskevas, 687 Pine Ave. W, Rm. S10-30, Montréal QC H3A 1A1; [steven.paraskevas@muhc.mcgill.ca](mailto:steven.paraskevas@muhc.mcgill.ca)