

# Magnetic resonance–guided percutaneous cryosurgery of breast carcinoma: technique and early clinical results

Jacques Morin, MD; Amidou Traoré, PhD; Guy Dionne, MD; Marcel Dumont, MD; Bertrand Fouquette, MD; Marie Dufour, MD; Sonia Cloutier, MD; Christian Moisan, PhD

**Purpose:** This phase I study was designed to demonstrate the feasibility, safety, efficacy and predictability of percutaneous cryosurgery, guided under magnetic resonance (MR) imaging, in the treatment of invasive breast carcinoma. **Patients and methods:** Under the guidance of near–real-time T<sub>1</sub>-weighted FSE images of a 0.5-T open-configuration MR system, percutaneous cryosurgery was performed in 25 patients with operable invasive breast carcinoma, 4 weeks prior to their scheduled mastectomy. Predictive assessments by interventional radiologists using 4 breast-imaging techniques (mammography, sonography, scintigraphy and MR) were correlated with postmastectomy results of histopathology and assessed for predictability. Local and systemic morbidity were also evaluated during the month of follow-up preceding mastectomy. **Results:** Percutaneous cryosurgery resulted in no serious complications, either local or systemic. All tumoural tissues included in the cryogenic “iceball” were destroyed, with no viable histologic residues. Ablation was total in 13 of the 25 tumours treated. Combining periprocedural MR images with postprocedure scintimammographic findings enabled a 96% rate for predicting the cryosurgical results. **Conclusions:** MR-guided cryosurgery of breast carcinoma is feasible, safe and efficient, with predictable results. Major drawbacks are that the cryolesion (a palpable iceball) persists for a month or more after the procedure, undermining the reliability of the physical examination; and that breast imaging (mammography, ultrasound and MR) presents the same difficulty of interpretation as the physical exam even 1 month after the procedure. More studies are required to refine this treatment method.

**Objet :** Cette étude de phase I devait démontrer la faisabilité, la sécurité, l’efficacité et la prévisibilité de la cryochirurgie percutanée guidée par imagerie à résonance magnétique (RM) dans le traitement du cancer du sein envahissant. **Patientes et méthodes :** En se guidant sur des séquences d’écho de spin rapide en pondération T<sub>1</sub> et en temps quasi réel d’un système RM à configuration ouverte de 0,5-T, on a procédé à une cryochirurgie percutanée chez 25 patientes qui avaient un cancer du sein envahissant opérable, quatre semaines avant la mastectomie prévue. On a établi un lien entre les évaluations prédictives de radiologistes d’intervention qui ont utilisé quatre techniques d’imagerie du sein (mammographie, échographie, scintigraphie et RM) et les résultats d’histologie après la mastectomie et on en a évalué la prévisibilité. On a aussi évalué la morbidité locale et systémique au cours du mois de suivi qui a précédé la mastectomie. **Résultats :** La cryochirurgie percutanée n’a causé aucune complication grave, locale ou systémique. Tous les tissus de la tumeur inclus dans la «masse de glace» cryogénique ont été détruits et n’ont laissé aucun résidu histologique viable. L’ablation a été totale dans 13 des 25 tumeurs traitées. La combinaison d’images RM périopercutées et des résultats de scintimammographies après l’intervention ont permis de prédire les résultats de la cryochirurgie à 96 %. **Conclusions :** La cryochirurgie guidée par RM d’un cancer du sein est faisable, sûre et efficace, et donne des résultats prévisibles. Les principaux inconvénients sont le fait que la cryolésion (masse de glace palpable) persiste pendant un mois ou plus après l’intervention, ce qui mine la fiabilité de l’examen physique, et le fait que l’imagerie du sein (mammographie, échographie et RM) présente la même difficulté d’interprétation que l’examen physique même un mois après l’intervention. D’autres études s’imposent pour raffiner cette méthode de traitement.

iMRI unit, Quebec City University Hospital, Quebec City, Que.

Accepted for publication Mar. 5, 2004

**Correspondence to:** Dr. Christian Moisan, iMRI Unit, CHUQ–Hôpital St-François d’Assise, Bureau/suite A0-212d, 10, rue de L’Espinay, Québec QC G1L 3L5; fax 418 525-4411; christian.moisan@rad.ulaval.ca

Cryosurgery is a procedure in which *in vivo* tissue ablation is achieved through freezing with bio-compatible cryogenic probes. This therapeutic approach has been used for almost 150 years in many anatomical sites,<sup>1</sup> particularly to treat nonresectable liver metastasis.

*In situ* cryosurgery has been shown in animals to be useful in treating breast cancer.<sup>2</sup> Not only is it minimally invasive, but local tumour necrosis in cryosurgery has potential to induce a cytoimmune reaction against surviving or recurrent neoplastic cells.<sup>3-5</sup> Thus far, however, successful clinical trials in women have been limited to a study by Staren and colleagues.<sup>2</sup>

When breast tumours are treated cryosurgically, monitoring is of practical concern. During these cryosurgical procedures, "iceball" growth is routinely monitored by ultrasound (US). The main drawback of this imaging modality is total US reflection at the ice interface; no structure can be seen beyond the edge of the iceball because of this acoustic shadow,<sup>6</sup> so that the iceball's exact dimensions remain unknown.

MRI offers several advantages that make it suitable for guidance and monitoring in cryosurgical procedures. It has high spatial and time resolution and (unlike US) is sensitive to temperature, providing good contrast between frozen and unfrozen tissues. This allows accurate delineation of the whole circumference of the growing iceball.<sup>7</sup> Furthermore, along with the availability of open-configuration MRI systems (Fig. 1), the development of new pulse sequences and magnetic resonance (MR)-compatible treatment devices have led to a breakthrough in the use of MRI in the guidance of minimally invasive therapies, particularly in cancer cryotherapy.<sup>8,9</sup>

Before percutaneous cryosurgery of breast tumours under near-real-time MRI guidance can be safely offered to patients as a therapeutic option, it is essential to demonstrate not

only the safety and effectiveness of the thermal treatment, but also the predictability of MR monitoring, to ensure that the monitored cryolesion accurately reflects the extent of tumour necrosis.

## Patients and methods

### Patient population

To ensure that local complications would not convert a possible partial mastectomy into a total mastectomy, 25 women were selected over a period of 2 years from a pool of almost 300 new cases of trocar-proven invasive breast cancer. Most of them (21) needed a total mastectomy for various reasons. For example, one patient had a new cancer in a breast already treated by partial mastectomy and radiotherapy; others had multicentric tumours or an invasive tumour with extensive *in situ* carcinoma. Our goal in these patients was not to eradicate all neoplastic tissues but to destroy the "dominant" invasive tumour. The MR-guided percutaneous breast cryosurgery was approved by our institute's review board. An informed-consent form approved by our ethics committee was signed by all patients.

### Methods

Before beginning this *in vivo* procedure study, we did check that the radiologic iceball corresponded to the pathologic iceball by an *ex vivo* study

of 15 breast-cancer specimens obtained by partial or total mastectomy. All iceballs were found to be of the same size to within a millimetre.

Four types of breast imaging were used on all patients: mammography, ultrasound, scintigraphy and MR. (For scintimammography we used the Mibi-Tc<sup>99m</sup> Miraluma, Dupont-Pharma Radiopharmaceuticals, North Billerica, Mass.) These exams were carried out before the cryoprocure and repeated 1 month later, before definitive surgery. Additional criteria for inclusion in the study were negative results from chest x-ray, abdominal US and bone scan. To avoid cryo-injury, the target lesion had to be at least 1 cm away from the skin and chest wall.

Percutaneous cryosurgery procedures were guided in the near-real-time imaging mode of a 0.5-T open-configuration Signa-SP MRI system (General Electric Medical Systems, Milwaukee, Wis.). A standard flexible linear surface square coil (LOOPI) placed directly over the treated breast (Fig. 2) served as a radiofrequency transmitter and receiver. The MR protocol used slices 5 mm thick, an FOV of 24 × 18 cm<sup>2</sup> and a matrix of 256 × 128. A  $T_1$ -weighted fast spin-echo sequence was used with a repetition time:effective echo time ratio ( $TR/TE_{eff}$ ) of 350/17 ms and an echo train length of 4, leading to a refresh rate of 9 s/image. One procedure was performed upon each lesion, to a total of 25.

Freezing was done with a cryotherapy delivery system (CryoHit, Galil Medical Ltd., Yokneam, Israël)



FIG. 1. Open-configuration MRI system (Signa-SP, General Electric Medical Systems, Milwaukee, Wis.).




FIG. 2. Breast magnetic resonance (MR) antenna.

with high-pressure cooling argon converted to a low-pressure liquid by means of the Joule–Thompson effect (Fig. 3).

During the cryosurgery protocol itself, a lethal thermal stress was imposed on the tumour cells until the resulting radiologic iceball completely encompassed the “dominant” tumour. A systematic attempt was made to “overfreeze” each tumour to ensure an oncologic security margin of 1 cm.

Typically, cryogenic probes delivered 2 or 3 freezing cycles of up to 15 minutes each at a target temperature of  $-180^{\circ}\text{C}$ . Freezing cycles alternated with 15-minute periods of passive thawing with the cryogenic probes turned off.

Cryosurgery was done with the patients under local anesthesia and intravenous narcosis. The first 10 patients were observed in the hospital for 24 hours afterward; subsequent procedures were performed on an outpatient basis.

Each procedure began with insertion of a cryoprobe into the targeted lesion. For the first 6 patients, the only probes available were 6 mm in diameter, which failed to adequately penetrate the tumour. Therefore, beginning with the seventh patient (for whom 3-mm probes became available), the procedure first involved transfixing the breast completely through the long axis of the target tumour under US guidance with an 18-gauge puncture needle. Then a 0.35-mm Amplatz guidewire (Boston Scientific Corp., Watertown,

Mass.) was inserted to pierce the breast tumour entirely. This permitted placement of a 9F introducer (Terumo Medical Corp., Elkton, Md.) at either end of the guidewire. The distal ends of the introducers were brought into contact at the centre of the tumour to allow for the placement of 1 or 2 MR-compatible cryogenic probes 3 mm in diameter (Galil Medical Ltd.) in a head-on configuration at the heart of the lesion (Fig. 4).

Each procedure typically took 3 hours, followed by at least 2 hours of recovery. The interventionist’s periprocedural assessment of the result was recorded immediately for future comparison.

During the 1-month recovery period, patients were followed weekly with blood tests, a physical examination and an appropriate questionnaire (given by interview). The 4 types of

breast imaging used before the cryo-procedure were repeated before mastectomy to evaluate any changes induced by cryosurgery.

**Surgery and pathology**

Twenty-one patients underwent total mastectomy and 4, partial mastectomy. All had axillary nodes excised. No particular complications were noted in the postoperative period.

Immediately after surgery, each surgical specimen was analyzed histopathologically to assess the final ablative effect of the cryoprocedure. After a macroscopic exam, a complete cephalocaudal section centred on the tumour was performed. The 2 pieces were analyzed and the dimensions of the cryolesion recorded, along with its position relative to the skin and nipple. Tissue slices were then cut parallel to the long axis of the speci-



FIG. 4. Left, introducers inserted into the breast just before cryoprobe insertion. Right, a near-real-time image to guide cryoprobe placement.

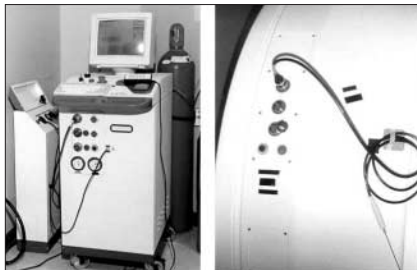


FIG. 3. Cryotherapy delivery system (CryoHit, Galil Medical Ltd., Yokneam, Israel).

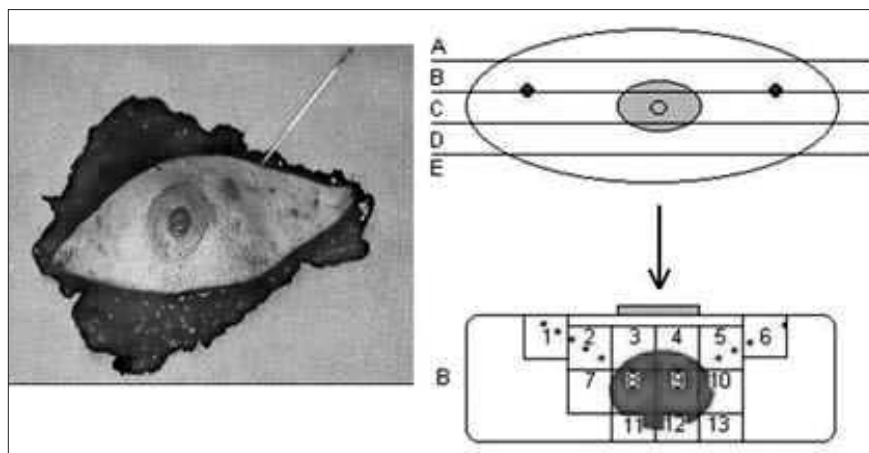


FIG. 5. Schematic for preparation of surgical specimens.

men. Histological cross-sections of the slices containing the trajectory of the probes (Fig. 5) were specifically studied to detect possible tumour-seeding during the insertion of the devices.

## Results

MR-guided percutaneous cryosurgery was well tolerated by all patients. Some reported a local sensitivity in the immediate recovery period. All

patients were discharged within 24 hours. The weekly blood tests revealed no significant changes. During the 1 month of follow-up, the most frequent complaint was a sensation of heaviness in the breast treated. Physical signs noted locally were a minimal skin burn at the entry points of the probes and signs of a traumatic mastitis that persisted until the mastectomy. No abscess formation was observed, even though no antibiotic prophylaxis was given.

Table 1 summarizes the results obtained. Importantly, no viable tumour cells were found in any of the pathologic iceballs. Pathologic tumour ablation was technically total in 13 of the 25 tumours treated. Of the 12 failures, 10 were declared for various reasons by the interventionist during the procedure. In the remaining 2 failures (cases 20 and 23) the interventionist overestimated his result, whereas scintimammography was positive for residual tumour. Only in case 13 did the interventionist underestimate his result (scintigraphy predicted the total ablation actually obtained). Only in case 22 was scintigraphy unpredictable, showing a negative result when residual tumour in fact remained.

Combining the interventionist's periprocedural assessment and pre-surgical scintimammography findings enabled the correct prediction of 96% of the histopathological results.

## Conclusions

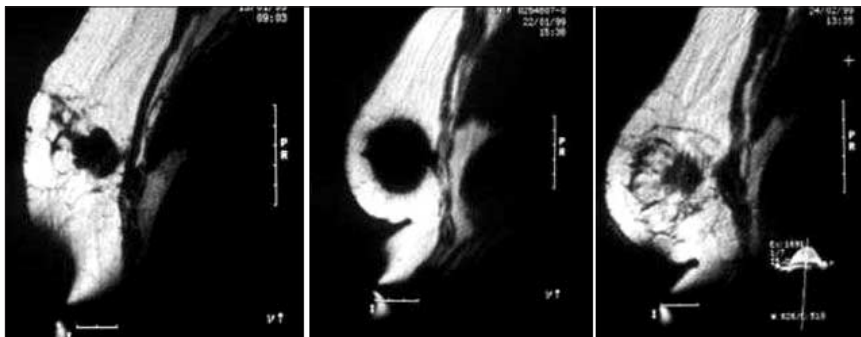
Percutaneous MR-guided cryosurgery of breast cancer has minimal morbidity. MR imaging seems very adequate to delineate tumour versus iceball (Fig. 6). Scintimammography seemed to be the simplest means of predicting results: images showing only a residual halo (Fig. 7) seem to predict total ablation.<sup>10,11</sup> The cryoprocure's major drawback is that the clinically palpable iceball persists for a month or more, undermining the reliability of the physical examination.

**Table 1**

### Summary of results

Pt no.	Age, yr	Maximum diameter, cm		1 or 2 probes	Type of mastectomy	Residual tumour		
		Tumour	Iceball			Predicted by		Histologic presence
						IR	Sc	
1	52	2.2	2.8	1	Total	+	+	+
2	69	3.5	2.4	1	Total	+	+	+
3	75	3.2	2.8	1	Total	+	+	+
4	41	4.0	3.4	1	Total	+	+	+
5	77	4.0	4.3	1	Total	+	+	+
6	43	3.8	2.8	1	Total	+	+	+
7	67	2.0	5.3	2	Total	—	—	—
8	54	3.8	5.8	2	Total	—	—	—
9	72	2.6	5.8	2	Total	—	—	—
10	48	2.0	4.5	2	Total	—	—	—
11	68	3.5	7.0	2	Total	—	—	—
12	68	3.2	4.2	1	Partial	—	—	—
13	73	3.5	4.2	1	Total	+	—	—
14	70	6.0	3.4	2	Total	+	+	+
15	57	3.5	5.9	2	Total	—	—	—
16	50	2.7	2.2	2	Partial	—	—	—
17	76	2.8	3.1	2	Total	—	—	—
18	48	1.8	4.4	2	Total	—	—	—
19	53	2.6	4.2	1	Partial	—	—	—
20	57	2.2	3.4	1	Total	—	+	+
21	74	2.1	3.2	2	Partial	+	+	+
22	59	2.5	3.1	2	Total	+	—	+
23	60	2.2	2.5	2	Total	—	+	+
24	41	1.2	3.0	2	Total	—	—	—
25	72	3.6	3.9	1	Total	+	+	+

+ = residual tumour; IR = interventional radiologist; Pt = patient; Sc = scintimammography



**FIG. 6.** Typical cryosurgical perioperative MR images. Left, the viable tumour before the cryoprocure. Middle, the growing "iceball" (not completed). Right, the residual iceball and dead tumour 1 month later (with a pre-existing traumatic lesion to the pectoral muscle behind).

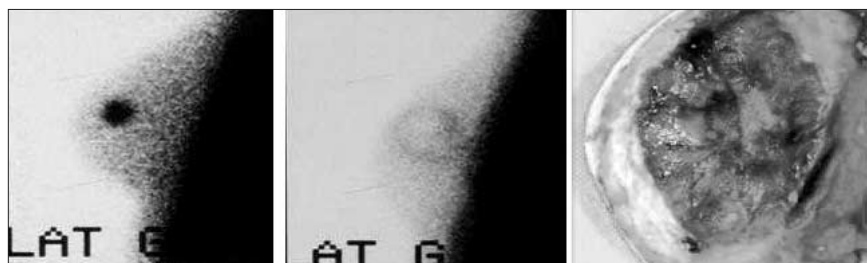

FIG. 7. Scintimammographic exam performed (left) 1 week prior to and (middle) 4 weeks after the cryosurgery, with (right) the corresponding pathologic sample.

The cryoprocure of 2 of our patients whose tumours were totally ablated had been synchronized with their trocar biopsy; they therefore had their definitive histologic diagnosis with local destruction of the tumour during about a 3-hour period under local anesthesia, as outpatients.

In conclusion, MRI-guided percutaneous cryosurgery was shown to be both feasible and safe. These results support this innovative technique as a promising, minimally invasive approach to the treatment of malignant breast lesions. Further clinical trials with long-term follow-up are warranted.

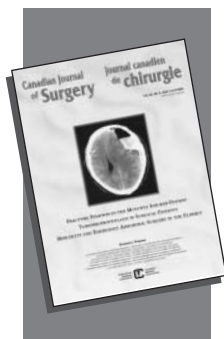Competing interests: None declared.

### References

1. Gage AA. Cryosurgery in the treatment of cancer. *Surg Gynecol Obstet* 1992;174:73-92.
2. Staren ED, Sabel MS, Gianakakis LM, Wiener GA, Hart VM, Gorski M, et al. Cryosurgery of breast cancer. *Arch Surg* 1997;132:28-33.
3. Neel HB 3rd. Immunotherapeutic effect of cryosurgical tumor necrosis. *Vet Clin North Am Small Anim Pract* 1980;10:763-9.
4. Neel HB 3rd, Ritts RE Jr. Immunotherapeutic effect of tumor necrosis after cryosurgery, electrocoagulation, and ligation. *J*

*Surg Oncol* 1979;11:45-52.

5. Tanaka S. Immunological aspects of cryosurgery in general surgery. *Cryobiology* 1982;19:247-62.
6. Rabin Y, Coleman R, Mordovich D, Ber R, Shitzer A. A new cryosurgical device for controlled freezing. *Cryobiology* 1996;33:93-105.
7. Baust J, Cage A, Ma H, Zhang CM. Minimally invasive cryosurgery—technological advances. *Cryobiology* 1997;34:373-84.
8. Matsumoto R, Selig AM, Colucci VM, Jolesz FA. MR monitoring during cryotherapy in the liver: predictability of histologic outcome. *J Magn Reson Imaging* 1993;3:770-6.
9. Silverman SG, Tuncali K, Adams DF, van-Sonnenberg E, Zou KH, Kacher DF, et al. MR imaging-guided percutaneous cryotherapy of liver tumors: initial experience. *Radiology* 2000;217:657-64.
10. Dumont M, Morin J, Marois M, Duchesne N, Dufour M, Dionne G, et al. Scintimammographic findings from short term follow up of breast cancer cryosurgery. *J Nucl Med* 1999;40:249.
11. Pérusse K, Dumont M, Morin J, Fouquet B, Marois M, Dionne G, et al. Diagnostic value of scintimammography in following up of MR-guided percutaneous cryosurgery of breast cancer. *J Nucl Med* 2001;42:292.



## Reprints

Bulk reprints of CJS articles are available in minimum quantities of 50

For information or orders:

Reprint Coordinator

tel 800 663-7336 x2110, fax 613 565-7704

janis.murrey@cma.ca

ASSOCIATION  
MÉDICALE  
CANADIENNE



CANADIAN  
MEDICAL  
ASSOCIATION