

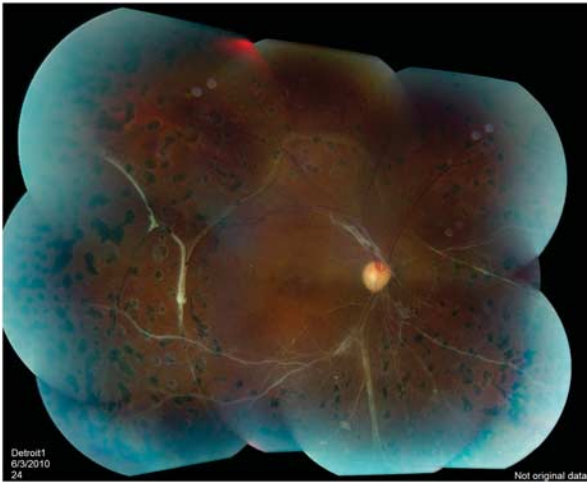

Figure 2 Right eye color photograph 4 months postvitrectomy. The retina is fully attached with islands of segmented preretinal fibrosis. Bands of subretinal fibrosis are seen temporal to the macula. Inferior macula and disk are ischemic and atrophic, as they were presurgically, with visual acuity of 6/18.

Comment

The present understanding of Hb C trait retinopathy is that it is extremely rare and, like Hb S trait retinopathy, only occurs with comorbidities.⁴ We theorize that the increased blood viscosity (due to Hb AC), and the narrowed vessels (due to hypertension), acted synergistically to cause occlusive microangiopathy, which lead to proliferative neovascularization. Our case demonstrates how two non-neovasculogenic diseases, if coexisting, can cause sight-threatening retinopathy.

Because the preretinal fibrosis leaked fluorescein (Figures 1c and d), we used preoperative IVB to decrease bleeding when cutting these fibrovascular membranes. The right eye VA did not improve beyond 6/18 after surgery because of preexisting disease-related ischemic maculopathy. As reported by others,⁵ we did not see IVB-related complications, such as worsening of the traction retinal detachment and macular ischemia.

Conflict of interest

The authors declare no conflict of interest.

Acknowledgements

Russell Pokroy received fellowship grants from the American Physicians Fellowship for Medicine in Israel, and from the Israel Ophthalmic Society.

References

- 1 Welch RB, Goldberg MF. Sickle-cell hemoglobin and its relation to fundus abnormality. *Arch Ophthalmol* 1996; **75**: 353–362.
- 2 Hingorani M, Bentley CR, Jackson H, Betancourt F, Arya R, Aclimandos WA *et al*. Retinopathy in haemoglobin C trait. *Eye (Lond)* 1996; **10**: 338–342.
- 3 Jampol LM, Green Jr JL, Goldberg MF, Peyman GA. An update on vitrectomy surgery and retinal detachment repair in sickle cell disease. *Arch Ophthalmol* 1982; **100**: 591–593.
- 4 Reynolds SA, Besada E, Winter-Corella C. Retinopathy in patients with sickle cell trait. (published erratum appears in *Optometry* 2008; **79**: 2) *Optometry* 2007; **78**: 582–587.
- 5 Siqueira RC, Costa RA, Scott IU, Cintra LP, Jorge R. Intravitreal bevacizumab (Avastin) injection associated with regression of retinal neovascularization caused by sickle cell retinopathy. *Acta Ophthalmol Scand* 2006; **84**: 834–835.

R Pokroy and UR Desai

Department of Ophthalmology, Henry Ford Hospital,
Detroit, MI, USA
E-mail: pokroy@yahoo.com

Eye (2011) **25**, 1514–1515; doi:10.1038/eye.2011.189;
published online 5 August 2011

Sir, Nerve fiber layer irregularity after internal limiting membrane peeling, seen by spectral domain optical coherence tomography

Tadayoni *et al*¹ reported that the retina acquired a particular appearance, featuring ‘arcuate striae’, after pars plana vitrectomy (PPV) for treatment of a macular hole. They considered that the feature was attributable to the presence of a dissociated optic nerve fiber layer (DONFL). Ito *et al*² found that a DONFL resulted in the development of numerous arcuate retinal striae mimicking a retinal nerve fiber layer (RNFL) defect. Earlier conventional time-domain (TD) OCT showed only focal dimples on two-dimensional imaging.

We performed a PPV with internal limiting membrane (ILM) peeling to treat macular hole. No frank retinal trauma was observed during PPV or the ILM peeling procedure. Preoperative fundus photograph showed no RNFL defect (Figure 1). On 12-months postoperative review, multiple dark round lesions were detected in the superior-temporal perimacular area. We performed high-resolution spectral-domain (SD) OCT with three-dimensional imaging (Cirrus OCT, Carl Zeiss Meditec, Inc., Dublin, CA, USA). SD OCT showed deep focal dimples, with clear margins, in the perimacular area, compatible with the presence of a DONFL. Three-dimensional SD OCT images, which reveal the inner retinal surface, confirmed the presence of multiple round, cobblestone-shaped, ‘beaten bronze’ dimples in the superior temporal perimacular area. DONFL did not present as the arcuate striae described in many previous reports.^{2–4} Many reports have described RNFL morphological changes after ILM peeling during vitrectomy with TD OCT.^{1–4} Removal of the ILM is a common procedure in macular hole surgery, as it increases the probability that the macular hole will close. In our case, we used SD OCT, which provides images of greater clarity and higher resolution than afforded by TD OCT. SD OCT clearly revealed the dimple margins and the exact depth of each DONFL. The shape and size of a DONFL could be visualized using the new three-dimensional SD OCT imaging facility. Our patient had

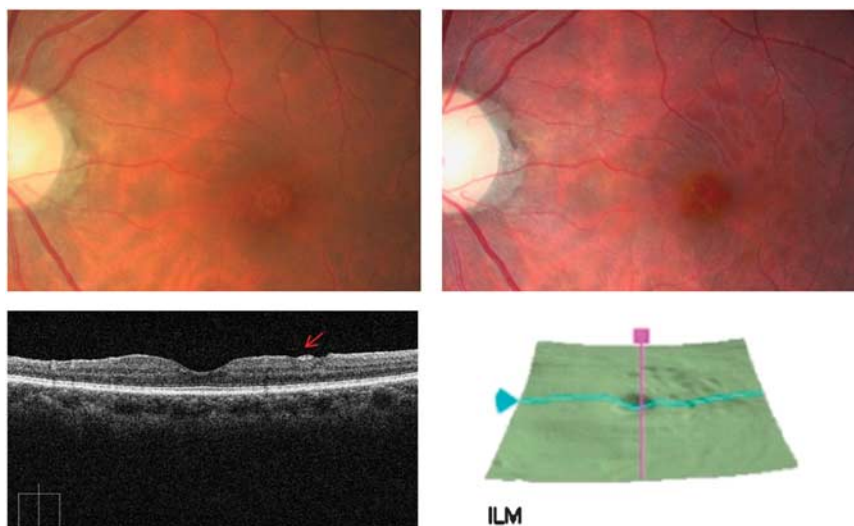


Figure 1 Upper left: preoperative fundus photography. No retinal nerve fiber layer defect in the perimacular area. Upper right: 12-months follow-up images after vitrectomy. Multiple dark round lesions in the superior temporal perimacular area. Lower left: well-demarcated DONFL (arrow) margin on OCT (vertical axis). Lower right: three-dimensional OCT mapping shows multiple round DONFLs, with a 'beaten bronze' cobblestone-like appearance, in the superior temporal perimacular area.

DONFLs with a 'beaten bronze' cobblestone-like appearance. DONFLs can, thus, present in various forms, including the cobblestones of our patients and the arcuate striae described in many reports.

Conflict of interest

The authors declare no conflict of interest.

References

- 1 Tadayoni R, Paques M, Massin P, Mouki-Benani S, Mikol K, Gaudric A. Dissociated optic nerve fiber layer appearance of the fundus after idiopathic epiretinal membrane removal. *Ophthalmology* 2001; **108**: 2279–2283.
- 2 Ito Y, Terasaki H, Takahashi A, Yamakoshi T, Kondo M, Nakamura M. Dissociated optic nerve fiber layer appearance after internal limiting membrane peeling for idiopathic macular holes. *Ophthalmology* 2005; **112**: 1415–1420.
- 3 Mitamura Y, Ohtsuka K. Relationship of dissociated optic nerve fiber layer appearance to internal limiting membrane peeling. *Ophthalmology* 2005; **112**: 1766–1770.
- 4 Mitamura Y, Suzuki T, Kinoshita T, Miyano N, Tashimo A, Ohtsuka K. Optical coherence tomographic findings of dissociated optic nerve fiber layer appearance. *Am J Ophthalmol* 2004; **137**: 1155–1156.

JB Chae¹, DK Choi¹ and J-G Kim²

¹Department of Ophthalmology, Chungbuk National University, College of Medicine, Cheongju, Korea

²Department of Ophthalmology, University of Ulsan, College of Medicine, Asan Medical Center, Seoul, Korea
E-mail: dropkim@dreamwiz.com

Eye (2011) **25**, 1515–1516; doi:10.1038/eye.2011.191; published online 19 August 2011

Sir,
Bevacizumab (Avastin) in central retinal vein occlusion

I read the article by Shah and Shah¹ with great interest. I congratulate the authors for evaluating the effects of early single intravitreal injection of bevacizumab followed by panretinal and macular grid photocoagulation laser in central retinal vein occlusion (CRVO) with macular oedema.

I would like to share my experience of single early intravitreal injection of bevacizumab in two cases of macular oedema secondary to central retinal vein occlusion. Both patients had only a single intravitreal injection of bevacizumab within a week of onset of symptoms, without the need for panretinal photocoagulation or macular grid lasers.

Case reports

Case 1

A 23-year old male presented with left eye CRVO and macular oedema and a visual acuity (VA) of 6/24. He received a single intravitreal injection of Avastin at 6 days after the onset of symptoms. He was seen 11 days later with VA of 6/6 and OCT showing resolution of macular oedema. Seventeen months later, his left VA remains 6/4.8 (unaided) and no macular oedema on OCT. He did not need any further intervention after the first injection.

Case 2

A 79-year old male presented with left CRVO with macular oedema and a VA of 2/60. He had neovascular glaucoma in the other eye secondary to CRVO. When seen 3 days after the onset of his symptoms in the left eye, he underwent an intravitreal injection of Avastin the same day. VA returned to 6/9 in 2 weeks. Twenty one months later, he still maintains a VA of 6/9 unaided and has no macular oedema on OCT.