

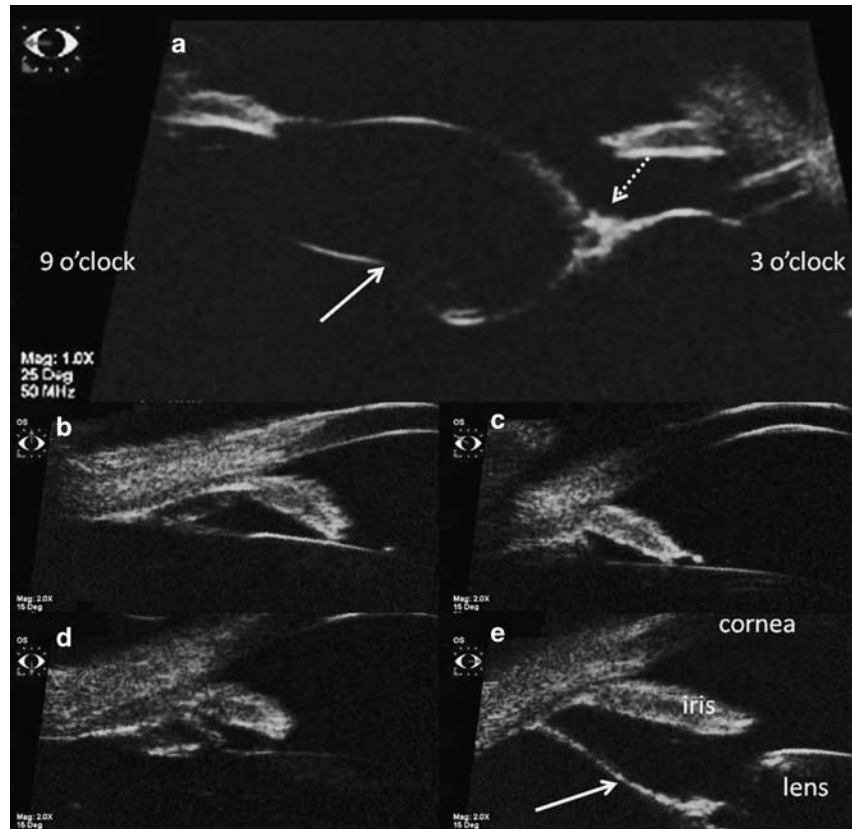

Figure 2 (a) Sulcus-to-sulcus scan of the left eye using ultrasound biomicroscopy (UBM) in the horizontal meridian, showing the extent of the brown lesion, which extended from the ciliary body region at 3 o'clock to the back of the lens with posterior bowing. Its nasal extent was denoted by a solid arrow, and the temporal edge of the lens by the dotted arrow. UBM of the left eye, showing normal configuration at superior (b), nasal (c), and inferior (d) aspects. The temporal (e) region showed a flat sheet-like structure (arrow) extending from the ciliary body region to the posterior aspect of the lens.

Conflict of interest

The authors declare no conflict of interest.

References

- 1 Goldberg MF. Persistent fetal vasculature (PFV): an integrated interpretation of signs and symptoms associated with persistent hyperplastic primary vitreous (PHPV). LIV Edward Jackson Memorial Lecture. *Am J Ophthalmol* 1997; **124**: 587–626.
- 2 Shields JA, Eagle Jr RC, Shields CL, Potter PD. Congenital neoplasms of the nonpigmented ciliary epithelium (medulloepithelioma). *Ophthalmology* 1996; **103**: 1998–2006.
- 3 Kilty LA, Hiles DA. Unilateral posterior lenticonus with persistent hyaloid artery remnants. *Am J Ophthalmol* 1993; **116**: 104–106.
- 4 Cheung JC, Summers CG, Young TL. Myopia predicts better outcome in persistent hyperplastic primary vitreous. *J Pediatr Ophthalmol Strabismus* 1997; **34**: 170–176.
- 5 Müllner-Eidenböck A, Amon M, Hauff W, Klebermass N, Abela C, Moser E. Surgery in unilateral congenital cataract caused by persistent fetal vasculature or minimal fetal vascular remnants: age-related findings and management challenges. *J Cataract Refract Surg* 2004; **30**: 611–619.

KR Darusman¹, MCD Aquino¹, TP Thamboo^{2,3} and IB Wong^{1,3}

¹Department of Ophthalmology, National University Hospital, Singapore

²Department of Pathology, National University Hospital, Singapore

³Yong Loo Lin School of Medicine, National University Singapore, Singapore

E-mail: inez_by_wong@nuhs.edu.sg

Eye (2011) **25**, 1521–1522; doi:10.1038/eye.2011.206; published online 19 August 2011

Sir,
Anterior segment OCT imaging in opaque grafts with secondary glaucoma following tectonic penetrating keratoplasty for perforated corneal ulcers

Penetrating keratoplasty performed for perforated corneal ulcers is associated with a high incidence of secondary glaucoma.^{1,2} Anterior segment optical coherence tomography (ASOCT) provides non-contact, non-invasive, high-resolution, real-time cross-sectional images of the anterior segment of the eye.^{3,4}

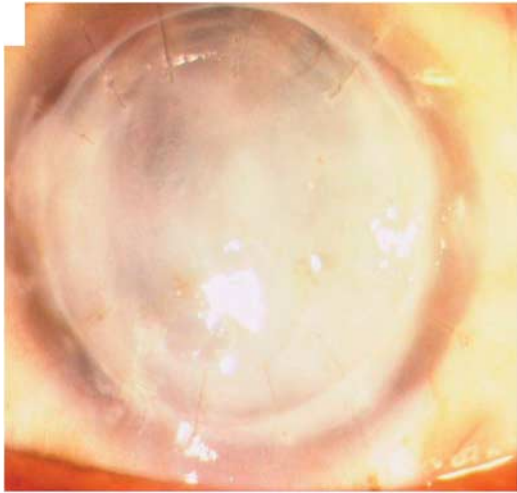


Figure 1 Post-therapeutic penetrating keratoplasty glaucoma with opaque graft.

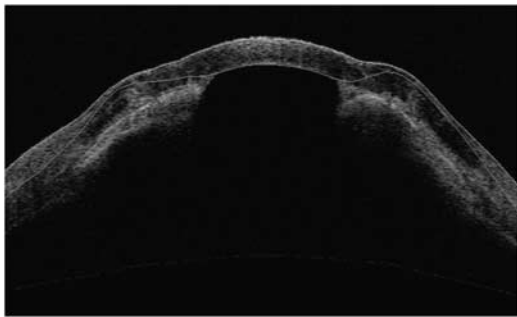


Figure 2 ASOCT image showing peripheral anterior synechiae approaching paracentral area.

Case report

We conducted a prospective study to evaluate the role of ASOCT in the evaluation of the anterior segment in opaque grafts with secondary glaucoma following penetrating keratoplasty performed for perforated corneal ulcers. Eyes with opaque corneal grafts (Figure 1) and with an intraocular pressure (IOP) > 25 mm of Hg on two separate occasions presenting three or more months post surgery were included in the study. Twenty five eyes of twenty-five patients with opaque corneal grafts and secondary glaucoma following therapeutic penetrating keratoplasty were enrolled in the present study. The mean IOP at presentation was 37.4 ± 8.9 mm Hg (range, 26–61 mm Hg). ASOCT examination revealed peripheral anterior synechiae in 5 eyes (Figure 2) (20%), a combination of peripheral anterior synechiae + graft-host junction synechiae (Figure 3) in 14 eyes (56%) and a combination of peripheral anterior synechiae + graft-host junction + central synechiae (Figure 4) in 6 eyes (24%). The extent of synechial angle closure was 90–180° in 2 eyes (8%), 180–270° in 4 eyes (16%) and 270–360° in the remaining 19 eyes (76%).

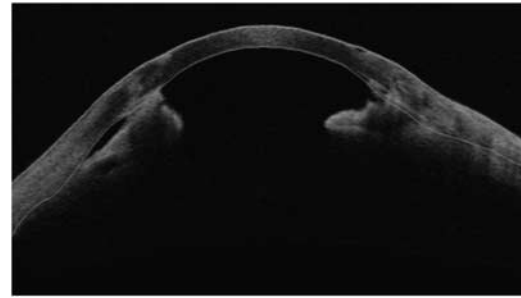


Figure 3 ASOCT image showing both peripheral anterior synechiae and graft-host junction synechiae.

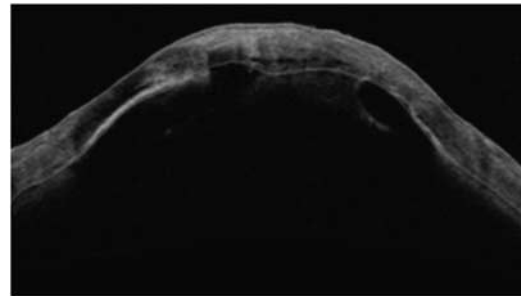


Figure 4 ASOCT image showing combined peripheral anterior synechiae, graft-host junction and central synechiae.

Comment

ASOCT enables detailed visualization of the anterior segment and angle anatomy in eyes with opaque corneal grafts and secondary glaucoma. Secondary angle closure due to peripheral anterior synechiae formation is an important mechanism for intraocular pressure elevation in these eyes. Knowledge of the exact sites of peripheral anterior synechiae pre-operatively in such eyes may be of help in planning the site of trabeculectomy or placement of aqueous drainage devices. Being a non-contact procedure, ASOCT helps in the immediate post-operative follow up of these patients. It provides rapid and high-resolution images of the entire circumference of the anterior chamber angle. Angle evaluation using ASOCT is recommended in all eyes with post-penetrating keratoplasty secondary glaucoma before planning any corneal or glaucoma intervention.

Conflict of interest

The authors declare no conflict of interest.

References

- 1 Ayyala RS. Penetrating keratoplasty and glaucoma. *Surv Ophthalmol* 2000; **45**: 91–105.
- 2 Dada T, Aggarwal A, Minudath KB *et al*. Post-Penetrating Keratoplasty Glaucoma. *Indian J Ophthalmol* 2008; **56**: 269–277.
- 3 Radhakrishnan S, Rollins AM, Roth JE, Yazdanfar S, Westphal V, Bardenstein DS *et al*. Real-time optical coherence tomography of the anterior segment at 1310 nm. *Arch Ophthalmol* 2001; **119**: 1179–1185.

- 4 Müller M, Dahmen G, Pörksen E, Geerling G, Laqua H, Ziegler A *et al.* Anterior chamber angle measurement with optical coherence tomography: intraobserver and interobserver variability. *J Cataract Refr Surg* 2006; **32**: 1803–1808.

T Dada, BM Shah, SJ Bali, N Bansal, A Panda and M Vanathi

Dr Rajendra Prasad Centre for Ophthalmic Sciences, All India Institute of Medical Sciences, New Delhi, India
E-mail: tanujdada@gmail.com

Eye (2011) **25**, 1522–1524; doi:10.1038/eye.2011.210; published online 9 September 2011

Sir,
Abnormal corneal nerves in a patient with Lyme disease

Lyme disease is a multiorgan disease caused by a spirochete, *Borrelia burgdorferi*. Although numerous ophthalmologic manifestations have been described following Lyme disease,^{1,2} this case describes a new feature: a bilateral corneal neuropathy.

Case report

A 69-year-old woman was referred for a suspicion of corneal dystrophy in both eyes that appeared during the last 6 months. Her past medical history was relevant for a tick bite complicated by Lyme disease 2 years ago. Despite oral antibiotic treatment (clarithromycin),

she still suffered from peripheral neuropathy in the lower extremities.

She presented with complaints of decrease vision bilaterally. Best corrected visual acuity was 20/25 in both eyes. Slit-lamp examination revealed irregularly enlarged corneal stromal nerves in both eyes (Figure 1). These abnormalities did not reach the central cornea and were predominantly observed in the mid-peripheral area of the right eye. Except this finding, corneal examination was normal in both eyes. No sign of inflammation of the anterior segment was observed. Examination of the posterior segment of both eyes was normal. The slight decrease in visual acuity was explained by a mild bilateral cataract. Using the Cochet–Bonnet aesthesiometer, a marked hypoesthesia was observed in the central cornea of the right eye (3.5 mm), whereas the corneal sensitivity was subnormal in the left eye (5.5 mm). Except the corneas, the sensitivity in the area innervated by the trigeminal nerves was not altered. *In vivo* confocal microscopy (HRT3, Heidelberg Engineering, Heidelberg, Germany) revealed enlarged stromal nerves with tortuous and abnormal branching in both eyes. Some nerve fibers showed a hyper-reflective peri-nerve infiltration (Figure 2).

Discussion

Cranial nerve involvements are well documented in early disseminated Lyme disease,³ but in the presented case, only the corneal nerves of both eyes showed alterations that were observed 2 years after the infection. In our patient, the association of distal paresthesia, suggesting axonal polyneuropathy and corneal nerves alterations, strongly supported the responsibility of Lyme disease. The mechanisms responsible for peripheral

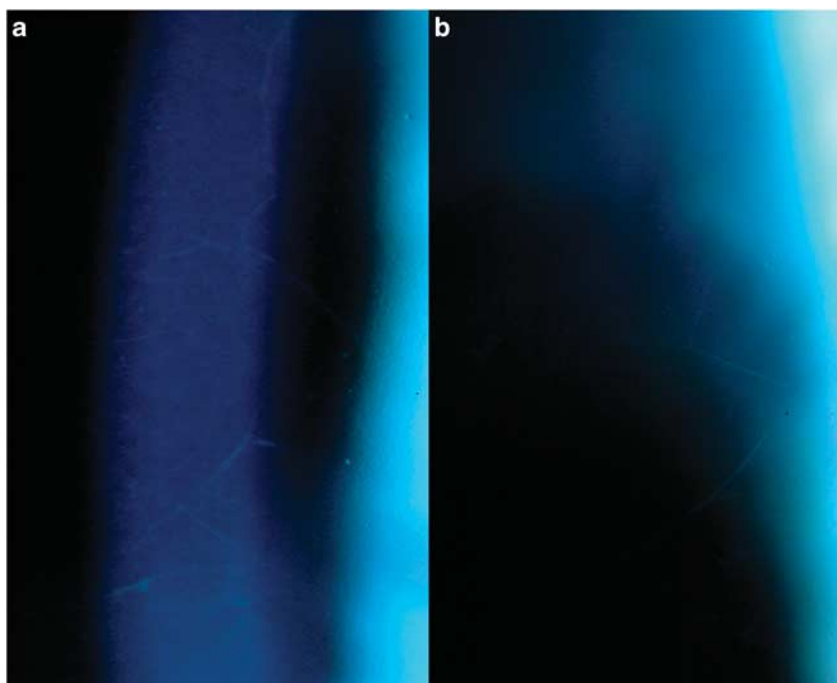


Figure 1 Slit-lamp images ($\times 20$) of irregularly enlarged nerves within the corneal stroma of the right eye (a) and the left eye (b).