

Neonatal Herpes Simplex Infection

David W. Kimberlin*

*Division of Pediatric Infectious Diseases, The University of Alabama at Birmingham,
Birmingham, Alabama 35233*

INTRODUCTION	1
BIOLOGY	2
Viral Structure	2
Latency and Neurovirulence.....	2
EPIDEMIOLOGY	2
Infections in Children and Nonpregnant Adults.....	2
Orolabial herpes (HSV-1).....	2
Genital herpes (HSV-2 or HSV-1).....	3
Maternal Genital Infections	3
Factors influencing neonatal transmission	4
Incidence of Neonatal Disease	4
Times of Transmission to the Neonate and Disease Classifications.....	4
CLINICAL PRESENTATIONS	4
Intrauterine Infection.....	4
Disseminated Disease.....	5
CNS Disease	5
SEM Disease.....	5
DIAGNOSIS	5
Overall Evaluation	5
Laboratory Assessment	6
Serologic testing	6
Viral culture.....	6
PCR amplification.....	6
TREATMENT AND MANAGEMENT	7
Antiviral Drugs.....	7
Mortality	7
Morbidity	8
(i) Disseminated and CNS disease.....	8
(ii) SEM disease.....	8
Summary of current treatment.....	9
Antibody Therapy.....	10
PREVENTION	10
Cesarean Delivery	10
Antiviral Prophylaxis during Pregnancy	10
Vaccine Development.....	11
CONCLUSIONS	11
ACKNOWLEDGMENTS	11
REFERENCES	11

INTRODUCTION

Neonatal infections with herpes simplex virus (HSV) were first reported in the mid-1930s, when Hass described the histopathologic findings of a fatal case (35) and when Batignani reported a newborn with herpes simplex keratitis (14). Over the subsequent decades, the spectrum of disease which HSV can cause in the newborn has been detailed and the efficacy of antiviral therapy in neonatal HSV infections has been established. The earliest antiviral agents with in vitro activity against

HSV, including 5-iodo-2'-deoxyuridine and 1- β -D-arabino-furanosylcytosine, proved too toxic in humans to be useful (16, 81). Vidarabine (1- β -D-arabinofuranosyladenine) was the first systemically administered antiviral medication with activity against HSV for which the therapeutic efficacy outweighed its toxicity for the management of life-threatening HSV disease. Licensed for use in the United States in 1977, vidarabine occupies a special place in the historical development of antiviral compounds. Due to toxicity when administered systemically, use of intravenous vidarabine was restricted by the Food and Drug Administration to life-threatening HSV and varicella-zoster virus infections. Multicenter collaborative clinical trials conducted by the National Institute of Allergy and Infectious Diseases (NIAID) Collaborative Antiviral Study Group established its efficacy in the treatment of neonatal HSV infections

* Mailing address: Division of Pediatric Infectious Diseases, The University of Alabama at Birmingham, 1600 Seventh Ave. South, CHB 303, Birmingham, AL 35233. Phone: (205) 996-7802. Fax: (205) 975-9972. E-mail: dkimberlin@peds.uab.edu

(98, 102), HSV encephalitis (101), varicella-zoster virus infections (96), and herpesvirus infections in immunocompromised patients (96, 100). Such collaborative efforts not only established the scientific merit of the compound but also foreshadowed the system by which newer antiviral drugs such as acyclovir and the antiretroviral compounds are evaluated. Additionally, close investigation of vidarabine provided detailed information about herpesvirus infections at a cellular level, illuminating not only the natural history of the diseases but also molecular mechanisms of antiviral action. Intravenous vidarabine has not been available in the United States since 1992, although a topical preparation remains on the market for the treatment of HSV keratitis.

The next development in the management of neonatal HSV disease was a landmark comparison of vidarabine and a lower dose of acyclovir (30 mg/kg/day administered intravenously in three divided doses for 10 days) conducted during the 1980s (92). Most recently, a higher dose of acyclovir (60 mg/kg/day administered intravenously in three divided doses for 21 days) has been evaluated in the management of neonatal HSV disease (47), as discussed in detail below. Each of these trials resulted in a change in the therapeutic standard for the management of neonatal HSV disease, either because of lower toxicity and improved ease of administration (in the case of the lower dose of acyclovir) or because of improved outcome (in the case of the higher dose of acyclovir).

Additional improvements in the outcomes of neonates with HSV disease have been achieved through advances in the diagnostics available to clinicians, the most powerful of which is the application of PCR to patients with neonatal HSV disease (46). This powerful diagnostic tool has enhanced the ability to correctly diagnose neonatal HSV infections and has proven especially beneficial in patients without overt manifestations of HSV disease such as skin vesicles. It also has provided an additional means by which response to therapy can be assessed.

Other areas of promise with respect to prevention of neonatal HSV infections include the development of genetically engineered subunit and live attenuated HSV vaccines for prevention of maternal genital infections and evaluation of antiviral administration to gravid women to reduce the likelihood of clinically apparent genital disease at the time of delivery. Of all the herpesvirus infections, neonatal HSV infection should be the most amenable to prevention and treatment because it is acquired most often at birth rather than early in gestation. This article summarizes the recent developments in neonatal HSV disease management, focusing on enhanced therapeutic interventions, improved diagnostic modalities, and possible means of preventing viral transmission to newborns in the future.

BIOLOGY

Viral Structure

HSV-1 and HSV-2 are two of the eight known viruses which comprise the human herpesvirus family. As with all herpesviruses, they are large, enveloped virions with an icosahedral nucleocapsid consisting of 162 capsomeres, arranged around a linear, double-stranded DNA core. The genome consists of two covalently linked components, designated L (long) and S

(short). Each component consists of a unique sequence flanked by inverted repeats. Additionally, the unique L and S components can invert relative to one another, yielding four linear isomers. Each intact HSV virion contains only one of these four isomers, and each of the four is equally virulent (functionally equivalent) in the host cell.

The DNAs of HSV-1 and HSV-2 are largely colinear, and considerable homology exists between the HSV-1 and HSV-2 genomes. These homologous sequences are distributed over the entire genomic map, and most of the polypeptides specified by one viral type are antigenically related to polypeptides of the other viral type. This results in considerable cross-reactivity between the HSV-1 and HSV-2 glycoproteins, although unique antigenic determinants exist for each virus. Viral surface glycoproteins mediate HSV attachment to and penetration into cells and provoke host immune responses. Eleven glycoproteins of HSV have been identified (gB, gC, gD, gE, gG, gH, gI, gJ, gK, gL, and gM), with a twelfth being predicted (gN). gD is the most potent inducer of neutralizing antibodies and appears related to viral entry into a cell, and gB also is required for infectivity. Antigenic specificity is provided by gG, with the resulting antibody response allowing for the distinction between HSV-1 (gG-1) and HSV-2 (gG-2).

Latency and Neurovirulence

Two biologic properties of HSV which directly influence human disease are latency and neurovirulence. During HSV infection, virions are transported by retrograde flow along axons that connect the point of entry into the body to the nuclei of sensory neurons (82). Viral multiplication occurs in a small number of sensory neurons, and the viral genome then remains in a latent state for the life of the host. With periodic reactivation brought on by events such as physical or emotional stress, fever, UV light, and tissue damage, the virus is transported back down the axon to replicate again at or near the original point of entry into the body. Such reactivation can result in clinically apparent disease (lesions) or clinically inapparent (asymptomatic, or subclinical) infection. The mechanisms by which HSV establishes latency are being intensely investigated but remain incompletely understood.

Neurovirulence refers to the affinity with which HSV is drawn to and propagated in neuronal tissue. This can result in profound disease with severe neurologic sequelae, as is the case with neonatal HSV central nervous system (CNS) disease and with herpes simplex encephalitis in older children and adults. Sites on the HSV genome which mediate this propensity for neurovirulence have been mapped to the thymidine kinase gene as well as the termini of the L component. Of note, the gene identified as $\gamma_134.5$ is required for replication in central nervous system tissue and prevents apoptosis of infected neuronal cells. Genetically engineered HSV virions lacking the $\gamma_134.5$ gene are currently being investigated as therapies for brain tumors (59, 60).

EPIDEMIOLOGY

Infections in Children and Nonpregnant Adults

Orolabial herpes (HSV-1). Virtually all herpetic orolabial disease is caused by HSV-1. The geographic distribution of

HSV-1 is worldwide, with infection occurring in both developed and underdeveloped countries. Animal vectors for human HSV infections have not been described, and humans remain the sole reservoir for transmission to other humans. Virus is transmitted from infected to susceptible individuals during close personal contact. There is no seasonal variation in the incidence of infection. Because infection is rarely fatal and HSV establishes latency, over one-third of the world's population has recurrent HSV infections and hence, the capability of transmitting HSV during episodes of productive infection. As such, recurrent herpes labialis is the largest reservoir of HSV infections in the community.

Using type-specific serologic assays, the seroprevalence of HSV-1 infections in the United States has been redefined utilizing sera obtained from the randomized National Health and Nutrition Examination Survey (37, 64). By the age of 5 years, over 35% of black children and 18% of white children are infected by HSV-1. Through adolescence, blacks have approximately a twofold higher prevalence of antibodies to HSV-1 than do whites, and females have a slightly higher antibody prevalence than do males. By the age of 40 years, both blacks and whites have a similar prevalence of antibodies, with 70 to 80% being HSV-1 seropositive. A similarly high prevalence of antibodies to HSV-1 exists among persons worldwide, although a high degree of country-to-country variability is seen.

Genital herpes (HSV-2 or HSV-1). Genital herpes infections are caused by HSV-2 or HSV-1. Epidemiologic studies of HSV-2 seroprevalence accurately reflect HSV-2-associated genital disease burden. However, similar studies of HSV-1 seroprevalence are not of equal utility in determining the magnitude of HSV-1-associated genital disease burden, because a majority of adults have acquired HSV-1 orolabial infections by the time they reach adulthood (34), as described above. Seroepidemiologic studies thus cannot distinguish a person with HSV-1 antibody due to prior orolabial infection from someone with prior HSV-1 genital disease.

When a person with no prior HSV-1 or HSV-2 antibody acquires either virus in the genital tract, a first-episode primary infection results. If a person with preexisting HSV-1 antibody acquires HSV-2 genital infection, a first-episode nonprimary infection ensues. Viral reactivation from latency and subsequent antegrade translocation of virus back to the skin and mucosal surfaces produces a recurrent infection.

HSV-2 antibodies do not routinely appear prior to adolescence (37, 56), and antibody prevalence correlates with prior sexual activity. The primary route of acquisition of HSV-2 infections is via genital-genital sexual contact with an infected partner (29, 38, 39, 66). Since the late 1970s, seroprevalence rates for HSV-2 in the United States have increased by 30%, despite concurrent efforts associated with the human immunodeficiency virus epidemic to raise awareness of safer sex practices (32). Currently, one-fifth of U.S. residents aged 12 years or older are infected with HSV-2 and one-quarter of U.S. residents aged 30 years or older are infected with HSV-2. These infection rates and their rise over the past two decades suggest that genital herpes is nearing epidemic proportions. Predictors of positive HSV-2 serologic status include female sex, black race or Mexican-American ethnic background, a greater lifetime number of sexual partners, older age, less

formal education, and an income below the poverty line (32, 37, 64). For sexually active Americans with a single lifetime sexual partner, the probability of acquisition of HSV-2 is 10.2%. This figure increases to 20.7, 25.9, 30.9, and 46.1% as the number of lifetime sexual partners increases to 2 to 4, 5 to 9, 10 to 49, and ≥ 50 , respectively (32). Despite these high seroprevalence rates, only 2 to 3% of adults in the United States report ever having had genital herpes, and it is this lack of recognition of one's own infection which contributes to the surreptitious spread of the infection.

Along with the increased incidence of genital HSV-2 infections over the past two decades, there has also been a dramatic rise in the incidence of genital HSV-1 infections. In the early 1980s, approximately 10% of cases of genital herpes in the United States were caused by HSV-1 (17, 26, 51, 64, 73). By the mid-1990s, the percentage of primary cases of genital herpes caused by HSV-1 had doubled to 20% (54). In other parts of the world, HSV-1 accounts for an even larger percentage of genital herpes cases, with rates in excess of 40% reported from Singapore, Sweden, England, Norway, and Japan (13, 25, 57, 65, 75, 87). Genital HSV-1 infections can result from either genital-genital contact or oral-genital contact with an infected person who is actively shedding virus. Given the decreased propensity of HSV-1 to reactivate at the genital site, however, it is oral-genital contact that accounts for most genital HSV-1 infections (54). Whites with genital herpes are more likely than blacks with genital herpes to have infection caused by HSV-1 (54). This may relate to the younger ages at which orolabial HSV-1 infections are acquired among minorities, thereby providing a degree of protection against genital HSV-1 infection in adulthood.

Maternal Genital Infections

Recurrent genital herpes infections are the most common form of genital HSV infections during gestation (94). However, as discussed below, it is the woman with primary genital HSV disease who is at highest risk of transmitting the virus to her baby. About 10% of HSV-2-seronegative pregnant women have an HSV-2-seropositive sexual partner and thus are at risk of contracting a primary HSV-2 infection (53). Among such discordant couples, women who are seronegative for both HSV-1 and HSV-2 have an estimated chance of seroconversion for either virus of 3.7% while women who are already seropositive for HSV-1 have an estimated chance of HSV-2 seroconversion of 1.7% (22). Approximately two-thirds of women who acquire genital herpes during pregnancy have no symptoms to suggest a genital HSV infection (22). This is consistent with the finding that 60 to 80% of women who deliver an HSV-infected infant have no evidence of genital HSV infection at the time of delivery and have neither a past history of genital herpes nor a sexual partner reporting a history of genital herpes (97, 99, 104).

For neonatal transmission to occur in the peripartum period, the gravid woman must be shedding virus, either symptomatically or asymptotically, at the time of delivery. Studies of nonpregnant HSV-seropositive women have shown that HSV, as detected by PCR, is shed asymptotically in the genital tract on approximately 1 of every 3 days (90), a remarkable figure that probably has significant implications for both gen-

ital and neonatal spread of HSV infections. Among pregnant women, the incidence of viral excretion proximate to delivery ranges from 0.20 to 0.39% for all pregnant women, irrespective of past history (15, 21, 69). Among pregnant women with a known history of recurrent genital HSV, the incidence of excretion may be as high as 0.77% (89) to 1.4% (4).

Factors influencing neonatal transmission. Factors that influence transmission from mother to neonate include the type of maternal infection (primary versus recurrent) (21, 23, 24, 28, 62), maternal antibody status (24, 70, 104, 105), duration of rupture of membranes (62), integrity of mucocutaneous barriers (e.g., use of fetal scalp electrodes) (24, 41, 67), and mode of delivery (cesarean section versus vaginal) (24).

Infants born to mothers who have a first episode of genital HSV infection near term are at much greater risk of developing neonatal herpes than are those whose mothers have recurrent genital herpes (21, 23, 24, 28, 62). The largest such assessment involved almost 40,000 women without clinical evidence of genital HSV infection and from whom samples were cultured within 48 h of delivery. Of these, 121 women were identified who both were asymptotically shedding HSV and for whom serum was available for serologic analysis. In this large trial, 57% of babies delivered to women with first-episode primary infection developed neonatal HSV disease compared with 25% of babies delivered to women with first-episode non-primary infection and 2% of babies delivered to women with recurrent HSV disease (24).

The duration of membrane rupture also appears to affect the risk of acquisition of neonatal infection. A small study published in 1971 demonstrated that cesarean delivery in a woman with active genital lesions can reduce the infant's risk of acquiring HSV if performed within 4 h of membrane rupture (62). Based on this observation, it has been recommended for more than three decades that babies of women with active genital lesions at the time of onset of labor be delivered by cesarean section (3). It was not until 2003, however, that cesarean delivery was definitively proven to be effective in the prevention of HSV transmission to the neonate from a mother actively shedding virus from the genital tract (24). Importantly, neonatal infection has occurred in spite of cesarean delivery performed prior to the rupture of membranes (97).

Incidence of Neonatal Disease

Estimates of the incidence of neonatal herpes have varied from 1 in 3,000 to 1 in 20,000 live births (63). While fluctuations in the incidence of neonatal HSV disease have been observed (21, 63), the current estimated rate of occurrence is approximately 1 in 3,200 deliveries (24). While a progressive increase in the number of cases of neonatal HSV infection has been noted in some areas of the country (85), neonatal HSV infections still occur far less frequently than do genital HSV infections in the adult population of child-bearing age. Overall, the United States, with approximately 4.0 million deliveries per year, has an estimated 1,500 cases of neonatal HSV infection annually.

As discussed above, women who acquire first-episode genital herpes during pregnancy are at far greater risk of transmitting the virus to their newborns than are women with genital reactivation of latent infection. As the baseline prevalence of

HSV-2 genital infection increases in the overall population, it will become increasingly likely that a gravid woman may acquire HSV-2 for the first time during her pregnancy through sexual contact with a partner with recurrent or primary genital HSV-2 infection. As such, it is possible that the incidence of neonatal HSV disease may increase in the years to come. Although data on neonatal HSV incidence in very recent years have not been systematically gathered, it is the impression of many experts that the severity of neonatal HSV disease, as manifest by devastating CNS and disseminated infections, has increased over the past 5 years. If confirmed over time, such an observation would probably be related to an increase in the incidence of primary genital infections (32) in pregnant women and its associated increase in the likelihood of transmission to the neonate (24), along with the associated lack of maternal antibodies which can limit the extent of disease in the infected neonate (70).

Times of Transmission to the Neonate and Disease Classifications

HSV disease of the newborn is acquired during one of three distinct time intervals: intrauterine (in utero), peripartum (perinatal), and postpartum (postnatal). The time of transmission for the overwhelming majority (~85%) of infected neonates is in the peripartum period. An additional 10% of infected neonates acquire the virus postnatally, and the final 5% are infected with HSV in utero. HSV infections acquired either peripartum or postpartum can be further classified as (i) disease localized to the skin, eyes, and/or mouth (SEM disease, accounting for ~45% of cases of neonatal HSV); (ii) encephalitis, with or without SEM involvement (CNS disease, accounting for ~30% of cases of neonatal HSV); and (iii) disseminated infection involving multiple organs, including the CNS, lungs, liver, adrenal glands, skin, eyes, and/or mouth (disseminated disease, accounting for ~25% of cases of neonatal HSV). This classification system is predictive of both morbidity and mortality (47, 48, 92, 93, 98). Patients with disseminated or SEM disease generally present to medical attention at 10 to 12 days of life, while patients with CNS disease on average present somewhat later, at 16 to 19 days of life (48).

CLINICAL PRESENTATIONS

Intrauterine Infection

Intrauterine HSV disease occurs in approximately 1 in 300,000 deliveries (10). While rare, in utero disease is unlikely to be missed due to the extent of involvement of affected babies. Infants acquiring HSV in utero typically have a triad of clinical findings consisting of cutaneous manifestations (scarring, active lesions, hypo- and hyperpigmentation, aplasia cutis, and/or an erythematous macular exanthem), ophthalmologic findings (microphthalmia, retinal dysplasia, optic atrophy, and/or chorioretinitis), and neurologic involvement (microcephaly, encephalomalacia, hydranencephaly, and/or intracranial calcification) (33, 36, 40, 61).

TABLE 1. Signs and symptoms prior to study enrollment^a

Sign or symptom	Incidence in patients with:							
	SEM disease (n = 64)		CNS disease (n = 63)		Disseminated disease (n = 59)		Total (n = 186)	
	No. (%) of patients	Duration (days) ^b	No. (%) of patients	Duration (days)	No. (%) of patients	Duration (days)	No. (%) of patients	Duration (days)
Skin vesicles	53 (83)	3.8 ± 0.5	40 (63)	6.1 ± 1.0	34 (58)	3.7 ± 0.6	127 (68)	4.5 ± 0.4
Lethargy	12 (19)	3.3 ± 0.7	31 (49)	4.6 ± 0.7	28 (47)	3.4 ± 0.7	71 (38)	3.9 ± 0.4
Fever	11 (17)	4.6 ± 1.5	28 (44)	3.1 ± 0.4	33 (56)	4.6 ± 0.6	72 (39)	4.0 ± 0.4
Conjunctivitis	16 (25)	6.5 ± 1.5	10 (16)	4.1 ± 1.3	10 (17)	5.9 ± 1.9	36 (19)	5.7 ± 0.9
Seizure	1 (2)	7.0	36 (57)	2.9 ± 0.5	13 (22)	2.5 ± 0.7	50 (27)	2.9 ± 0.4
DIC ^c	0 (0)		0 (0)		20 (34)	1.5 ± 0.3	20 (11)	1.5 ± 0.3
Pneumonia	0 (0)		2 (3)	9.0 ± 6.0	22 (37)	4.0 ± 0.8	24 (13)	4.5 ± 0.9

^a Adapted from reference 48.

^b Duration of symptoms (mean ± SEM).

^c DIC, disseminated intravascular coagulation.

Disseminated Disease

Historically, disseminated HSV infections have accounted for approximately one-half to two-thirds of all children with neonatal HSV disease. However, this figure has been reduced to about 25% since the development and utilization of antiviral therapy, probably the consequence of recognizing and treating SEM infection before its progression to more severe disease (97). Encephalitis is a common component of this category of infection, occurring in about 60 to 75% of infants with disseminated disease (94). While the presence of a vesicular rash can greatly facilitate the diagnosis of HSV infection, over 20% of neonates with disseminated HSV disease do not develop cutaneous vesicles during the course of their illness (5, 48, 86, 97). Events associated with disseminated neonatal HSV infection which actually result in death relate primarily to the severe coagulopathy, liver dysfunction, and pulmonary involvement of the disease.

CNS Disease

Almost one-third of all neonates with HSV infection are categorized as having CNS disease (with or without SEM involvement) (97). Clinical manifestations of CNS disease include seizures (both focal and generalized), lethargy, irritability, tremors, poor feeding, temperature instability, and bulging fontanelle. Between 60 and 70% of babies classified as having CNS disease have associated skin vesicles at some point in the disease course (48, 86). In infants with CNS disease, mortality is usually caused by devastating brain destruction, with resulting acute neurologic and autonomic dysfunction.

SEM Disease

SEM disease has historically accounted for approximately 18% of all cases of neonatal HSV disease. With the introduction of early antiviral therapy, this frequency has increased to approximately 45% (97). Systematic application of PCR to blood samples from babies with neonatal HSV disease will probably demonstrate that these disease classifications are really more of a spectrum than absolute differences in disease manifestations (11, 30, 50, 58), with SEM disease having more limited viral dissemination but without visceral (liver, lung,

etc.) involvement as detected biochemically (e.g., elevated transaminase levels) or clinically (e.g., pneumonitis).

DIAGNOSIS

Overall Evaluation

With ~95% of infected babies acquiring HSV during the peripartum and postpartum periods, therapeutic intervention can potentially occur relatively soon after viral replication begins, prior to widespread viral dissemination and the development of significant and possibly permanent damage to infected tissues and organs (49). For antiviral therapy to be initiated, however, the treating physician must have an index of suspicion which allows for prompt institution of acyclovir therapy. Selected symptoms and signs of neonatal HSV infection at the time of presentation for medical care are presented in Table 1, according to extent of disease. The presence of skin vesicles among patients in any of the disease categories and of seizures in patients with CNS HSV disease appear to be among the findings most suggestive of HSV infection. The absence of fever is common at the time of presentation of neonatal HSV disease. As Table 1 illustrates, however, no single constellation of presenting symptoms and signs identifies all babies with neonatal HSV disease.

A recent comparison between two periods (1981 to 1988 and 1989 to 1997) spanning 16 years suggests that no progress has been made since 1981 in decreasing the time interval between onset of symptoms and initiation of antiviral therapy (48). Given the highly effective antiviral therapies that currently exist for the management of neonatal HSV disease, the most meaningful and immediate manner in which the outcomes of neonatal HSV disease may be rapidly altered is to raise awareness of this infection and hence to decrease the time to diagnostic evaluation for neonatal HSV disease and subsequently to initiation of appropriate antiviral therapy (86). While it is the opinion of the author and of many other experts that acyclovir should not be added routinely to standard antibiotics as management for neonates admitted to rule out sepsis (48), HSV should be considered in the differential diagnosis of acutely ill infants younger than 1 month (48). If the presentation is compatible with neonatal HSV disease, appropriate laboratory specimens should be obtained and acyclovir therapy

should then be initiated. This is especially true if the patient's bacterial cultures are negative at 48 to 72 h and the neonate has not improved clinically. The diagnostic evaluations obtained prior to initiation of acyclovir therapy should include HSV cultures of skin vesicles (if present), oropharynx, conjunctivae, urine, blood, stool or rectum, and cerebrospinal fluid (CSF) (1). Cerebrospinal fluid should also be sent to a reliable laboratory for HSV DNA PCR (46), as discussed below. Liver transaminase levels should also be determined, since their elevation could suggest disseminated HSV infection.

Laboratory Assessment

Serologic testing. Until recently, the commercially available serologic assays were unable to distinguish between HSV-1 and HSV-2 antibodies, severely limiting their utility. In the past few years, type-specific antibody assays have been approved by the Food and Drug Administration and are on the U.S. market. These include tests manufactured by Diagnostics (HSV-2) (7, 8, 51) and MRL (now called Focus Technologies; HSV-1 and HSV-2) (55, 68, 103); tests by at least three additional companies are under development. A number of additional tests which claim to distinguish between HSV-1 and HSV-2 antibody are commercially available but have such high cross-reactivity rates that they should be avoided (6). It is important to note that serologic testing identifies only past infection and cannot identify the site of HSV infection: patients with cold sores due to HSV-1 will test HSV-1 seropositive regardless of whether they also have genital HSV-1 infection. With these type-specific assays, however, it is now possible to identify serodiscordant couples in which the woman is HSV-2 seronegative, and the partner is seropositive. Women in such couples are at risk for acquiring primary genital HSV infection during pregnancy and are thus at higher risk of transmitting the virus to their babies during birth. At present the optimal application of these type-specific assays has not been determined. Recent studies documenting the efficacy of condom use (91) and of antiviral suppression of the seropositive partner (L. Corey, S. Tyring, K. Beutner, T. Warren, S. Sacks, R. Patel, A. Wald, G. Mertz, J. Paavonen, and the Valaciclovir Study Group, Program Abstr. 42nd Intersci. Conf. Antimicrob. Agents Chemother, abstr. LB-3, 2002) in preventing the acquisition of genital herpes suggest that successful interventions based on knowledge of a couple's serologic status can be devised.

In contrast to other congenital and neonatal infections, serologic diagnosis of neonatal HSV infection is not of great clinical value. With the availability of reliable type-specific assays, one barrier to interpreting serologic results in babies with suspected HSV disease has been removed. However, the presence of transplacentally acquired maternal immunoglobulin G still confounds the assessment of the neonatal antibody status during acute infection, especially given the large proportions of the adult American population who are HSV-1 and HSV-2 seropositive. Serial antibody assessment may be useful in the very specific circumstance of a mother who has a primary infection late in gestation and transfers very little or no antibody to the fetus. In general, however, serologic studies play no role in the diagnosis of neonatal HSV disease.

Viral culture. Isolation of HSV by culture remains the definitive diagnostic method of establishing HSV disease. If skin

TABLE 2. PCR results from CSF of infected neonates^a

PCR result	No. (%) of patients with:		
	SEM disease (n = 29)	CNS disease (n = 34)	Disseminated disease (n = 14)
Positive	7 (24)	26 (76)	13 (93)
Negative	22 (76)	8 (24)	1 (7)

^a Data from reference 46.

lesions are present, a scraping of the vesicles should be transferred in appropriate viral transport medium on ice to a diagnostic virology laboratory. Such specimens are inoculated into cell culture systems, which are then monitored for cytopathic effects characteristic of HSV replication. Typing of an HSV isolate may then be done by one of several techniques. Other sites from which virus may be isolated include the CSF, urine, blood, stool or rectum, oropharynx, and conjunctivae. Collection of duodenal aspirates for HSV isolation may be indicated in infants with hepatitis, necrotizing enterocolitis, or other gastrointestinal manifestations of disease (95). Specimens for viral culture from multiple body sites (with the exception of CSF) may be combined prior to plating in cell culture in order to decrease costs. The reason is that with the exception of CNS involvement, the important information gathered from such cultures is the presence or absence of replicating virus rather than its precise location.

Of the sites routinely cultured for HSV during a recent study (48), skin cultures and eye or conjunctival cultures consistently provided the greatest yields regardless of disease classification, with $\geq 90\%$ of cultures being positive. Overall, 58 (94%) of 62 patients had a positive skin or eye culture, 33 (48%) of 69 patients had a positive mouth/oropharyngeal culture, and 17 (40%) of 42 patients with CNS involvement (CNS disease or disseminated disease with CNS involvement) had a positive CSF or brain biopsy culture (48).

PCR amplification. The diagnosis of neonatal HSV infections has been revolutionized by the application of PCR technology to clinical specimens including CSF (2, 46, 50, 58, 76, 77, 88) and blood (11, 30, 50, 58). Direct comparisons of the results of these studies are complicated by differences in the methods used in different laboratories. In the largest series, CSF specimens from 77 neonates in the United States with culture-proven HSV disease were evaluated retrospectively by PCR (46). The results of this analysis both enhanced the understanding of the spectrum of the natural history of neonatal HSV disease and validated the utilization of PCR in the management of such infants. These 77 infants had been previously enrolled during the 1980s in a comparative study of vidarabine and acyclovir for the treatment of neonatal HSV disease. As such, categorization of infants by extent of disease (e.g., SEM disease, CNS disease, and disseminated disease) reflected the laboratory technologies available at the time.

As shown in Table 2, HSV DNA was detected by PCR in the CSF of almost one-quarter of infants who had previously been categorized as having SEM disease (46). These results suggest that the spectrum of neonatal HSV disease may reflect more of a continuum than rigid placement in one of three categories, as has been suggested as well by others (58). A complete understanding of the significance of a positive CSF PCR result in an

infant with no other laboratory, radiographic, or clinical evidence of CNS involvement requires additional prospective evaluation.

In the same investigation, HSV DNA was detected in the CSF of 13 (93%) of the 14 infants classified as having disseminated disease (Table 2) (46). Of the 34 infants categorized as having CNS disease, 26 (76%) were PCR positive in their CSF (Table 2). This is remarkably similar to the Swedish experience of applying PCR to stored specimens from patients with neonatal HSV diagnosed between 1973 and 1996, where 78% of neonates with CNS HSV disease were found to be PCR positive from CSF (58). Of the eight neonates with CNS disease and negative CSF PCR results in the U.S. study, seven had a single CSF specimen available for retrospective PCR analysis (46). Furthermore, the specimens for six of the eight infants were obtained 5 days or more after initiation of antiviral therapy, and one could speculate that this time interval could explain why the samples were PCR negative. Thus, the PCR assay in the U.S. investigation had an overall sensitivity of 80% (due to their failure to detect HSV DNA from CSF specimens of eight infants with CNS disease) and an overall specificity of 71% (due to the finding of HSV DNA in the CSF of seven infants with presumed SEM disease) (46). In comparison, the sensitivities of PCR assays used in two other investigations of neonatal HSV disease were 100% (50) and 75% (88) and the specificities were 100% in both studies (50, 88).

While the broad ranges of sensitivity and specificity cited above can be explained at least in part by differences in the methods used in the individual studies, many of which involved retrospective PCR analysis of stored biological specimens, the variability in performance of PCR between laboratories warrants consideration. Interlaboratory standards which ensure that identical specimens processed in two different laboratories will yield identical results are largely nonexistent. Furthermore, the performance of PCR is highly dependent on the manner in which the specimen was collected and maintained prior to reaching the laboratory for PCR analysis (9). Given these caveats, interpretation of PCR results, either positive or negative, must be correlated with the patient's clinical presentation and disease course in determining the ultimate clinical or diagnostic significance of the results. A negative CSF PCR result does not in and of itself rule out neonatal HSV CNS disease.

Given the lack of systematic and large-scale prospective investigation of PCR amplification of CSF specimens in the diagnosis and management of neonates with HSV disease, the clinical significance of positive and of negative CSF PCR results at the end of intravenous therapy has yet to be fully delineated. In the U.S. trial cited above, infants who had HSV DNA detected in the CSF by PCR following completion of intravenous antiviral therapy were more likely to either die or suffer moderate to severe neurologic impairment than were those infants whose post-therapy CSF specimens were PCR negative (Table 3) (46). Differences in disease classifications between the PCR-positive and PCR-negative groups, as well as possible sampling bias (only patients with a clinical indication for repeat lumbar puncture such as persistent seizures, fever, or neurologic deterioration were evaluated) of this retrospective analysis, complicate one's ability to draw definitive conclusions from these findings and further emphasize the need

TABLE 3. PCR results following completion of antiviral therapy^a

Infant characteristic	No. (%) with PCR result		
	Negative ^b	Positive ^c	P
Disease classification			
CNS disease	4 (36.4)	14 (73.7)	<0.001
Disseminated disease	0 (0.0)	5 (26.3)	
SEM disease	7 (63.6)	0 (0.0)	
CSF indices			
Normal	6 (54.5)	1 (5.3)	
Abnormal	3 (27.3)	17 (89.4)	
Morbidity and mortality after 12 mo			
Normal	6 (54.5)	1 (5.3)	<0.001
Mild	0 (0.0)	0 (0.0)	
Moderate	1 (9.1)	3 (15.8)	
Severe	2 (18.2)	10 (52.6)	
Dead	0 (0.0)	5 (26.3)	
Unknown	2 (18.2)	0 (0.0)	

^a Adapted from reference 46 with permission of the publisher.

^b All samples negative after treatment.

^c At least one positive result.

for prospective data on which informed clinical decisions can be based. Nevertheless, the available data suggest that having HSV DNA detected in CSF at or after the completion of intravenous therapy is associated with poor outcomes (46, 58). All patients with CNS HSV involvement should undergo a repeat lumbar puncture at the end of intravenous acyclovir therapy to determine that the specimen is PCR negative in a reliable laboratory and to document the end-of-therapy CSF indices (48). Persons who remain PCR positive should continue to receive intravenous antiviral therapy until PCR negativity is achieved (46, 48).

TREATMENT AND MANAGEMENT

Antiviral Drugs

Mortality. In the preantiviral era, 85% of patients with disseminated neonatal HSV disease died by 1 year of age, as did 50% of patients with CNS neonatal HSV disease (98) (Table 4). Evaluations of two different doses of vidarabine and of a lower dose of acyclovir (30 mg/kg/day for 10 days) documented that both of these antiviral drugs reduce mortality to comparable degrees (92, 98, 102), with mortality rates from disseminated disease and from CNS disease at 1 year decreasing to 54 and 14%, respectively (92) (Table 4). Despite its lack of therapeutic superiority, the lower dose of acyclovir quickly supplanted vidarabine as the treatment of choice for neonatal HSV disease due to its favorable safety profile and its ease of administration. Unlike acyclovir, vidarabine had to be administered over prolonged infusion times and in large volumes of fluid.

With utilization of a higher dose of acyclovir (60 mg/kg/day for 21 days), 12-month mortality was further reduced to 29% for disseminated neonatal HSV disease and to 4% for CNS HSV disease (47) (Fig. 1 and 2, respectively). Differences in mortality at 24 months among patients treated with the higher and lower doses of acyclovir are statistically significant after

TABLE 4. Mortality and morbidity outcomes among 295 infants with neonatal HSV infection, Evaluated by the NIAID Collaborative Antiviral Study Group between 1974 and 1997^a

Extent of disease	No. (%) of patients treated with:			
	Placebo (98)	Vidarabine (92)	Acyclovir (92), 30 mg/kg/day	Acyclovir (47), 60 mg/kg/day
Disseminated disease				
Total	13	28	18	34
Dead	11 (85)	14 (50)	11 (61)	10 (29)
Alive	2 (15)	14 (50)	7 (39)	24 (71)
Normal	1 (50)	7 (50)	3 (43)	15 (63)
Abnormal	1 (50)	5 (36)	2 (29)	3 (13)
Unknown	0 (0)	2 (14)	2 (29)	6 (25)
CNS disease				
Total	6	36	35	23
Dead	3 (50)	5 (14)	5 (14)	1 (4)
Alive	3 (50)	31 (86)	30 (86)	22 (96)
Normal	1 (33)	13 (42)	8 (27)	4 (18)
Abnormal	2 (67)	17 (55)	20 (67)	9 (41)
Unknown	0 (0)	1 (3)	2 (7)	9 (41)
SEM disease				
Total	8	31	54	9
Dead	0 (0)	0 (0)	0 (0)	0 (0)
Alive	8 (100)	31 (100)	54 (100)	9 (100)
Normal	5 (62)	22 (71)	45 (83)	2 (22)
Abnormal	3 (38)	3 (10)	1 (2)	0 (0)
Unknown	0 (0)	6 (19)	8 (15)	7 (78)

^a Adapted from reference 44.

stratification for disease category (CNS versus disseminated) [$P = 0.0035$; odds ratio = 3.3 with 95% confidence interval CI of (1.5, 7.3)] (47). Lethargy and severe hepatitis are associated with mortality among patients with disseminated disease, as are prematurity and seizures in patients with CNS disease (48).

Morbidity. (i) Disseminated and CNS disease. Improvements in morbidity rates with antiviral therapies have not been as dramatic as have improvements in mortality rates. In the preantiviral era, 50% of survivors of disseminated neonatal HSV infections were developing normally at 12 months of age (98) (Table 4). With utilization of the higher dose of acyclovir

for 21 days, this percentage has increased to 83% (47) (Fig. 3). In the case of CNS neonatal HSV disease, 33% of patients in the preantiviral era were developing normally at 12 months of age (Table 4) while 31% of higher-dose acyclovir recipients develop normally at 12 months today (47, 98) (Fig. 3). While these differences are not dramatic, it is important to note that as more neonates survive neonatal HSV disease based on the mortality data presented above, the total numbers of patients who subsequently develop normally is higher today even while the percentages of survivors with normal development are not dramatically different. Seizures at or before the time of initiation of antiviral therapy are associated with increased risk of morbidity both in patients with CNS disease and in patients with disseminated infection (48).

(ii) SEM disease. Unlike disseminated or CNS neonatal HSV disease, morbidity following SEM disease has dramatically improved during the antiviral era. Prior to utilization of antiviral therapies, 38% of SEM patients experienced developmental difficulties at 12 months of age (98) (Table 4). With vidarabine and lower-dose acyclovir, these percentages were reduced to 12 and 2%, respectively (92). In the high-dose acyclovir study, no SEM patients developed neurologic sequelae at 12 months of life (47) (Fig. 3).

In the preantiviral era, 70% of neonates with disease initially limited to skin vesicles experienced progression of disease to involvement of the CNS or visceral organs (99). It is likely that the initial reduction in morbidity among patients with SEM disease from 38% (98) to 2–12% (92) resulted from antiviral therapy impeding this progression to CNS or disseminated disease, each of which carries a higher risk of neurologic sequelae (97). The continued reduction in morbidity among patients with SEM disease seen in the recently completed high-dose acyclovir study might relate to a redefinition of what constitutes SEM versus CNS involvement. Prior to the application of PCR technology to neonatal HSV disease, patients were classified as having SEM disease if they had no overt laboratory or clinical evidence of viral dissemination to the viscera and/or CNS. The lack of CNS involvement was manifest by no CNS symptoms (seizures, abnormal neuroimaging studies, abnormal electroencephalograms, etc.) and normal

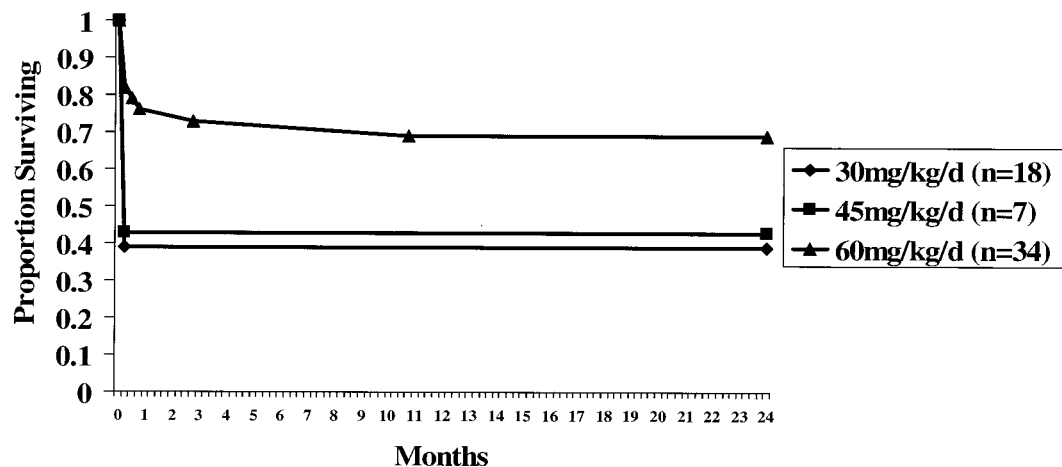


FIG. 1. Mortality in patients with disseminated neonatal HSV disease. Reprinted from reference 47 with permission of the publisher.

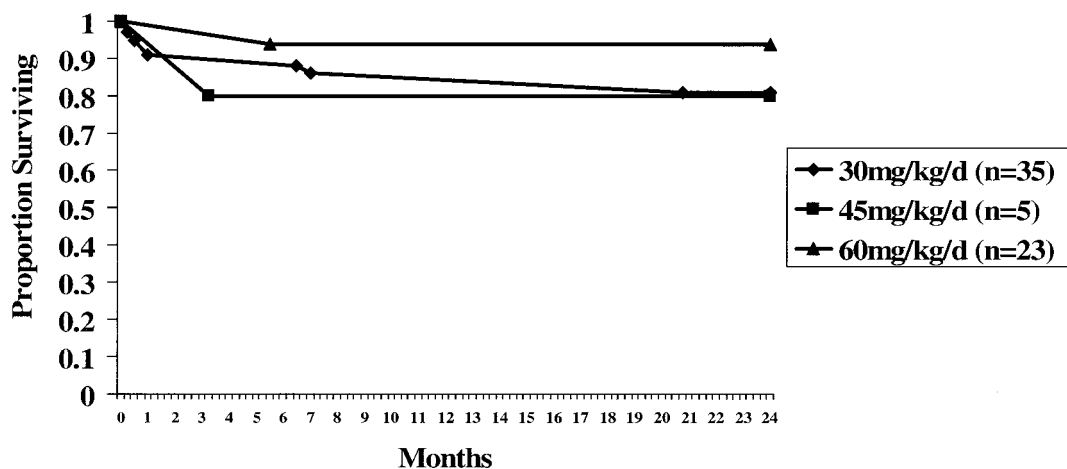


FIG. 2. Mortality in patients with CNS neonatal HSV disease. Reprinted from reference 47 with permission of the publisher.

CSF indices. As discussed above, however, PCR analysis of CSF specimens from neonates classified by these criteria as having SEM disease revealed that approximately one-quarter (7 [24%] of 29) of these infants actually had HSV DNA present in their CSF during the acute disease course (46). One of these seven patients subsequently developed significant neurologic impairment by the age of 12 months. Therefore, it is possible that at least some of the SEM patients in the earlier studies who subsequently developed neurologic impairment actually had subclinical CNS disease, which could be detected only by means of the powerful investigative tool provided in the 1990s by the development of PCR. These data have resulted in a revised classification of CNS disease, such that a positive CSF PCR result is now sufficient to classify a patient as having CNS HSV infection.

Another possible explanation for the neurologic impairment previously experienced by some infants with SEM disease could be that while low-level viremia from the cutaneous lesions results in seeding of the CNS, initial damage to brain tissue during the acute illness does not occur, either due to a host response to infection or due to antiviral therapy. Subclinical reactivation of virus within the CNS, with or without a clinical cutaneous recurrence, might then cause neurologic impairment, as suggested previously (44, 93). Supporting this

hypothesis, HSV DNA has been detected in the CSF of an infant with SEM disease at the time of a cutaneous recurrence (42). Randomized, controlled studies of long-term suppressive oral acyclovir therapy following the acute neonatal disease are currently being conducted by the NIAID Collaborative Antiviral Study Group to evaluate this hypothesis. At present, however, no evidence exists to suggest that suppressive oral acyclovir therapy is beneficial in preventing neurological complications. Furthermore, almost half of the infants receiving oral acyclovir in an open-label phase I/II investigation developed neutropenia during therapy (42), raising substantial questions about the safety of such a therapeutic approach outside of the strictly monitored confines of a clinical investigation.

Summary of current treatment. The improvements in mortality and morbidity achieved with the use of higher-dose acyclovir support the use of acyclovir at 60 mg/kg/day delivered intravenously in three divided daily doses, as currently recommended (1, 47). The dosing interval of intravenous acyclovir may have to be increased in premature infants, based on their creatinine clearance (31). The duration of therapy is 21 days for patients with disseminated or CNS neonatal HSV disease and 14 days for patients with HSV infection limited to the SEM (1). As noted above, all patients with CNS HSV involvement should have a repeat lumbar puncture at the end of

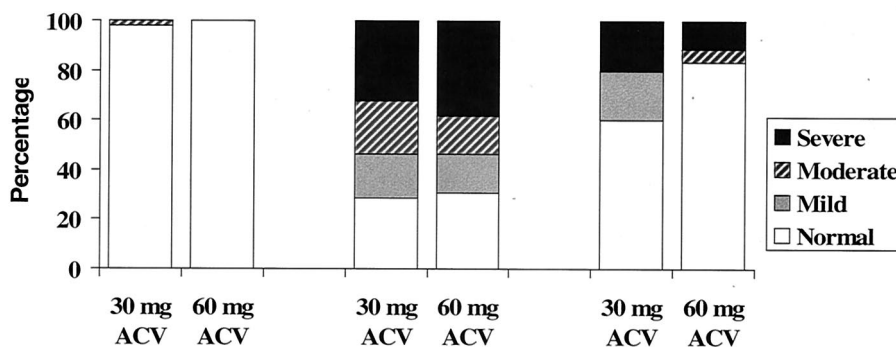


FIG. 3. Morbidity among patients with known outcomes after 12 months of life. ACV, acyclovir. Reprinted from reference 47 with permission of the publisher.

intravenous acyclovir therapy to determine that the specimen is PCR negative as ascertained in a reliable laboratory and to document the end-of-therapy CSF indices (48). Persons who remain PCR positive should continue to receive intravenous antiviral therapy until PCR negativity is achieved (46, 48).

The primary apparent toxicity associated with the use of intravenous acyclovir administered at 60 mg/kg/day is neutropenia, with approximately one-fifth of patients developing an absolute neutrophil count of $\leq 1,000/\mu\text{l}$ (47). Although the neutropenia resolves either during continuation of intravenous acyclovir therapy or following its cessation, it is prudent to monitor the neutrophil counts at least twice weekly throughout the course of intravenous acyclovir therapy, with consideration being given to decreasing the dose of acyclovir or administering granulocyte colony-stimulating factor if the absolute neutrophil count remains below $500/\mu\text{l}$ for a prolonged period (47).

Antibody Therapy

Future therapeutic options for further improvement in the management of neonatal HSV disease may reside in the utilization of passive immunotherapy as an adjuvant to active antiviral interventions. Both human and humanized monoclonal antibodies directed against gB or gD are beneficial in animal models of HSV disease (12, 19). Studies with humans have documented the protective effects of high titers of neutralizing antibodies, with neonates with higher neutralizing antibody titers being less likely to become infected with HSV following perinatal exposure (70) and being more likely to have localized disease (and less likely to have disseminated disease) once they are infected (52, 84). While antibody therapy offers promise for improving disease prevention and outcome, studies of humans have yet to be carried out. In addition, an HSV hyperimmune globulin preparation does not exist, and the amount of anti-HSV antibodies present in conventional intravenous gamma globulin preparations is variable. For these reasons, the use of intravenous gamma globulin in the management of neonates with HSV disease cannot be recommended at this time. A monoclonal antibody directed against gD has been produced and may be available for clinical investigation as an adjuvant therapeutic agent by the NIAID Collaborative Antiviral Study Group in future years.

PREVENTION

Cesarean Delivery

As noted above, cesarean delivery in women with active genital lesions can reduce the infant's risk of acquiring HSV (24, 62). In 1999, the American College of Obstetricians and Gynecologists updated its management guidelines for genital herpes in pregnancy (3). To prevent neonatal HSV disease, cesarean section should be performed if genital HSV lesions or prodromal symptoms are present at the time of delivery. As a method to reduce the incidence of neonatal HSV disease, however, cesarean delivery has a number of drawbacks, including the fact that 60 to 80% of babies who develop neonatal HSV disease are born to women without a history of genital herpes (97, 99, 104), and thus infection in these babies may not

be prevented by this approach. Furthermore, women with recurrent infections who are shedding virus at the time of delivery are at low risk of their babies developing neonatal HSV disease (21, 23, 24, 28, 62), as discussed above. Decision analyses estimate that 1,580 excess cesarean section deliveries are performed for every poor neonatal outcome prevented, 0.57 maternal death occurs for every neonatal death prevented, and an estimated \$2.5 million is spent for every neonatal case averted by this approach (71, 72). These figures contrast with ones regarding cesarean deliveries for women with no history of genital herpes, which result in only nine excess cesarean deliveries per poor neonatal outcome prevented and 0.004 maternal death for every neonatal death prevented. The issue of cesarean delivery is complicated even further by the fact that neonatal infection has occurred in spite of cesarean delivery performed prior to the rupture of membranes (97).

Antiviral Prophylaxis during Pregnancy

Because of the safety record of acyclovir in pregnancy, along with a desire to decrease neonatal HSV disease and reduce the number of cesarean deliveries performed for the indication of herpes, utilization of oral acyclovir near the end of pregnancy to suppress genital HSV recurrences has become increasingly common in clinical practice. Over a 14-year period from 1984 to 1998, the Acyclovir in Pregnancy Registry recorded outcomes of pregnancies in which in utero exposure to acyclovir or valacyclovir occurred (74). No differences were seen with respect to fetal outcomes or birth defects, although the numbers of subjects in the registry were too small to draw definitive conclusions. During the course of this registry, deliberate utilization of acyclovir near the end of pregnancy to suppress genital HSV recurrences became increasingly common in clinical practice, and several small studies investigated the use of acyclovir suppressive therapy during the last weeks of pregnancy (18, 20, 78, 79, 83). These trials suggest that suppressive treatment decreases the occurrence of clinically apparent genital HSV disease at the time of delivery (18, 78, 79), with an associated decrease in cesarean section rates for the indication of genital HSV among women receiving active drug (18, 79, 83). However, they are too small for us to draw definitive conclusions regarding safety and efficacy in treating a disease such as genital herpes which affects one-quarter of the U.S. population. Furthermore, subclinical shedding is not fully suppressed in patients studied to date (20), suggesting that neonatal transmission is likely to still be possible despite antiviral suppression in the mother. Acyclovir concentrations in cord blood of babies whose mothers have received valacyclovir approach levels that have appeared to cause significant neutropenia in infants receiving long-term oral acyclovir suppressive therapy following neonatal HSV disease (42, 43). While neutropenia has yet to be observed among infants born to the small number of gravid women in trials of acyclovir suppressive therapy, ongoing studies continue to investigate this possibility. At present, the safety to the fetus of antiviral suppression in the gravid woman is unproven, and additional studies are needed to more definitively establish the effectiveness and safety of late-pregnancy maternal HSV suppression, including the potential for neutropenia in neonates born to women re-

ceiving antiviral suppressive therapy (D. W. Kimberlin, Abstract SAT 12, *Int. J. STD AIDS* 13 (Suppl. 1): 60, 2002).

Vaccine Development

A number of efforts have been made to create a vaccine for genital herpes. Until recently, all had been failures. However, a candidate HSV-2 gD subunit vaccine adjuvanted with alum combined with 3-deacylated monophosphoryl lipid A has recently demonstrated promising results. In two large phase III studies, the vaccine has been demonstrated to be safe and, in a subset of volunteers, effective in preventing HSV-1 or HSV-2 genital herpes disease (vaccine efficacy, ~75%) and HSV-2 infection (vaccine efficacy, ~40%) (80). In both studies, efficacy was limited to women who were HSV-1 and HSV-2 seronegative prior to vaccination. There was no evidence of vaccine efficacy in men or in women who were HSV-1 positive but HSV-2 negative prior to vaccination. Because these earlier trials were neither designed nor powered to assess efficacy in women who were HSV-1 and HSV-2 negative, another phase III trial is being undertaken by GlaxoSmithKline and NIAID.

CONCLUSIONS

Tremendous advances in the diagnosis and management of neonatal HSV disease have occurred over the past 30 years. Mortality in patients with disseminated disease has decreased from 85 to 29%, and that in patients with CNS disease has decreased from 50 to 4%. Morbidity has been improved more modestly, with the proportion of patients with disseminated disease who are developing normally at 1 year of age increasing from 50 to 83%. While the proportion of patients with neurologic morbidity following CNS disease has remained essentially unchanged over the past three decades, the total number of patients who are developing normally following HSV CNS disease has increased due to the improved survival. While additional therapeutic advances are possible in the future, more immediate methods for further improvements in outcome for this potentially devastating disease lie in enhancing our awareness of neonatal HSV infection and disease. Educational efforts focusing on these aims and based on an understanding of the biology and natural history of HSV in the gravid woman and the neonate should be systematically undertaken.

ACKNOWLEDGMENTS

This work was supported under contract with the Virology Branch, Division of Microbiology and Infectious Diseases of the National Institute of Allergy and Infectious Diseases (NIAID), NO1-AI-15113 and NO1-AI-62554, and by grants from the General Clinical Research Center Program (RR-032) and the State of Alabama.

REFERENCES

- American Academy of Pediatrics. 2000. Herpes simplex, p. 309-318. *In* L. K. Pickering (ed.), 2000 Red Book: report of the Committee on Infectious Diseases, 25th ed. American Academy of Pediatrics, Elk Grove Village, Ill.
- Anderson, N. E., K. F. Powell, and M. C. Croxson. 1993. A polymerase chain reaction assay of cerebrospinal fluid in patients with suspected herpes simplex encephalitis. *J. Neurol. Neurosurg. Psychiatry* 56:520-525.
- Anonymous. 2000. ACOG practice bulletin. Management of herpes in pregnancy, no. 8, October 1999. Clinical management guidelines for obstetrician-gynecologists. *Int. J. Gynaecol. Obstet.* 68:165-173.
- Arvin, A. M., P. A. Hensleigh, C. G. Prober, D. S. Au, L. L. Yasukawa, A. E. Witte, P. E. Palumbo, S. G. Paryani, and A. S. Yeager. 1986. Failure of antepartum maternal cultures to predict the infant's risk of exposure to herpes simplex virus at delivery. *N. Engl. J. Med.* 315:796-800.
- Arvin, A. M., A. S. Yeager, F. W. Bruhn, and M. Grossman. 1982. Neonatal herpes simplex infection in the absence of mucocutaneous lesions. *J. Pediatr.* 100:715-721.
- Ashley, R. L. 2001. Sorting out the new HSV type specific antibody tests. *Sex. Transm. Infect.* 77:232-237.
- Ashley, R. L., and M. Eagleton. 1998. Evaluation of a novel point of care test for antibodies to herpes simplex virus type 2. *Sex. Transm. Infect.* 74:228-229.
- Ashley, R. L., A. Wald, and M. Eagleton. 2000. Premarket evaluation of the POCkit HSV-2 type-specific serologic test in culture-documented cases of genital herpes simplex virus type 2. *Sex. Transm. Dis.* 27:266-269.
- Atkins, J. T. 1999. HSV PCR for CNS infections: pearls and pitfalls. *Pediatr. Infect. Dis. J.* 18:823-824.
- Baldwin, S., and R. J. Whitley. 1989. Intrauterine herpes simplex virus infection. *Teratology* 39:1-10.
- Barbi, M., S. Binda, V. Primache, A. Tettamanti, C. Negri, and C. Brambilla. 1998. Use of Guthrie cards for the early diagnosis of neonatal herpes simplex virus disease. *Pediatr. Infect. Dis. J.* 17:251-252.
- Baron, S., M. G. Worthington, J. Williams, and J. W. Gaines. 1976. Post-exposure serum prophylaxis of neonatal herpes simplex virus infection of mice. *Nature* 261:505-506.
- Barton, I. G., G. R. Kinghorn, S. Najem, L. S. Al-Omar, and C. W. Potter. 1982. Incidence of herpes simplex virus types 1 and 2 isolated in patients with herpes genitalis in Sheffield. *Br. J. Vener. Dis.* 58:44-47.
- Batignani, A. 1934. Conjunctivite da virus erpetico in neonato. *Boll. Ocul.* 13:1217.
- Bolognese, R. J., S. L. Corson, D. A. Fucillo, R. Traub, F. Moder, and J. L. Sever. 1976. Herpesvirus hominis type II infections in asymptomatic pregnant women. *Obstet. Gynecol.* 48:507-510.
- Boston Interhospital Virus Study Group. 1975. An NIAID-sponsored cooperative antiviral clinical study: failure of high dose 5-iodo-2'-deoxyuridine in the therapy of herpes simplex virus encephalitis. Evidence of unacceptable toxicity. *N. Engl. J. Med.* 292:599-603.
- Boucher, F. D., L. L. Yasukawa, R. N. Bronzan, P. A. Hensleigh, A. M. Arvin, and C. G. Prober. 1990. A prospective evaluation of primary genital herpes simplex virus type 2 infections acquired during pregnancy. *Pediatr. Infect. Dis. J.* 9:499-504.
- Braig, S., D. Luton, O. Sibony, C. Edlinger, C. Boissinot, P. Blot, and J. F. Oury. 2001. Acyclovir prophylaxis in late pregnancy prevents recurrent genital herpes and viral shedding. *Eur. J. Obstet. Gynecol. Reprod. Biol.* 96:55-58.
- Bravo, F. J., N. Bourne, C. J. Harrison, C. Mani, L. R. Stanberry, M. G. Myers, and D. I. Bernstein. 1996. Effect of antibody alone and combined with acyclovir on neonatal herpes simplex virus infection in guinea pigs. *J. Infect. Dis.* 173:1-6.
- Brocklehurst, P., G. Kinghorn, O. Carney, K. Helsen, E. Ross, E. Ellis, R. Shen, F. Cowan, and A. Mindel. 1998. A randomised placebo controlled trial of suppressive acyclovir in late pregnancy in women with recurrent genital herpes infection. *Br. J. Obstet. Gynaecol.* 105:275-280.
- Brown, Z. A., J. Benedetti, R. Ashley, S. Burchett, S. Selke, S. Berry, L. A. Vontver, and L. Corey. 1991. Neonatal herpes simplex virus infection in relation to asymptomatic maternal infection at the time of labor. *N. Engl. J. Med.* 324:1247-1252.
- Brown, Z. A., S. Selke, J. Zeh, J. Kopelman, A. Maslow, R. L. Ashley, D. H. Watts, S. Berry, M. Herd, and L. Corey. 1997. The acquisition of herpes simplex virus during pregnancy. *N. Engl. J. Med.* 337:509-515.
- Brown, Z. A., L. A. Vontver, J. Benedetti, C. W. Critchlow, C. J. Sells, S. Berry, and L. Corey. 1987. Effects on infants of a first episode of genital herpes during pregnancy. *N. Engl. J. Med.* 317:1246-1251.
- Brown, Z. A., A. Wald, R. A. Morrow, S. Selke, J. Zeh, and L. Corey. 2003. Effect of serologic status and cesarean delivery on transmission rates of herpes simplex virus from mother to infant. *JAMA* 289:203-209.
- Cheong, W. K., T. Thirumoorthy, S. Doraisingham, and A. E. Ling. 1990. Clinical and laboratory study of first episode genital herpes in Singapore. *Int. J. STD AIDS* 1:195-198.
- Corey, L., H. G. Adams, Z. A. Brown, and K. K. Holmes. 1983. Genital herpes simplex virus infections: clinical manifestations, course, and complications. *Ann. Intern. Med.* 98:958-972.
- Reference deleted.
- Corey, L., and A. Wald. 1999. Genital herpes, p. 285-312. *In* K. K. Holmes, P. F. Sparling, P. A. Mardh, S. M. Lemon, W. E. Stamm, P. Piot, and J. N. Wasserheit (ed.), Sexually transmitted Diseases, 3rd ed. McGraw-Hill, New York, N.Y.
- Deardourff, S. L., F. A. Deture, D. M. Drylie, Y. Centifano, and H. Kaufman. 1974. Association between herpes hominis type 2 and the male genitourinary tract. *J. Urol.* 112:126-127.
- Diamond, C., K. Mohan, A. Hobson, L. Frenkel, and L. Corey. 1999. Viremia in neonatal herpes simplex virus infections. *Pediatr. Infect. Dis. J.* 18:487-489.

31. Englund, J. A., C. V. Fletcher, and H. H. Balfour, Jr. 1991. Acyclovir therapy in neonates. *J. Pediatr.* **119**:129-135.
32. Fleming, D. T., G. M. McQuillan, R. E. Johnson, A. J. Nahmias, S. O. Aral, F. K. Lee, and M. E. St Louis. 1997. Herpes simplex virus type 2 in the United States, 1976 to 1994. *N. Engl. J. Med.* **337**:1105-1111.
33. Florman, A. L., A. A. Gershon, P. R. Blackett, and A. J. Nahmias. 1973. Intrauterine infection with herpes simplex virus. Resultant congenital malformations. *JAMA* **225**:129-132.
34. Glezen, W. P., G. W. Fernald, and J. A. Lohr. 1975. Acute respiratory disease of university students with special reference to the etiologic role of Herpesvirus hominis. *Am. J. Epidemiol.* **101**:111-121.
35. Hass, M. 1935. Hepatoadrenal necrosis with intranuclear inclusion bodies: report of a case. *Am. J. Pathol.* **11**:127.
36. Hutto, C., A. Arvin, R. Jacobs, R. Steele, S. Stagno, R. Lyrene, L. Willett, D. Powell, R. Andersen, and J. Werthammer. 1987. Intrauterine herpes simplex virus infections. *J. Pediatr.* **110**:97-101.
37. Johnson, R. E., A. J. Nahmias, L. S. Magder, F. K. Lee, C. A. Brooks, and C. B. Snowden. 1989. A seroepidemiologic survey of the prevalence of herpes simplex virus type 2 infection in the United States. *N. Engl. J. Med.* **321**:7-12.
38. Josey, W. E., A. J. Nahmias, and Z. M. Naib. 1972. The epidemiology of type 2 (genital) herpes simplex virus infection. *Obstet. Gynecol. Surv.* **27**(Suppl):295-302.
39. Josey, W. E., A. J. Nahmias, Z. M. Naib, P. M. Utley, W. J. McKenzie, and M. T. Coleman. 1966. Genital herpes simplex infection in the female. *Am. J. Obstet. Gynecol.* **96**:493-501.
40. Karesh, J. W., S. Kapur, and M. MacDonald. 1983. Herpes simplex virus and congenital malformations. *South. Med. J.* **76**:1561-1563.
41. Kaye, E. M., and E. C. Dooling. 1981. Neonatal herpes simplex meningoencephalitis associated with fetal monitor scalp electrodes. *Neurology* **31**:1045-1047.
42. Kimberlin, D., D. Powell, W. Gruber, P. Diaz, A. Arvin, M. Kumar, R. Jacobs, R. Van Dyke, S. Burchett, S. J. Soong, A. Lakeman, R. Whitley, and The National Institute of Allergy and Infectious Diseases Collaborative Antiviral Study Group. 1996. Administration of oral acyclovir suppressive therapy after neonatal herpes simplex virus disease limited to the skin, eyes and mouth: results of a phase I/II trial. *Pediatr. Infect. Dis. J.* **15**:247-254.
43. Kimberlin, D., S. Weller, R. J. Whitley, W. W. Andrews, J. C. Hauth, F. Lakeman, and G. Miller. 1998. Pharmacokinetics of oral valacyclovir and acyclovir in late pregnancy. *Am. J. Obstet. Gynecol.* **179**:846-851.
44. Kimberlin, D. W. 2001. Advances in the treatment of neonatal herpes simplex infections. *Rev. Med. Virol.* **11**:157-163.
45. Reference deleted.
46. Kimberlin, D. W., F. D. Lakeman, A. M. Arvin, C. G. Prober, L. Corey, D. A. Powell, S. K. Burchett, R. F. Jacobs, S. E. Starr, R. J. Whitley, and The National Institute of Allergy and Infectious Diseases Collaborative Antiviral Study Group. 1996. Application of the polymerase chain reaction to the diagnosis and management of neonatal herpes simplex virus disease. *J. Infect. Dis.* **174**:1162-1167.
47. Kimberlin, D. W., C. Y. Lin, R. F. Jacobs, D. A. Powell, L. Corey, W. C. Gruber, M. Rathore, J. S. Bradley, P. S. Diaz, M. Kumar, A. M. Arvin, K. Gutierrez, M. Shelton, L. B. Weiner, J. W. Sleasman, T. M. de Sierra, S. J. Soong, J. Kiell, F. D. Lakeman, R. J. Whitley, and The National Institute of Allergy and Infectious Diseases Collaborative Antiviral Study Group. 2001. Safety and efficacy of high-dose intravenous acyclovir in the management of neonatal herpes simplex virus infections. *Pediatrics* **108**:230-238.
48. Kimberlin, D. W., C. Y. Lin, R. F. Jacobs, D. A. Powell, L. M. Frenkel, W. C. Gruber, M. Rathore, J. S. Bradley, P. S. Diaz, M. Kumar, A. M. Arvin, K. Gutierrez, M. Shelton, L. B. Weiner, J. W. Sleasman, T. M. de Sierra, S. J. Soong, J. Kiell, F. D. Lakeman, R. J. Whitley, and The National Institute of Allergy and Infectious Diseases Collaborative Antiviral Study Group. 2001. Natural history of neonatal herpes simplex virus infections in the acyclovir era. *Pediatrics* **108**:223-229.
49. Kimberlin, D. W., and C. G. Prober. 2003. Antiviral agents, p. 1527-1547. *In* S. S. Long, L. K. Pickering, and C. G. Prober (ed.), *Principles and practice of pediatric infectious diseases*, 2nd ed. Churchill Livingstone, Philadelphia, Pa.
50. Kimura, H., M. Futamura, H. Kito, T. Ando, M. Goto, K. Kuzushima, M. Shibata, and T. Morishima. 1991. Detection of viral DNA in neonatal herpes simplex virus infections: frequent and prolonged presence in serum and cerebrospinal fluid. *J. Infect. Dis.* **164**:289-293.
51. Kinghorn, G. R. 1998. Type-specific serological testing for herpes simplex infection. *Int. J. STD AIDS* **9**:497-500.
52. Kohl, S., M. S. West, C. G. Prober, W. M. Sullender, L. S. Loo, and A. M. Arvin. 1989. Neonatal antibody-dependent cellular cytotoxic antibody levels are associated with the clinical presentation of neonatal herpes simplex virus infection. *J. Infect. Dis.* **160**:770-776.
53. Kulhanjian, J. A., V. Soroush, D. S. Au, R. N. Bronzan, L. L. Yasukawa, L. E. Weylman, A. M. Arvin, and C. G. Prober. 1992. Identification of women at unsuspected risk of primary infection with herpes simplex virus type 2 during pregnancy. *N. Engl. J. Med.* **326**:916-920.
54. Lafferty, W. E., L. Downey, C. Celum, and A. Wald. 2000. Herpes simplex virus type 1 as a cause of genital herpes: impact on surveillance and prevention. *J. Infect. Dis.* **181**:1454-1457.
55. Leach, C. T., R. L. Ashley, J. Baillargeon, and H. B. Jensen. 2002. Performance of two commercial glycoprotein G-based enzyme immunoassays for detecting antibodies to herpes simplex viruses 1 and 2 in children and young adolescents. *Clin. Diagn. Lab. Immunol.* **9**:1124-1125.
56. Lee, F. K., R. M. Coleman, L. Pereira, P. D. Bailey, M. Tatsuno, and A. J. Nahmias. 1985. Detection of herpes simplex virus type 2-specific antibody with glycoprotein G. *J. Clin. Microbiol.* **22**:641-644.
57. Lowhagen, G. B., P. Tunback, K. Andersson, T. Bergstrom, and G. Johansson. 2000. First episodes of genital herpes in a Swedish STD population: a study of epidemiology and transmission by the use of herpes simplex virus (HSV) typing and specific serology. *Sex. Transm. Infect.* **76**:179-182.
58. Malm, G., and M. Forsgren. 1999. Neonatal herpes simplex virus infections: HSV DNA in cerebrospinal fluid and serum. *Arch. Dis. Child. Fetal Neonatal Ed.* **81**:F24-F29.
59. Markert, J. M., G. Y. Gillespie, R. R. Weichselbaum, B. Roizman, and R. J. Whitley. 2000. Genetically engineered HSV in the treatment of glioma: a review. *Rev. Med. Virol.* **10**:17-30.
60. Markert, J. M., M. D. Medlock, S. D. Rabkin, G. Y. Gillespie, T. Todo, W. D. Hunter, C. A. Palmer, F. Feigenbaum, C. Tornatore, F. Tufaro, and R. L. Martuza. 2000. Conditionally replicating herpes simplex virus mutant, G207 for the treatment of malignant glioma: results of a phase I trial. *Gene Ther.* **7**:867-874.
61. Monif, G. R., K. R. Kellner, and W. H. Donnelly, Jr. 1985. Congenital herpes simplex type II infection. *Am. J. Obstet. Gynecol.* **152**:1000-1002.
62. Nahmias, A. J., W. E. Josey, Z. M. Naib, M. G. Freeman, R. J. Fernandez, and J. H. Wheeler. 1971. Perinatal risk associated with maternal genital herpes simplex virus infection. *Am. J. Obstet. Gynecol.* **110**:825-837.
63. Nahmias, A. J., H. L. Keyserling, and G. M. Kerrick. 1983. Herpes simplex, p. 636-678. *In* J. S. Remington and J. O. Klein (ed.), *Infectious diseases of the fetus and newborn infants*, 2nd ed. The W. B. Saunders Co., Philadelphia, Pa.
64. Nahmias, A. J., F. K. Lee, and S. Beckman-Nahmias. 1990. Sero-epidemiological and sociological patterns of herpes simplex virus infection in the world. *Scand. J. Infect. Dis. Suppl.* **69**:19-36.
65. Nilsen, A., and H. Myrmed. 2000. Changing trends in genital herpes simplex virus infection in Bergen, Norway. *Acta Obstet. Gynecol. Scand.* **79**:693-696.
66. Parker, J. D., and J. E. Banatvala. 1967. Herpes genitalis; clinical and virological studies. *Br. J. Vener. Dis.* **43**:212-216.
67. Parvey, L. S., and L. T. Ch'ien. 1980. Neonatal herpes simplex virus infection introduced by fetal-monitor scalp electrodes. *Pediatrics* **65**:1150-1153.
68. Prince, H. E., C. E. Ernst, and W. R. Hogrefe. 2000. Evaluation of an enzyme immunoassay system for measuring herpes simplex virus (HSV) type 1-specific and HSV type 2-specific IgG antibodies. *J. Clin. Lab. Anal.* **14**:13-16.
69. Prober, C. G., P. A. Hensleigh, F. D. Boucher, L. L. Yasukawa, D. S. Au, and A. M. Arvin. 1988. Use of routine viral cultures at delivery to identify neonates exposed to herpes simplex virus. *N. Engl. J. Med.* **318**:887-891.
70. Prober, C. G., W. M. Sullender, L. L. Yasukawa, D. S. Au, A. S. Yeager, and A. M. Arvin. 1987. Low risk of herpes simplex virus infections in neonates exposed to the virus at the time of vaginal delivery to mothers with recurrent genital herpes simplex virus infections. *N. Engl. J. Med.* **316**:240-244.
71. Randolph, A. G., R. M. Hartshorn, and A. E. Washington. 1996. Acyclovir prophylaxis in late pregnancy to prevent neonatal herpes: a cost-effectiveness analysis. *Obstet. Gynecol.* **88**:603-610.
72. Randolph, A. G., A. E. Washington, and C. G. Prober. 1993. Cesarean delivery for women presenting with genital herpes lesions. Efficacy, risks, and costs. *JAMA* **270**:77-82.
73. Reeves, W. C., L. Corey, H. G. Adams, L. A. Vontver, and K. K. Holmes. 1981. Risk of recurrence after first episodes of genital herpes. Relation to HSV type and antibody response. *N. Engl. J. Med.* **305**:315-319.
74. Reiff-Eldridge, R., C. R. Heffner, S. A. Ephross, P. S. Tennis, A. D. White, and E. B. Andrews. 2000. Monitoring pregnancy outcomes after prenatal drug exposure through prospective pregnancy registries: a pharmaceutical company commitment. *Am. J. Obstet. Gynecol.* **182**:159-163.
75. Ross, J. D., I. W. Smith, and R. A. Elton. 1993. The epidemiology of herpes simplex types 1 and 2 infection of the genital tract in Edinburgh 1978-1991. *Genitourin. Med.* **69**:381-383.
76. Rowley, A. H., R. J. Whitley, F. D. Lakeman, and S. M. Wolinsky. 1990. Rapid detection of herpes-simplex-virus DNA in cerebrospinal fluid of patients with herpes simplex encephalitis. *Lancet* **335**:440-441.
77. Schlesinger, Y., and G. A. Storch. 1994. Herpes simplex meningitis in infancy. *Pediatr. Infect. Dis. J.* **13**:141-144.
78. Scott, L. L., L. M. Hollier, D. McIntire, P. J. Sanchez, G. L. Jackson, and G. D. Wendel, Jr. 2002. Acyclovir suppression to prevent recurrent genital herpes at delivery. *Infect. Dis. Obstet. Gynecol.* **10**:71-77.
79. Scott, L. L., P. J. Sanchez, G. L. Jackson, F. Zeray, and G. D. Wendel, Jr. 1996. Acyclovir suppression to prevent cesarean delivery after first-episode genital herpes. *Obstet. Gynecol.* **87**:69-73.

80. Stanberry, L. R., S. L. Spruance, A. L. Cunningham, D. I. Bernstein, A. Mindel, S. Sacks, S. Tyring, F. Y. Aoki, M. Slaoui, M. Denis, P. Vandepapeliere, G. Dubin, and The GlaxoSmithKline Herpes Vaccine Efficacy Study Group. 2002. Glycoprotein-D-adjuvant vaccine to prevent genital herpes. *N. Engl. J. Med.* **347**:1652–1661.
81. Stevens, D. A., G. W. Jordan, T. F. Waddell, and T. C. Merigan. 1973. Adverse effect of cytosine arabinoside on disseminated zoster in a controlled trial. *N. Engl. J. Med.* **289**:873–878.
82. Stevens, J. G., and M. L. Cook. 1971. Latent herpes simplex virus in spinal ganglia of mice. *Science* **173**:843–845.
83. Stray-Pedersen, B. 1990. Acyclovir in late pregnancy to prevent neonatal herpes simplex. *Lancet* **336**:756.
84. Sullender, W. M., J. L. Miller, L. L. Yasukawa, J. S. Bradley, S. B. Black, A. S. Yeager, and A. M. Arvin. 1987. Humoral and cell-mediated immunity in neonates with herpes simplex virus infection. *J. Infect. Dis.* **155**:28–37.
85. Sullivan-Bolyai, J., H. F. Hull, C. Wilson, and L. Corey. 1983. Neonatal herpes simplex virus infection in King County, Washington. Increasing incidence and epidemiologic correlates. *JAMA* **250**:3059–3062.
86. Sullivan-Bolyai, J. Z., H. F. Hull, C. Wilson, A. L. Smith, and L. Corey. 1986. Presentation of neonatal herpes simplex virus infections: implications for a change in therapeutic strategy. *Pediatr. Infect. Dis.* **5**:309–314.
87. Thompson, C. 2000. Genital herpes simplex typing in genitourinary medicine: 1995–1999. *Int. J. STD AIDS* **11**:501–502.
88. Troendle-Atkins, J., G. J. Demmler, and G. J. Buffone. 1993. Rapid diagnosis of herpes simplex virus encephalitis by using the polymerase chain reaction. *J. Pediatr.* **123**:376–380.
89. Vontver, L. A., D. E. Hickok, Z. Brown, L. Reid, and L. Corey. 1982. Recurrent genital herpes simplex virus infection in pregnancy: infant outcome and frequency of asymptomatic recurrences. *Am. J. Obstet. Gynecol.* **143**:75–84.
90. Wald, A., L. Corey, R. Cone, A. Hobson, G. Davis, and J. Zeh. 1997. Frequent genital herpes simplex virus 2 shedding in immunocompetent women. Effect of acyclovir treatment. *J. Clin. Investig.* **99**:1092–1097.
91. Wald, A., A. G. Langenberg, K. Link, A. E. Izu, R. Ashley, T. Warren, S. Tyring, J. M. Douglas, Jr., and L. Corey. 2001. Effect of condoms on reducing the transmission of herpes simplex virus type 2 from men to women. *JAMA* **285**:3100–3106.
92. Whitley, R., A. Arvin, C. Prober, S. Burchett, L. Corey, D. Powell, S. Plotkin, S. Starr, C. Alford, J. Connor, and The National Institute of Allergy and Infectious Diseases Collaborative Antiviral Study Group. 1991. A controlled trial comparing vidarabine with acyclovir in neonatal herpes simplex virus infection. *N. Engl. J. Med.* **324**:444–449.
93. Whitley, R., A. Arvin, C. Prober, L. Corey, S. Burchett, S. Plotkin, S. Starr, R. Jacobs, D. Powell, A. Nahmias, and The National Institute of Allergy and Infectious Diseases Collaborative Antiviral Study Group. 1991. Predictors of morbidity and mortality in neonates with herpes simplex virus infections. *N. Engl. J. Med.* **324**:450–454.
94. Whitley, R. J. 1990. Herpes simplex virus infections, p. 282–305. *In* J. S. Remington and J. O. Klein (ed.), *Infectious diseases of the fetus and newborn infants*, 3rd ed. The W. B. Saunders Co., Philadelphia, Pa.
95. Whitley, R. J. 1996. Herpes simplex viruses, p. 2297–2342. *In* B. N. Fields, D. M. Knipe, P. M. Howley, R. M. Chanock, J. L. Melnick, T. P. Monath, B. Roizman, and S. E. Straus (ed.), *Fields virology*, 3rd ed., vol. 2. Lippincott-Raven Publishers, Philadelphia, Pa.
96. Whitley, R. J., L. T. Ch'ien, R. Dolin, G. J. Galasso, and C. A. Alford, Jr. 1976. Adenine arabinoside therapy of herpes zoster in the immunosuppressed. NIAID collaborative antiviral study. *N. Engl. J. Med.* **294**:1193–1199.
97. Whitley, R. J., L. Corey, A. Arvin, F. D. Lakeman, C. V. Sumaya, P. F. Wright, L. M. Dunkle, R. W. Steele, S. J. Soong, and A. J. Nahmias. 1988. Changing presentation of herpes simplex virus infection in neonates. *J. Infect. Dis.* **158**:109–116.
98. Whitley, R. J., A. J. Nahmias, S. J. Soong, G. G. Galasso, C. L. Fleming, and C. A. Alford. 1980. Vidarabine therapy of neonatal herpes simplex virus infection. *Pediatrics* **66**:495–501.
99. Whitley, R. J., A. J. Nahmias, A. M. Visintine, C. L. Fleming, and C. A. Alford. 1980. The natural history of herpes simplex virus infection of mother and newborn. *Pediatrics* **66**:489–494.
100. Whitley, R. J., S. J. Soong, R. Dolin, R. Betts, C. Linnemann, Jr., and C. A. Alford, Jr. 1982. Early vidarabine therapy to control the complications of herpes zoster in immunosuppressed patients. *N. Engl. J. Med.* **307**:971–975.
101. Whitley, R. J., S. J. Soong, R. Dolin, G. J. Galasso, L. T. Ch'ien, C. A. Alford, and The National Institute of Allergy and Infectious Diseases Collaborative Antiviral Study Group. 1977. Adenine arabinoside therapy of biopsy-proved herpes simplex encephalitis. *N. Engl. J. Med.* **297**:289–294.
102. Whitley, R. J., A. Yeager, P. Kartus, Y. Bryson, J. D. Connor, C. A. Alford, A. Nahmias, and S. J. Soong. 1983. Neonatal herpes simplex virus infection: follow-up evaluation of vidarabine therapy. *Pediatrics* **72**:778–785.
103. Wutzler, P., H. W. Doerr, I. Farber, U. Eichhorn, B. Helbig, A. Sauerbrei, A. Brandstadt, and H. F. Rabenau. 2000. Seroprevalence of herpes simplex virus type 1 and type 2 in selected German populations—relevance for the incidence of genital herpes. *J. Med. Virol.* **61**:201–207.
104. Yeager, A. S., and A. M. Arvin. 1984. Reasons for the absence of a history of recurrent genital infections in mothers of neonates infected with herpes simplex virus. *Pediatrics* **73**:188–193.
105. Yeager, A. S., A. M. Arvin, L. J. Urbani, and J. A. Kemp III. 1980. Relationship of antibody to outcome in neonatal herpes simplex virus infections. *Infect. Immun.* **29**:532–538.