

Sir,  
**A mutation in the Norrie disease gene (*NDP*) associated with familial exudative vitreoretinopathy**

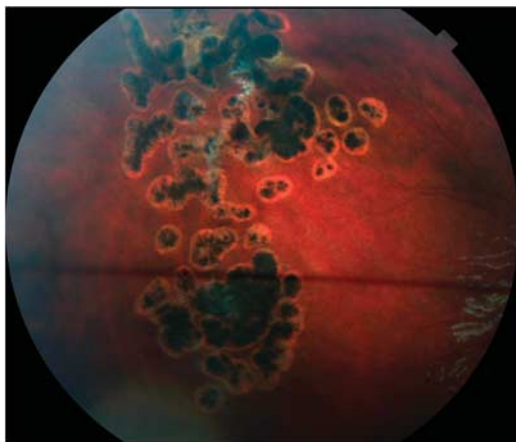
Familial exudative vitreoretinopathy (FEVR) is a hereditary disorder that is characterised by aberrant and incomplete vascularisation of the peripheral retina. An early diagnosis of FEVR is important for adequate genetic counselling and treatment. FEVR is a genetically heterogeneous disease that shows X-linked recessive, autosomal dominant, and autosomal recessive modes of inheritance. X-linked recessive FEVR has been associated with mutations in the Norrie disease (*NDP*) gene.<sup>1,2</sup>

**Case report**

A 2-year-old male infant was diagnosed with FEVR on clinical grounds and a lack of prematurity. The patient presented as a 1 year old with a left esotropia and an abnormal red reflex in the left eye. Fundoscopy at EUA detected inferotemporal peripheral vascular and gliotic changes in the right eye and a dragged macula with retinal exudation in the left eye. The right eye was treated with retinal laser photocoagulation and the left developed a total retinal detachment. Both parents had normal retinal examinations and FFAs. His sister underwent an EUA and the retinae were normal. A major concern in the family was the risks to other children. DNA was extracted from peripheral blood leukocytes. The Norrie disease gene (*NDP*) was screened using Sanger sequencing by the NHS UK Genetic Testing Network (UKGTN). Mutational analysis of the *NDP* gene detected a C>T mutation in exon 2 resulting in a substitution of arginine by cysteine (p.Arg38Cys).

**Comment**

A French study identified this *NDP* mutation (p.Arg38Cys) in a patient with Norrie disease. The sequence was only identified in one family and was not seen in 75 control chromosomes. Our examination of the literature for identical FEVR-related SNPs reveals a Spanish paper, which identified two families with XL-FEVR and this mutation. They shared other common pieces of DNA and were therefore assumed to be



**Figure 1** The peripheral vascular and gliotic changes treated with retinal laser photocoagulation in the right eye.

distantly related. The phenotype ranged from primary hyperplastic primary vitreous to XL-FEVR with variable ophthalmic signs. One family member who had the mutation did not have any signs of XL-FEVR and this was felt to be a case of incomplete penetrance. Genetic analysis of the *NDP* gene confirmed X-linked FEVR and enabled genetic counselling, thus removing the requirement of EUAs in at-risk children. The UKGTN now offers testing of three FEVR genes: *NDP*, *frizzled-4*, and *LRP5*, which will improve clinical care of families and children (Figure 1).

**Conflict of interest**

The authors declare no conflict of interest.

**References**

- 1 Royer G, Hanein S, Raclin V, Gigarel N, Rozet J, Munnich A *et al.* *NDP* gene mutations in 14 French families with Norrie disease. *Hum Mutat* 2003; **22**: 499.
- 2 Riveiro-Alvarez R, Trujillo-Tiebas J, Gimenez-Pardo A, Garcia-Hoyos M, Cantalapiedra D, Lorda-Sanchez I *et al.* Genotype-phenotype variations in five Spanish families with Norrie disease or X-linked FEVR. *Mol Vis* 2005; **11**: 705–712.

S Chamney, E McLoone and CE Willoughby

Department of Ophthalmology, Royal Victoria Hospital, Queen's University Belfast & Belfast HSC Trust, Northern Ireland, UK  
 E-mail: sarahchamney@gmail.com

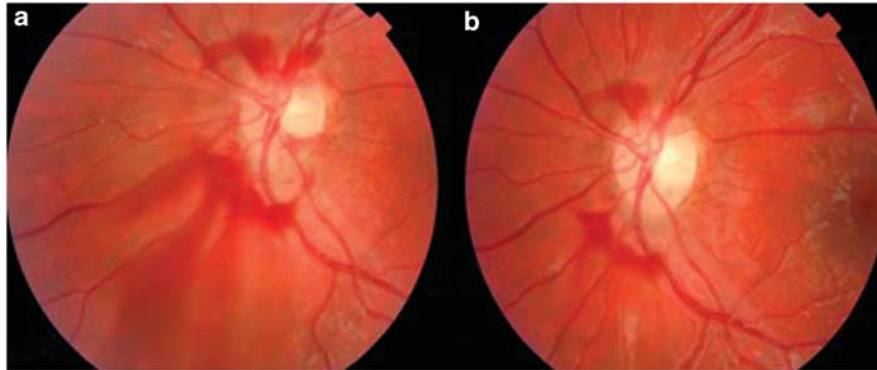
*Eye* (2011) **25**, 1658; doi:10.1038/eye.2011.226;  
 published online 30 September 2011

Sir,  
**Acute disseminated encephalomyelitis associated with optic neuritis and marked peri-papillary hemorrhages**

Acute disseminated encephalomyelitis (ADEM) is thought to have an underlying autoimmune, demyelinating aetiology. It resembles multiple sclerosis and typically occurs in children.<sup>1–3</sup> It is characterized by diffuse neurological features including headache, cerebellar ataxia, altered mental state, choreiform movements and vertigo. The classic ophthalmic manifestation is optic neuritis. We report the first case of ADEM with optic neuritis associated with marked peri-papillary haemorrhages.

**Case report**

A 6-year-old boy with an 8-week history of headache and reduced vision in his left eye was referred by his neurologist. On examination his visual acuity was RE 6/24, LE 6/60, he had an RAPD in the left eye. Eye movements were full and anterior segments were quiet. Fundoscopy revealed optic disc swelling with marked peri-papillary haemorrhages with otherwise normal maculae (Figure 1a). FBC, U + E, CRP, and ESR



**Figure 1** (a) Left fundus. Optic nerve swelling with peri-papillary haemorrhages. (b) Left fundus. Resolution of optic nerve swelling and reabsorbing haemorrhages.

were all normal, whereas PCR for HSV1 and 2, EBV, and CMV were all negative. LP was normal with an opening pressure of 14 mm Hg. An MR scan showed a number of peri-ventricular high-signal lesions. He was diagnosed with ADEM and optic neuritis, and treated with two doses of intravenous methyl-prednisolone followed by a reducing dose of oral prednisolone. He has made a good recovery with improved vision to 6/6 in his left eye, resolution of optic nerve swelling, and reabsorbing peri-papillary haemorrhages (Figure 1b). His right eye remains quiescent and there have been no further neurological or ophthalmic episodes.

#### Comment

To the best of our knowledge, this is the first report of ADEM with peri-papillary haemorrhages. This observation raises the question as to the underlying aetiology and although an autoimmune mechanism with HLA-DR linkage is likely, other forces may have a role to perform.<sup>4,5</sup> Further work is required to ascertain the possibility of a vasculitic element to the underlying processes.

#### Conflict of interest

The authors declare no conflict of interest.

#### References

- Lucas J. An account of uncommon symptoms succeeding the measles with additional remarks on the infection of measles and smallpox. *London Med J* 1790; **11**: 325–331.
- Menage T, Hemmer B, Nessler S, Wiendl H, Neuhaus O, Hartung HP *et al*. Acute disseminated encephalomyelitis. *Arch Neurol* 2005; **62**(11): 1673–1680.
- Murphy J, Austin J. Spontaneous infection or vaccination as cause of acute disseminated encephalomyelitis. *Neuroepidemiology* 1985; **4**: 138–145.
- Schwarz S, Mohr A, Knauth M, Wildermann B, Storch-Hagenlocher B. Acute disseminated encephalomyelitis: a follow-up study of 40 adult patients. *Neurology* 2001; **56**: 1313–1318.
- Rush J. Idiopathic optic neuritis of childhood. *J Pediatric Ophthalmol Strabismus* 1981; **18**: 39–41.

WH Chan<sup>1,2</sup>, IC Lloyd<sup>1</sup>, JL Ashworth<sup>1</sup>, S Jain<sup>3</sup>, K May<sup>1</sup>, I Hughes<sup>1</sup> and S Biswas<sup>1</sup>

<sup>1</sup>Department of Paediatric Ophthalmology and Strabismus, Manchester Royal Eye Hospital, Oxford Road, Manchester, UK

<sup>2</sup>NiuHu Eye Research Center, NiuHu, Guangdong, China

<sup>3</sup>Department of Ophthalmology, Royal Free Hospital, London, UK

E-mail: WaiBruceLeeChan.MD.FRCOphth@gmail.com

*Eye* (2011) **25**, 1658–1659; doi:10.1038/eye.2011.227; published online 23 September 2011

#### Sir, Shield or not to shield? Postoperative protection after modern cataract surgery

The evolution of cataract surgery continues. Surgery has progressed rapidly from ICCE to sub-3-mm sutureless phacoemulsification. In 1996, 66% of anaesthetic was peribulbar, but modern surgery requires only subtenon (47%) or topical ± intracameral (27%) administration.<sup>1</sup> All these advances are backed by evidence. However, there is a relative paucity of data supporting postoperative ocular protection. Some surgeons routinely employ an eye shield for up to 6 weeks, whereas others completely avoid any ocular protection. Current practice is varied predominantly based on historical and anecdotal evidence. Shield users cite valid arguments. They confer confidence to both patient and surgeon by providing a physical barrier to recently operated eyes and protect from errant fingers. However, the routine use of shields was questioned 20 years ago,<sup>2</sup> yet there remains no definitive answer to whether they are still necessary for modern micro-incisional surgery?

A study of 133 patients following topical cataract surgery found that ocular protection confers no safety benefit but elicits higher rates of patient discomfort with 53% of patients feeling it was unnecessary.<sup>3</sup>

We retrospectively analysed electronically all cataract procedures between 1 April 2010 and 31 March 2011