

Original

Morphological and Biochemical Changes During Aging and Photoaging of the Skin of C57BL/6J Mice

Ayako Sayama¹, Tomomi Soushin¹, Taro Okada¹, Kunio Doi¹, and Hiroyuki Nakayama¹

¹Department of Veterinary Pathology, Graduate School of Agricultural and Life Sciences, The University of Tokyo, 1-1-1 Yayoi, Bunkyo-ku, Tokyo 113-8657, Japan

Abstract: The differences between the dorsal skin of 11- and 16-week-old C57BL/6J mice were examined morphologically and biochemically. The dermis of the 16-week-old mice was thinner than that of the 11-week-old mice due to decreases in the amounts of soluble collagen and elastin. Next, the changes in dorsal skin exposed to UVA irradiation for 8 weeks (576 J/cm²) were examined in 3 (younger)- and 8 (older)-week-old C57BL/6J mice. The thickness of the dermis was not significantly different between the UVA-irradiated and control mice in either the younger or older group. The increase in the amount of collagen was related to the increase in the level of soluble collagen in the younger mice. In contrast, it was related to the increase in the level of insoluble collagen in the older mice. In the UVA-irradiated older mice, the activity of the latent form of MMP-13 was significantly higher than that in the control mice. These results suggest that aging and UVA-induced photoaging in the skin are histologically and biochemically different phenomena. (J Toxicol Pathol 2010; 23: 133–139)

Key words: skin, aging, photoaging, UVA, mouse

Introduction

Aging is a progressive process that occurs equally in all organs. However, skin aging is a little different from the aging of other organs because the skin is always exposed to the external environment. There are many external factors that affect skin aging, such as temperature, humidity, tobacco smoke and mechanical stress^{1–4}. Among the factors, ultraviolet (UV) radiation influences skin aging most. UV radiation is divided into 3 groups according to wavelength, UVA (320–400 nm), UVB (280–320 nm) and UVC (< 280 nm). The adverse effects of UV radiation on the skin have been studied since the 1890s, and the strong cytotoxicity and carcinogenicity of UVB had attracted much attention. However, in the 1980s, it was clarified that UV mildly accelerates skin aging, and the term ‘photoaging’ was coined^{5–7}. Photoaging is mainly caused by UVA, which has the longest wavelength, and induces long-term cumulative changes in the skin. There have been many reports on photoaging, but few of them focused on the pathological features of UVA *in*

vivo. UVA is the major component of UV, reaches the deeper skin and is intimately involved in chronological skin aging.

In the present study, we examined the morphological and biochemical changes that occurred in the skin of younger and older mice exposed to UVA and the differences between aging and UVA-induced photoaging.

Materials and Methods

Animals

Female C57BL/6J mice were obtained from Japan SLC, Hamamatsu, Japan. They were housed under controlled conditions (23 ± 2°C and 55 ± 5% relative humidity with a 14-hr light and 10-hr dark cycle) using an isolator caging system (Niki Shoji, Tokyo, Japan) and were fed commercial pellets (MF, Oriental Yeast, Tokyo, Japan) and water *ad libitum* during the experimental period. We used female mice because a lot of previous reports concerning skin photoaging had dealt with females. All experimental procedures were approved by the Animal Care and Use Committee of the University of Tokyo, and the experiments were performed according to the Implementation Manual for Animal Experiments at the University of Tokyo.

UVA treatment

Table 1 shows details of the experimental design. The animals were divided into 8 groups of 3 animals each and

Received: 15 April, 2010, Accepted: 3 June 2010

Mailing address: Hiroyuki Nakayama, Department of Veterinary Pathology, Graduate School of Agricultural and Life Sciences, The University of Tokyo, 1-1-1 Yayoi, Bunkyo-ku, Tokyo 113-8657, Japan

TEL: 81-3-5841-5400 FAX: 81-3-5841-8185

E-mail: anakaya@mail.ecc.u-tokyo.ac.jp

Table 1. Experimental Designs

| Group | Age at the first irradiation (weeks) | UVA-irradiation | Period of irradiation (weeks) | Age at sacrifice (weeks) |
|---------|--------------------------------------|-----------------|-------------------------------|--------------------------|
| Younger | 3 | (-) | 2 | 5 |
| | | | 4 | 7 |
| | | | 6 | 9 |
| | | | 8 | 11 |
| | | (+) | 2 | 5 |
| | | | 4 | 7 |
| | | | 6 | 9 |
| | | | 8 | 11 |
| Older | 8 | (-) | 2 | 10 |
| | | | 4 | 12 |
| | | | 6 | 14 |
| | | | 8 | 16 |
| | | (+) | 2 | 10 |
| | | | 4 | 12 |
| | | | 6 | 14 |
| | | | 8 | 16 |

Table 2. Procedure for Collagen Extraction

| | Treatment | Temperature | Duration |
|---|---------------------------------|-------------|----------|
| A | 0.05 M Tris buffer + 1.0 M NaCl | 4°C | 3 days |
| B | 0.5 M Acetic Acid | 4°C | 2 days |
| C | 0.5 M Acetic Acid + Pepsin | 4°C | 7 days |
| D | DW | 100°C | 2 hours |
| E | 0.5 M Acetic Acid + Pepsin | 100°C | 2 hours |

kept in irradiation cages (70 × 150 × 105 mm). Before irradiation, their dorsal hair was shaved off. Then, the mice were exposed to artificial UVA light (wavelength: 365 nm) generated with a UV generator (HP-6LM, ATTO, Tokyo, Japan) for 16 hours (total irradiation dose: 24 J/cm²) three times a week. The UVA dose was determined based on a preliminary dose-finding study using a UVA detector (ATR-3WX with a CX-365 sensor, ATTO, Tokyo, Japan).

Morphological analysis

Skin samples were obtained from the dorsal midline portions after each irradiation period, fixed in 10% neutral-buffered formalin and embedded in paraffin wax. Four- μ m thick sections were stained with hematoxylin and eosin (H&E), Masson's trichrome, Weigert's elastic fiber (Krut-say) and Toluidine blue. The thicknesses of the dermis and subcutaneous adipose tissue were measured, and the relative thickness of the dermis (the ratio of the dermis to the dermis plus subcutaneous adipose tissue) was calculated.

Collagen measurements

The amount of collagen in the dermis was measured using a Sircol Collagen Assay kit (Biocolor, Belfast, Northern Ireland) based on the fact that the Sirius red dye binds to the side chains of the amino acids in collagen. Both soluble

and covalently cross-linked insoluble collagen fractions were obtained by successive treatment of the skin with 10 volumes of 5 types of buffer (Table 2). The collagen extracted with buffers A and B was categorized as soluble collagen, and that extracted with buffers C, D and E was categorized as insoluble collagen.

Elastin measurements

The amount of elastin in the dermis was measured using a Fastin Elastin Assay kit (Biocolor) based on the fact that the Fastin dye binds to the side chains of the amino acids in elastin. The elastin fraction was obtained by three successive treatments of the skin samples with 0.25 M oxalic acid at 100°C for 1.5 hours.

Protein extraction

Frozen skin samples were minced and homogenized in 10 volumes of extraction buffer (1% NP-40, 20 mM Tris-HCl (pH 7.8); 150 mM NaCl; 2 mM Na₃VO₄; 10 mM Na; and Proteinase Inhibitor Cocktail, EDTA-Free). The homogenate was centrifuged at 9,000 g at 4°C for 15 min, and the supernatant was collected as an extracted protein. The protein concentration of the supernatant was measured by Lowry's method using a DC Protein Assay kit (Bio-Rad, Hercules, CA, USA).

Zymography

Gelatin zymography was performed to detect MMP-13 activity in the proteins extracted from the skin samples using a previously described method⁸ with minor modifications. The proteins in each sample were separated by sodium dodecyl sulphate polyacrylamide gel electrophoresis (SDS-PAGE) on a 15% gel containing 1 mg/mL gelatin. Human MMP-13 protein (Merck, Darmstadt, Germany) was used as a positive control. The samples were then electrophoresed at 20 mA for 75 min, and the gel sheet was washed in a denaturing buffer (50 mM Tris aminomethane, 0.2 M NaCl and 2.5% Triton X-100) at room temperature for 1 h and incubated in a developing buffer (50 mM Tris aminomethane, 50 mM Tris-HCl, 0.2 M NaCl, 0.02% Brij-35 and 5 mM CaCl₂), first at room temperature for 30 min and then at 37°C for 20 hr. The gel sheet was stained with 2.5% Coomassie Blue R-250 in a 50% methanol and 10% acetic acid solution for 30 min and destained in 30% methanol and 10% acetic acid solution until the active bands became clear.

Statistical analysis

The mean quantitative values obtained were statistically analyzed using the Student's *t*-test, and *P* values less than 5% (two-tailed) were considered to be significant.

Results

Non-irradiated mice

Morphological analysis: The relative dermal thickness (the ratio of the dermis to the dermis plus subcutaneous adipose tissue) of the older (16-week-old) non-irradiated mice (0.360 ± 0.06) was significantly lower than that of the younger (11-week-old) mice (0.487 ± 0.03 ; $P < 0.05$; Fig. 1).

Collagen amount: The total amount of dermal collagen in the older non-irradiated mice ($510 \pm 44.8 \mu\text{g/ml}$) was significantly lower than that in the younger mice ($672 \pm 56.7 \mu\text{g/ml}$; $P < 0.05$; Fig. 2A). The amount of soluble collagen in the older mice ($90.0 \pm 3.28 \mu\text{g/ml}$) was significantly lower than that in the younger mice ($238 \pm 28.9 \mu\text{g/ml}$; $P < 0.05$; Fig. 2C). However, the amount of insoluble collagen was not significantly different between the two groups (Fig. 2D).

Elastin amount: The amount of elastin in the older non-irradiated mice ($42.9 \pm 3.66 \mu\text{g/ml}$) was significantly lower than that in the younger mice ($70.0 \pm 7.51 \mu\text{g/ml}$; $P < 0.05$; Fig. 2B).

Gelatin zymography: There was no significant difference in the activity of the latent or active form of MMP 13 between the non-irradiated older and younger mice (data not shown).

UVA-irradiated mice

Morphological analysis: Slight mononuclear cell infiltration into the dermis was detected 2 weeks after UVA irradiation. In addition, hyperkeratosis in the epidermis was found 4 weeks after irradiation. Dermal thickening and an increase in the amount of collagen fibers in the subcutaneous fat layer were also observed at 8 weeks after irradiation. The

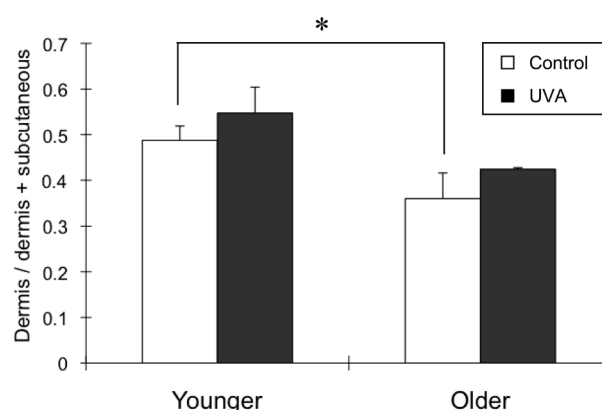


Fig. 1. Relative thickness of the dermis in the 8-week non- and UVA-irradiated mice. The relative thickness of the dermis (the ratio of the dermis to the dermis plus subcutaneous adipose tissue) was calculated at 8 weeks after with and without UVA irradiation in both the younger and older mice ($n=3$). In the non-irradiated mice, the relative thickness of the dermis in the older mice was lower than that in the younger mice ($*P < 0.05$). UVA-irradiated mice showed an increase in the relative thickness of the dermis in each group, but the difference was not significant.

amount of elastic fibers in the dermis was increased at 4 weeks after irradiation, and some of the fibers were tangled at 6 weeks after irradiation (Fig. 3). The number of mast cells was increased at 2 weeks after irradiation, especially at the dermal-subcutaneous junction (data not shown). These changes were observed in both the younger and older mice.

In the younger group, the relative dermal thickness of the 8 week UVA-irradiated mice (0.547 ± 0.06) was not significantly different from that of the control mice (0.487 ± 0.03). Similarly, in the older group, the dermal thickness of the 8 week UVA-irradiated mice (0.424 ± 0.003) was not significantly different from that of the control mice (0.360 ± 0.06 ; Fig. 1).

Collagen amount: In the younger mice, the amount of total collagen was higher in the 8 week UVA-irradiated mice ($840 \pm 133 \mu\text{g/ml}$) than in the control mice ($672 \pm 56.7 \mu\text{g/ml}$), but the difference was not significant (Fig. 2A). The amount of soluble collagen was significantly higher in the 8 week UVA-irradiated mice ($369 \pm 40.7 \mu\text{g/ml}$) than in the control mice ($238 \pm 28.9 \mu\text{g/ml}$; $P < 0.05$; Fig. 2C). However, there were no significant changes in the amount insoluble collagen between the 8 week UVA-irradiated and control mice (Fig. 2D).

In the older mice, the total collagen amount was significantly higher in the 8 week UVA-irradiated mice ($653 \pm 44.0 \mu\text{g/ml}$) than in the control mice ($510 \pm 44.8 \mu\text{g/ml}$; $P < 0.05$; Fig. 2A). The soluble collagen amount was significantly lower in the 8 week UVA-irradiated mice ($78.6 \pm 2.68 \mu\text{g/ml}$) than in the control mice ($90.0 \pm 3.28 \mu\text{g/ml}$; $P < 0.05$; Fig. 2C). The amount of insoluble collagen was significantly higher in the 8 week UVA-irradiated mice ($575 \pm 41.8 \mu\text{g/ml}$) than in the control mice ($420 \pm 48.1 \mu\text{g/ml}$; $P < 0.05$;

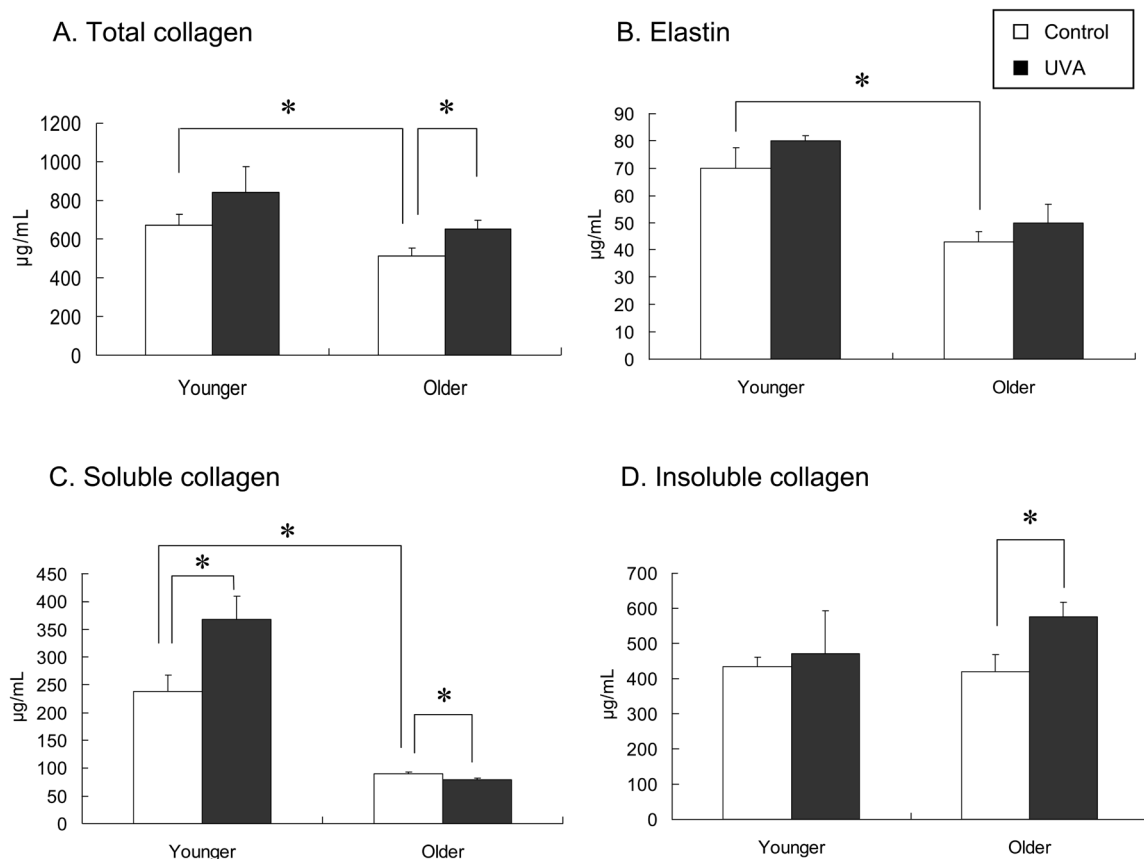


Fig. 2. The amounts of dermal collagen and elastin in the 8-week non- and UVA-irradiated mice. The amount of total collagen, which consists of soluble and insoluble collagen, and that of elastin in the skin were measured at 8 weeks after with and without UVA irradiation in both the younger and older mice ($n=3$). In the non-irradiated mice, the amounts of total collagen, soluble collagen and elastin in the older mice were significantly lower than those in the younger mice ($*P<0.05$; A, B, and C). The amount of insoluble collagen was similar in the younger and older mice (D). In the UVA-irradiated mice, the amounts of total collagen and elastin tended to be higher than those in the non-irradiated control mice in both groups (A and B). The amount of soluble collagen in the UVA-irradiated mice was significantly higher than that in the non-irradiated control mice in the younger group ($*P<0.05$; C). The amount of insoluble collagen in the UVA-irradiated mice was also significantly higher than that in the non-irradiated control mice in the older group ($*P<0.05$; D).

Fig. 2D).

Elastin amount: In the younger mice, the amount of elastin was not significantly different between the 8 week UVA-irradiated mice ($80.0 \pm 1.90 \mu\text{g/ml}$) and the control mice ($70.0 \pm 7.51 \mu\text{g/ml}$; Fig. 2B).

In the older mice, the amount of elastin was not significantly different between the 8 week UVA-irradiated mice ($49.8 \pm 6.79 \mu\text{g/ml}$) and the control mice ($42.9 \pm 3.66 \mu\text{g/ml}$; Fig. 2B).

Gelatin zymography: In the younger mice, the activity of the latent form of MMP-13 in the 8 week UVA-irradiated mice ($76.8 \pm 9.89 \text{ OD} \times \text{mm}^2$) tended to be higher than that in the control mice ($51.4 \pm 17.0 \text{ OD} \times \text{mm}^2$), but the difference was not significant. The activity of the active form of MMP-13 was very low in both the 8 week UVA-irradiated and control mice, and there was no significant difference between its activity in these two groups (Fig. 4A and C).

In the older mice, the activity of the latent form of MMP-13 in the UVA-irradiated mice ($95.4 \pm 24.3 \text{ OD} \times$

mm^2) was significantly higher than that in the control mice ($43.0 \pm 16.5 \text{ OD} \times \text{mm}^2$; $P<0.05$). The activity of the active form of MMP-13 in the UVA-irradiated mice ($45.9 \pm 29.3 \text{ OD} \times \text{mm}^2$) was higher than that in the control mice ($12.2 \pm 8.45 \text{ OD} \times \text{mm}^2$), but the difference was not significant (Fig. 4B and C).

Discussion

The dermis is mostly composed of collagen and elastic fibers. The former is a major component and provides the tension and structural integrity of the skin, and the latter is a minor component but provides the skin's elasticity⁹. Skin aging is histologically characterized by general atrophy of the extracellular matrix as a result of a decreased number of fibroblasts and reduced amounts of collagen and elastin¹⁰⁻¹². In the present study, we found that age-related skin atrophy (reduced thickness of the dermis) was caused by decreases in the amounts of collagen and elastin. Moreover, we found

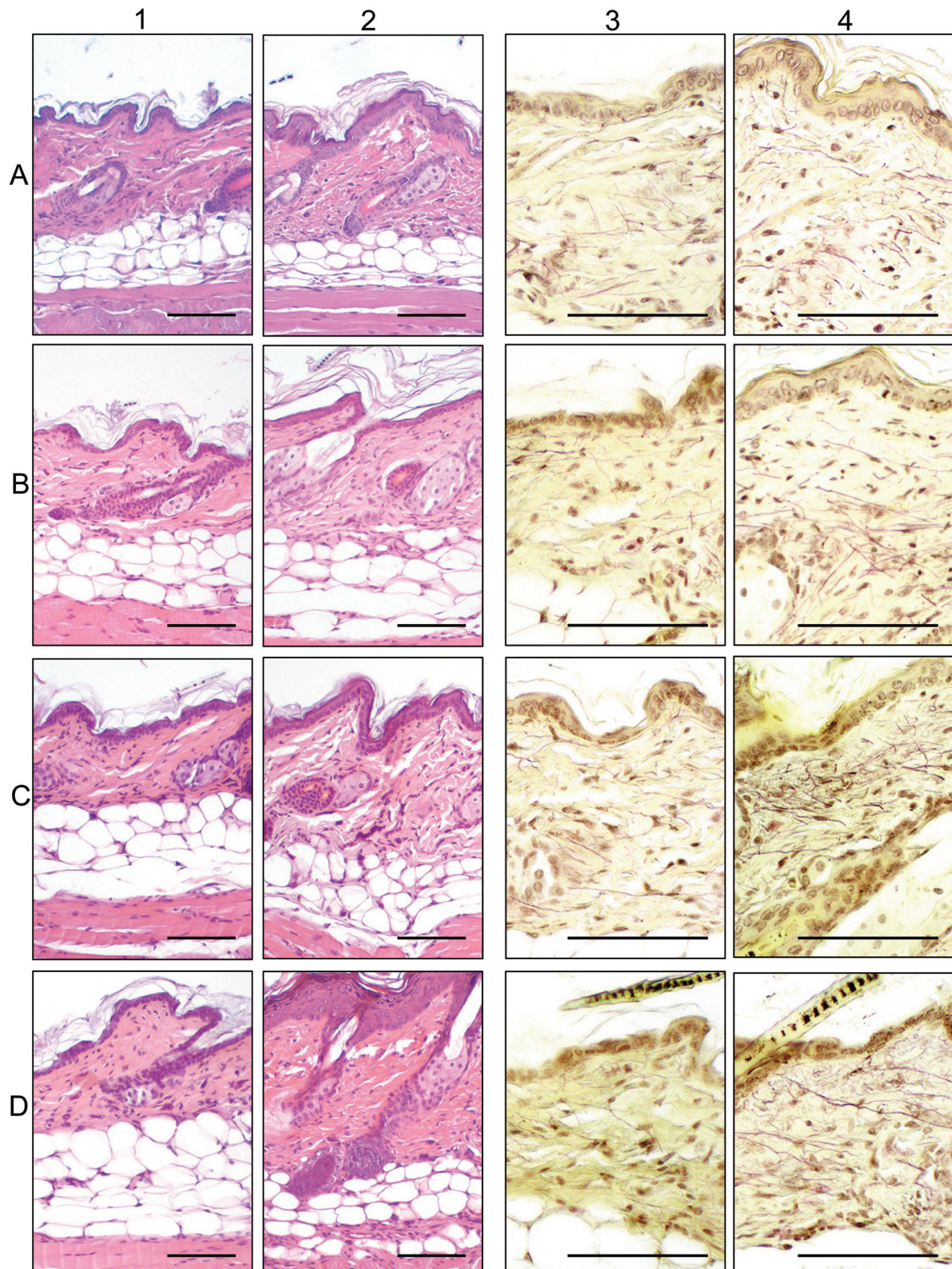


Fig. 3. Histological changes in the skin of older mice exposed to 2 (A), 4 (B), 6 (C) and 8 (D) weeks of UVA irradiation (columns 2 and 4) and the non-irradiated controls (columns 1 and 3). (columns 1 and 2): H&E staining. Inflammatory cell infiltration into the dermis at 2 weeks after irradiation (A-2), hyperkeratosis in the epidermis at 4 weeks after irradiation (B-2), thickening of the dermis and increased amount of collagen fibers in the subcutaneous layer at 8 weeks after irradiation (D-2). (columns 3 and 4): Weigert's elastic fiber staining. Increased number of elastic fibers in the dermis at 4 weeks after irradiation (B-4) and tangle formation of elastic fibers at 6 weeks after irradiation (C-4). Bar=50 μ m.

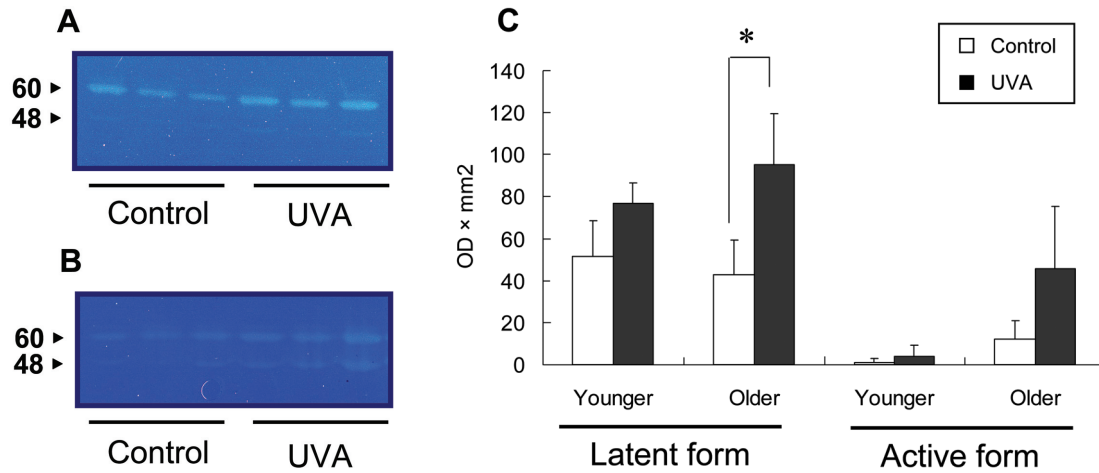


Fig. 4. MMP-13 activity in 8-week UVA-irradiated mice. The results of zymographic analysis of the younger (A) and older (B) UVA-irradiated mice. The bands at 60 and 48 kDa indicate latent and active MMP-13, respectively. The latent form of MMP-13 activity in the UVA-irradiated mice was significantly higher than that of the non-irradiated control mice ($*P < 0.05$) in the older group (C).

that the decrease in the amount of total collagen was caused by a decrease in the level of soluble collagen, but not that of insoluble collagen. Soluble collagen is immature collagen that is freshly secreted by fibroblasts and becomes insoluble by intermolecular cross linkage^{13–15}. Therefore, we assume that the decrease in the level of total collagen was caused by reduced biosynthesis of collagen molecules. In addition, gelatin zymography revealed no differences in MMP-13 activity in the skin between the 16- and 11-week-old mice, indicating that degradation of collagen does not change with age. The cause of the decrease in elastin is not clear, but some reports have suggested that the degradation of elastic fibers accelerates with age in human skin^{10, 11}.

We then examined the effect of UVA irradiation on the skin as a model of photoaging. Hairless mice have been widely used in previous studies due to their advantages of having skin with a similar appearance to human skin and the fact that they do not need to be shaved before and during the experiment. However, hairless mice have disadvantages as a model of human skin: they have a thick epidermis and an abnormal hair cycle, are prone to cyst formation and dermal inflammation as a result of the cysts rupturing, show a tendency to form foreign body granulomas and suffer from a high tumor incidence¹⁶. As the purpose of the present experiment was to examine the effect of UVA irradiation on normal skin, we used shaved C57BL/6J mice instead of hairless mice.

The pathological changes induced in the skin by UV irradiation vary according to the wavelength used. UVB induces serious lesions in the epidermis and upper dermis, such as squamous cell carcinoma, hyperkeratosis, sebaceous gland dilatation and a thickened dermis as a result of cyst formation^{17, 18}. In contrast, UVA induces comparatively mild lesions mainly in the dermis, such as degeneration of

collagenous and elastic fibers^{19, 20}. In the present study, the level of soluble collagen was increased in the young mice by 8 weeks of UVA irradiation, while that of insoluble collagen was increased in the older animals by exposure to the same amount of UVA irradiation. These results suggest that the increase in total collagen induced by UVA irradiation is caused by elevated collagen production in younger mice, but that the increase is caused by inhibited collagen degradation in older mice.

In humans, solar elastosis, which is characterized by the accumulation of abnormal and amorphous elastin-containing material, is a common pathological condition in the skin associated with prolonged sun exposure^{21, 22}. However, in mouse skin, it is difficult to induce the same condition by UV irradiation^{23, 24}. In the present study, though abnormal tangled elastic fibers were observed in UV-irradiated mice, solar elastosis was not diagnosed, as in the previous reports.

Increased activity of MMP has been reported in sun-exposed human skin^{25–27}. The present study also revealed that the activity of MMP-13, which degrades type 1 collagen, was high in both the younger and older UVA-irradiated mice. In the older UVA-irradiated mice, the activity of latent MMP-13 was significantly higher than that in the control mice. It is well known that degradation of the extracellular matrix depends on the balance of MMP and its inhibitor, tissue inhibitor of metalloproteinase (TIMP). Therefore, it is possible that UVA irradiation induces an increase in TIMP activity, which suppresses the activity of MMP, and consequently results in the accumulation of collagen. Reverse zymography should be performed to measure TIMP activity.

The present study revealed that aging and UVA-induced photoaging of the skin are histologically and biochemically different phenomena. Skin aging is thought to be

a complex process involving the interaction of the two phenomena.

References

- Kadunce DP, Burr R, Gress R, Kanner R, Lyon JL, and Zone JJ. Cigarette smoking: risk factor for premature facial wrinkling. *Ann Intern Med.* **114**: 840–844. 1991.
- Placzec M, Kerkmann U, Bell S, Koepke P, and Przybilla B. Tobacco smoke is phototoxic. *Br J Dermatol.* **150**: 991–993. 2004.
- Fisher GJ, Kang S, Varani J, Bata-Csorgo Z, Wan Y, Datta S, and Voorhees J. Mechanisms of photoaging and chronological skin aging. *Arch Dermatol.* **138**: 1462–1470. 2002.
- Landau M. Exogenous factors in skin aging. *Curr Probl Dermatol.* **35**: 1–13. 2007.
- Kligman LH. The hairless mouse. Model for photoaging. *Clin Dermatol.* **14**: 183–195. 1996.
- Winkelman RK, Zollman PE, and Baldes EJ. Squamous cell carcinoma produced by ultraviolet light in hairless mice. *J Invest Dermatol.* **40**: 217–224. 1963.
- Kligman LH. Photoaging. Manifestations, prevention and treatment. *Clin Geriatr Med.* **5**: 235–251. 1989.
- Kawai K, Uetsuka K, Doi K, and Nakayama H. The activity of matrix metalloproteinases (MMPs) and tissue inhibitors metalloproteinases (TIMPs) in mammary tumors of dogs and rats. *J Vet Med Sci.* **68**: 105–111. 2006.
- Oikarinen A. Aging of the skin connective tissue: how to measure the biochemical and mechanical properties of aging dermis. *Photodermatol Photoimmunol Photomed.* **10**: 47–52. 1994.
- Braverman IM and Fonferko E. Studies in cutaneous aging. I. The elastic fiber network. *J Invest Dermatol.* **78**: 434–443. 1982.
- Uitto J. Connective tissue biochemistry of the aging dermis. Age-related alterations in collagen and elastin. *Dermatol Clin.* **4**: 433–446. 1986.
- Varani J, Spearman D, Perone P, Fligel SEG, Datta SC, Wang ZQ, Shao Y, Kang S, Fisher GJ, and Voorhees JJ. Inhibition of type I procollagen synthesis by damaged collagen in photoaged skin and by collagenase-degraded collagen in vitro. *Am J Pathol.* **158**: 931–942. 2001.
- Okuyama T. *Doubutsu seibun riyoushusei, rikusan doubutsuhen.* R&D Planning. Tokyo. 2002 (In Japanese).
- Eyre DR, Paz MA, and Gallop PM. Cross-linking in collagen and elastin. *Annu Rev Biochem.* **53**: 717–748. 1984.
- Herbage D, Le Lous M, Cohen-Solal L, and Bazin S. Study of collagen cross-links. *Front Matrix Biol.* **10**: 59–91. 1985.
- Sundberg JP and King LE Jr. Mouse mutations as animal models and biochemical tools for dermatological research. *J Invest Dermatol.* **106**: 368–376. 1996.
- Lesnik RH, Kligman LH, and Kligman AM. Agents that cause enlargement of sebaceous glands in hairless mice: Ultraviolet radiation. *Arch Dermatol Res.* **284**: 106–108. 1992.
- Kligman LH, Akin FJ, and Kligman AM. Prevention of ultraviolet damage to the dermis of hairless mice by sunscreens. *J Invest Dermatol.* **78**: 181–189. 1982.
- Kligman LH, Akin FJ, and Kligman AM. The contributions of UVA and UVB to connective tissue damage in hairless mice. *J Invest Dermatol.* **84**: 272–276. 1985.
- Zheng P and Kligman LH. UVA-induced ultrastructural changes in hairless mouse skin: a comparison to UVB-induced damage. *J Invest Dermatol.* **100**: 194–199. 1993.
- Rabe JH, Mamelak AJ, McElgunn PJS, Morison WL, and Sauder DN. Photoaging: Mechanisms and repair. *J Am Acad Dermatol.* **55**: 1–19. 2006.
- Muto J, Kuroda K, Wachi H, Hirose S, and Tajima S. Accumulation of elafin in actinic elastosis of sun-damaged skin: elafin binds to elastin and prevents elastolytic degradation. *J Invest Dermatol.* **127**: 1358–1366. 2007.
- Ogawa F and Sato S. Roles of oxidative stress in photoaging and the pathogenesis of systemic sclerosis. *Jpn J Clin Immunol.* **29**: 349–358. 2006.
- Janig E, Haslbeck M, Aigelsreiter A, Braun N, Unterthor D, Wolf P, Khaskhely NM, Buchner J, Denk H, and Zatloukal K. Clusterin associates with altered elastic fibers in human photoaged skin and prevents elastin from ultraviolet-induced aggregation in vitro. *Am J Pathol.* **171**: 1474–1482. 2007.
- Fischer GJ, Wang ZQ, Datta SC, Varani J, Kang S, and Voorhees JJ. Pathophysiology of premature skin aging induced by ultraviolet light. *N Engl J Med.* **337**: 1419–1428. 1997.
- Hase T, Shinta K, Murase T, Tokimitsu I, Hattori M, Takimoto R, Tsuboi R, and Ogawa H. Histological increase in inflammatory infiltrate in sun-exposed skin of female subjects: the possible involvement of matrix metalloproteinase-1 produced by inflammatory infiltrate on collagen degradation. *Br J Dermatol.* **142**: 267–273. 2000.
- Fagot D, Asselineau D, and Bernerd F. Matrix metalloproteinase-1 production observed after solar-stimulated radiation exposure is assumed by dermal fibroblasts but involves a paracrine activation through epidermal keratinocytes. *Photochem Photobiol.* **79**: 499–505. 2004.