

Case Report

Nocardia Brain Abscess in a Liver Transplant Recipient

Jung Hyeon Moon, M.D.,¹ Won-Sang Cho, M.D.,³ Hyun-Seung Kang, M.D., Ph.D.,^{1,2} Jeong Eun Kim, M.D., Ph.D.¹

Departments of Neurosurgery,¹ Radiology;² Seoul National University College of Medicine, Seoul National University Hospital, Seoul, Korea
Department of Neurosurgery;³ Kangwon National University Hospital, School of Medicine, Kangwon National University, Chuncheon, Korea

Nocardia brain abscess is rare. We report on a unique case of *N. farcinica* brain abscess in a liver transplant recipient, following *Aspergillus fumigatus* pneumonia. A 43-year-old liver transplant recipient presented with altered mentality at 2 months after *A. fumigatus* pneumonia. He was successfully treated with surgical removal and antibiotic therapy with trimethoprim-sulfamethoxazole and ceftriaxone.

Key Words : Brain abscess · Liver transplant · Nocardia.

INTRODUCTION

Brain abscesses after organ transplantation are rare, however, they are known to result in the high mortality and morbidity²⁰. In a review, the incidence of brain abscess is 0.6% among the liver transplant recipients, and patients with brain abscess shows a mortality rate of 20% and high morbidity, including seizures (up to 80%), altered mentality, and focal neurological deficits^{2,25}. Fungi are the predominant organisms in the immunocompromised host and usually arise by hematogenous dissemination from the lung¹⁶. *Aspergillus* species are the most common respiratory pathogens, 10% of which disseminates to the brain^{7,18-20}.

Nocardia species, as a nonfungal organism, are the rare cause of brain abscess and *N. farcinica* brain abscess is much rare. Only a single case has been reported in Korea²¹. Here, we report on a case of *N. farcinica* brain abscess in a liver transplant recipient, following *Aspergillus fumigatus* pneumonia.

CASE REPORT

A 43-year-old man was admitted for the evaluation and treatment of sudden altered mentality in June 2008. He had been diagnosed as hepatitis B virus-related liver cirrhosis 12 years before and had undergone liver transplantation from a living donor in September 2007. After the surgery, he has been taking immunosuppressive (tacrolimus and prednisolone) and antiviral

agents (adefovir and lamivudine). Post-transplantation clinical course has been uneventful until April 2008, with neither transplant rejection nor serious infectious diseases. Two months prior to the admission, he was diagnosed as *Aspergillus fumigatus* pneumonia, and was prescribed amphotericin B for 3 weeks, resulting in complete recovery.

He suffered from headache and blurred vision a month ago and rigidity of the legs which made him unable to walk a week ago. His mentality became drowsy a day ago. At admission, he was semicomatose and hemiparetic on the left side. Brain computed tomographic scan and magnetic resonance (MR) imaging demonstrated a 4×4-cm multiloculated rim-enhancing lesion with massive perilesional edema which was presumed to be a brain abscess (Fig. 1)

To achieve etiologic diagnosis and reduction of mass effect, craniotomy and removal of the lesion was performed. During the operation, non-odorous and creamy pus was drained from two cavities. The lesion could be easily dissected from the surrounding brain and was completely removed. After surgery, the patient became alert but right homonymous hemianopsia and left side weakness (Grade II/V) persisted. On the pathologic examination, the lesion was found to be organizing abscess with necrosis and fibrosis (Fig. 2). The microbiological studies revealed that the etiologic agent was *Nocardia farcinica*.

He was treated with intravenous trimethoprim-sulfamethoxazole (TMP/SMX) 1,920 mg every 8 hour (15 mg/kg/day) and ceftriaxone 2 gm every 12 hour for 2 weeks and then with intravenous TMP/SMX for additional 3 weeks. During the antibiotic treatment, he also received immunosuppressive and antiviral therapies although prednisolone was reduced from 30 mg to 5 mg. During the second week of the treatment, he developed progressive thrombocytopenia probably caused by TMP/SMX. Instead of withdrawing the drug, platelet concentrates were trans-

• Received : May 3, 2011 • Revised : September 20, 2011

• Accepted : October 10, 2011

• Address for reprints : Hyun-Seung Kang, M.D., Ph.D.

Department of Neurosurgery, Seoul National University College of Medicine,
Seoul National University Hospital, 101 Daehak-ro, Jongno-gu,
Seoul 110-744, Korea

Tel : +82-2-2072-1351, Fax : +82-2-744-8459

E-mail : hsk4428@yahoo.com

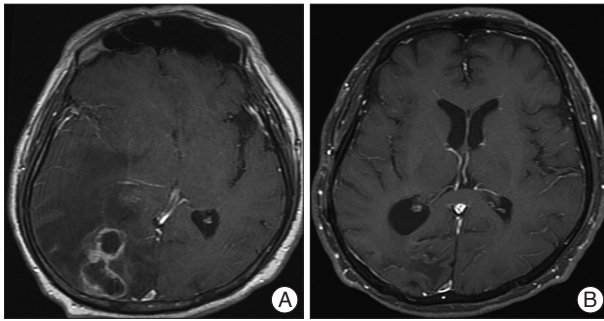


Fig. 1. A : Brain magnetic resonance (MR) imaging. A multiloculated rim-enhancing lesion with perilesional edema is observed in the right occipital lobe with a significant mass effect. B : Follow-up MR imaging. There is no residual enhancing lesion and no edema in the right occipital lobe at 2 months after operation.

fused, and his platelet count was maintained in the range of 50,000/uL to 100,000/uL. He also developed hyperkalemia (6.0 mmol/L) which thought to be due to TMP/SMX medication. It was controlled with oral kalimate administration.

After 6 weeks of rehabilitation, he was discharged home in a state of walker ambulation. The follow-up MR images 2 months after operation demonstrated no residual brain abscess. The antibiotic treatment with TMP/SMX was continued up to 12 months after operation. The patient achieved good recovery in 15 months after operation.

DISCUSSION

Nocardia species are soil-borne aerobic actinomycetes, and most of human infections have been caused by *Nocardia asteroides* and *brasiliensis*¹³. *Nocardia* brain abscesses account for about 1% to 2% of all brain abscesses, and most of them occur as a primary lesion with no evidence of extracranial lesions¹⁶. Overall, the mortality associated with brain abscesses is estimated to be 10%^{9,18}, however, cerebral nocardiosis shows the fatality rate of 30%¹⁷. Half of the affected patients are immunocompromised.

To our knowledge, cases of brain abscess caused by *N. farcinica* have been reported less than 20 in number^{3-5,8,10,22-24}. This is the second case report of *N. farcinica* brain abscess in Korea. It is unique in that the brain abscess was preceded by *Aspergillus fumigatus* pneumonia with a 2-month interval. Diagnosis of nocardial respiratory infection is difficult because of the slow growth of the bacteria and the presence of normal flora in the culture¹. If the patient had not undergone operation for the brain lesion, he might have been treated with an antifungal agent, such as amphotericin B, which was used for treatment of the previous pneumonia. We confirmed that the etiologic organism was *N. farcinica* by the microbiological study. After successful surgical removal of the lesion and the etiologic diagnosis, we could start an appropriate antimicrobial therapy, including TMP/SMX, which led to a satisfactory outcome in the present case.

Due to the good tolerance and excellent penetration into the

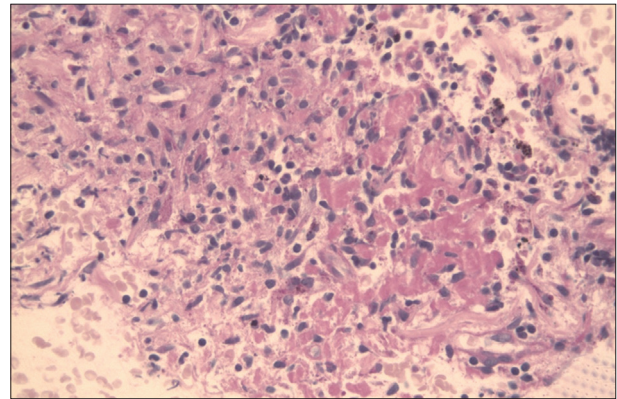


Fig. 2. Pathologic examination of brain tissue. There is chronic active inflammation with reactive gliosis (H&E staining, ×400).

cerebrospinal fluid space, TMP/SMX is the preferred initial treatment option for *N. farcinica* brain abscesses. Amikacin, carbapenem, sulfonamide, minocycline, ciprofloxacin, or a third-generation cephalosporin are also reported to be effective^{14,16,17}. In this case, the platelet count number was decreased to 50,000/uL during the antimicrobial therapy. The sulfamethoxazole component of TMP/SMX is known to be one of the most common causes of isolated leukopenia or thrombocytopenia¹¹. However, majority of them have safely continued to receive TMP/SMX with resolution of the adverse reactions, either spontaneously or with a supportive care with drugs, such as anti-histamine, anti-pyretic, or corticosteroid therapy⁶. Our patient responded well to corticosteroid therapy and platelet transfusion. Antimicrobial therapy is often continued for many months after apparent cure because of high relapse rate. If the brain is involved or the patient is immunosuppressed, the treatment should be continued for 12 months^{12,15}.

CONCLUSION

In immunocompromised patients who present with a brain abscess, it is important to know that various organisms, including *N. farcinica*, can cause the lesion, irrespective of the previous infections. In this case, we confirmed the etiologic agents, and achieved a good outcome through surgical removal of the mass lesion and adequate antibiotic treatment.

References

1. Barnaud G, Deschamps C, Manceron V, Mortier E, Laurent F, Bert F, et al. : Brain abscess caused by *Nocardia cyriacigeorgica* in a patient with human immunodeficiency virus infection. *J Clin Microbiol* 43 : 4895-4897, 2005
2. Carpenter J, Stapleton S, Holliman R : Retrospective analysis of 49 cases of brain abscess and review of the literature. *Eur J Clin Microbiol Infect Dis* 26 : 1-11, 2007
3. Chung TT, Lin JC, Hsieh CT, Chen GJ, Ju DT : *Nocardia farcinica* brain abscess in an immunocompetent patient treated with antibiotics and two surgical techniques. *J Clin Neurosci* 16 : 1675-1677, 2009
4. Fellows GA, Kalsi PS, Martin AJ : *Nocardia farcinica* brain abscess in a patient without immunocompromise. *Br J Neurosurg* 21 : 301-303, 2007

5. Fihman V, Berçot B, Mateo J, Losser MR, Raskine L, Riahi J, et al. : First successful treatment of *Nocardia farcinica* brain abscess with moxifloxacin. *J Infect* 52 : e99-e102, 2006
6. Gleckman R, Altschullter C : Trimethoprim-sulphamethoxazole in Gorbach SL, Barlett JG, Blacklow NR (eds) : *Infectious Disease*. Philadelphia : Lippincott Williams and Wilkins, 2004, pp247
7. Hur JH, Kwon AH, Gwak HS, Rhee CH : Postoperative brain abscess caused by co-infection of aspergillus and staphylococcus : case report. *J Korean Neurosurg Soc* 33 : 81-84, 2003
8. Iannotti CA, Hall GS, Procop GW, Tuohy MJ, Staugaitis SM, Weil RJ : Solitary *Nocardia farcinica* brain abscess in an immunocompetent adult mimicking metastatic brain tumor : rapid diagnosis by pyrosequencing and successful treatment. *Surg Neurol* 72 : 74-79; discussion 79, 2009
9. Jansson AK, Enblad P, Sjölin J : Efficacy and safety of cefotaxime in combination with metronidazole for empirical treatment of brain abscess in clinical practice : a retrospective study of 66 consecutive cases. *Eur J Clin Microbiol Infect Dis* 23 : 7-14, 2004
10. Kandasamy J, Iqbal HJ, Cooke RP, Eldridge PR : Primary *Nocardia farcinica* brain abscess with secondary meningitis and ventriculitis in an immunocompetent patient, successfully treated with moxifloxacin. *Acta Neurochir (Wien)* 150 : 505-506, 2008
11. Katzung BG, Trevor AJ : Sulfonamids, trimethoprim, and fluoroquinolones in : Katzung BG, Trevor AJ (eds) : *Examination and board review pharmacology*. Norwalk : Appleton and Lange, 1998, pp338-341
12. Kramer MR, Uttamchandani RB : The radiographic appearance of pulmonary nocardiosis associated with AIDS. *Chest* 98 : 382-385, 1990
13. Lai CC, Lee LN, Teng LJ, Wu MS, Tsai JC, Hsueh PR : Disseminated *Nocardia farcinica* infection in a uraemia patient with idiopathic thrombocytopenia purpura receiving steroid therapy. *J Med Microbiol* 54 : 1107-1110, 2005
14. Lee GY, Daniel RT, Brophy BP, Reilly PL : Surgical treatment of nocardial brain abscesses. *Neurosurgery* 51 : 668-671; discussion 671-672, 2002
15. Lerner PI : Nocardiosis. *Clin Infect Dis* 22 : 891-903; quiz 904-905, 1996
16. Malincarne L, Marroni M, Farina C, Camanni G, Valente M, Belfiori B, et al. : Primary brain abscess with *Nocardia farcinica* in an immunocompetent patient. *Clin Neurol Neurosurg* 104 : 132-135, 2002
17. Mamelak AN, Obana WG, Flaherty JF, Rosenblum ML : Nocardial brain abscess : treatment strategies and factors influencing outcome. *Neurosurgery* 35 : 622-631, 1994
18. Mathisen GE, Johnson JP : Brain abscess. *Clin Infect Dis* 25 : 763-779, 1997
19. Patchell RA : Neurological complications of organ transplantation. *Ann Neurol* 36 : 688-703, 1994
20. Selby R, Ramirez CB, Singh R, Kleopoulos I, Kusne S, Starzl TE, et al. : Brain abscess in solid organ transplantation recipients receiving cyclosporine-based immunosuppression. *Arch Surg* 132 : 304-310; quiz 780-781, 1997
21. Sim SH, Park HC, Kim CJ, Jeon JH, Kim EC, Oh MD, et al. : A case of *Nocardia farcinica* brain abscess in the patient receiving steroid treatment. *Infect Chemother* 40 : 301-304, 2008
22. Sonesson A, Oqvist B, Hagstam P, Björkman-Burtscher IM, Miörner H, Petersson AC : An immunosuppressed patient with systemic vasculitis suffering from cerebral abscesses due to *Nocardia farcinica* identified by 16S rRNA gene universal PCR. *Nephrol Dial Transplant* 19 : 2896-2900, 2004
23. Tatti KM, Shieh WJ, Phillips S, Augenbraun M, Rao C, Zaki SR : Molecular diagnosis of *Nocardia farcinica* from a cerebral abscess. *Hum Pathol* 37 : 1117-1121, 2006
24. Viganò SM, Edefonti A, Ferrareso M, Ranzi ML, Grossi P, Righini A, et al. : Successful medical treatment of multiple brain abscesses due to *Nocardia farcinica* in a paediatric renal transplant recipient. *Pediatr Nephrol* 20 : 1186-1188, 2005
25. Yang SY : Brain abscess : a review of 400 cases. *J Neurosurg* 55 : 794-799, 1981