

Fatal Outcomes in Family Transmission of *Mycoplasma pneumoniae*

T. R. Kannan,¹ R. D. Hardy,^{2,a} J. J. Coalson,³ D. C. Cavuoti,⁴ J. D. Siegel,⁵ M. Cagle,¹ O. Musatovova,¹ C. Herrera,¹ and J. B. Baseman¹

¹Department of Microbiology and Immunology, The University of Texas Health Science Center at San Antonio; ²Department of Internal Medicine and Pediatric Infectious Diseases, University of Texas Southwestern Medical Center, Dallas; ³Department of Pathology, The University of Texas Health Science Center at San Antonio; ⁴Department of Pathology, and ⁵Department of Pediatrics, University of Texas Southwestern Medical Center, Dallas

Background. *Mycoplasma pneumoniae* continues to be a significant cause of community-acquired pneumonia and, on rare occasions, manifests as fulminant disease that leads to mortality, even in healthy individuals.

Methods. We conducted a retrospective study on members of a family who were quarantined by the Centers for Disease Control and Prevention in 2002 for respiratory failure and death of a 15-year-old brother (sibling 1) and a 13-year-old sister (sibling 2). Collected airway, cerebrospinal fluid (CSF), and serum samples from both deceased siblings and serum samples from both parents and the remaining 3 ill siblings (sibling 3–5) were tested using a range of diagnostic assays. Autopsy lung tissue samples from sibling 2 were also assessed using immunohistochemical and immunoelectron microscopic methods.

Results. Autopsy evaluation of sibling 1 revealed cerebral edema consistent with hypoxic ischemic encephalopathy and pulmonary findings of bronchiolitis obliterans with organizing pneumonia (BOOP). Postmortem lung examination of sibling 2 revealed lymphoplasmacytic bronchiolitis with intraluminal purulent exudate, BOOP, and pulmonary edema. Results of diagnostic assays implicated the household transmission of *M. pneumoniae* among all 5 siblings and both parents. Further analysis of lung tissue from sibling 2 demonstrated the presence of *M. pneumoniae* organisms and community-acquired respiratory distress syndrome toxin. *M. pneumoniae* was cultured directly from sibling 2 autopsy lung tissue.

Conclusion. Evidence is provided that *M. pneumoniae* was readily transmitted to all members of the household and that the resulting infections led to a spectrum of individual responses with variation in disease progression, including lymphoplasmacytic bronchiolitis, BOOP, and death.

Mycoplasma pneumoniae is an atypical bacterial pathogen without a cell wall that affects both the upper and lower respiratory tracts of children and adults. It is implicated in airway diseases including pneumonia, exacerbation of wheezing, tracheobronchitis, and pharyngitis, as well as extrapulmonary manifestations such as neurological, hematologic, gastrointestinal, and dermatological pathologies [1, 2]. Among *M. pneumoniae*–

infected patients, it is estimated that 3%–10% develop clinical pneumonia and that <5% of cases of pneumonia are severe enough to require hospitalization. *M. pneumoniae*–mediated fulminant pneumonia is considered to be rare, regardless of the high prevalence of the infection in the general population [1, 2].

Although *M. pneumoniae* has been recognized as a significant clinical pathogen for decades, its virulence determinants have only been partially deciphered. Recently, we identified a unique *M. pneumoniae* adenosine diphosphate-ribosylating and vacuolating cytotoxin (designated community-acquired respiratory distress syndrome [CARDS] toxin) [3]. The severity of pulmonary disease caused by *M. pneumoniae* appears to be dependent on biological properties of individual mycoplasma strains and CARDS toxin concentration [4]. Interestingly, CARDS toxin transcription and translation are substantially up-regulated during infection, in

Received 21 April 2011; accepted 15 September 2011; electronically published 3 November 2011.

^aPresent affiliation: ID Specialists PA, Dallas, Texas.

Correspondence: Joel B. Baseman, PhD, Department of Microbiology and Immunology, The University of Texas Health Science Center at San Antonio, 7703 Floyd Curl Dr, MC7758, San Antonio, TX 78229-3900 (baseman@uthscsa.edu).

Clinical Infectious Diseases 2012;54(2):225–31

© The Author 2011. Published by Oxford University Press on behalf of the Infectious Diseases Society of America. All rights reserved. For Permissions, please e-mail: journals.permissions@oup.com.

DOI: 10.1093/cid/cir769

contrast to in vitro growth [5]. Furthermore, CARDS toxin shares similarities to the toxin of *Bordetella pertussis* [3, 6].

The pulmonary presentations of *M. pneumoniae* pneumonia have included cellular bronchiolitis [7], bronchiolitis obliterans with organizing pneumonia (BOOP) or without organizing pneumonia [7–9], bronchiectasis, pleural effusion, adult respiratory distress syndrome [10], pulmonary embolism [11], chronic interstitial fibrosis [12], and lung abscess [13]. The current literature stresses the benign and often subclinical nature of many of these infections; hence, the term “walking pneumonia” is sometimes used to describe *M. pneumoniae* pneumonia. However, cases of fulminant pneumonia due to *M. pneumoniae* have been encountered with resultant respiratory failure or death [8].

In this study, we describe a range of clinical manifestations associated with *M. pneumoniae* infection in a previously healthy family. To our knowledge, for the first time, *M. pneumoniae*-mediated disease progression is described in terms of mycoplasma load, CARDS toxin detection, and individual subject immunological and clinical responsiveness to infection.

MATERIALS AND METHODS

Collection of Samples

Patients' samples were obtained for testing from the family members after consent as approved by the institutional review board (IRB) of The University of Texas Southwestern Medical Center (IRB no. 0802-447). Informed consent was obtained from legal guardians and informed assent was obtained from patients ≥ 10 years of age. The University of Texas Health Science Center at San Antonio IRB determined that this study did not require IRB review.

Bacterial Strains and Recombinant Proteins

M. pneumoniae reference strain M129 and a clinical isolate designated SA1 were grown in SP4 broth. Recombinant P1 adhesin carboxyl immunodominant domain (rP1-C) and recombinant CARDS toxin (rCARDS toxin) were expressed and purified as reported elsewhere [3, 14].

Polymerase Chain Reaction (PCR) and Quantitative Real-time PCR (qPCR) Detection of *M. pneumoniae* Infection

Collected lung tissue, cerebrospinal fluid (CSF), and serum samples from both deceased siblings and serum samples alone from the parents and the remaining 3 ill siblings were subjected to DNA extraction using the QIAmp DNA Mini Kit (Qiagen, Valencia, CA). Detection of *M. pneumoniae* was by PCR and qPCR using P1 nucleotide sequences [15].

Isolation of *M. pneumoniae* Strain SA1 and Subtyping

Lung samples from the deceased 13-year-old subject were incubated in SP4 broth and subsequently plated on SP4 agar. Single mycoplasma colonies were picked and cloned in SP4

medium and compared with reference strain M129 by use of sodium dodecyl sulfate polyacrylamide gel electrophoresis (SDS-PAGE) analysis of total mycoplasma proteins and immunoblotting against specific *M. pneumoniae* proteins. To further characterize the *M. pneumoniae* clinical isolate, we used P1 adhesin repetitive element-based PCR restriction fragment length polymorphism assays (P1-PCR-RFLP [16]). In addition, PCR-amplified full-length CARDS toxin gene was sequenced to determine nucleotide differences between reference and clinical strains (GenBank accession no. ABE27143).

Detection of Antibodies Against *M. pneumoniae*

Serum samples from each subject and CSF samples from siblings 1 and 2 were analyzed using enzyme-linked immunosorbent assay (ELISA) and immunoblotting against total cell lysates of both *M. pneumoniae* reference and SA1 strains and using ELISA against rCARDS toxin and rP1-C as indicator proteins [14].

Histological, Immunohistochemical, and Immunoelectron Microscopic Assessments

Lung autopsy samples were examined as described elsewhere [17]. Briefly, paraffin-embedded sections were cut at 4- μ m thickness and stained with hematoxylin-eosin. Rabbit antiserum reactive against rCARDS toxin and mouse anti-P1 monoclonal antibody (US Biological, Swampscott, MA) at 1:1500 and 1:10 dilutions, respectively, were incubated with representative lung sections, which were then stained with diaminobenzidine chromagen (Vector Laboratories, Burlington, CA) [17]. Control sections were treated similarly but without primary antibodies. For immunogold electron microscopy, lung samples were processed and analyzed for the presence of *M. pneumoniae* using anti-P1 rabbit antiserum (1:100 dilution) as reported elsewhere [5].

RESULTS

Case Report

All 5 children of a family were admitted to a pediatric hospital in Dallas, Texas, over a period of 5 days; 2 of the children experienced a fatal outcome. All siblings were previously healthy without contributory past medical history and were home-schooled. Table 1 details the age, sex, clinical presentation, and diagnostic assessment of the subjects, and the timeline graph in Figure 1 indicates the onset of symptoms and time of diagnosis.

15-Year-Old Deceased Male Sibling (Sibling 1)

A 15-year-old white male was admitted in August 2000 to the pediatric intensive care unit for sudden onset of respiratory failure. He was in his usual state of health until 2 days prior to admission when he developed sore throat, cough, and rhinorrhea with no noted fever, headache, or altered mental status. On the morning of admission, his family was not able to arouse him from sleep but confirmed him to be breathing and with heart-beat. The family then noted cessation of breathing and called

Table 1. Characteristics of *Mycoplasma pneumoniae* Infection Within a Family By Use of Serum Samples

Parameters	Sibling 1 ^a	Sibling 2 ^a	Sibling 3	Sibling 4	Sibling 5	Father	Mother
Age in years	15	13	6	10	17	NA	NA
Sex	Male	Female	Male	Female	Male	Male	Female
Diagnosis	Respiratory failure/arrest	Respiratory failure/arrest	Respiratory infection	Respiratory infection	Pneumonia	NCE	NCE
Test results							
PCR	+	+	+	+	+	-	-
ELISA IgM P1 ^b	++	-	++	+	++++	-	-
CARDS toxin	++++	-	++	++	++++	-	-
ELISA IgG P1 ^b	++++	-	+	++	+++	++	++
CARDS toxin	-	+	+	+	++++	++	++
Immunoblot P1 ^c	+++	-	+	++	++	+	+
CARDS toxin ^b	+	±	-	+++	+	+	+
<i>M. pneumoniae</i> WCL ^d	++	±	+	++	+++	+++	++

Abbreviations: CARDS, community-acquired respiratory distress syndrome; ELISA, enzyme-linked immunosorbent assay; Ig, immunoglobulin; NA, not available; NCE, not clinically evaluated; PCR, polymerase chain reaction; WCL, whole cell lysate.

^a Death.

^b ELISA positivity was determined based on optical density (405 nm) readings. OD₄₀₅ values of <0.2 were considered to be negative. ELISA positivity: -, negative; +, 0.2-0.4; ++, 0.41-0.6; +++, 0.6-0.8; +++++, >0.8.

^c Immunoblot positivity: -, negative; +/-, threshold level; +, low intensity; ++, medium intensity; +++, strong intensity.

^d Immunoblot profiles using *M. pneumoniae* strains SA1 and M129 were similar.

paramedics, who found the patient to be pulseless with cardiac electrical activity and initiated cardiopulmonary resuscitation (CPR) including endotracheal intubation. On admission to the hospital, physical examination was only notable for a febrile (39°C), sedated, and mechanically ventilated male patient. Initial chest X-ray radiograph revealed multifocal parenchymal opacities involving the perihilar regions and lower lobes. The patient continued with intermittent fevers throughout his hospital course, during which a maculopapular rash developed. General laboratory studies (complete blood cell count, liver function tests, electrolyte levels, and creatinine levels) were remarkable for an initial white blood cell count of 13.2 k/μL, initial

aspartate aminotransferase level of 247 U/L, and initial alanine aminotransferase level of 506 U/L; these values normalized over the course of hospitalization. Toxicology testing was negative. CSF indices were within reference limits, except for a white blood cell count of 22 cells/μL.

An infectious diseases evaluation was performed. Endotracheal aspirates revealed many white blood cells with no bacteria seen on Gram stain and no growth of bacteria on routine culture. Viral direct fluorescence assays on nasopharyngeal specimens for respiratory syncytial virus, adenovirus, influenza virus, and parainfluenza virus and viral culture were negative. Blood, urine, and cerebral spinal fluid bacterial cultures were without

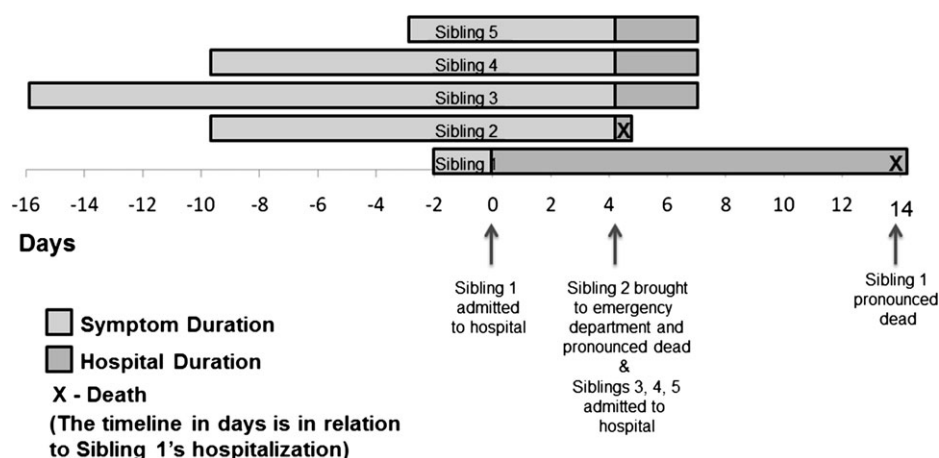


Figure 1. Timeline graph showing the onset of symptoms and time of diagnosis of the siblings. Further details of the siblings are included in Table 1.

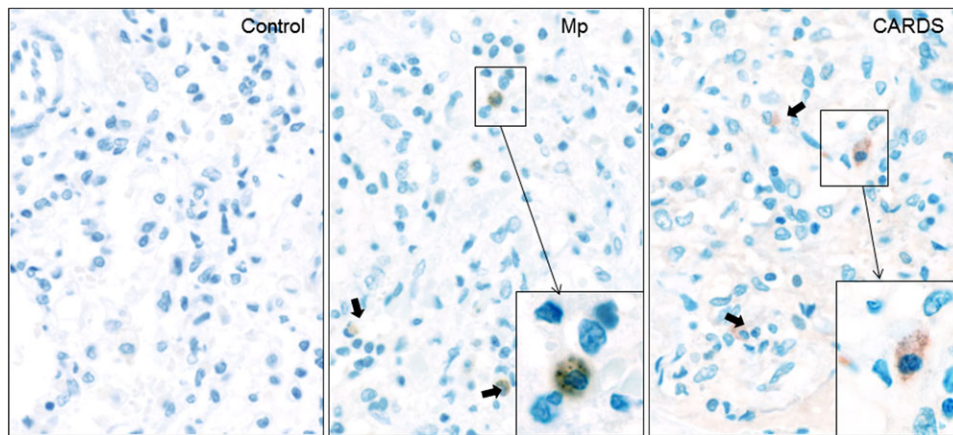


Figure 2. Immunolocalization of *Mycoplasma pneumoniae* and community-acquired respiratory distress syndrome (CARDS) toxin in lung specimen of sibling 2. In focal peribronchiolar sites, intra-alveolar collections of alveolar macrophages and monocytes were present, some of which showed positively-immunostained intracytoplasmic mycoplasma aggregates and CARDS toxin. Bold arrows indicate immunostained aggregates of mycoplasma organisms (Mp panel) and CARDS toxin (CARDS panel) that are similar in size and distribution (original magnification $\times 40$). Insets indicate the higher magnification of same (original magnification $\times 60$).

growth. Commercially available PCR assays for enterovirus, herpes simplex virus, and *M. pneumoniae* on CSF were negative. Serum immunofluorescence assays for St Louis encephalitis virus immunoglobulin M (IgM) and immunoglobulin G (IgG), West Nile virus IgM and IgG, California encephalitis virus IgM and IgG, and *Legionella* species were negative. Serum *Chlamydia* species IgG and human immunodeficiency virus (HIV) ELISAs were negative. However, serum *M. pneumoniae* IgM and IgG ELISAs were positive at 1:80 and 1:160, respectively (ARUP Laboratories, UT); serum *M. pneumoniae* complement fixation was positive at $>1:256$. Total serum IgM and IgG levels were normal. Over the hospital course, the subject received broad-spectrum antibiotics, including gatifloxacin, clindamycin, ceftriaxone, azithromycin, and doxycycline. His neurological status never improved beyond minimal response to painful stimuli, even when all sedation was stopped, and computed tomography of the brain was consistent with severe global hypoxic ischemic injury. Support was withdrawn 14 days after admission. The findings recorded in the autopsy report included cerebral edema consistent with hypoxic ischemic encephalopathy, with no evidence of encephalitis or meningitis, and acute and organizing pneumonia with BOOP. Because the complement fixation test to detect *M. pneumoniae* infection is based on crude lipid antigen that contains glycolipids that occur commonly in plants and bacteria [18] and even in human brain tissue [19], we further confirmed the positive *M. pneumoniae* serologic results by measuring IgM and IgG serum responses to *M. pneumoniae* unique rP1-C and rCARDS toxin proteins. As shown in Table 1, the subject exhibited strong immunoresponsiveness against these *M. pneumoniae* proteins. In addition, PCR analysis for *M. pneumoniae* was positive.

13-Year-Old Deceased Female Sibling (Sibling 2)

The 13-year-old sister was noted to exhibit 2 weeks of respiratory symptoms similar to those preceding sibling 1's sudden onset of respiratory failure. Four days after sibling 1 was admitted to the hospital, sibling 2 developed fever and complained of dyspnea. She was found unresponsive in her bed the next morning by her family; paramedics confirmed her to be asystolic and initiated CPR. She was pronounced dead after advanced cardiac life support failed to revive her in the emergency center. Premortem bacterial blood and sputum cultures and nasopharyngeal viral culture were unrevealing. Total serum immunoglobulin levels were low (IgG level, 322 mg/dL; IgM level, 24 mg/dL; IgA level, 32 mg/dL). HIV test was negative.

Detection of serum *M. pneumoniae* IgM and IgG levels was negative by commercial laboratory testing, in contrast to sibling 1. Lymphoplasmatic bronchiolitis and focal sites of BOOP and alveolar edema and intra-alveolar hemorrhages were histopathological findings at autopsy. Some of the bronchioles also contained an intraluminal exudate of neutrophils, admixed with monocytes and epithelial debris that extended into subjacent alveoli, (ie, focal bronchopneumonia). Postmortem lung stains and/or cultures were negative for routine bacteria, acid-fast bacilli, fungi, *Legionella* species, and viruses. However, *M. pneumoniae* PCR (ARUP Laboratories, UT) was positive on lung tissue. Furthermore, our studies indicated positive *M. pneumoniae* serum PCR (Table 1) and lung tissue qPCR; in the latter case, 8×10^7 *M. pneumoniae* genome copies were detected per gram of lung tissue. Immunostaining using mouse monoclonal antibodies reactive against P1 adhesin protein revealed *M. pneumoniae* organisms localized to the surface of bronchiolar epithelium (Figure 2, Mp).

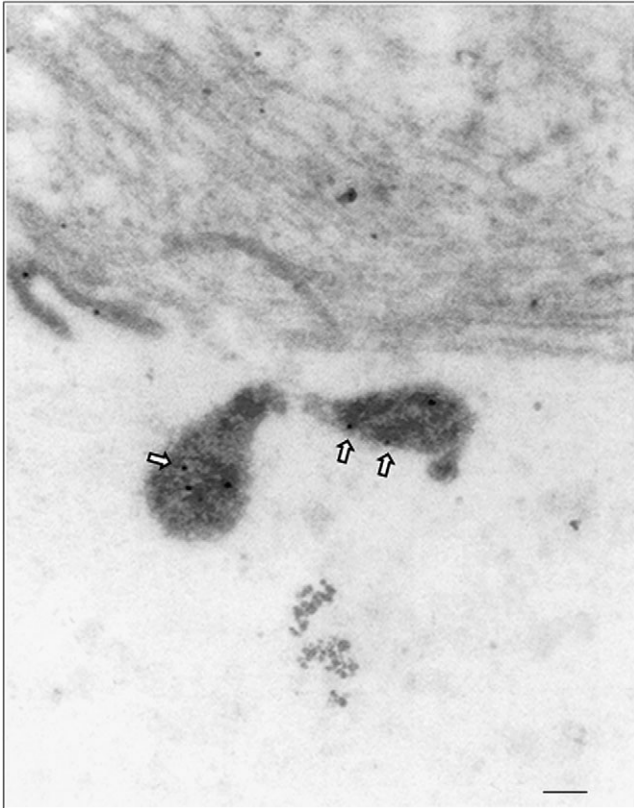


Figure 3. Immunogold electron microscopic detection of *Mycoplasma pneumoniae* in lung tissue of sibling 2. *M. pneumoniae* cells were gold-particle-labeled with anti-*M. pneumoniae* antibodies (arrows) as described in the Materials and Methods. Mycoplasma cells were visualized with a JEOL 1230 transmission electron microscope. Gold labeling (arrows) reveals *M. pneumoniae* with its characteristic tip organelle (scale bar, 0.1 μ m).

Importantly, immunostaining of lung sections also revealed the presence of CARDS toxin (Figure 2, CARDS) associated with alveolar macrophages. Furthermore, immunoelectron microscopy clearly demonstrated *M. pneumoniae* organisms in the lungs (Figure 3). We also were able to successfully culture *M. pneumoniae* organisms from sibling 2's lung specimens at 2 independent research laboratories (The University of Texas Southwestern Medical Center at Dallas and The University of Texas Health Science Center at San Antonio). In an attempt to understand the unusual severity of these *M. pneumoniae* infections, we further characterized the *M. pneumoniae* clinical isolate designated as SA1, which was isolated in San Antonio. This strain was confirmed as *M. pneumoniae* by sequencing of the CARDS toxin gene, by comparing SA1 protein profiles with reference strain M129 using SDS-PAGE and immunoblotting against major *M. pneumoniae* proteins (P1, P30, ClpB, CARDS toxin, pyruvate dehydrogenase subunits A and B, and elongation factor Tu), and by subtyping, which determined the clinical isolate to be categorized as type II-b using P1-PCR-RFLP.

Interestingly, sibling 2 did not demonstrate a notable humoral immune response to *M. pneumoniae* proteins (Table 1).

Siblings 3, 4, and 5, and Parents

The 6-year-old brother, 10-year-old sister, and 17-year-old brother were admitted to the hospital on the same day that sibling 2 died. These children had been experiencing respiratory symptoms, mainly consisting of cough and rhinorrhea without fever, for 1–3 weeks. Two of the children had experienced a nonspecific erythematous rash, and one had experienced myalgias and arthralgias prior to admission. On admission, general laboratory studies (complete blood cell count, liver function tests, electrolyte levels, and creatinine levels) and physical examination were unremarkable, except that one child had scattered rales on chest auscultation. In addition, total IgG, IgM, and IgA levels were normal for all siblings. Chest X-ray radiographs revealed focal infiltrates consistent with pneumonia and bronchial wall involvement among the surviving 3 siblings. The 3 siblings were tested for infectious agents in a similar manner as for sibling 1, except CSF samples were not obtained, and the results were similarly unrevealing. However, serum ELISA for *M. pneumoniae* total IgG and IgM were positive in siblings 3, 4, and 5. All 3 children plus both parents (Table 1) were immunoblot positive against *M. pneumoniae* whole cell lysates, CARDS toxin, and/or P1 (Table 1). Both parents exhibited detectable serum *M. pneumoniae* IgG levels. Furthermore, PCR analysis revealed the presence of *M. pneumoniae* in serum samples of the 6-, 10-, and 17-year-olds but not in those of the mother or father. Azithromycin therapy was prescribed for these siblings, and recovery was uneventful. The parents were not clinically evaluated (Table 1).

DISCUSSION

Since the first report of fatal *M. pneumoniae* infection [20], severe cases have been reported sporadically. In the previous reviews of fatal *M. pneumoniae* infection, death was associated with diffuse pneumonia, adult respiratory distress syndrome, vascular thrombosis, and disseminated intravascular coagulation [20–23]. Histopathological analyses of tissues from fatal cases of *M. pneumoniae* pneumonia [7–9, 24] and from *M. pneumoniae*-infected animal models [17, 25] have shown ulceration and destruction of ciliated epithelium of bronchi and bronchioles, edema of bronchial and bronchiolar walls, bronchiolar and alveolar infiltrates of macrophages and lymphocytes, and bronchiolitis obliterans. Chan and Welsh [8] reviewed cases of *M. pneumoniae* pneumonia that resulted in respiratory failure and death and reported that fulminant cases were more common in young healthy adults. Rollins et al [7] observed BOOP based on open lung biopsy and emphasized that *M. pneumoniae* causation is often omitted from differential diagnosis. In the present study, both deceased siblings had

experienced respiratory symptoms for about 2 weeks before their acute cardiopulmonary failure episodes, so the findings of a reparative lung response, such as BOOP, could be expected. However, the primary lung finding in sibling 2 was lymphoplasmacytic bronchiolitis with intraluminal exudate, a pattern reported in *M. pneumoniae*-infected humans and experimentally infected animals.

In earlier animal studies centered on localizing *M. pneumoniae* in tissue sites, mycoplasmas were identified primarily on the surface of airway epithelium whereas evidence of tissue inflammation and tissue injury throughout the bronchial walls suggested diffusion of unknown mycoplasma products from the surface epithelium into deeper tissues. Since our discovery of CARDS toxin, we showed that CARDS toxin, along with *M. pneumoniae* organisms, can be detected on respiratory epithelium surfaces of infected lungs and in peribronchiolar alveolar spaces that contained inflammatory exudates of edema, neutrophils, and alveolar macrophages and monocytes [17]. Furthermore, rCARDS toxin alone elicits airway vacuolization and cytotoxicity and extensive peribronchial and perivascular cellular inflammation in baboons and mice after inoculation into lungs [26]. We also reported that CARDS toxin concentrations in bronchiolar lavage fluids of infected mice are directly related to *M. pneumoniae* organism load and disease severity [4]. In the lung tissue of sibling 2, we observed the localization and distribution of *M. pneumoniae* and CARDS toxin by immunohistochemical staining. We also detected *M. pneumoniae* organisms by immunogold electron microscopy. The substantial load of *M. pneumoniae* genomes within the lung of sibling 2, the detection of CARDS toxin, and the extensive lung pathology clearly reinforce the contributory roles of *M. pneumoniae* to disease progression. Most likely, the heavily infected lung tissue of sibling 2 permitted isolation of *M. pneumoniae* strain SA1 subtype II-b from lung specimen. Interestingly, in our prior investigation of various *M. pneumoniae* strains and associated elicited pulmonary disease severity, it was the type II strain that was most adept at colonizing, replicating, and persisting, thus resulting in high concentrations of CARDS toxin in bronchiolar lavage fluids and extensive lung disease [4]. Why there was such a discrepancy in the *M. pneumoniae* IgM and IgG responses between siblings 1 and 2 is unresolved.

Due to the high prevalence of *M. pneumoniae* infections worldwide, severe cases of pneumonia are not uncommon, but they are probably underdiagnosed. However, new methods have been developed to identify *M. pneumoniae* infections [27, 28]. Furthermore, we reported that the CARDS toxin gene-based qPCR assay and the CARDS toxin antigen-based capture assay are highly specific and sensitive in the detection of active infection of *M. pneumoniae* among mechanically ventilated subjects [29] and in a high proportion of adult subjects with refractory asthma [30]. As previously noted, the increase in the

severity of *M. pneumoniae* pneumonia in younger patients may be biased, possibly due to a greater prevalence of infection or increased susceptibility in younger patients. Possibly the siblings (1 and 2) with a fatal outcome had an immunodeficiency, whereas the other siblings who did not have a fatal outcome did not share this immunodeficiency.

In summary, this report highlights the potentially serious nature, as well as the diversity of individual immune response and outcome, of *M. pneumoniae* infection in a previously healthy family. The relatively young age of patients with fatal *M. pneumoniae* infection is of unclear significance. Furthermore, this study is the first, to our knowledge, to link *M. pneumoniae* infection, mycoplasma genome number, and CARDS-toxin-mediated events in human disease, emphasizing the need for improved diagnostic and treatment modalities.

Notes

Acknowledgments. We thank Mark Blaylock for his help with electron microscope images and Rose Garza for her assistance in assembling the manuscript. The content is solely the responsibility of the authors and does not necessarily represent the official views of the National Institute of Allergy and Infectious Diseases or the National Institutes of Health.

Financial support. This study was funded by grants from the National Institutes of Health (U19AI070412) and The Kleberg Foundation, to J. B. B.

Potential conflicts of interest. All authors: No reported conflicts.

All authors have submitted the ICMJE Form for Disclosure of Potential Conflicts of Interest. Conflicts that the editors consider relevant to the content of the manuscript have been disclosed.

References

1. Atkinson TP, Balish MF, Waites KB. Epidemiology, clinical manifestations, pathogenesis and laboratory detection of *Mycoplasma pneumoniae* infections. *FEMS Microbiol Rev* **2008**; 32:956–73.
2. Waites KB, Talkington DF. *Mycoplasma pneumoniae* and its role as a human pathogen. *Clin Microbiol Rev* **2004**; 17:697–728.
3. Kannan TR, Baseman JB. ADP-ribosylating and vacuolating cytotoxin of *Mycoplasma pneumoniae* represents unique virulence determinant among bacterial pathogens. *Proc Natl Acad Sci U S A* **2006**; 103:6724–9.
4. Techasaensiri C, Tagliabue C, Cagle M, et al. Variation in colonization, ADP-ribosylating and vacuolating cytotoxin, and pulmonary disease severity among *Mycoplasma pneumoniae* strains. *Am J Respir Crit Care Med* **2010**; 182:797–804.
5. Kannan TR, Musatovova O, Balasubramanian S, et al. *Mycoplasma pneumoniae* community acquired respiratory distress syndrome toxin expression reveals growth phase and infection-dependent regulation. *Mol Microbiol* **2010**; 76:1127–41.
6. Kannan TR, Provenzano D, Wright JR, Baseman JB. Identification and characterization of human surfactant protein A binding protein of *Mycoplasma pneumoniae*. *Infect Immun* **2005**; 73:2828–34.
7. Rollins S, Colby T, Clayton F. Open lung biopsy in *Mycoplasma pneumoniae* pneumonia. *Arch Pathol Lab Med* **1986**; 110:34–41.
8. Chan ED, Welsh CH. Fulminant *Mycoplasma pneumoniae* pneumonia. *West J Med* **1995**; 162:133–42.
9. Llibre JM, Urban A, Garcia E, Carrasco MA, Murcia C. Bronchiolitis obliterans organizing pneumonia associated with acute *Mycoplasma pneumoniae* infection. *Clin Infect Dis* **1997**; 25:1340–2.

10. Fischman RA, Marschall KE, Kislak JW, Greenbaum DM. Adult respiratory distress syndrome caused by *Mycoplasma pneumoniae*. *Chest* **1978**; 74:471–3.
11. Simmons BP, Aber RC. *Mycoplasma pneumoniae* pneumonia: symptoms mimicking pulmonary embolism with infarction. *JAMA* **1979**; 241:1268–9.
12. Tablan OC, Reyes MP. Chronic interstitial pulmonary fibrosis following *Mycoplasma pneumoniae* pneumonia. *Am J Med* **1985**; 79:268–70.
13. Leonardi S, del Giudice MM, Spicuzza L, Saporito M, Nipitella G, La Rosa M. Lung abscess in a child with *Mycoplasma pneumoniae* infection. *Eur J Pediatr* **2010**; 169:1413–5.
14. Berg CP, Kannan TR, Klein R, et al. Mycoplasma antigens as a possible trigger for the induction of antimitochondrial antibodies in primary biliary cirrhosis. *Liver Int* **2009**; 29:797–809.
15. Ursi D, Dirven K, Loens K, Ieven M, Goossens H. Detection of *Mycoplasma pneumoniae* in respiratory samples by real-time PCR using an inhibition control. *J Microbiol Methods* **2003**; 55:149–53.
16. Sasaki T, Kenri T, Okazaki N, et al. Epidemiological study of *Mycoplasma pneumoniae* infections in Japan based on PCR-restriction fragment length polymorphism of the P1 cytoadhesin gene. *J Clin Microbiol* **1996**; 34:447–9.
17. Kannan TR, Coalson JJ, Cagle M, Musatovova O, Hardy RD, Baseman JB. Synthesis and distribution of CARDS toxin during *Mycoplasma pneumoniae* infection in a murine model. *J Infect Dis* **2011**; 204:1596–1604.
18. Kenny GE, Newton RM. Close serological relationship between glycolipids of *Mycoplasma pneumoniae* and glycolipids of spinach. *Ann New York Acad Sci* **1973**; 225:54–61.
19. Biberfeld G. Antibodies to brain and other tissues in cases of *Mycoplasma pneumoniae* infection. *Clin Exp Immunol* **1971**; 8:319–33.
20. Maisel JC, Babbitt LH, John TJ. Fatal *Mycoplasma pneumoniae* infection with isolation of organisms from lung. *JAMA* **1967**; 202:287–90.
21. Koletsky RJ, Weinstein AJ. Fulminant *Mycoplasma pneumoniae* infection: report of a fatal case, and a review of the literature. *Am Rev Respir Dis* **1980**; 122:491–6.
22. Williamson J, Marmion BP, Kok T, Antic R, Harris RJ. Confirmation of fatal *Mycoplasma pneumoniae* infection by polymerase chain reaction detection of the adhesin gene in fixed lung tissue. *J Infect Dis* **1994**; 170:1052–3.
23. Carrascosa MF, Lucena MI, Andrade RJ, et al. Fatal acute hepatitis after sequential treatment with levofloxacin, doxycycline, and naproxen in a patient presenting with acute *Mycoplasma pneumoniae* infection. *Clin Ther* **2009**; 31:1014–9.
24. Wachowski O, Demirakca S, Muller KM, Scheurlen W. *Mycoplasma pneumoniae* associated organising pneumonia in a 10 year old boy. *Arch Dis Child* **2003**; 88:270–2.
25. Cimolai N, Taylor GP, Mah D, Morrison BJ. Definition and application of a histopathological scoring scheme for an animal model of acute *Mycoplasma pneumoniae* pulmonary infection. *Microbiol Immunol* **1992**; 36:465–78.
26. Hardy RD, Coalson JJ, Peters J, et al. Analysis of pulmonary inflammation and function in the mouse and baboon after exposure to *Mycoplasma pneumoniae* CARDS toxin. *PLoS One* **2009**; 4:e7562.
27. Degrange S, Cazanave C, Charron A, Renaudin H, Bebear C, Bebear CM. Development of multiple-locus variable-number tandem-repeat analysis for molecular typing of *Mycoplasma pneumoniae*. *J Clin Microbiol* **2009**; 47:914–23.
28. Loens K, Ursi D, Goossens H, Ieven M. Molecular diagnosis of *Mycoplasma pneumoniae* respiratory tract infections. *J Clin Microbiol* **2003**; 41:4915–23.
29. Muir MT, Cohn SM, Loudon C, Kannan TR, Baseman JB. Novel toxin assays implicate *Mycoplasma pneumoniae* in prolonged ventilator course and hypoxemia. *Chest* **2011**; 139:305–10.
30. Peters J, Singh H, Brooks EG, et al. Persistence of community-acquired respiratory distress syndrome toxin-producing mycoplasma pneumoniae in refractory asthma. *Chest* **2011**; 140:401–7.