

# Cusp-Level Chordal Shortening for Rheumatic Mitral Regurgitation

## Early Results

**A. Sampath Kumar, MCh**  
**Anil Bhan, MCh**  
**R.V. Kumar, MCh**  
**S. Shrivastava, DM**  
**A.K. Sood, DM**  
**N. Gopinath, MS**

*From February of 1987 through February of 1991, 25 patients with rheumatic mitral disease underwent cusp-level shortening of the chordae of the anterior mitral leaflet as part of the valvular reconstruction procedure at our institutions. All patients had moderate or severe mitral regurgitation, with prolapse of the anterior mitral leaflet. Seventeen patients also had mitral stenosis. Postoperative echocardiograms, both transthoracic and transesophageal, showed correction of leaflet prolapse and mitral regurgitation. This preliminary report suggests that the technique satisfactorily corrects mitral regurgitation in patients with elongated and thickened chordae characteristic of rheumatic mitral disease. (Texas Heart Institute Journal 1992;19:47-50)*

**P**rolapse of the anterior mitral leaflet, usually caused by chordal rupture and elongation, leads to gross mitral regurgitation. The customary technique of repairing elongated chordae, described by Carpentier and colleagues<sup>1</sup> and by Duran,<sup>2</sup> involves shortening the chorda or chordae at the level of the papillary muscle. Frater<sup>3</sup> was the first to describe the technique of shortening at the cusp level. Here we relate our experience with cusp-level chordal shortening in 25 patients with rheumatic mitral regurgitation.

## Patients and Methods

### Patients

Of the 150 consecutive patients at our institutions who underwent mitral valve reconstruction for mitral regurgitation from February of 1987 through February of 1991, 25 patients underwent chordal shortening. There were 14 males and 11 females, ranging in age from 7 to 28 years. All had rheumatic mitral regurgitation, and all had prolapse of the anterior mitral leaflet, with elongation of one or more chordae. In 18 patients the regurgitation was severe, and in 7 it was moderate. The mean transmitral gradient was 13 mmHg. Six patients were in atrial fibrillation, and 19 were in sinus rhythm.

Ten patients had 1 chorda shortened by this technique, whereas 9 patients had 2 chordae shortened, 4 patients had 3, 1 patient had 4, and 1 patient had 5.

**Concomitant Repairs.** Seventeen patients had mitral stenosis in addition to mitral regurgitation. Three patients underwent concomitant repair of the tricuspid valve. Seventeen patients required open mitral commissurotomy, in addition to chordal shortening, due to fusion at one or both commissural ends. In 7 patients, 1 papillary muscle required splitting. In 2 patients, a fenestration was required of 1 papillary muscle and chordae.

### Methods

**Echocardiographic Studies.** Transthoracic echocardiographic studies were performed on all 25 patients, using ATL Ultramark 8/9 equipment (Advanced Technology Laboratories; Bothell, Washington, USA); in 10 of the more recent patients, this was supplemented by transesophageal echocardiography (Fig. 1A) performed under topical Xylocaine anesthesia, using Hewlett Packard Sonos 1000 equipment (77030A Ultrasound System, Hewlett Packard Co.; Andover, Massachusetts, USA), with a single-plane 5-MHz Hewlett-Packard transducer. Anatomic details of the

**Key words:** Chordae tendineae; chordal shortening; echocardiography; Doppler; mitral valve prolapse; mitral valve stenosis

**From:** Cardiothoracic Sciences Centre, All India Institute of Medical Sciences (Drs. A.S. Kumar, Bhan, R.V. Kumar, and Shrivastava), and SBISR Centre for Heart Care & Rehabilitation, (Drs. Sood and Gopinath), New Delhi, India

**Address for reprints:** Dr. A. Sampath Kumar, Department of Cardiothoracic and Vascular Surgery, All India Institute of Medical Sciences, Ansari Nagar, New Delhi-110029, India

mitral valve apparatus were studied, with special attention to chordal structures. Pulsed Doppler or color-flow mapping, or both, were done to quantify the degree of mitral regurgitation. In all 25 patients, echocardiographic studies were conducted preoperatively, and were repeated postoperatively within 3 weeks of surgical repair. The 10 patients who had undergone preoperative transesophageal echocardiography were studied again between the 6th and 14th postoperative days (Fig. 1B). All 25 patients underwent repeat transthoracic echocardiography at 1 month, 3 months, 6 months, and 12 months postoperatively.

**Technique of Chordal Shortening.** All patients underwent mitral valve reconstruction under cardiopulmonary bypass. Systemic hypothermia (30 °C) and cold potassium cardioplegia were used for myocardial protection. In patients with mitral stenosis, this condition was corrected prior to chordal shortening. The chorda to be shortened was then located,

and a silk thread was looped around both it and the opposite (posterior cusp) chorda (Fig. 2A). The left ventricle was then filled with saline solution, and the length of chorda to be shortened was determined by assessing the anterior mitral leaflet's degree of prolapse (Fig. 2B). A traction suture was placed at the tip of the papillary muscle where the chorda originates. Traction on this suture, and countertraction on the leading edge of the cusp, provided excellent exposure of the chorda. A 5-0 polypropylene double-armed suture was taken and the needle passed through the chorda, and then through the edge of the anterior mitral leaflet close to its point of attachment (Fig. 2C). If more than 1 chorda needed to be shortened, the other end of the suture was passed through the adjacent chorda in a similar fashion. Both needles could then be passed through the thickened edge of the cusp. The suture was then tied (Fig. 2D). A posterior semicircular annuloplasty was done, using a strip of Teflon felt.

The repair was assessed by filling the left ventricle with saline solution, to observe the movement of the anterior mitral leaflet and to watch for mitral regurgitation. If the repair was satisfactory, the left atrium was closed and the patient was rewarmed. Cardiopulmonary bypass was discontinued after de-airing the heart and removing the aortic clamp. Mitral regurgitation was assessed by observing the left atrial pressure tracing for normal sinus rhythm and good hemodynamics.

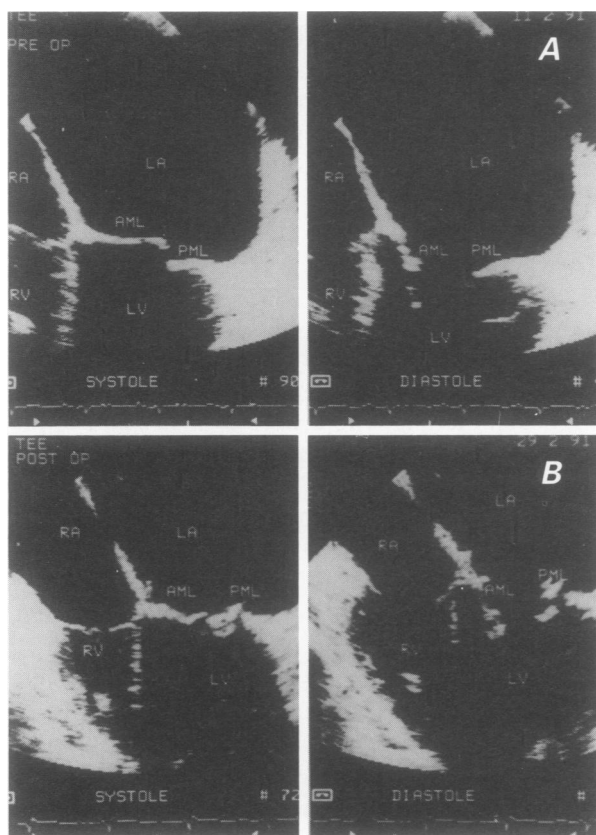
## Results

Although 2 patients died (1 of hepatitis at 6 weeks and another of cerebral infarction at 2 months), there were no operative deaths in these 25 patients; and prolapse of the anterior mitral leaflet was adequately corrected in all patients. The follow-up period for the 23 survivors ranged from 6 to 23 months, with a mean of 11.6 months. All patients received oral anticoagulation for 6 weeks and dipyridamole for 6 months.

Postoperative echocardiography showed no or trivial mitral regurgitation in all patients. Postoperative mitral valve area as demonstrated by transesophageal echocardiography (in the 10 patients who underwent that procedure) was 2.0 to 3.3 cm<sup>2</sup> (mean, 2.8 cm<sup>2</sup> unindexed). The mean transmitral gradient was 4.5 mmHg. During the immediate postoperative period, 2 patients were in atrial fibrillation, and 23 were in sinus rhythm. No patient has returned with symptoms or has required reoperation.

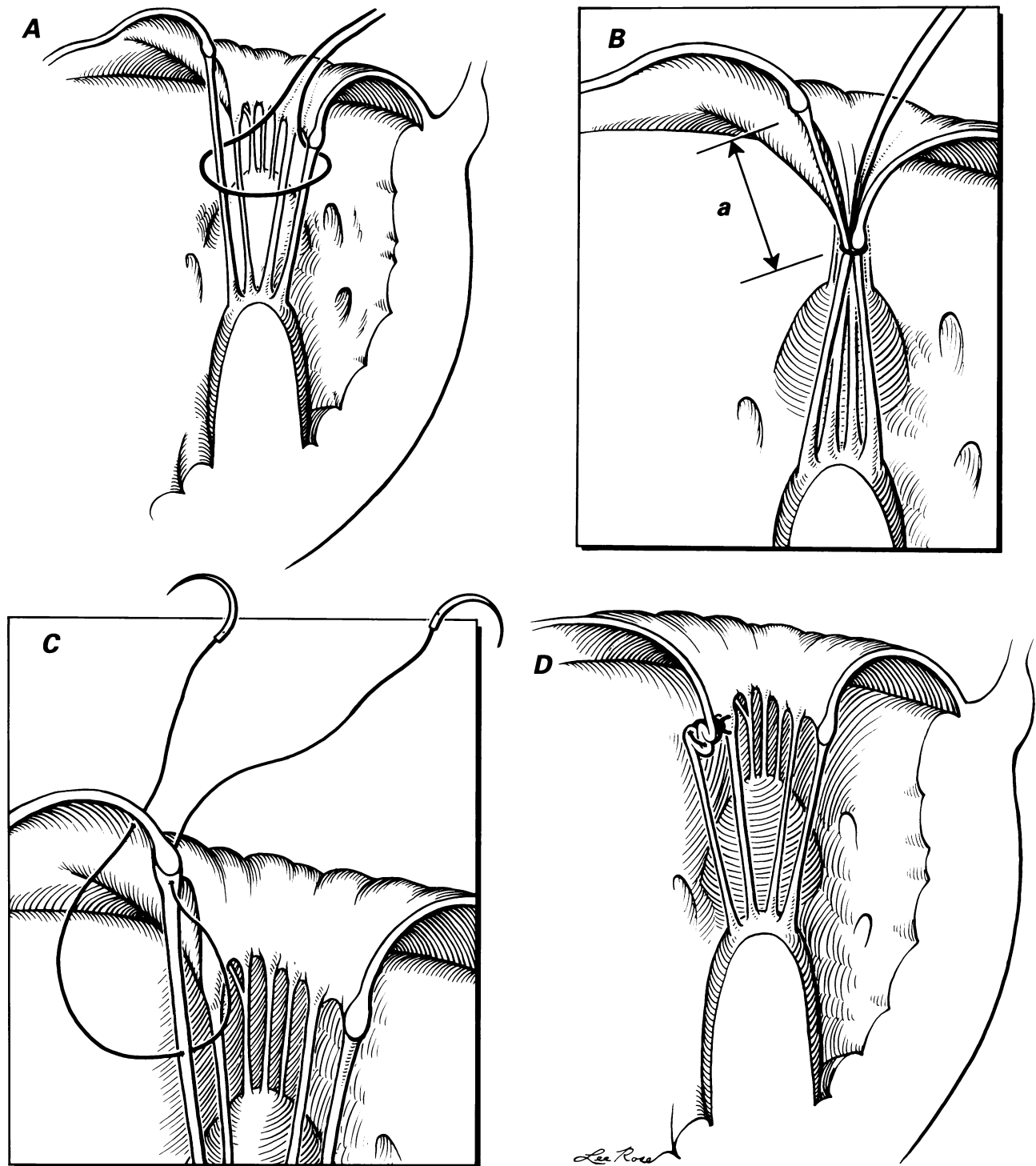
## Discussion

The customary technique for chordal shortening has been the technique described by Carpentier and co-



**Fig. 1** Representative result of cusp-level chordal shortening as demonstrated by transesophageal echocardiography: **A**) preoperative systolic (left) and diastolic (right) frames show prolapse of the anterior mitral leaflet; and **B**) postoperative systolic (left) and diastolic (right) frames show correction of the prolapse.

AML = anterior mitral leaflet; LA = left atrium; LV = left ventricle; PML = posterior mitral leaflet; RA = right atrium; RV = right ventricle; TEE = transesophageal echocardiography



**Fig. 2** Technique of chordal shortening: **A**) a silk suture is passed around both the chorda to be shortened and the opposite (posterior cusp) chorda; **B**) after the left ventricle has been filled with saline solution, the silk suture is tightened so that the anterior mitral leaflet's degree of prolapse can be assessed and the length of chorda to be shortened (**a**) can be determined; **C**) after exposure of the chorda with a traction suture (not shown), a 5-0 polypropylene double-armed suture is taken, and the needle is passed through the chorda and then through the edge of the anterior mitral leaflet close to its point of attachment; and **D**) the polypropylene suture is tied, shortening the chorda at cusp level.

workers<sup>1</sup> and by Duran.<sup>2</sup> Frater<sup>3</sup> described chordal shortening at the cusp level, but to our knowledge his technique has not been widely used. In recent

years, however, we have used it in all our patients with prolapse of the anterior mitral leaflet caused by rheumatic fever because we believe it corrects the

prolapse satisfactorily and is more easily performed.

Prolapse of the anterior mitral leaflet can occur in rheumatic valvular disease due to elongation of chordae. This may be associated with thickening and fusion at one or both commissural ends, as was seen in 17 of our patients. A combination of open commissurotomy and chordal shortening will then be required. These early results suggest that this technique can correct prolapse and mitral regurgitation satisfactorily in rheumatic mitral disease.

In their 1983 report<sup>4</sup> of an alternative technique for the correction of chordal elongation—the use of autologous and xenograft pericardium\* to construct new chordae—Frater and co-authors classified as type 3 the mitral regurgitation due to elongated, thickened chordae in rheumatic heart disease. It is in this group that we have used the newer technique of chordal shortening at cusp level. (This technique is not suitable when chordae are thin.) In our patients, we have not found it necessary to construct new chordae.

\* New chordae have also been constructed of expanded PTFE (polytetrafluoroethylene) stents by Revuelta and coworkers,<sup>5</sup> but this technique was applied only to animal models.

---

## Acknowledgment

---

The authors wish to thank Mr. Lee Rose for the illustrations.

---

## References

---

1. Carpentier A, Chauvaud S, Fabiani JN, et al. Reconstructive surgery of mitral valve incompetence: ten-year appraisal. *J Thorac Cardiovasc Surg* 1980;79:338-48.
2. Duran CMG. Techniques in mitral valve reconstruction. In: Starek PJK, ed. *Heart valve replacement and reconstruction: clinical issues and trends*. Chicago: Year Book Medical Publishers, 1987:115-23.
3. Frater RWM. Mitral valvuloplasty. In: Roberts AJ, Conti CR, eds. *Current surgery of the heart*. Philadelphia: Lippincott, 1987:62-77.
4. Frater RWM, Gabbay S, Shore D, Factor S, Strom J. Reproducible replacement of elongated or ruptured mitral valve chordae. *Ann Thorac Surg* 1983;35:14-28.
5. Revuelta JM, Garcia-Rinaldi R, Gaité L, Val F, Garijo F. Generation of chordae tendineae with polytetrafluoroethylene stents: results of mitral valve chordal replacement in sheep. *J Thorac Cardiovasc Surg* 1989;97:98-103.