

Interrupted Right-Sided Aortic Arch

Patrick T. Roughneen, MB, ChB
Daniel Wallach, MD
David O. Ott, MD

Incomplete development of a right-sided interrupted aortic arch has not, to our knowledge, been recorded in the literature. We present a case of a 6-day-old neonate delivered at 37 weeks' gestation with an incomplete right-sided aortic arch. The anomaly was repaired with a 1-step surgical approach and the patient was discharged from the hospital.

We propose a classification system for right-sided interrupted aortic arch based on that of the more common left-sided interruption. (Texas Heart Institute Journal 1993; 20:112-4)

Both interrupted aortic arch and right-sided aortic arch constitute rare anomalies representing 1% and 2.6%, respectively, of all congenital heart defects.¹⁻⁸ Although isolated right-sided arch is a relatively innocuous condition in terms of patient longevity, interrupted arch is a highly lethal anomaly accounting for 4% of all deaths from heart disease in the 1st month of life.^{1,5} The median age of death for an infant with an untreated interrupted arch is 4 to 10 days, and overall mortality at 1 month of life is 76%.¹

Incomplete development of a right-sided arch has not, to our knowledge, been recorded in the literature. We present a 6-day-old neonate with an incomplete right-sided aortic arch, and we propose a system of nomenclature for the classification of this anomaly based on that of left-sided arch interruptions reported by Celoria and Patton.⁹

Case Report

A 6-day-old male neonate, delivered at 37 weeks' gestation, presented with respiratory distress. Chest radiography showed evidence of cardiomegaly. Echocardiography and cardiac catheterization revealed a right-sided interrupted aortic arch with mirror-image branching between the right common carotid and subclavian arteries, as well as a secundum-type atrial septal defect (ASD) and a ventricular septal defect (VSD) (Fig. 1).

The right-sided incomplete arch was surgically repaired on 3 December 1991. After cannulation, the aorta was cross-clamped and the patient was cooled to 24 °C with an infusion of cold cardioplegia (10 cc/kg of body weight). A primary anastomotic repair was performed between the distal aorta at the insertion of the ductus and the proximal aorta. Toward this end, the ductus was divided and the proximal end oversewn. The conduit was then fashioned by careful resection of all contractile tissue in the ductus, and the distal aorta was mobilized. Following this, the patient was placed on hypothermic circulatory arrest, and an aortotomy was made on the underside of the ascending aorta at the origin of the right carotid artery. An anastomosis was formed with 5-0 Prolene suture. The reconstructed anatomy is depicted in Figure 2. After the anastomosis was completed, the patient was placed back on the pump oxygenator; subsequently, primary repair of the VSD and ASD with patches was achieved. The body temperature was restored to 37 °C and the patient was weaned from cardiopulmonary bypass. The patient's postoperative progress was unremarkable, except for a period during which weaning from the ventilator was delayed. After weaning, the patient was discharged from the hospital.

Key words: Abnormalities, multiple; aorta; heart defects, congenital; heart surgery; infant, newborn; nomenclature, medical

From: The Division of Cardiovascular Surgery, Texas Heart Institute, Houston, Texas

Address for reprints: David A. Ott, MD, MC 4-185, Texas Heart Institute, P.O. Box 20345, Houston, TX 77225-0345

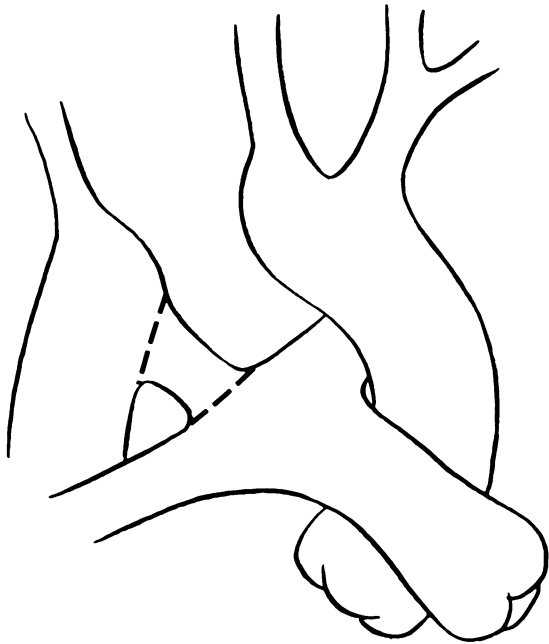


Fig. 1 Schematic drawing of an interrupted right-sided aortic arch in a 6-day-old neonate.

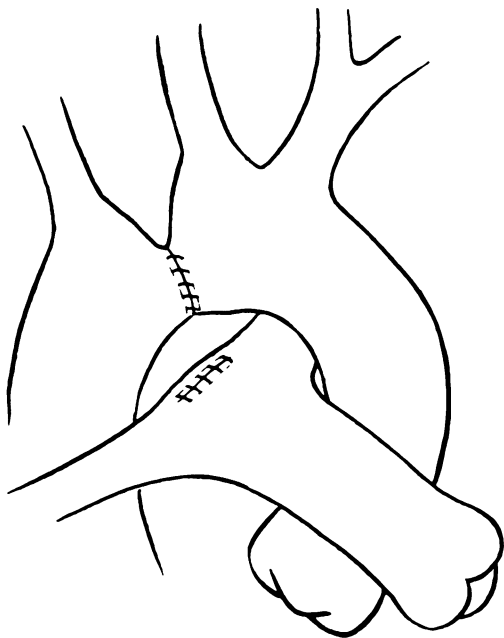


Fig. 2 Reconstructed anatomy after repair of interrupted aortic arch.

Discussion

Right-sided aortic arch was 1st reported by Fiorratti and Aglietta in 1763. In 1778, Steidle described the 1st documented case of interrupted aortic arch. Samson and colleagues,¹⁰ in 1955, reported the 1st successful correction of an interrupted aortic arch.

Celoria and Patton⁹ proposed the currently used classification of interrupted arches into types A, B, and C: type A being interruption between the distal aorta and the subclavian artery; type B, between the subclavian and left common carotid arteries; and type C, between the left common carotid and innominate arteries. Van Praagh¹ reported that type B was the most common anomaly, accounting for 53% of all interrupted arches; type A accounted for 43% and type C, 4%.

The presence of interruption in a right-sided arch necessitates a clarification of nomenclature. Right-sided arches may be classified as 1 of 2 types.¹¹⁻¹³ In the 1st type, right aortic arch with mirror-image branching, the 1st branch of the arch is the left innominate artery (Fig. 3). This anomaly is nearly always associated with cyanotic congenital heart disease.¹³ In the 2nd type, right aortic arch with non-mirror-image branching, the anomaly is often accompanied by anomalous origin of the left subclavian artery from the descending aorta (Fig. 4). The 1st branch of the arch, in this instance, is the left common carotid artery, the 2nd is the right common carotid, and the 3rd is the right subclavian artery. This anomaly is seldom associated with congenital heart disease.¹³

We propose, for mirror-image right-sided interruptions, a classification system (Fig. 3) based on Celoria and Patton's⁹ description of left-sided arches: type A

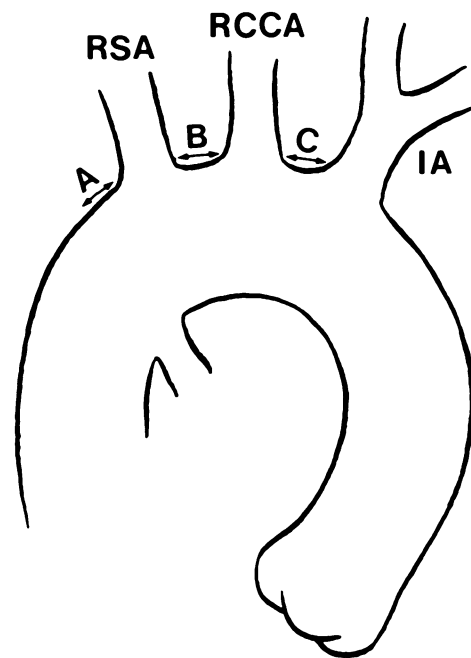


Fig. 3 Proposed nomenclature system for interrupted right-sided aortic arch with mirror-image branching.

IA = innominate artery; RCCA = right common carotid artery; RSA = right subclavian artery

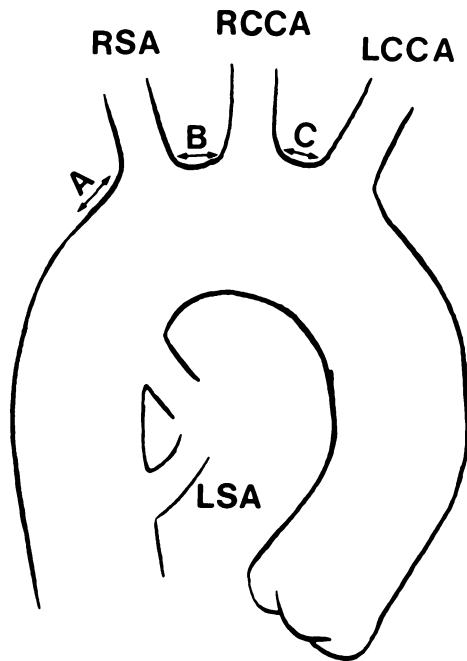


Fig. 4 Proposed nomenclature system for interrupted right-sided aortic arch with non-mirror-image branching.

LCCA = left common carotid artery; LSA = left subclavian artery; RCCA = right common carotid artery; RSA = right subclavian artery

being interruption distal to the right subclavian artery; type B, interruption between the right subclavian and the common carotid arteries; and type C, interruption between the right common carotid and the left innominate arteries. Non-mirror-image right-sided aortic arches present a less distinct situation in terms of their classification. We propose the nomenclature shown in Figure 4: type A being interruption distal to the right subclavian artery; type B, interruption between the right subclavian and the right common carotid arteries; and type C, interruption between the right common carotid and the left common carotid arteries.

The ultimate goal of surgical correction of an interrupted arch is to restore aortic continuity. Toward this end, the current options comprise direct anastomosis of the aortic segments, end-to-side anastomosis of an arch vessel to a proximal or distal segment, division of the ductus with anastomosis to the proximal segment, or placement of an interpositional graft. In our patient, we used direct anastomosis after preparing the distal aorta at the origin of the ductus. Using that approach, it is essential, from a technical standpoint, that all contractile tissue be resected at the origin of the ductus; otherwise, contraction and fibrosis with resultant stenosis at the anastomosis will follow. The alternative of using a prosthetic graft for interrupted arch was first described by Van Praagh in 1971,¹ but that method is

correctly contraindicated because the conduits become restrictive and require replacement as the child grows.^{14,15}

A 2-stage surgical approach could be used for interrupted right-sided aortic arch, consisting initially of a right anterolateral thoracotomy and arch reconstruction, followed later by the repair of intracardiac anomalies.^{16,17} Despite controversy over whether 1-stage or 2-stage repair is better, we prefer the 1-stage approach as long as it is performed by a surgical team experienced in neonatal hypothermic perfusion techniques. This method can be used successfully in the rare instance of interrupted right-sided arch as with the case presented herein.

References

1. Van Praagh R, Bernhard WF, Rosenthal A, Parisi LF, Fyler DC. Interrupted aortic arch: surgical treatment. *Am J Cardiol* 1971;27:200-11.
2. Reardon MJ, Hallman GL, Cooley DA. Interrupted aortic arch: brief review and summary of an eighteen-year experience. *Tex Heart Inst J* 1984;11:250-9.
3. Gokcebay TM, Batillas J, Pinck RL. Complete interruption of the aorta at the arch. *AJR Am J Roentgenol* 1972;114:362-70.
4. Moller JH, Edwards JE. Interruption of the aortic arch: anatomic patterns and associated cardiac malformations. *AJR Am J Roentgenol* 1965;95:557-72.
5. Hastreiter AR, D'Cruz IA, Cantez T. Right-sided aorta. Part I: Occurrence of right aortic arch in various types of congenital heart disease. *Br Heart J* 1966;28:722-5,737-9.
6. Ingram MT, Ott DA. Concomitant repair of aortopulmonary window and interrupted aortic arch. *Ann Thorac Surg* 1992;53:909-11.
7. Glasow PF, Huhta JC, Yoon GY, Murphy DJ Jr, Danford DA, Ott DA. Surgery without angiography for neonates with aortic arch obstruction. *Int J Cardiol* 1988;18:417-25.
8. Collins-Nakai RL, Dick M, Parisi-Buckley L, Fyler DC, Castaneda AR. Interrupted aortic arch in infancy. *J Pediatr* 1976;88:959-62.
9. Celoria GC, Patton RB. Congenital absence of the aortic arch. *Am Heart J* 1959;58:407-13.
10. Merrill D, Webster C, Samson PC. Congenital absence of the aortic isthmus. *J Thorac Cardiovasc Surg* 1957;33:311-6.
11. Knight L, Edwards JE. Right aortic arch: types and associated cardiac anomalies. *Circulation* 1974;50:1047-51.
12. D'Cruz IA, Cantez T, Namin EP, Licata R, Hastreiter AR. Right-sided aorta. Part II: Right aortic arch, right descending aorta, and associated anomalies. *Br Heart J* 1966;28:725-39.
13. Stewart JR, Kincaid OW, Titus JL. Right aortic arch: plain film diagnosis and significance. *Am J Roentgenol Rad Ther Nucl Med* 1966;97:377-89.
14. Sturm JT, vanHeeckeren DW, Borkat G. Surgical treatment of interrupted aortic arch in infancy with expanded polytetrafluoroethylene grafts: two-year follow-up results. *J Thorac Cardiovasc Surg* 1981;81:245-50.
15. Braunlin EA, Lock JE, Foker JE. Repair of type B interruption of the aortic arch: results and follow-up. *J Thorac Cardiovasc Surg* 1983;86:920-5.
16. Griffin S, Richens D, Behl R. Early results of direct repair of aortic interruption by the lateral approach. *Ann Thorac Surg* 1992;53:430-4.
17. Foker JE. Surgical repair of aortic arch interruption [editorial]. *Ann Thorac Surg* 1992;53:369-70.