

Successful Surgical Treatment of Visceral Artery Aneurysms

after Failure of Percutaneous Treatment

Germano Melissano, MD
Roberto Chiesa, MD

We report 2 cases involving aneurysms of visceral arteries that needed surgical treatment after unsuccessful percutaneous treatment. In the 1st case, repeated embolizations with Gianturco coils and angiographic guidewires had failed to obliterate a large aneurysm of the hepatic artery. In the 2nd case, a peripancreatic pseudoaneurysm caused recurrent gastrointestinal bleeding despite embolization with Gianturco coils. In both patients, left medial rotation of the viscera provided access to the origin of the affected artery at the aorta, enabling the surgeon to control bleeding before opening the aneurysm. The advantages and limitations of the most commonly performed percutaneous procedures are discussed, as are the surgical options. (Tex Heart Inst J 1998;25:75-8)

T rue and false aneurysms of visceral arteries are uncommon;^{1,2} however, large vascular surgery services encounter this disease process quite regularly. Since 1990, we have observed at our own service a yearly average of 2 cases (splenic 7, renal 3, celiac and its branches 2, superior mesenteric and its branches 3).

In regard to aneurysms of the celiac and superior mesenteric arteries and their branches, treatment is usually advisable even in asymptomatic cases, due to the very high mortality rate associated with rupture. A percutaneous endovascular approach to the treatment of these lesions, available for the last 2 decades,^{3,4} is particularly appealing for use in poor-risk patients and in the treatment of aneurysms that are difficult to expose (e.g., intrahepatic lesions).

The embolization of steel coils, Gelfoam™ plugs, or other absorbable or non-absorbable materials into visceral artery aneurysms has been reported to be effective in obliterating these lesions,⁵ which suggests that this treatment can provide a definitive cure. Sometimes it is enough to occlude the proximal feeding artery, which spares the weak aneurysmal wall. Embolization of such materials to the aneurysm itself, however, may lead to complete thrombosis while leaving the parent vessel patent.

Percutaneous treatments are not risk free: aneurysmal rupture has been reported even after procedures in which total obliteration was apparently obtained.^{6,7} Other sequelae include inadvertent occlusion of the wrong vessel, migration of the coils to undesired branches, infection, and aneurysmal rupture induced by the high pressure necessary to inject the embolus.⁵

We describe herein 2 cases in which surgery was eventually required to cure visceral artery aneurysms that had undergone percutaneous treatment.

Patient 1

This man was 68 years old when he was referred to us in February 1992 for evaluation of a large, asymptomatic, pulsating epigastric mass. Color-flow ultrasonography, magnetic resonance imaging (MRI), and digital subtraction angiography (DSA) enabled us to diagnose the lesion as a saccular aneurysm of the proximal hepatic artery, with a diameter of 6 cm.

The aneurysm underwent transfemoral embolization with several Gianturco coils. An impressive reduction of blood flow was evident immediately, and a further reduction was noticed a few days later, upon ultrasonography. The patient was discharged after an uneventful course, and follow-up was performed at 6-

Key words: Aneurysm/ complications; aneurysm/ therapy; celiac artery; hepatic artery; embolization, therapeutic; mesenteric arteries; splanchnic circulation

From: Divisione di Chirurgia Vascolare, IRCCS H. San Raffaele, 20132 Milan, Italy

Address for reprints:
Germano Melissano, MD,
Divisione di Chirurgia Vascolare, IRCCS H. San Raffaele, Via Olgettina 66, 20132 Milan, Italy

month intervals: flow was still evident, and by July 1993 the mass had progressed to 8 cm in diameter. The patient was admitted for further DSA evaluation, during which 4 meters of angiographic guidewire were embolized into the residual portion of the aneurysm through a transfemoral approach. Ultrasonography performed 2 days later showed little residual flow in the aneurysm, and the patient was once again discharged after an uneventful course.

The lesion remained stable until September 1996, when progression to 11 cm was demonstrated ultrasonographically. The patient was admitted for further evaluation by means of computed tomographic (CT) scan and DSA: selective injection of the celiac trunk showed opacification of the core of the aneurysm, while selective injection of the superior mesenteric artery showed opacification of the hepatic artery distal to the aneurysm (through the gastroduodenal artery).

Therefore, the patient underwent operative treatment of the lesion through a midline transabdominal incision. Control of the celiac artery at its origin was achieved by means of a left transperitoneal medial visceral rotation,⁸ heparin was administered, and the celiac axis was temporarily clamped. The aneurysm (Fig. 1A) was then incised, and a large, organized thrombus—which included the coils and the guidewires that occupied most of the aneurysm—was removed (Fig. 1B). A small break in the feeding vessel was found and sutured, without any apparent effect upon the distal vasculature. Most of the aneurysmal wall was then excised, and the abdomen was closed in a routine fashion. The postoperative course was uneventful, and the patient was discharged on the 7th postoperative day. He is alive and well 9 months after the operation.

Patient 2

In May of 1995, a 57-year-old man with previous chronic pancreatitis was admitted to a different hospital for upper-quadrant pain and gastrointestinal (GI) bleeding. Abnormal epigastric pulsatility was described, and the patient underwent CT scanning, which revealed a 2-cm aneurysm of the splenic artery and a 5.5-cm pseudoaneurysm of the superior mesenteric artery that originated at a point 4 cm distal to the origin of that vessel. Gastroscopy revealed a non-bleeding duodenal ulcer. The patient underwent DSA, which confirmed the presence of the 2 aneurysms; Gianturco coils were embolized to both lesions.

A few days later, the patient experienced recurrence of severe GI bleeding, and in June 1995, he was transferred to us for further evaluation. He underwent CT scanning, which showed complete thrombosis of the splenic artery aneurysm but only partial thrombosis of the larger pseudoaneurysm, the

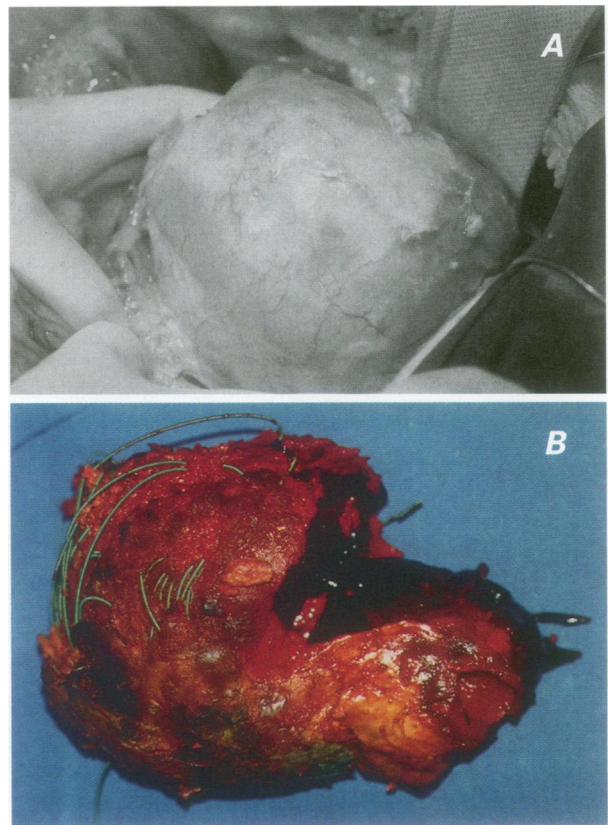


Fig. 1 A (Patient 1) This large hepatic artery aneurysm was exposed through a midline abdominal incision. Previous control of the origin of the artery at the aorta was obtained by rotating the viscera medially, after incising the left lateral peritoneum through the phrenicocolic and lienorenal ligaments. **B** (Patient 1) Impressive but incomplete thrombus formation—induced by percutaneous embolization of Gianturco coils and angiographic guidewires—did not prevent enlargement of the hepatic artery aneurysm.

diameter of which had progressed to 6 cm. The exam did not reveal the source of bleeding.

The patient underwent surgical treatment through a midline transabdominal incision. Control of the superior mesenteric artery at its origin was obtained with left medial visceral rotation.⁸ The pseudoaneurysm was found to arise from the lower portion of the head of the pancreas. Heparin was administered, the superior mesenteric artery was temporarily clamped, the pseudoaneurysm was incised, and the clot containing the coils was removed (Fig. 2). Specimens were sent to the lab for microbiologic assessment that turned out to be negative. The source of the bleeding was identified as a small (2- to 3-mm) break on the side of the superior mesenteric artery, which was sutured with a single 4-0 polypropylene stitch on a Teflon pledget. Blood flow in the superior mesenteric artery was restored after 8 minutes and yielded excellent vascularization of the bowel. The aneurysmal sac was then obliterated, the area

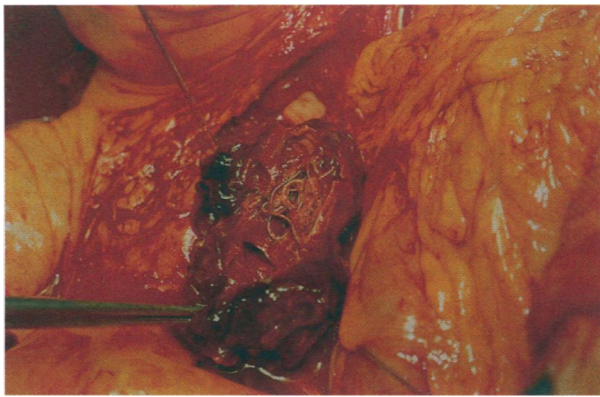


Fig. 2 (Patient 2) After control of the superior mesenteric artery at its aortic origin, the pseudoaneurysm is incised. Once again, thrombosis induced by the Gianturco coils is extensive but not complete: a residual lumen is present in the core of the aneurysm.

was drained, and the abdomen was closed in a routine manner. The postoperative course was uneventful, and the GI bleeding stopped completely.

The patient was discharged on the 6th postoperative day and is alive and well 22 months after the operation.

Discussion

Aneurysmal thrombosis achieved by percutaneous coil embolization has the potential to block the evolution of the aneurysm itself, and has obvious advantages over conventional surgical repair. However, the long-term efficacy of this treatment (in wide use for only the last decade) is yet to be proved—particularly for aneurysms of the visceral arteries, which are relatively rare.

Shanley and coworkers^{1,2} have recently reviewed the English medical literature from 1985 to 1995, for reports of visceral artery aneurysms. In contrast to previous investigators, they found that the hepatic arteries were the most frequently reported location of such aneurysms. This trend has been associated with the increasing use of percutaneous diagnostic and therapeutic procedures in the biliary tract, which may cause iatrogenic false aneurysms. In fact, over 50% of all hepatic artery aneurysms reported in the last decade are false aneurysms of the intrahepatic arterial branches.^{1,2} Moreover, the increased use of CT scanning after blunt liver trauma has improved the detection of post-traumatic false aneurysms. The vast majority of iatrogenic and post-traumatic false aneurysms were managed percutaneously. Overall, 37% of the 103 reported hepatic artery cases were treated percutaneously. As for superior mesenteric artery aneurysms, operative therapy has been the treatment of choice in most of the 52 reported cases;

however, percutaneous therapies have been used occasionally (4%).^{1,2}

Due to the scarcity of these lesions, the overall reported number of splanchnic aneurysms that received interventional treatment is very small.^{1,2} Yet it is apparent that a variety of materials and techniques are available for embolization. The site of the lesion, its size, its cause, the characteristics of the aneurysmal wall, and the quality of the collateral circulation together dictate the approach and the materials to be used. Most investigators prefer non-absorbable materials for embolization, unless severe ischemia of the organ is likely. Either the aneurysm itself or its proximal feeding vessel is embolized. Low-pressure delivery systems are favored, in order to reduce the risk of rupturing the aneurysm during embolization; peripancreatic pseudoaneurysms are particularly vulnerable to rupture, for their walls can be very fragile.

Low-pressure techniques include super-selective catheterization by means of coaxially introduced microcatheters, through which a liquid polymer (such as cyanoacrylate) may be injected.⁵ Because cyanoacrylate polymerizes instantly upon contact with ionic material such as saline or blood, it is rather difficult to handle and the main risk associated with its use is the inadvertent occlusion of normal vessels. Another low-pressure technique involves the use of latex or silicone detachable balloons that are deployed in the aneurysmal cavity. The main risk associated with this technique is that of over-expansion and rupture of the aneurysm (pseudoaneurysms are especially vulnerable). Anaphylactic reactions to the latex have also been described.⁵

The most popular objects to embolize are steel coils, which are readily available in several different shapes and sizes. Once again, either the feeding vessel or the aneurysmal cavity itself may be the target of embolization. In the latter case, a large number of coils might be needed to achieve extensive thrombosis. Unfortunately, extensive thrombosis does not guarantee obliteration of the cavity, as our 2 cases clearly demonstrate. Even a small residual flow within the sac increases tension on the aneurysmal wall and can, in the long run, enlarge and eventually rupture the aneurysm.

Particulate materials, such as Gelfoam (which is reabsorbed in 2 to 3 weeks) have also been used. They are, however, not very popular for use in these locations and should be avoided altogether in the pancreatic region, where proteolytic enzymatic digestion may cause reabsorption in only a few hours.

Occlusion of the wrong vessel is one of the most feared complications, but it can be tolerated in organs with extensive collateral circulation. For example, occlusion of the common hepatic artery is generally compensated for by increased flow through

the gastroduodenal artery and the bile duct arteries, and through an increase in the portal perfusion. On the other hand, occlusion of the proper hepatic artery more commonly causes hepatic necrosis and failure. In the mesenteric arteries, occlusion of terminal branches can have catastrophic consequences; most investigators are hesitant to use percutaneous techniques in these vessels, so interventional treatment of mesenteric artery aneurysms has seldom been reported in the literature.^{1,2}

It should be borne in mind that percutaneous treatment of visceral artery aneurysms, while less invasive than surgery, is not devoid of risks; and the cure it provides may not be definitive. The indications for percutaneous embolization should therefore be weighed carefully. Indeed, we consider percutaneous embolization a questionable 1st choice for the treatment of visceral artery aneurysms. Moreover, the uncertainty of the evolution of visceral artery aneurysms after percutaneous treatment appears to demand close follow-up over an indefinite period of time—with the aid of color-flow ultrasonography and arteriography, whenever progression of the lesion is suspected.

It has been suggested that stents or stented grafts be used to occlude the origin of the visceral artery aneurysm, while maintaining the patency of the feeding artery.⁵ This technique could play an increasingly prominent role in the future, as it did in application to abdominal aortic aneurysms. The lack of long-term results, however, suggests caution, as with any new technique.

Except in very old or very high-risk patients, the diagnosis of hepatic or superior mesenteric aneurysm indicates some form of treatment even in asymptomatic patients, since spontaneous rupture is frequent and the mortality rate associated with rupture approaches 35% for hepatic and 50% for superior mesenteric aneurysm.⁹ In specific regard to surgical treatment, aneurysmectomy is usually performed, with or without reconstruction of the involved vessel. Bleeding, organ ischemia, and infection are the most common and feared sequelae. In our own limited surgical experience with unruptured splanchnic artery aneurysms (15 cases), no operative mortality was recorded. In the literature, operative mortality for non-ruptured hepatic and superior mesenteric artery aneurysms is nowadays probably in the single percentage figures, which compares favorably with the natural history of these lesions. Once the aneurysm is safely removed, long-term prognosis is usually excellent.¹⁰

In conclusion, surgical therapy of visceral artery aneurysms may be carried out not only as a 1st-choice treatment but as a secondary procedure, after percutaneous catheter-based treatment has failed to stop the evolution of the aneurysm. Surgical treat-

ment of aneurysms originating from the celiac axis, the superior mesenteric artery, or their branches may be carried out more safely after control of the artery has been achieved at its point of origin from the aorta. This may be performed by rotating the viscera medially after incising the left lateral peritoneum through the phrenicocolic and lienorenal ligaments, as nicely described by Murray and colleagues.⁸

References

1. Shanley CJ, Shah NL, Messina LM. Common splanchnic artery aneurysms: splenic, hepatic, and celiac. *Ann Vasc Surg* 1996;10:315-22.
2. Shanley CJ, Shah NL, Messina LM. Uncommon splanchnic artery aneurysms: pancreaticoduodenal, gastroduodenal, superior mesenteric, inferior mesenteric, and colic. *Ann Vasc Surg* 1996;10:506-15.
3. Gianturco C, Anderson JH, Wallace S. Mechanical devices for arterial occlusion. *Am J Roentgenol Radium Ther Nucl Med* 1975;124:428-35.
4. Mandel SR, Jaques PF, Sanofsky S, Mauro MA. Nonoperative management of peripancreatic arterial aneurysms. A 10-year experience. *Ann Surg* 1987;205:126-8.
5. Uflacker R. Interventional management of visceral arterial aneurysms. In: Strandness DE Jr, van Breda A, editors. *Vascular diseases: surgical and interventional therapy*. Vol 2. New York: Churchill Livingstone Inc.; 1994. p. 823-44.
6. Lina JR, Jaques P, Mandell V. Aneurysm rupture secondary to transcatheter embolization. *AJR Am J Roentgenol* 1979; 132:553-6.
7. Onohara T, Okadome K, Mii S, Yasumori K, Muto Y, Sugimachi K. Rupture of embolised coeliac artery pseudoaneurysm into the stomach: is coil embolisation an effective treatment for coeliac anastomotic pseudoaneurysm? *Eur J Vasc Surg* 1992;6:330-2.
8. Murray SP, Kuestner LM, Stoney RJ. Transperitoneal medial visceral rotation. *Ann Vasc Surg* 1995;9:209-16.
9. Stanley JC, Zelenock GB. *Splanchnic artery aneurysms*. In: Rutherford RB, editor. 4th ed. *Vascular surgery*. Philadelphia: W.B. Saunders Company; 1995. p. 1124-39.
10. Clyne CAC. Operations for splanchnic artery aneurysms. In: Bell PRF, Jamieson CW, Ruckley CV, editors. *Surgical management of vascular disease*. London: W.B. Saunders Company; 1992. p. 883-8.