

# Two-Dimensional and Doppler Echocardiography

for the Assessment of Congestive Heart Failure

Susan Wilansky, MD, FACC

**C**ongestive heart failure is a major cause of morbidity and mortality in the United States. An estimated 2 million patients are treated annually and more than 400,000 new cases are diagnosed each year.<sup>1</sup> Fundamental to this diagnosis is accurate assessment of systolic and diastolic function.

## Assessment of Systolic Function

A reliable and widely used method for the assessment of systolic function is 2-dimensional echocardiography. The parameter most often used to express global left ventricular (LV) systolic function is ejection fraction, which is a powerful predictor of outcome in almost all cardiac conditions. Several methodologies for the calculation of ejection fraction have been validated. These include the modified Simpson's method<sup>2</sup> using LV volumes, the simplified method of Quinones,<sup>3</sup> and the M-mode calculation of fractional shortening.<sup>4</sup> Visual methods of estimating ejection fraction have also been noted to be reliable by several authors.<sup>5</sup>

Other indices of systolic function have been validated by echocardiography, including dp/dt (ratio of change in ventricular pressure to change in time),<sup>6,7</sup> cardiac output (which correlates well with Fick cardiac output),<sup>8</sup> and systolic time intervals derived from Doppler echocardiography.<sup>9</sup>

## Assessment of Diastolic Function

Doppler echocardiographic evaluation of diastolic function has become an important tool in the initial assessment of the patient with congestive heart failure, as well as an indicator of prognosis.

*Normal Physiology.* Mitral inflow represents the pressure differences between the left atrium and left ventricle throughout diastole (Fig. 1). The mitral valve opens when left atrial (LA) pressure exceeds LV pressure. The time from aortic valve closure to mitral valve opening is known as the isovolumic relaxation time (IVRT). The peak E wave of mitral inflow reflects the LA/LV pressure difference at the onset of diastole. The auscultatory equivalent is  $S_3$ .<sup>10</sup> The deceleration time is the time required for equilibration of LA/LV pressure (or the time to diastasis). The peak A wave reflects the LA/LV pressure difference at the onset of atrial systole ( $S_4$ ).<sup>10</sup> With normal aging, the IVRT is progressively prolonged and the peak A wave velocity increases.<sup>11</sup>

As with mitral inflow, pulmonary and hepatic venous flows are also a reflection of atrial/ventricular pressure differences. During atrial diastole, there is venous inflow to the atria, which is inscribed as the dominant wave (*x* descent of the jugular venous pressure). During ventricular diastole, there is a lower-velocity inflow (*y* descent). A small reversal of flow occurs during atrial systole (Fig. 2).

*Abnormal Filling Patterns in Congestive Heart Failure.* As the LA pressure rises, the time to mitral valve opening shortens. This is reflected by a shortened IVRT, which is perhaps the most specific Doppler marker of high filling pressures in the presence of sinus rhythm. When filling pressures are high, the time to LA/LV equilibration shortens. Both of these shortened times are reflected in the mitral inflow as a high peak E wave, an increased E/A ratio, and a shortened deceleration time—the so-called “restrictive filling” pattern. Mitral inflow can be influenced by several variables, including the position of the patient,<sup>12</sup> loading conditions (i.e., preload and afterload),<sup>13</sup> heart rate, and PR interval. It should also be noted that in the presence of significant tachycardia, the E and A waves may

### Section editors:

Edward K. Massin, MD  
O.H. Frazier, MD  
John R. Cooper, MD  
Sayed F. Feghali, MD

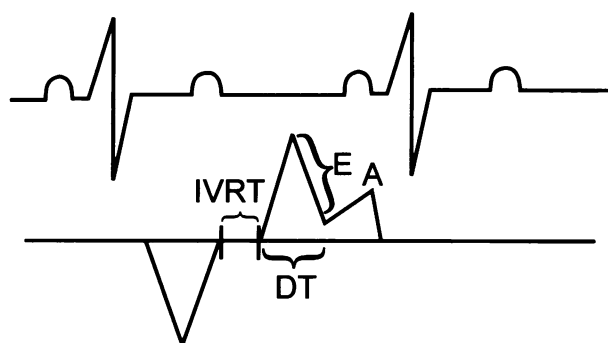
### Key words:

Diastole; dobutamine/diagnostic use; echocardiography/methods; heart failure, congestive/diagnosis; heart failure, congestive/ultrasonography; heart ventricle/ultrasonography; myocardial contraction; myocardial ischemia; predictive value of tests; pulmonary wedge pressure; systole; ventricular function, left/ultrasonography

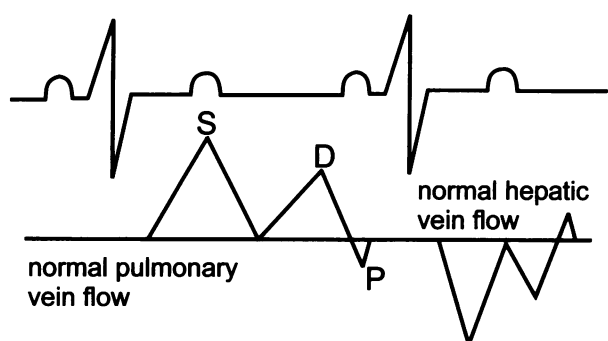
**From:** The Department of Cardiology, Texas Heart Institute and St. Luke's Episcopal Hospital, Houston, Texas 77030

### Address for reprints:

Susan Wilansky, MD,  
Department of Cardiology,  
Texas Heart Institute at St.  
Luke's Episcopal Hospital,  
Suite 2480,  
6624 Fannin Street,  
Houston, TX 77030



**Fig. 1** Doppler echocardiography of the mitral inflow pattern. A = A wave; DT = deceleration time; E = E wave; IVRT = isovolumic relaxation time



**Fig. 2** Doppler echocardiography demonstrating normal pulmonary (left side) and hepatic venous (right side) profile. D = diastole; P = P wave reversal; S = systole

be fused and the IVRT falsely shortened. Similarly, when LA pressure is high, there is a large LA “V” wave. This blunts systolic inflow from the pulmonary veins and thus results in the pattern of diastolic dominance (Fig. 2). This pattern, however, has also been demonstrated in young people with healthy, normal hearts.

Serial echocardiography before and after treatment has shown that mitral inflow is dynamic and a continuous reflection of LA/LV pressure differences;<sup>10,11</sup> therefore, it may “pseudo-normalize” when the patient has shown maximal response to medical therapy.

**Use of Doppler Echocardiography to Predict Left Ventricular Filling Pressures.** It has been well established that certain parameters of the mitral inflow correlate well with LA pressure.<sup>14</sup> In an elegant study that applied Doppler echocardiography and cardiac catheterization simultaneously, Nishimura and associates<sup>15</sup> demonstrated an inverse relationship between the deceleration time of the mitral inflow and LA pressure in patients with LV systolic dysfunction. In fact, the sensitivity and specificity of the deceleration time—less than 180 msec, which indicated

LA pressures of 20 mmHg or higher—were both 100%. More complex regression equations for prediction of the pulmonary capillary wedge pressure have been derived using parameters of mitral and pulmonary venous inflow.<sup>16</sup>

Another simple method for the determination of pulmonary capillary wedge pressure was 1st described by Nishimura and Tajik<sup>17</sup> and further validated by Gorcsan and colleagues<sup>18</sup>. This method makes use of the continuous Doppler wave signal of the mitral regurgitant jet, which is a reflection of the LA/LV pressure difference in systole. Subtracting the systolic blood pressure from this pressure difference yields the pulmonary capillary wedge pressure with an *r* value of 0.88.

Finally, Doppler echocardiography of the pulmonary veins provides insight into elevated LV filling pressures. This pattern is characterized by blunted or absent systolic forward flow,<sup>14,19</sup> which reflects the inability of blood to enter the left atrium in the presence of a large LA “V” wave. Diastolic dominance is also normal in the young and healthy heart. Caution must be used in the interpretation of pulmonary venous flow in the presence of atrial fibrillation, significant mitral regurgitation, ventricular pacing, and severe LV dysfunction.<sup>20</sup>

Therefore, the assessment of diastolic function should integrate the information derived from the mitral inflow, the IVRT, and the pulmonary venous flow profile.

With regard to the prognostic capabilities of Doppler echocardiography, several studies have indicated that Doppler-derived mitral deceleration time is a very powerful and independent predictor of mortality in patients with dilated cardiomyopathy.<sup>21,22</sup> In another study, Xie and coworkers<sup>23</sup> used Doppler-echocardiography-derived “restrictive” mitral inflow patterns in patients with congestive heart failure to predict a 4-fold increase in their mortality rate at 1 year.

### Use of Dobutamine Echocardiography to Assess Myocardial Viability

The concepts of stunned and hibernating myocardium have expanded our understanding of the effects of ischemia on LV dysfunction. It has been suggested that LV dysfunction may be reversible in up to 40% of patients with coronary artery disease (CAD).<sup>24</sup> Stunned myocardium has been defined as myocardium that has sustained an acute injury but has adequate perfusion at rest. Hibernating myocardium, by contrast, involves chronic, severe ischemia that has caused severe systolic dysfunction; however, since the contractile mechanism of hibernating myocardium has been downregulated rather than damaged, revascularization may restore systolic function.<sup>24,25</sup> Positron emission tomography (PET)

has been the gold standard for noninvasive assessment of myocardial viability in these cases.

Dobutamine echocardiography (DE) has accurately identified myocardial viability at low dobutamine doses (5, 7.5, and 10  $\mu\text{g}/\text{kg}/\text{min}$ ). Viability has been defined as an improvement in regional wall motion to the extent that an akinetic segment becomes hypokinetic or a hypokinetic segment becomes normal.

In one of the earliest reports on this topic, Pierard and associates<sup>26</sup> compared low-dose DE with PET for the noninvasive assessment of viable myocardium in 17 patients with acute myocardial infarction who had received thrombolytic therapy. There was a 79% concordance between the 2 techniques. A summary of currently available PET, thallium single-photon emission computed tomography (SPECT), and DE studies reviewed by Bonow<sup>24</sup> revealed positive predictive accuracies of 82% for PET, 69% for thallium SPECT, and 83% for DE. Smart and colleagues<sup>27</sup> performed DE on 63 patients after lytic therapy for myocardial infarction, with follow-up echocardiography at 1 month. In the hands of these very experienced investigators, the specificity of low-dose DE in predicting reversible ischemia was 90% and the sensitivity was 86%.

Several more recent reports compared thallium scintigraphy with DE for the assessment of myocardial viability. Table I summarizes the findings of these studies.<sup>28-31</sup>

In the study by Nagueh and coworkers,<sup>28</sup> the specificity of DE was enhanced by the demonstration of a biphasic response (improved wall motion at a low dose of dobutamine and deterioration at a peak dose), but DE sensitivity was increased by any improvement in wall motion. Furthermore, sensitivity for the prediction of functional recovery was higher in hypokinetic (100%) than in akinetic (70%) segments, although specificity was higher in akinetic (82%) than in hypokinetic (46%) segments. These authors demonstrated that myocardial contrast echocardiography (MCE) may be another good noninvasive method for the identification of hibernating myocardium. Myocardial contrast echocardiography had an 80% concordance with thallium-201 tomography and a negative predictive accuracy of 86% to 88%, but a poorer positive predictive accuracy (51% to 57%), depending upon the criteria used.

Finally, in a prospective study of 84 patients with chronic CAD and LV dysfunction who were undergoing aorto-coronary bypass, Scognamiglio and colleagues<sup>32</sup> demonstrated a 91.5% sensitivity, an 84% specificity, and an 88.1% accuracy for DE in predicting reversible wall motion abnormalities after aorto-coronary bypass.

Dobutamine echocardiography has also been found to be accurate in detecting CAD in patients

**Table I.** Selected Studies Comparing Thallium Scintigraphy with Doppler Echocardiography for the Assessment of Myocardial Viability

Study	Method	% Sensitivity	% Specificity
Nagueh <sup>28</sup>	DE	91	61
	Thallium	91	43
Vanovershelde <sup>29</sup>	SPECT	72	73
	DE	88	77
Marzullo <sup>30</sup>	Early thallium scintigraphy (10 minutes)	79	73
	Late thallium scintigraphy	86	92
	Sestamibi	75	84
	DE	82	92

\*Perrone-Filardi<sup>31</sup>

\*In this study, concordance between thallium-201 tomography and dobutamine echocardiography was 82% in hypokinetic segments and 43% in akinetic segments.

DE = dobutamine echocardiography; SPECT = single-photon emission computed tomography

with dilated cardiomyopathy. Sharp and associates<sup>33</sup> demonstrated DE to have an 83% sensitivity and a 71% specificity for diagnosing CAD in patients with LV dysfunction (defined as fractional shortening of less than 0.18). The sensitivity of DE increased as the number of diseased vessels increased (69% for single-vessel disease, 83% for double-vessel, and 100% for triple-vessel).

## Conclusion

In conclusion, 2-dimensional and Doppler echocardiography are invaluable tools for the assessment and prognostication of systolic and diastolic heart failure. The development of new contrast agents may help to further delineate the role of ischemia during pharmacologic echocardiography. Further studies are needed to assess predictors of outcome for the newer methods of treating congestive heart failure, such as LV reduction surgery.

## Acknowledgments

The author wishes to express her gratitude to Linda Clifton for secretarial support and to Jonah Markowitz for research assistance.

## References

1. Braunwald E, editor. Heart disease: a textbook of cardiovascular medicine, 5th edition. Philadelphia: WB Saunders, 1997.
2. Schiller NB, Shah PM, Crawford M, DeMaria A, Devereux R, Feigenbaum H, et al. Recommendations for quantitation of the left ventricle by two-dimensional echocardiography. American Society of Echocardiography Committee on Standards, Subcommittee on Quantitation of Two-Dimensional Echocardiograms. *J Am Soc Echocardiogr* 1989;2:358-67.
3. Quinones MA, Waggoner AD, Reduto LA, Nelson JG, Young JB, Winters WL Jr, et al. A new, simplified and accurate method for determining ejection fraction with two-dimensional echocardiography. *Circulation* 1981;64:744-53.
4. Feigenbaum H. Echocardiography, 5th edition. Philadelphia: Lea & Febiger, 1994;661.
5. Feigenbaum H. p. 173.
6. Ge Z, Zhang Y, Kang W, Fan D, Duran C. A simultaneous study of Doppler-echo and catheterization in noninvasive assessment of the left ventricular dp/dt. *Clin Cardiol* 1993; 16:422-8.
7. Chen C, Rodriguez L, Lethor JP, Levine RA, Semigran MS, Fifer MA, et al. Continuous wave Doppler echocardiography for noninvasive assessment of left ventricular dp/dt and relaxation time constant from mitral regurgitant spectra in patients. *J Am Coll Cardiol* 1994;23:970-6.
8. Gola A, Pozzoli M, Capomolla S, Traversi E, Sanarico M, Cobelli F, et al. Comparison of Doppler echocardiography with thermodilution for assessing cardiac output in advanced congestive heart failure. *Am J Cardiol* 1996;78:708-12.
9. Burwash IG, Otto CM, Pearlman AS. Use of Doppler-derived left ventricular time intervals for noninvasive assessment of systolic function. *Am J Cardiol* 1993;72:1331-3.
10. Cohen GI, Pietrolungo JF, Thomas JD, Klein AL. A practical guide to assessment of ventricular diastolic function using Doppler echocardiography. *J Am Coll Cardiol* 1996;27:1753-60.
11. Nishimura RA, Tajik AJ. Evaluation of diastolic filling of left ventricle in health and disease: Doppler echocardiography is the clinician's Rosetta Stone. *J Am Coll Cardiol* 1997;30:8-18.
12. Tanabe K, Ishibashi Y, Ohta T, Oyake N, Shimada T, Murakami R, et al. Effect of left and right lateral decubitus positions on mitral flow pattern by Doppler echocardiography in congestive heart failure. *Am J Cardiol* 1993;71:751-3.
13. DeMaria AN, Wisenbaugh TW, Smith MD, Harrison MR, Berk MR. Doppler echocardiographic evaluation of diastolic dysfunction. *Circulation* 1991;84(3 Suppl):I288-95.
14. Appleton CP, Hatle LK, Popp RL. Demonstration of restrictive ventricular physiology by Doppler echocardiography. *J Am Coll Cardiol* 1988;11:757-68.
15. Nishimura RA, Appleton CP, Redfield MM, Ilstrup DM, Holmes DR Jr, Tajik AJ. Noninvasive Doppler echocardiographic evaluation of left ventricular filling pressures in patients with cardiomyopathies: a simultaneous Doppler echocardiographic and cardiac catheterization study. *J Am Coll Cardiol* 1996;28:1226-33.
16. Pozzoli M, Capomolla S, Pinna G, Cobelli F, Tavazzi L. Doppler echocardiography reliably predicts pulmonary artery wedge pressure in patients with chronic heart failure with and without mitral regurgitation. *J Am Coll Cardiol* 1996; 27:883-93.
17. Nishimura RA, Tajik AJ. Determination of left-sided pressure gradients by utilizing Doppler aortic and mitral regurgitant signals: validation by simultaneous dual catheter and Doppler studies. *J Am Coll Cardiol* 1988;11:317-21.
18. Gorcsan J 3rd, Snow FR, Paulsen W, Nixon JV. Noninvasive estimation of left atrial pressure in patients with congestive heart failure and mitral regurgitation by Doppler echocardiography. *Am Heart J* 1991;121(3 Pt 1):858-63.
19. Yamamoto K, Masuyama T, Tanouchi J, Uematsu M, Doi Y, Naito J, et al. Decreased and abnormal left ventricular filling in acute heart failure: role of pericardial constraint and its mechanism. *J Am Soc Echocardiogr* 1992;5:504-14.
20. Bartzokis T, Lee R, Yeoh TK, Grogin H, Schnittger I. Transesophageal echo-Doppler echocardiographic assessment of pulmonary venous flow patterns. *J Am Soc Echocardiogr* 1991;4:457-64.
21. Giannuzzi P, Temporelli PL, Bosimini E, Silva P, Imbarato A, Corra U, et al. Independent and incremental prognostic value of Doppler-derived mitral deceleration time of early filling in both symptomatic and asymptomatic patients with left ventricular dysfunction. *J Am Coll Cardiol* 1996;28:383-90.
22. Pinamonti B, Di Lenarda A, Sinagra G, Camerini F. Restrictive left ventricular filling pattern in dilated cardiomyopathy assessed by Doppler echocardiography: clinical, echocardiographic and hemodynamic correlations and prognostic implications. Heart Muscle Disease Study Group. *J Am Coll Cardiol* 1993;22:808-15.
23. Xie GY, Berk MR, Smith MD, Gurley JC, DeMaria AN. Prognostic value of Doppler transmitral flow patterns in patients with congestive heart failure. *J Am Coll Cardiol* 1994;24:132-9.
24. Bonow RO. Identification of viable myocardium [editorial]. *Circulation* 1996;94:2674-80.
25. Thomas JD, Topol EJ. Wanted: dead or alive. Assessment of myocardial viability after thrombolysis [editorial]. *Circulation* 1993;88:797-9.
26. Pierard LA, De Landsheere CM, Berthe C, Rigo P, Kulbertus HE. Identification of viable myocardium by echocardiography during dobutamine infusion in patients with myocardial infarction after thrombolytic therapy: comparison with positron emission tomography. *J Am Coll Cardiol* 1990;15: 1021-31.
27. Smart SC, Sawada S, Ryan T, Segar D, Atherton L, Berkovitz K, et al. Low-dose dobutamine echocardiography detects reversible dysfunction after thrombolytic therapy of acute myocardial infarction. *Circulation* 1993;88:405-15.
28. Nagueh SF, Vaduganathan P, Ali N, Blaustein A, Verani MS, Winters WL Jr, et al. Identification of hibernating myocardium: comparative accuracy of myocardial contrast echocardiography, rest-redistribution thallium-201 tomography and dobutamine echocardiography. *J Am Coll Cardiol* 1997;29: 985-93.
29. Vanoverschelde JL, D'Hondt AM, Marwick T, Gerber BL, De Kock M, Dion R, et al. Head-to-head comparison of exercise-redistribution-reinjection thallium single-photon emission computed tomography and low dose dobutamine echocardiography for prediction of reversibility of chronic left ventricular ischemic dysfunction. *J Am Coll Cardiol* 1996;28:432-42.
30. Marzullo P, Parodi O, Reisenhofer B, Sambucetti G, Picano E, Distante A, et al. Value of rest thallium-201/technetium-99m sestamibi scans and dobutamine echocardiography for detecting myocardial viability. *Am J Cardiol* 1993;71:166-72.
31. Perrone-Filardi P, Pace L, Prastaro M, Squame F, Betocchi S, Soricelli A, et al. Assessment of myocardial viability in patients with chronic coronary artery disease. Rest-4-hour-24-hour <sup>201</sup>Tl tomography versus dobutamine echocardiography. *Circulation* 1996;94:2712-9.
32. Scognamiglio R, Fasoli G, Casarotto D, Miorelli M, Nistri S, Palisi M, et al. Postextrasystolic potentiation and dobutamine echocardiography in predicting recovery of myocardial

- function after coronary bypass revascularization. *Circulation* 1997;96:816-20.
33. Sharp SM, Sawada SG, Segar DS, Ryan T, Kovacs R, Fineberg NS, Feigenbaum H. Dobutamine stress echocardiography: detection of coronary artery disease in patients with dilated cardiomyopathy. *J Am Coll Cardiol* 1994;24:934-9.