

A Lipoma of the Transverse Colon Causing Intermittent Obstruction: A Rare Cause for Surgical Intervention

Daniel J. Gould, BS^{1,2}
C. Anne Morrison, MD, MPH³
Kathleen R. Liscum, MD^{3,4}
Eric J. Silberfein, MD^{3,4}

¹Medical Scientist Training Program, Baylor College of Medicine, Houston, Texas; ²Department of Bioengineering, Rice University, Houston, Texas; ³Michael E. DeBakey Department of Surgery, Baylor College of Medicine, Houston, Texas; ⁴Ben Taub General Hospital, Harris County Hospital District, Houston, Texas

Lipomas of the digestive tract are rare and most often found incidentally during a colonoscopy, computed tomography (CT) scan, surgery, or autopsy.¹⁻³ Lipomas of the colon were first reported by Bauer in 1757 and are most often located in the ascending colon near the cecum.⁴ These fatty tumors are rarely greater than 2 cm in size and are rarely symptomatic. The most common presentations of symptomatic patients with lipomas greater than 2 cm in size include abdominal pain, hemorrhage, diarrhea, or constipation.⁴ Lipomas that grow more than 4 cm in size can lead to obstruction and intussusception requiring surgical or endoscopic resection.³⁻⁶ These benign tumors are often difficult to diagnose because of their asymptomatic nature or the intermittent nature of patients' symptoms. On plain radiograph, these lesions may produce a radiolucent area above the region of affected bowel. Barium studies are nondiagnostic unless changes in the lipoma's shape and size are seen via a diagnostic test (the squeeze sign).⁴ More commonly, definitive diagnosis is made after the lipoma is removed and subjected to histopathologic staining.⁷ Surgical resection is recommended to alleviate symptoms and to rule out malignancy.⁷ In this case report, we describe an intussuscepted, transverse colonic lipoma that caused intermittent bowel obstruction.

Case Report

A 58-year-old, otherwise healthy woman presented to an ambulatory clinic complaining of left-sided abdomi-

nal pain, intermittent bloating, nausea, and bright red blood per rectum. The patient underwent a colonoscopy, which revealed a large ulcerated mass in the transverse colon that encompassed more than 50% of the bowel lumen. An endoscopic biopsy showed reactive changes without evidence of dysplasia or malignancy. A CT scan revealed a concentric mass in the distal transverse colon with evidence of colonic intussusception (Figure 1). The patient's hemoglobin level measured 11.4 g/dL, and her carcinoembryonic antigen level was normal. Because of the size of the mass and the inability to rule out a malignant intussusception, the patient was taken to the operating room, where a large mass was palpated in the mid-transverse colon. She underwent a successful transverse colectomy primary anastomosis. Gross examination of the specimen revealed a large pedunculated mass, and histologic examination showed mature adipocytes in the submucosa, with mucosal ulceration consistent with a benign lipoma (Figure 2). The patient had an uneventful postoperative course and was discharged home on the fifth postoperative day.

Discussion

Lipomas represent the most common nonepithelial-derived tumor of the gastrointestinal tract.⁷ These tumors are more prevalent in women than in men and have a peak incidence in patients between 50 and 60 years of age.^{5,8} Several studies have shown that the most common site of colonic lipomas is the ascending colon (45%), although tumors may occur in the sigmoid colon (30.3%), descending colon (15.2%), and transverse colon (9.1%).^{2,4,9-12} Thus, the least common location of a colonic lipoma is the transverse colon, which was the site of the tumor in this case report.^{3,12,13} Our finding is only the

Address correspondence to:

Dr. Eric J. Silberfein, Michael E. DeBakey Department of Surgery, Baylor College of Medicine, One Baylor Plaza, MS:390, Houston, TX 77030; Tel: 713-873-5324; Fax: 713-795-5622; E-mail: ejs@bcm.edu

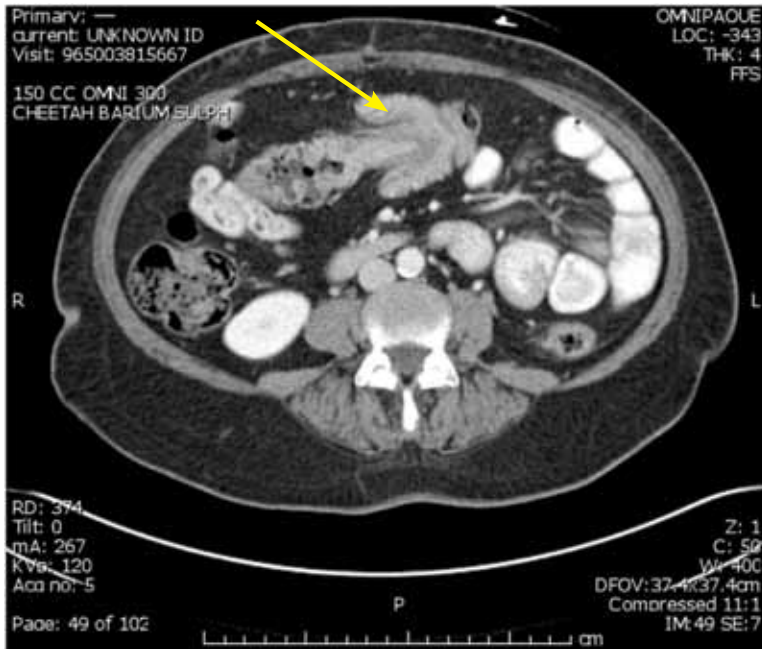


Figure 1. A computed tomography scan of the abdomen showing colonic intussusception (yellow arrow).

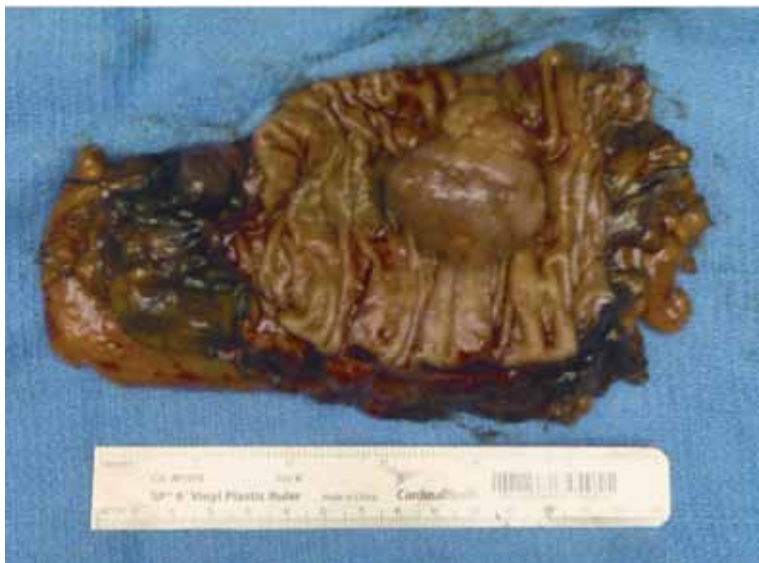

Figure 2. Gross surgical pathology at the time of resection revealed a large pedunculated mass.

seventh report of a transverse colonic lipoma published in the literature (Table 1).

The diagnosis of a colonic lipoma can be established radiographically, endoscopically, or surgically. The pathognomonic sign of a colonic lipoma is the squeeze sign, in which a radiolucent, spherical filling defect with well-defined margins can be shown to change size and shape in response to peristalsis during administration of a barium enema.¹² Ninety percent of colonic lipomas are

localized to the submucosa; colonic lipomas are rarely found in other layers of the bowel wall.^{12,13} Due to this location, 3 endoscopic signs can aid in the diagnosis of a lipoma: the “cushion” sign, which occurs when forceps press into the mass, resulting in a depression or pillowing; the “tenting” sign, which occurs when mucosa is grabbed over the lesion and pulled away, resulting in a tent-like appearance; and the “naked fat” sign, which occurs when fat is grossly extruded after biopsy.¹⁴ Furthermore, the

Table 1. Cases of Transverse Colonic Lipomas Published in the Literature

Reference	Year	Age (years)	Gender	Symptoms	Size (cm)	Treatment
Liessi G, et al ²	1996	50	Male	Abdominal pain, nausea, and cramping	5	Right hemicolectomy
Stone C, Weber HC ⁹	2001	60	Male	Constipation	5	Endoscopic removal
Rogers SO Jr, et al ¹⁰	2002	45	Female	Abdominal pain and diarrhea	5	Surgical resection
Atila K, et al ¹¹	2007	56	Female	Acute abdominal pain, nausea, and vomiting	5	Right hemicolectomy
Mnif L, et al ¹²	2009	67	Female	Abdominal pain	5	Surgical resection
Mason R, et al ⁴	2010	51	Female	Intermittent colicky abdominal pain	4.5	Right hemicolectomy

submucosal location of these tumors has led to several techniques for endoscopic removal, including endoloop excision, nylon loop–assisted removal, endoclipping, and sectioning of the overlying mucosa via segmental cuts.^{9,15-17} One of the most common and feared complications of endoscopic removal is colonic perforation, although its true incidence is likely underestimated due to the rarity of lipomas.

The clinical diagnosis of a lipoma can be very difficult. In fact, several cases of lipomas with overlying villous adenomas or other presentations mimicking carcinomas have been reported in the literature.¹⁸⁻²⁰ In most cases, segmental surgical resection is the most appropriate treatment, as it ensures proper collection of lymph nodes for appropriate staging of presumed colonic carcinoma. According to Jiang and colleagues, surgical intervention is warranted when the lipoma is more than 4 cm in size; there is an unclear preoperative diagnosis; the lipoma has associated morbidity (intussusception) and the patient is symptomatic; there is involvement of the muscular or serosal layer; or the lesion cannot be radically resected endoscopically.³

Recently, Tamura and colleagues reported a case of a giant colonic lipoma, and they proposed that accessible pedunculation and normal complete blood counts, blood chemistry, and carcinoembryonic antigen levels warrant endoscopic rather than surgical resection.²¹ Tamura and coworkers used indigo carmine to demonstrate normal colonic pitting and to detect the submucosal location of the tumor.²¹ They also used endoscopic ultrasonography to demonstrate the presence of a hyperechoic mass, which was consistent with a lipoma. Examination of the tumor's base is the key for providing sufficient indication for endoscopic resection. Histologically, hematoxylin and eosin staining will generally show adipose tissue located in the submucosa with numerous fibra intervals.¹²

Based on the diagnostic criteria proposed by Jiang and associates and oncologic principles, we chose to perform surgical resection of the transverse colon.³ This decision allowed for complete staging if the tumor was found to be malignant.

In summary, large symptomatic colonic lipomas should be excised either surgically or endoscopically. Small lipomas (<4 cm) with pedunculated bases in patients with normal blood counts and tumor markers may be amenable to endoscopic resection. Lesions that are greater than 4 cm in size and/or lesions found in patients in whom malignancy cannot be reasonably ruled out should undergo segmental resection.

References

- Pfeil SA, Weaver MG, Abdul-Karim FW, Yang P. Colonic lipomas: outcome of endoscopic removal. *Gastrointest Endosc.* 1990;36:435-438.
- Liessi G, Pavanello M, Cesari S, Dell'Antonio C, Avventi P. Large lipomas of the colon: CT and MR findings in three symptomatic cases. *Abdom Imaging.* 1996;21:150-152.
- Jiang L, Jiang LS, Li FY, et al. Giant submucosal lipoma located in the descending colon: a case report and review of the literature. *World J Gastroenterol.* 2007;13:5664-5667.
- Mason R, Bristol JB, Petersen V, Lyburn ID. Education and imaging. Gastrointestinal: lipoma induced intussusception of the transverse colon. *J Gastroenterol Hepatol.* 2010;25:1177.
- Ryan J, Martin JE, Pollock DJ. Fatty tumours of the large intestine: a clinicopathological review of 13 cases. *Br J Surg.* 1989;76:793-796.
- Sarker SK. Lipoma of the descending colon causing acute large-bowel intussusception. *Internet J Surgery.* 2010;22. http://www.ispub.com/journal/the_internet_journal_of_surgery/volume_22_number_1_1/article/lipoma-of-the-descending-colon-causing-acute-large-bowel-intussusception.html. Modified January 9, 2010.
- Bardají M, Roset F, Camps R, Sant F, Fernández-Layos MJ. Symptomatic colonic lipoma: differential diagnosis of large bowel tumors. *Int J Colorectal Dis.* 1998;13:1-2.
- Michowitz M, Lazebnik N, Noy S, Lazebnik R. Lipoma of the colon. A report of 22 cases. *Am Surg.* 1985;51:449-454.
- Stone C, Weber HC. Endoscopic removal of colonic lipomas. *Am J Gastroenterol.* 2001;96:1295-1297.
- Rogers SO Jr, Lee MC, Ashley SW. Giant colonic lipoma as lead point for intermittent colo-colonic intussusception. *Surgery.* 2002;131:687-688.

11. Atila K, Terzi C, Obuz F, Yilmaz T, Füzün M. Symptomatic intestinal lipomas requiring surgical interventions secondary to ileal intussusception and colonic obstruction: report of two cases. *Ulus Travma Acil Cerrahi Derg.* 2007;13:227-231.
12. Mnif L, Amouri A, Masmoudi MA, et al. Giant lipoma of the transverse colon: a case report and review of the literature. *Tunis Med.* 2009;87:398-402.
13. Ghidirim G, Mishin I, Gutsu E, Gagauz I, Danch A, Russu S. Giant submucosal lipoma of the cecum: report of a case and review of literature. *Rom J Gastroenterol.* 2005;14:393-396.
14. De Beer RA, Shinya H. Colonic lipomas. An endoscopic analysis. *Gastrointest Endosc.* 1975;22:90-91.
15. Raju GS, Gomez G. Endoloop ligation of a large colonic lipoma: a novel technique. *Gastrointest Endosc.* 2005;62:988-990.
16. Murray MA, Kwan V, Williams SJ, Bourke MJ. Detachable nylon loop assisted removal of large clinically significant colonic lipomas. *Gastrointest Endosc.* 2005;61:756-759.
17. Katsinelos P, Chatzimavroudis G, Zavos C, Paroutoglou G, Papaziogas B, Kountouras J. A novel technique for the treatment of a symptomatic giant colonic lipoma. *J Laparoendosc Adv Surg Tech A.* 2007;17:467-469.
18. Huh KC, Lee TH, Kim SM, et al. Intussuscepted sigmoid colonic lipoma mimicking carcinoma. *Dig Dis Sci.* 2006;51:791-795.
19. Capra F, Zorcolo L, Scintu F, Mascia R, Casula G. Giant sigmoid lipoma covered by a villous adenoma. *Int J Colorectal Dis.* 2007;22:563-564.
20. Martin P, Sklow B, Adler DG. Large colonic lipoma mimicking colon cancer and causing colonic intussusception. *Dig Dis Sci.* 2008;53:2826-2827.
21. Tamura S, Yokoyama Y, Morita T, Tadokoro T, Higashidani Y, Onishi S. "Giant" colon lipoma: what kind of findings are necessary for the indication of endoscopic resection? *Am J Gastroenterol.* 2001;96:1944-1946.

Review

Large Colonic Lipomas

Geetha Nallamotheu, MD¹

Douglas G. Adler, MD^{1,2}

¹Division of Gastroenterology, Hepatology, and Nutrition

²Huntsman Cancer Center

University of Utah School of Medicine

Salt Lake City, Utah

Lipomas are common, nonepithelial, benign, fatty tumors that can be found throughout the gastrointestinal tract, although they are most frequently seen in the colon. Approximately 90% of colonic lipomas are located in the submucosa; the remainder of these tumors are subserosal or intramucosal in origin. The reported incidence of colonic lipomas ranges from 0.2% to 4.4%.¹ Lipomas of the large intestine are most commonly seen (in order of decreasing frequency) in the cecum, ascending colon, and sigmoid colon. Of note, more than 70% of these tumors are located in the right hemicolon. Colonic lipomas are more common in women than in men, with a predilection for the right colon in women and the left colon in men. The mean age of patients with colonic lipomas falls within the sixth decade. Colonic lipomas vary in size from several millimeters to 30 cm. Lipomas are usually well-delineated, soft, ovoid, yellowish masses. These tumors

can be found by themselves or in groups, and they can be sessile or pedunculated.^{2,3} Several cases of primary colonic liposarcomas have been reported in the literature, whereas other lipomas are mostly seen in conjunction with retroperitoneal liposarcomas.⁴

Presentation

Colonic lipomas are generally asymptomatic and are found incidentally during a colonoscopy or surgery for other conditions. Symptoms correlate with the size of the lipoma; lipomas larger than 4 cm in size become symptomatic in 75% of patients.^{5,6} Lipomas often present with vague symptoms—such as abdominal pain and/or alterations in bowel habits—and rarely manifest as gastrointestinal bleeding, perforation, or obstruction.⁷ Giant lipomas (>4 cm) are the most common benign tumors in the colon that cause intussusception, although no specific incidence data have been documented.⁸ Even patients with large lipomas may have nonspecific or intermittent symptoms, which causes delay and difficulty in making the diagnosis. Intussusceptions are usually limited to 1 segment of the colon—either ascending, transverse, or descending—but can extend to more than 1 segment in some cases.⁹ Large lipomas may develop superficial ulceration and bleeding and may present with a combination of symptoms.¹⁰ Due to similarities in age and symptoms, colonic lipomas may mimic malignancy in presentation.

Gould and associates present a case of a colonic lipoma that meets the typical age, gender, and symptoms of this tumor but not the typical location or appearance; the patient had a large mass with atypical characteristics (ulceration) on gross examination, an atypical site, and development of intussusception.¹⁰

Address correspondence to:

Dr. Douglas G. Adler, Division of Gastroenterology, Hepatology, and Nutrition, Huntsman Cancer Center, University of Utah School of Medicine, 30N 1900E 4R118, Salt Lake City, UT 84132; Tel: 801-581-7878; Fax: 801-581-8007; E-mail: douglas.adler@hsc.utah.edu