

Images in Clinical Tropical Medicine

Leptospirosis after Typhoon

Chien-Yu Lin, Nan-Chang Chiu, and Chun-Ming Lee*

Division of Infectious Disease, Department of Pediatrics, Hsinchu Mackay Memorial Hospital, Hsinchu City, Taiwan; Division of Infectious Disease and Neurology, Department of Pediatrics, Mackay Memorial Hospital, Taipei; Mackay Medicine, Nursing and Management College, Taipei, Taiwan; Division of Infectious Disease, Department of Internal Medicine, Mackay Memorial Hospital, Taipei; Mackay Medicine, Nursing and Management College, Taipei; Taipei Medical University School, Taipei, Taiwan

Abstract. Leptospirosis is a zoonotic disease with protean manifestations. A 35-year-old male presented with pneumonia after the Typhoon Morakot. Skin rash, conjunctival suffusion, and subconjunctival hemorrhage led us to the diagnosis of leptospirosis and the microscopic agglutination test confirmed the diagnosis. This patient well demonstrated the picture of conjunctival suffusion and reminded us of the alertness of leptospirosis after a typhoon.

An immunocompetent 35-year-old male telecom company employee presented with fever and myalgia in early September 2009, a month after the moderate-strength Typhoon Morakot that caused a heavy rainfall in Taiwan. He was diagnosed with pneumonia with respiratory distress and shock (Figure 1). Intensive care with respiratory and inotropic support and broad-spectrum antibiotics with piperacillin/tazobactam were administered upon admission. He subsequently developed skin rash, conjunctival suffusion, and subconjunctival hemorrhage, which were suggestive of leptospirosis (Figures 2 and 3). Thus, empirical therapy with penicillin + ceftriaxone was initiated to treat leptospirosis and cover possible bacterial co-infection, although he could have been treated with either

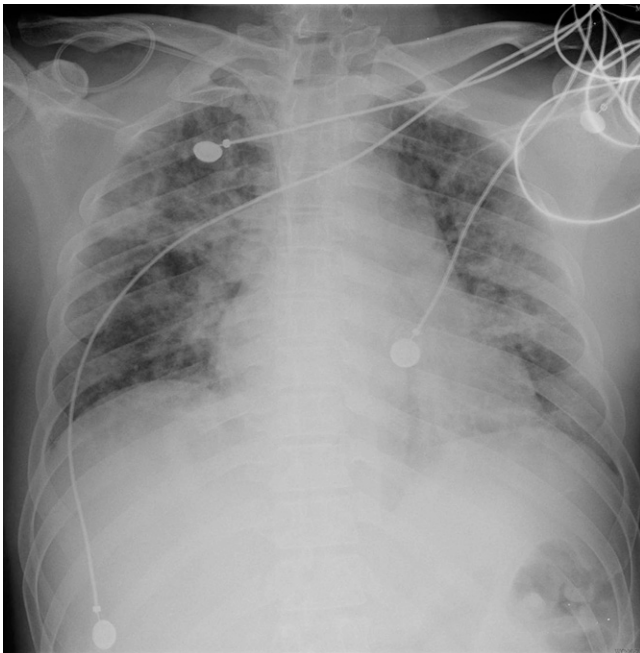


FIGURE 1. Chest roentgenography showing bilateral pneumonia with edema. Pneumonia with acute respiratory distress syndrome was suspected.

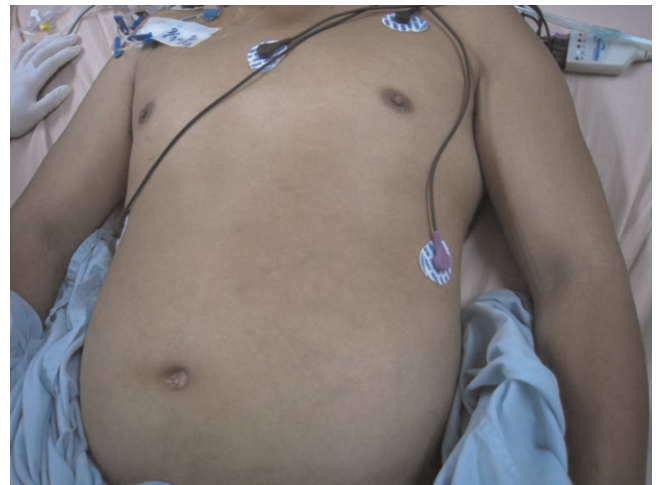

FIGURE 2. Fine, non-itching, red-colored eruptions developed over the abdomen on the second hospitalization day.

drug alone. His recovery was uneventful, and the microscopic agglutination test confirmed the diagnosis of leptospirosis.

Leptospirosis is a re-emerging worldwide zoonotic waterborne disease with protean manifestations and remains a diagnostic challenge. Leptospirosis has a low annual incidence

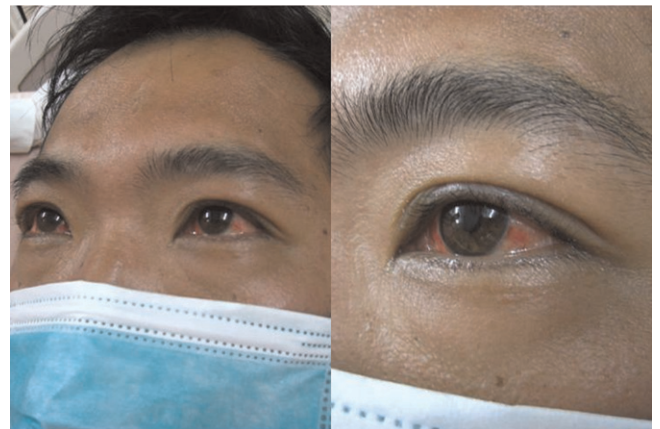


FIGURE 3. Conjunctival suffusion with subconjunctival hemorrhage (ou), which was suggestive of leptospirosis, developed on the second hospitalization day.

* Address correspondence to Chun-Ming Lee, Department of Internal Medicine, Mackay Memorial Hospital, 92, Section 2, Chungshan North Road, Taipei, Taiwan. E-mail: a6159@ms7.mmh.org.tw

in Taiwan ($< 1/100,000$) and is often associated with occupational exposure.¹ However, outbreaks may occur after natural disasters including typhoons, heavy rain, and floods.² Leptospirosis has diverse clinical courses, ranging from subclinical infection to fatal multiple organ failure. The microscopic agglutination test is time-consuming and timely treatment is valuable for patients with severe illness. Conjunctival suffusion is indicative of leptospirosis, and a high index of suspicion should be maintained in tropical and subtropical areas, particularly after typhoons.

Received August 10, 2011. Accepted for publication August 30, 2011.

Disclaimer: The authors declare that they have no competing interests.

Authors' addresses: Chien-Yu Lin, Division of Infectious Disease, Department of Pediatrics, Hsinchu Mackay Memorial Hospital,

Hsinchu City, Taiwan, E-mail: mmhped.lin@gmail.com. Nan-Chang Chiu, Division of Infectious Disease and Neurology, Department of Pediatrics, Mackay Memorial Hospital, Taipei; Mackay Medicine, Nursing and Management College, Taipei, Taiwan, E-mail: ncc88@ms2.mmh.org.tw. Chun-Ming Lee, Division of Infectious Disease, Department of Internal Medicine, Mackay Memorial Hospital, Taipei; Mackay Medicine, Nursing and Management College, Taipei; Taipei Medical University School, Taipei, Taiwan, E-mail: a6159@ms7.mmh.org.tw.

REFERENCES

1. Victoriano AF, Smythe LD, Gloriani-Barzaga N, Cavinta LL, Kasai T, Limpakarnjanarat K, Ong BL, Gongal G, Hall J, Coulombe CA, Yanagihara Y, Yoshida S, Adler B, 2009. Leptospirosis in the Asia Pacific region. *BMC Infect Dis* 9: 147.
2. Su HP, Chan TC, Chang CC, 2011. Typhoon-related leptospirosis and melioidosis, Taiwan, 2009. *Emerg Infect Dis* 17: 1322–1324.