

ADVANCES IN ENDOSCOPY

Current Developments in Diagnostic and Therapeutic Endoscopy

Section Editor: John Baillie, MB ChB, FRCP

Endoscopic Ultrasound Elastography



Paolo Giorgio Arcidiacono, MD
Chief, Endosonography Unit
Gastroenterology and Gastrointestinal Endoscopy Unit
Vita Salute San Raffaele University
San Raffaele Scientific Institute
Milan, Italy

G&H Currently, how common is the use of endoscopic ultrasound for the detection and staging of gastrointestinal diseases? Is this modality now being used more frequently than endoscopic retrograde cholangiopancreatography?

PGA Endoscopic ultrasound (EUS) has evolved over time into a diagnostic and therapeutic modality that has a major clinical impact on both digestive and mediastinal diseases. Nevertheless, the main indication of EUS has remained the diagnosis and staging of pancreatobiliary diseases, for which EUS is currently considered to be the first-choice examination. Due to its high accuracy, EUS has almost displaced endoscopic retrograde cholangiopancreatography (ERCP) as a diagnostic modality for studying the common bile duct and pancreas. For this reason, the number of EUS procedures is increasing each year, and, consequently, the number of diagnostic ERCP procedures is decreasing.

G&H EUS elastography is a relatively recent addition to the tools used by EUS endoscopists. How does this new modality work?

PGA EUS elastography is an imaging modality that has recently been proposed for the visualization and evaluation of tissue elasticity. This method enables areas with varying elasticities to be differentiated within a target organ. The principle of elastography is based on the assumption that compression of a target tissue by an echoendoscopic probe creates a strain (ie, displacement of one tissue structure by another) that differs according to the hardness and softness of the tissue. Thus, by calculating the elasticity of tissue, it is possible to differentiate benign (soft) tissue from malignant (hard) tissue.

As the EUS elastography procedure is being performed, elastography is shown in real time as transparent color images (red, green, and blue) in a region-of-interest box that is superimposed over the conventional gray-scale b-mode EUS image, similar to color Doppler images. Strain is shown via different colors based on the elasticity of the tissue: Green indicates soft tissue, whereas blue indicates hard tissue. This evaluation of tissue elasticity is qualitative.

Recently, the echographic systems were updated with new software that can improve elastography quality by calculating the strain ratio. This software can calculate the difference in elasticity between abnormal tissue and surrounding normal tissue, yielding an absolute number, which is the quotient between the elasticity of the 2 tissues.

G&H What are the principal applications of EUS elastography?

PGA The first application of EUS elastography involved the differential diagnosis of pancreatic lesions. Giovannini and colleagues showed the possibility of using elastography to distinguish among the various types of pancreatic lesions according to their elastographic features. The authors proposed a classification system of 5 elastic scores corresponding to normal pancreatic tissue, chronic pancreatitis, small pancreatic cancer, neuroendocrine tumor, and large pancreatic cancer, with an overall sensitivity of 100% in tumor detection and a specificity of 67% in differentiation among the different types of tumors (Figures 1 and 2). These data have recently been confirmed by a prospective, European, multicenter trial conducted by the European Elastography Group, which examined the differential diagnosis of 258 patients with focal pancreatic masses at 13 participating centers. In this study, EUS elastography showed a sensitivity of 93.4%, a specificity of 66.0%, a positive predictive value of 92.5%, a negative predictive value of 68.9%, and an overall accuracy of 85.4%.

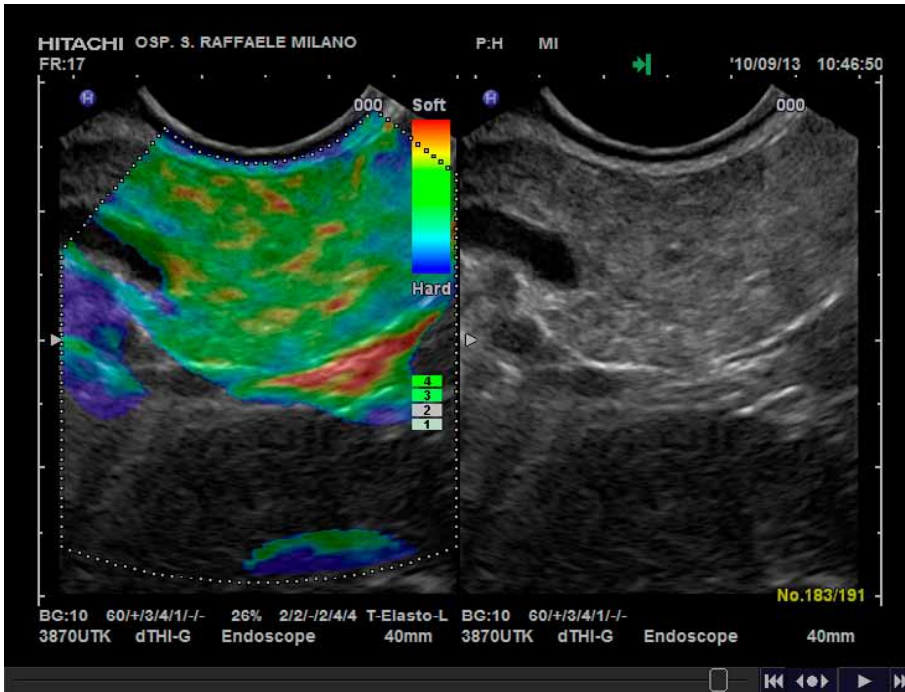


Figure 1. Endoscopic elastography image of a normal pancreas.

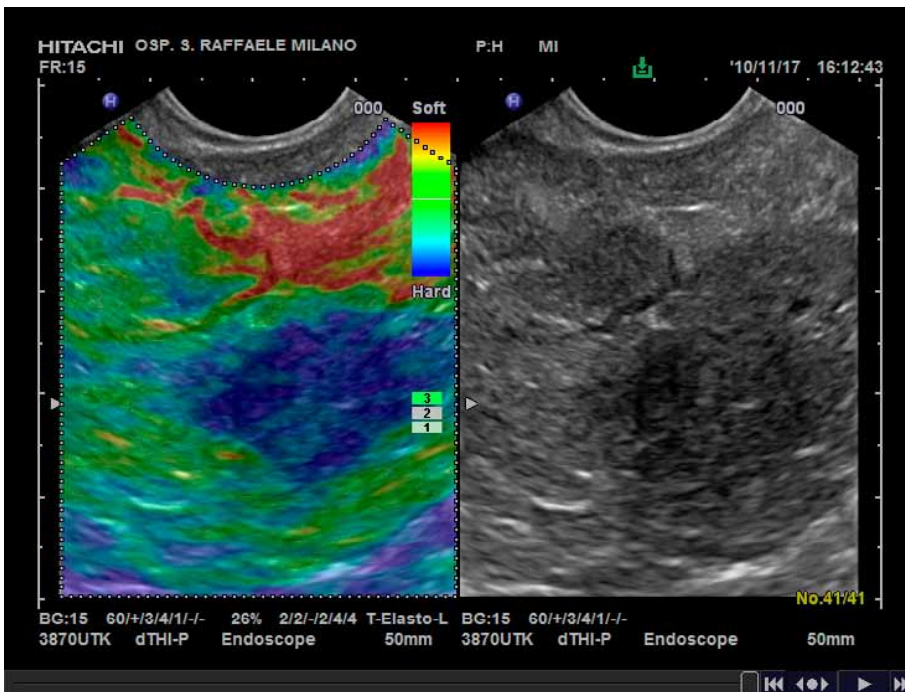


Figure 2. Endoscopic elastography image of pancreatic cancer.

Using quantitative analysis of the strain ratio, Iglesias-Garcia and colleagues reported that the specificity and negative predictive values for elastography increase to 92% and 100%, respectively, for differentiating among the various types of pancreatic lesions. The authors also set standard cutoffs for quantitative levels of strain ratio that are predictive of the different types of pancreatic lesions (Figure 3).

The other main target of EUS elastography is the differential diagnosis of lymph node invasion. Since the first report by Giovannini and colleagues, other papers have also reported the high specificity of this technique for differentiating malignant lymph nodes. In addition, a recent meta-analysis examined 7 of 72 published studies and reported that EUS elastography had a pooled sensitivity and specific-

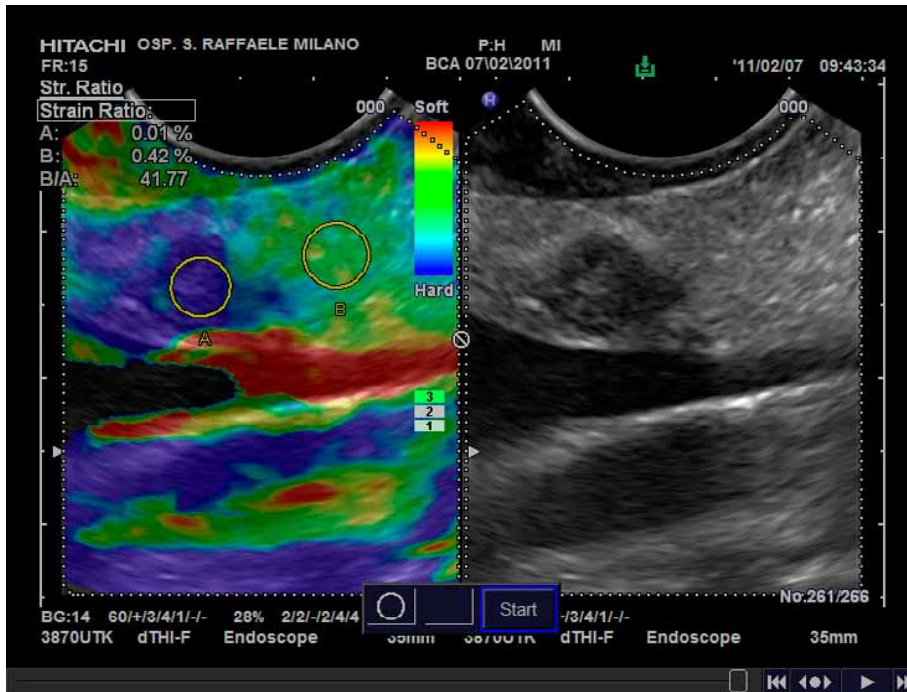


Figure 3. Endoscopic elastography image of a small pancreatic neuroendocrine tumor with strain ratio.

ity of 85% and 91%, respectively, for differentiating between malignant lymph nodes and benign lymph nodes.

G&H What are the advantages of using EUS elastography, particularly compared to using EUS alone?

PGA All of the studies that have been published on elastography underline its capability to help the endosonographer select a site where fine-needle aspiration (FNA) can be performed with improved accuracy. This is particularly true in the setting of chronic pancreatitis, where the negative predictive value of EUS and EUS-FNA is low (nearly 70%).

It is well known that using EUS appearance to differentiate benign lymph nodes from malignant ones is difficult and that EUS morphologic criteria have low specificity. For this reason, EUS-FNA is usually performed to obtain a pathologic diagnosis. EUS elastography could be a valuable method for guiding FNA to an appropriate target, thus reducing the number of false-negative results and repeated procedures.

The most significant advantage of EUS elastography is its real-time results; it can be performed during a diagnostic examination and can immediately give the endosonographer important information that can impact the patient's management.

G&H What are the limitations of this modality?

PGA This procedure has several limitations, some of which are not amenable to correction and some of which

have already been addressed by technical improvements in software. The main pitfall of EUS elastography is the endosonographer's inability to control tissue compression. In external ultrasound elastography, it is well known that a strong pressure on the target tissue can result in a misdiagnosis; this problem is almost impossible to avoid during EUS. Usually, no or minimal pressure is required to obtain a good compression from the pulsatility of abdominal vessels.

Another difficulty is when there are no or minimal soft tissues surrounding the target zone, such as with lymph nodes in the mediastinum that are very close to the aorta or spine. In this scenario, artifacts caused by these extremely rigid tissues could hamper the acquisition of good pictures.

In the first ultrasound machines that had EUS elastography, pictures were selected by the endosonographer, introducing a significant selection bias. The current state-of-the-art echographic machines include software that produces, in real time, a short elastography movie that analyzes the hue histogram of each individual elastographic image and creates a single picture that serves as the elastography pattern of all of the recorded frames. This process avoids the problem of selection bias.

G&H Is EUS elastography being used in the average clinical practice or just in specialized centers?

PGA The use of EUS elastography is increasing in Europe, particularly in referring centers, which have a higher prevalence of difficult cases in which a differential diagnosis is requested compared to smaller centers.

(Continued on page 67)

(Continued from page 50)

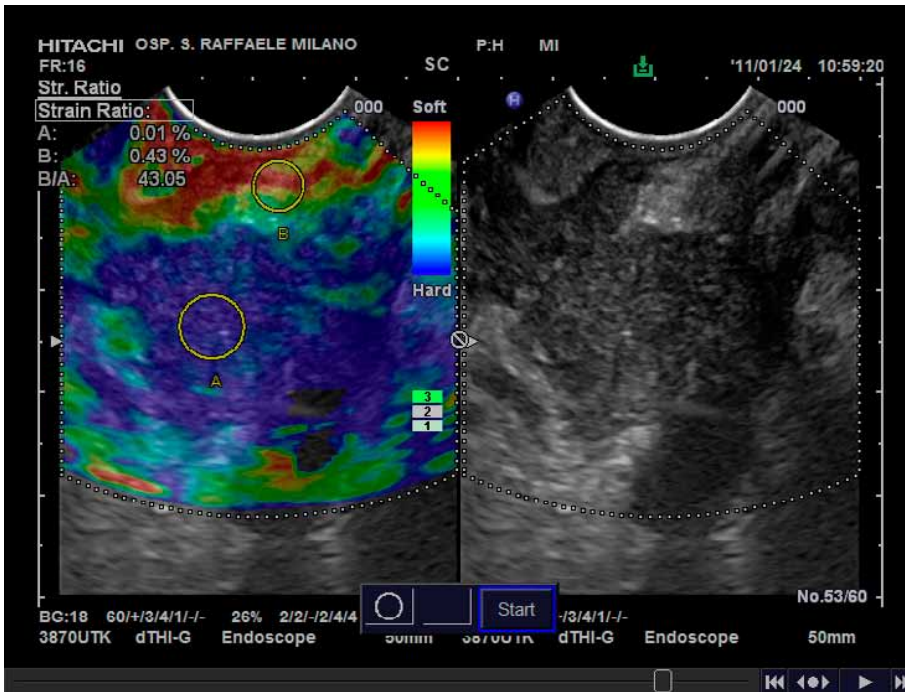


Figure 4. Endoscopic elastography image of pancreatic cancer with vessel encasement and strain ratio.

Until recently, diffusion of elastography among centers was limited by the fact that this technology was only available with Pentax-Hitachi instruments. Now, a similar type of technology is provided on Olympus systems as well.

G&H Do EUS endoscopists need additional training to use elastography?

PGA There is no need for additional training for an expert EUS endoscopist to perform a good elastography procedure. The key factor for performing this procedure is a good setting of the ultrasound machine, which is usually provided by the manufacturer.

G&H Do you foresee elastography being used for other EUS applications in the future?

PGA Several other indications are being investigated with EUS elastography. One potential indication is the examination of rectal cancer following radiotherapy treatment to evaluate residual cancer in an area of fibrosis or post-treatment inflammation. Another potential indication includes differential diagnosis of vessel infiltration by pancreatic cancer (Figure 4). The adhesion of pancreatic cancer to the vessel wall may occasionally be inflammatory in nature and may not reflect true involvement; EUS elastography could differentiate

between these 2 scenarios, which could greatly influence the patient's management.

G&H Are there any upcoming or ongoing studies examining the use of EUS elastography?

PGA The European Elastography Group is currently examining a neural network–based approach for diagnosing pancreatic masses and correlating EUS elastography with contrast-enhanced EUS to improve sensitivity and specificity for the differential diagnosis of pancreatic cancer.

Suggested Reading

Giovannini M, Thomas B, Erwan B, et al. Endoscopic ultrasound elastography for evaluation of lymph nodes and pancreatic masses: a multicenter study. *World J Gastroenterol.* 2009;15:1587-1593.

Săftoiu A, Vilmann P, Gorunescu F, et al; European EUS Elastography Multicentric Study Group. Efficacy of an artificial neural network-based approach to endoscopic ultrasound elastography in diagnosis of focal pancreatic masses. *Clin Gastroenterol Hepatol.* 2012;10:84.e1-90.e1.

Iglesias-Garcia J, Larino-Noia J, Abdulkader I, Forteza J, Dominguez-Munoz JE. Quantitative endoscopic ultrasound elastography: an accurate method for the differentiation of solid pancreatic masses. *Gastroenterology.* 2010;139:1172-1180.

Xu W, Shi J, Zeng X, et al. EUS elastography for the differentiation of benign and malignant lymph nodes: a meta-analysis. *Gastrointest Endosc.* 2011;74:1001-1009; quiz 1115.e1-1115.e4.

Săftoiu A, Vilmann P, Gorunescu F, et al; European EUS Elastography Multicentric Study Group. Accuracy of endoscopic ultrasound elastography used for differential diagnosis of focal pancreatic masses: a multicenter study. *Endoscopy.* 2011;43:596-603.