

Trichuris vulpis (Froelich, 1789) Infection in a Child: A Case Report

Adrian Márquez-Navarro¹, Gudelio García-Bracamontes², Blanca E. Álvarez-Fernández³, Luz P. Ávila-Caballero³,
Isabel Santos-Aranda³, Dylan L. Díaz-Chiguer¹, Rosa M. Sánchez-Manzano¹, Elvia Rodríguez-Bataz³
and Benjamín Noguera-Torres^{1,*}

¹Departamento de Parasitología, Escuela Nacional de Ciencias Biológicas-IPN, México DF, 11340, México; ²Hospital General de Ometepepec, Carretera Ometepepec-Acapulco km 2.25, Ometepepec, Guerrero, México; ³Unidad Académica de Ciencias Químico Biológicas de la U.A.G., Av. Lázaro Cárdenas, S/N. Ciudad Universitaria, 39090, Chilpancingo, Guerrero, México

Abstract: We present a human infection with the canine whipworm, *Trichuris vulpis*, in a child suffering from rhinitis with a diagnosis of rhinitis. *T. vulpis* eggs resemble those of *T. trichiura* but they can be differentiated based on their morphological features and egg size, using micrometry with an ocular micrometer. *T. vulpis* eggs measured an average of 90 µm by 44 µm (range 86-99 µm by 38-47 µm). Prevalence of hookworms (28.1%), *Toxocara canis* (11.8%), and *Trichuris vulpis* (3.5%) was found in 292 fecal samples of dogs collected at the peri-domicile, which showed that the risk of infection was not only fortuitous. The treatment of canine whipworm infections is similar to that of *T. trichiura* infection. We recommend differentiation of the 2 species for their epidemiological and prevention implications.

Key words: *Trichuris vulpis*, canine whipworm, micrometry, rhinitis

INTRODUCTION

Trichuriasis is a common soil-transmitted helminthiasis in tropical and subtropical regions with an estimated of 604-795 million infected people and a global prevalence of 22-44.9% [1,2]. In Latin America and Caribbean countries, it is estimated that 100 million people are infected with *Trichuris trichiura* (prevalence of 19%), where 66% of those infected were over 15 years of age [2,3]. In addition, the landscape of geohelminthiasis has also changed because the incidence has decreased significantly not only due to appropriate control measures by government but also by migration of rural people to urban zones [2,4]. The etiological agents of trichuriasis are *Trichuris suis* in swine, *Trichuris vulpis* in canids, and *T. trichiura* in man. Although *T. vulpis* or *T. suis* are rarely found in humans, they can cause an uncommon zoonosis. Light *Trichuris* infections are often asymptomatic but in heavy infections, some patients develop eosinophilia, dysentery syndrome, anemia, mucosal

swelling, tenesmus, and rectal prolapse. The first case of *T. vulpis* in man was reported in 1956 by Hall and Sonnenberg [5] in a 4-year-old child. Since then, several cases have been reported in the literature as single infections in some communities [6-8] [6-13]. In addition, mixed infections by *T. trichiura* and *T. vulpis* were reported in Mexico [9,14].

The diagnosis of trichuriasis is based on the identification of eggs by coproparasitologic analysis. *Trichuris* eggs have particular morphological characteristics which, in routine analysis, technicians diagnose them only as *T. trichiura* eggs. However, *T. vulpis* eggs can occasionally be confused with *T. trichiura* eggs. Therefore, it is important to identify accurately *T. vulpis* eggs in stool examinations to perform a suitable diagnosis and hence to carry out appropriate actions. In the present study, we report a case of *T. vulpis* infection in a Mexican child.

CASE RECORD

A 9-years-old girl was presented at the medical services with epistaxis lasting 2 years. The patient had nasal bleeding 4 times a day for 5 days without an apparent cause. Physical examination showed normal pharynx and moderate rhinorrhea. The x-ray did not show cardiopulmonary complications, and there were no symptoms of abdominal discomfort. The diagnosis

•Received 2 November 2011, revised 8 December 2011, accepted 7 January 2012.

*Corresponding author (bnogueta@yahoo.com)

© 2012, Korean Society for Parasitology

This is an Open Access article distributed under the terms of the Creative Commons Attribution Non-Commercial License (<http://creativecommons.org/licenses/by-nc/3.0>) which permits unrestricted non-commercial use, distribution, and reproduction in any medium, provided the original work is properly cited.

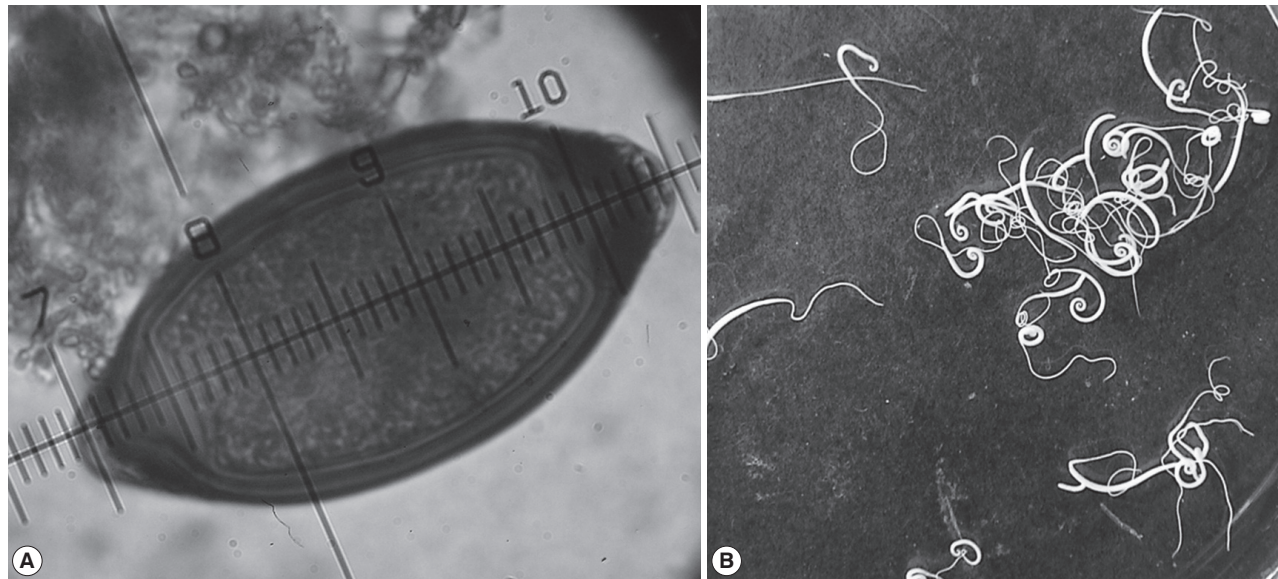


Fig. 1. An egg measured with an ocular micrometer (A) and adult worms (B) of *Trichuris vulpis* from a 9-year-old girl in Mexico.

was rhinitis. After that, the patient was presented at the medical services with a clinical history of abdominal discomfort and new epistaxis. Laboratory tests showed mild eosinophilia in a blood test. The patient submitted a fecal sample which was concentrated and examined following standard laboratory protocols. There were no worms in the feces but the examination with iodine wet mount showed the presence of yellowish-brown eggs with 2 polar plugs that resemble *Trichuris* eggs. The average size of the eggs was 90 μm in length and 44 μm in width (range 86-99 μm by 38-47 μm) (Fig. 1A).

Based on these findings, this case was diagnosed as *T. vulpis* (Froelich, 1789) infection. The infection probably did not occur at home, since no eggs of *T. vulpis* were detected in the coproparasitologic studies of their 2 pets, but in 292 fecal samples of dogs collected in a period of 5 days in the peri-domicile, prevalence of hookworms (28.1%), *Toxocara canis* (11.8%), and *Trichuris vulpis* (3.5%) was found. The patient was treated with mebendazole 100 mg per os twice daily for 3 days. From the first day of treatment, whitish worms were released in the feces (Fig. 1B). Numerous pieces of worms immersed in the semisolid feces were observed. The number of intact adult specimens collected were 315 and their morphology resembled *T. vulpis*. The size was 7.4 ± 1.2 cm and the thinnest parts (esophagus) were reddish but soon they became whitish. The ratio of males and females was 1:4. In follow-up stool examinations, neither adult worms nor eggs of *T. vulpis* were found in there feces.

DISCUSSION

Micrometry is a useful tool in the identification of different stages of parasites. In many laboratories, the lack of an ocular micrometer makes these organisms misidentified during routine stool examinations. The eggs of *T. trichiura* measure 50 to 55 μm length by 20 to 25 μm width (Fig. 1A), while *T. vulpis* eggs measure 72 to 90 μm length by 32 to 40 μm width (Fig. 1A). However, occasionally a small proportion of large *T. trichiura* eggs were found which can measure up to 78 μm length and 30 μm width [10,15], while in *T. vulpis*, the majority of eggs are bigger (90 μm long and 74 μm wide). These differences have also been demonstrated by other authors [11,12,16,17]. There has been an approach using molecular tools, which could help identifying different species of *Trichuris* sp. [13,14,18,19], but their application on many laboratories is difficult, particularly in underdeveloped countries. Since *T. vulpis* eggs were not found in the feces of the family pet, we analyzed the feces of dogs at the peri-domicile. The frequency of *T. vulpis* was 3.5%. Therefore, the infection probably occurred through contact with dogs that are close to home.

T. vulpis have been found to cause visceral larva migrans [15, 16,20,21]. The eosinophilia found in this patient may have been caused by migration of larval forms in early stages of the disease, so the rhinitis could be associated with the presence of *T. vulpis*. The nasal mucosa might have been involved and rhinitis was caused for a long period of time. This clinical presen-

tation gradually decreased after the antiparasitic treatment.

The treatment of trichuriasis in humans is based on the use of mebendazole as a drug of choice [17,22], but the prevention and control measures are different when other species are found. So, it is imperative to achieve an accurate diagnosis in order to prevent further infections or reinfections, particularly considering the nature of *T. vulpis* as a zoonotic agent and the role of dogs as a source of infection. Due to a variety in the size of *T. trichiura* eggs in human feces, we recommend routine use of micrometry of eggs for an accurate identification of *Trichuris* species.

REFERENCES

- Bethony J, Brooker S, Albonico M, Geiger SM, Loukas A, Diemert D, Hotez PJ. Soil-transmitted helminth infections: Ascariasis, trichuriasis, and hookworm. *Lancet* 2006; 367: 1521-1532.
- de Silva NR, Brooker S, Hotez PJ, Montresor A, Engels D, Savioli L. Soil-transmitted helminth infections: Updating the global picture. *Trends Parasitol* 2003; 19: 547-551.
- Hotez PJ, Brindley PJ, Bethony JM, King CH, Pearce EJ, Jacobson J. Helminth infections: The great neglected tropical diseases. *J Clin Invest* 2008; 118: 1311-1321.
- Carrada-Bravo T. Trichuriasis: Epidemiología, diagnóstico y tratamiento. *Rev Mex Ped* 2004; 71: 299-305.
- Hall JE, Sonnenberg B. An apparent case of human infection with the whipworm of dogs, *Trichuris vulpis* (Froelich, 1789). *J Parasitol* 1956; 42: 197-199.
- De Carneri I, Gazzola E, Biagi F. Repeated infestations, presumably, of *Trichuris vulpis* in a child living in an endemic region of trichocephalosis. *Riv Parassitol* 1971; 32: 135-136.
- Kennedy M, Eveland LK. Infection of man with *Trichuris vulpis*, the whipworm of dogs. *Am J Clin Pathol* 1978; 69: 199.
- Kennedy M, Yermakov V. Infection of man with *Trichuris vulpis*, the whipworm of dogs. *Am J Trop Med Hyg* 1980; 29: 1205-1208.
- Lineburg A, Jastrzebski M. A case of infestation with *Trichuris* (*Trichocephalus vulpis*) Froelich, 1789 (Nematoda, Enoplida) in Poland. *Wiad Parazytol* 1987; 33: 181-184.
- Dunn JJ, Columbus ST, Aldeen WE, Davis M, Carroll KC. *Trichuris vulpis* recovered from a patient with chronic diarrhea and five dogs. *J Clin Microbiol* 2002; 40: 2703-2704.
- Kagei N, Hayashi S, Kato K. Human cases of infection with canine whipworms, *Trichuris vulpis* (Froelich, 1789), in Japan. *Jpn J Med Sci Biol* 1986; 39: 177-184.
- Singh S, Samantaray JC, Singh N, Das GB, Verma IC. *Trichuris vulpis* infection in an Indian tribal population. *J Parasitol* 1993; 79: 457-458.
- Mirdha BR, Singh YG, Samantray JC, Mishra B. *Trichuris vulpis* infection in slum children. *Indian J Gastroenterol* 1998; 17: 154.
- Vásquez TO, Martínez BII, Romero CR, Valencia RS, Tay ZJ. Mixed infection by *Trichuris trichiura* and *Trichuris vulpis*. *Rev Gastroenterol Peru* 1997; 17: 255-258.
- Yoshikawa H, Yamada M, Matsumoto Y, Yoshida Y. Variations in egg size of *Trichuris trichiura*. *Parasitol Res* 1989; 75: 649-654.
- Correa LL, Yamanaka MT, Correa M, Silva M, Silva R. Ocorrência de ovos grandes de *Trichuris trichiura* em fezes humanas. *Rev Inst Adolfo Lutz* 1980; 40: 59-64.
- Ash LR, Orihel TC. *Atlas of Human Parasitology*. 4th ed. Chicago, USA. American Society of Clinical Pathologists Press. 1997.
- Cutillas C, de Rojas M, Ariza C, Ubeda JM, Guevara D. Molecular identification of *Trichuris vulpis* and *Trichuris suis* isolated from different hosts. *Parasitol Res* 2007; 100: 383-389.
- Areekul P, Putaporntip C, Pattanawong U, Sitthicharoenchai P, Jongwutiwes S. *Trichuris vulpis* and *T. trichiura* infections among schoolchildren of a rural community in northwestern Thailand: the possible role of dogs in disease transmission. *Asian Biomed* 2010; 4: 49-60.
- Sakano T, Hamamoto K, Kobayashi Y, Sakata Y, Tsuji M, Usui T. Visceral larva migrans caused by *Trichuris vulpis*. *Arch Dis Child* 1980; 55: 631-633.
- Masuda Y, Kishimoto T, Ito H, Tsuji M. Visceral larva migrans caused by *Trichuris vulpis* presenting as a pulmonary mass. *Thorax* 1987; 42: 990-991.
- Knopp S, Mohammed KA, Speich B, Hattendorf J, Khamis IS, Khamis AN, Stothard JR, Rollinson D, Marti H, Utzinger J. Albendazole and mebendazole administered alone or in combination with ivermectin against *Trichuris trichiura*: a randomized controlled trial. *Clin Infect Dis* 2010; 51: 1420-1428.

