

Research Article

Reduced Striatal Dopamine Transporters in People with Internet Addiction Disorder

Haifeng Hou,^{1,2,3,4} Shaowe Jia,⁵ Shu Hu,⁵ Rong Fan,⁵ Wen Sun,⁵
Taotao Sun,⁵ and Hong Zhang^{1,2,3,4}

¹Department of Nuclear Medicine, Second Affiliated Hospital of Zhejiang University School of Medicine, Hangzhou, Zhejiang 310009, China

²Zhejiang University Medical PET Center, Hangzhou 310009, China

³Institute of Nuclear Medicine and Molecular Imaging, Zhejiang University, Hangzhou 310009, China

⁴Key Laboratory of Medical Molecular Imaging of Zhejiang Province, Hangzhou 310009, China

⁵Department of Nuclear Medicine, Peking University Shenzhen Hospital, Shenzhen 310009, China

Correspondence should be addressed to Hong Zhang, hzhang21@gmail.com

Received 5 January 2012; Accepted 31 January 2012

Academic Editor: Mei Tian

Copyright © 2012 Haifeng Hou et al. This is an open access article distributed under the Creative Commons Attribution License, which permits unrestricted use, distribution, and reproduction in any medium, provided the original work is properly cited.

In recent years, internet addiction disorder (IAD) has become more prevalent worldwide and the recognition of its devastating impact on the users and society has rapidly increased. However, the neurobiological mechanism of IAD has not been fully expressed. The present study was designed to determine if the striatal dopamine transporter (DAT) levels measured by ^{99m}Tc-TRODAT-1 single photon emission computed tomography (SPECT) brain scans were altered in individuals with IAD. SPECT brain scans were acquired on 5 male IAD subjects and 9 healthy age-matched controls. The volume (*V*) and weight (*W*) of bilateral corpus striatum as well as the ^{99m}Tc-TRODAT-1 uptake ratio of corpus striatum/the whole brain (*Ra*) were calculated using mathematical models. It was displayed that DAT expression level of striatum was significantly decreased and the *V*, *W*, and *Ra* were greatly reduced in the individuals with IAD compared to controls. Taken together, these results suggest that IAD may cause serious damages to the brain and the neuroimaging findings further illustrate IAD is associated with dysfunctions in the dopaminergic brain systems. Our findings also support the claim that IAD may share similar neurobiological abnormalities with other addictive disorders.

1. Introduction

The use of the internet has expanded incredibly across the world over the last few years. The internet provides remote access to others and abundant information in all areas of interest. However, maladaptive use of the internet has resulted in impairment of the individual's psychological well-being, academic failure, and reduced work performance and, especially led to internet addiction disorder (IAD) [1–4]. IAD was first raised in 1990s [5] and according to the Beard's definition of IAD, "an individual is addicted when an individual's psychological state, which includes both mental and emotional states, as well as their scholastic, occupational, and social interactions, is impaired by the overuse of the medium." [6]

In recent years, IAD has become more prevalent worldwide; the recognition of its devastating impact on the users and society has rapidly increased [7]. Importantly, recent studies have found dysfunctions of IAD are similar to other types of addictive disorders, such as substance abuse disorders and pathological gambling [7–10]. People experiencing IAD showed clinical features such as craving, withdrawal and tolerance [7, 8], increased impulsiveness [9], and impaired cognitive performance in tasks involving risky decision-making [10].

As similar with the abnormalities in the dopaminergic neural system in individuals with substance-related addiction [11], the role of dopaminergic neural system in IAD also has been elucidated in a few researches [12–14]. In a recent study, people with IAD were found to have altered

resting-state glucose metabolism in several brain regions including the major dopamine projection areas such as the striatum and orbitofrontal region [12]. Moreover, another study found that adolescents with increased genetic polymorphisms in genes coding for the dopamine D2 receptor and dopamine degradation enzyme were more susceptible to excessive internet gaming compared with an age-matched cohort of controls [14]. In a positron emission tomography (PET) imaging study, reduced levels of dopamine D2 receptor in subdivisions of the striatum including the bilateral dorsal caudate and right putamen were found in the individuals with IAD [13]. Taken together, these findings suggest that IAD may also be partly due to impaired dopaminergic neural systems similar to substance-related addiction [15].

Dopamine transporter (DAT) is a protein situated in the presynaptic terminal and striatal DAT is responsible for the active dopamine reuptake into the presynaptic neuron and plays a critical role in the regulation of striatal synaptic dopamine levels [16–18]. Altered DAT concentration in the striatum following chronic substance administration has been reported previously [19–24]. However, whether the abnormality of DAT also exists in IAD has not been illustrated before.

In recent years, imaging of DAT has been used as an important tool in clinical settings to display changes in the brain structure of patients with substance-related addiction [21–24]. In addition, the radiotracer ^{99m}Tc -TRODAT-1, a technetium-99 m (^{99m}Tc) labeled tropane derivative (technetium,2-[[2-[[[3-(4-chlorophenyl)-8-methyl-8-azabicyclo[3, 2, 1]oct-2-yl]-methyl](2-mercaptoethyl)amino]ethyl]-amino]ethanethiolato(3-)]-oxo-[1R-(exo-exo)]-), is regarded as a safe and suitable imaging agent for monitoring DAT status for human imaging studies [21, 25, 26]. In the present study, we used single photon emission tomography (SPECT) with the radiotracer ^{99m}Tc -TRODAT-1 to investigate striatal DAT density to identify potential presynaptic abnormalities in IAD subjects compared to age-matched healthy controls. This study aims to test the hypothesis that the altered availability of DAT is associated with the pathogenesis of IAD.

2. Materials and Methods

2.1. Diagnosed Criteria of IAD. IAD was assessed using Young's Internet Addiction Diagnostic Questionnaire (IADDQ) [4] and Goldberg's Internet addictive Disorder Diagnostic Criteria (IADDC) [27]. All of the questions of IADDQ and IADDC were translated into Chinese. To be eligible, participants in the IAD group were asserted that five or more "yes" responses to the eight questions of IADDQ and to satisfy three or more of IADDC (i.e., tolerance, withdrawal, craving and unplanned use, failure to reduce use, excessive use, sacrificing social activities to use, and physical and psychological problems associated with use).

2.2. Subjects. Five men (mean \pm SD, 20.40 \pm 2.30 years old) with IAD were randomly selected from the patients seeking treatment at the Peking University Shenzhen Hospital.

The IAD subjects used the internet almost everyday, and spend more than 8 hours (mean \pm SD, 10.20 \pm 1.48 hours) everyday in front of the monitor, mostly for chatting with cyber friends, playing online games, and watching online pornographies or adult movies. These subjects were initially familiar with internet mostly at the early stage of their adolescence (mean age \pm SD, 12.80 \pm 1.92 years old) and had the indications of IAD for more than 6 years (mean \pm SD, 7.60 \pm 1.52 years).

Nine age-matched controls (mean \pm SD, 20.44 \pm 1.13 years old) recruited through advertisement participated in this study. No statistical difference was found for the ages of the participants between the two groups ($P = 0.96$). The participants in the control group used Internet occasionally or frequently but spent no more than 5 hours a day on the line (mean \pm SD, 3.81 \pm 0.76 hours) and did not satisfy the diagnosed criteria of IAD [4, 27].

All the recruited participants were native Chinese speakers, never used illegal substances (sometimes, a few of the participants smoked or drink alcohol, but none of them meet the diagnosis criteria of substance-related disorders [28]), had no history of significant medical, neurological or psychiatric diseases, and were right-handed. All the participants gave written informed consent before participation after the nature of the procedure was fully explained, including possible risks and side effects. All procedures for this study were approved by the ethics committee of the Peking University Shenzhen Hospital.

2.3. Imaging. TRODAT-1 ligand (liquid) was supplied by the Department of Chemistry, Beijing Normal University (Beijing, China). The radiotracer ^{99m}Tc -TRODAT-1, 740 MBq (20 mCi) with purity >90% was synthesized as described previously [25]. And SPECT studies with ^{99m}Tc -TRODAT-1 were carried out using a Siemens DIACAM/E.CAM/ICON double detector SPECT with lower-energy all-purpose collimator (Siemens, Erlangen, Germany). The imaging method was performed as described previously [25, 29]. Subjects were injected intravenously with 740 MBq (20 mCi) of ^{99m}Tc -TRODAT-1. Imaging was performed 2.5 h after the administration of ^{99m}Tc -TRODAT-1. The acquisition parameters included 64 views over 18 s per view and a 128 \times 128 matrix over 360° with a rotation in 5.6° increments. Transverse reconstruction backprojection was applied to the raw data. A Butterworth filter was then applied with an order of 15 and a cutoff of 0.33 Nyquist frequency. Photon attenuation correction was performed using Chang's first order correction method using an attenuation coefficient of 0.15 cm^{-1} [30]. The transverse image thickness was 2.7 mm (1 pixel). All images were processed and reconstructed using the same procedure.

2.4. Image Analysis. Image analysis was done using the region ratio software of the E-Cam. Regions of interest (ROIs) were drawn on 12 transverse images, the pixels were extracted and counts of whole brain and bilateral corpus striatum were carried out. The volume (V) and weight (W) of bilateral corpus striatum as well as the ratio of

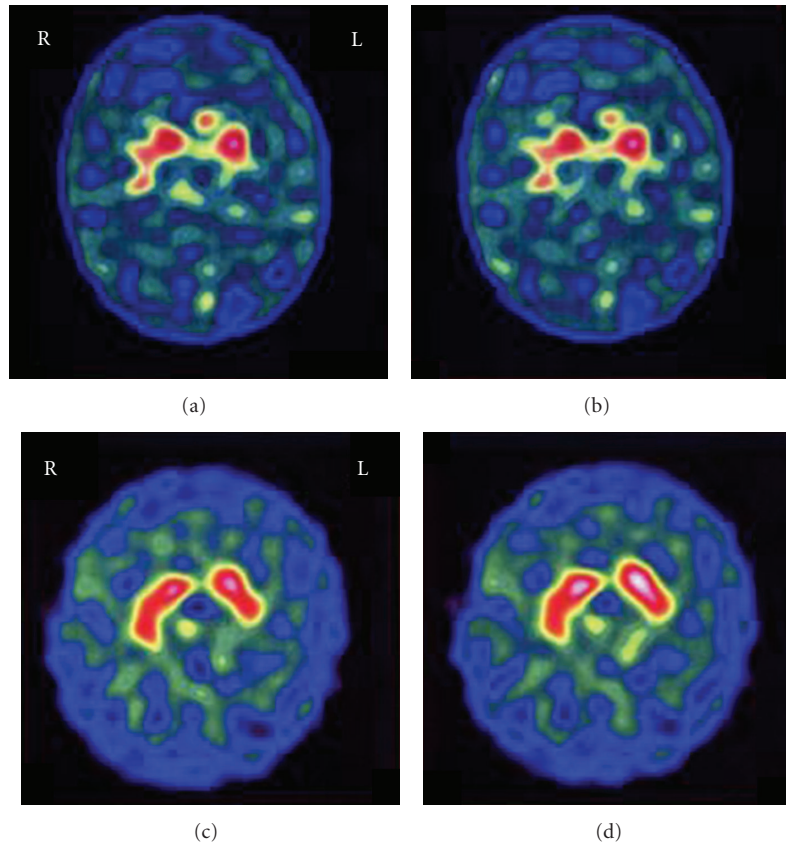


FIGURE 1: (a,b) representative ^{99m}Tc -TRODAT-1 SPECT images of an IAD subject in comparison with an age-matched healthy control ((a) a 20-year-old male IAD subject; (b) a 20-year-old male healthy control). Left hemisphere is on right side of image. The IAD subject demonstrates a significant decrease in binding of ^{99m}Tc -TRODAT-1 to the DAT in the striatum and the bilateral corpus striatum is much smaller and more irregular than that in the control.

corpus striatum/the whole brain (Ra) was calculated using the mathematical models as described in the previous paper [21, 31].

2.5. Data Analysis. Data in the present paper are presented as means \pm standard (mean \pm SD). Statistical Program for the Social Sciences for Windows, version 11 (SPSS 13.0, SPSS Inc, Chicago, USA) was used to analyze the data. Differences between the groups were assessed by Student's *t*-test. For all of the tests conducted, the criterion for significance was set at $P < 0.05$.

3. Results

The DAT images of the bilateral corpus striatum in the control group showed a panda-eye shape and DATs were distributed uniformly and symmetrically in the corpus striatum. The bilateral corpus striatum was situated on 8–12 layers, as shown in Figure 1(b). However, the DAT images of the IAD subjects displayed different levels of abnormality, in which the corpus stratums were much smaller and showed different shapes, dumbbell, thin strip, lunate shape, or sporadic spot (Figure 1(a)).

As shown in Figure 1 and Table 1, DAT expression level of striatum was significantly decreased in IAD subjects. Briefly, in comparison with the controls, there were significantly lower values of V (cm^3), W (g) and Ra of corpus striatum in the IAD group, suggesting that decreased ^{99m}Tc -TRODAT-1 bound to DAT or impairment as well as dysfunction of corpus striatum occurred. No statistical difference was found as comparing V or W of the bilateral corpus striatum (left side and right side) either in the IAD group ($P = 0.67$ and $P = 0.68$ resp.) or in the health control group ($P = 0.10$ and $P = 0.11$ resp.).

4. Discussion

IAD resulted in impaired individual psychological well-being, academic failure, and reduced work performance, especially among adolescents [1–4]. However, there is currently no standardized treatment targeted for IAD. To develop effective methods for intervention and treatment of IAD, it will first require establishing a clear understanding of the underlying neurobiological mechanisms. In the present study, we assessed the DAT expression level in IAD subjects and healthy controls using ^{99m}Tc -TRODAT-1 SPECT. We found that DAT expression level of striatum was significantly

TABLE 1: Comparison of corpus striatum V (cm^3), W (g), and Ra between IAD subjects and the controls.

| | Volume of corpus striatum V (cm^3) | | Weight of corpus striatum W (g) | | Ratio of corpus striatum/whole brain |
|--------------------------|---|-----------------------|-----------------------------------|-----------------------|--------------------------------------|
| | VL (left side) | VR (right side) | WL (left side) | WR (right side) | Ra (%) |
| Controls ($n = 9$) | 16.69 ± 1.63 | 18.17 ± 2.00 | 17.53 ± 1.71 | 19.08 ± 2.10 | 7.93 ± 0.75 |
| IAD subjects ($n = 5$) | $11.72 \pm 3.13^*$ | $12.51 \pm 2.53^{**}$ | $12.30 \pm 3.28^*$ | $13.14 \pm 2.10^{**}$ | $5.38 \pm 0.77^{**}$ |

Values are expressed as mean \pm SD with $*P < 0.05$ and $**P < 0.01$.

decreased and the values of V , W , and Ra of the corpus striatum in IAD subjects were greatly reduced. The imaging results provided the direct-viewing proof of altered availability of DAT in brain of people with IAD.

DATs play a critical role in the regulation of striatal synaptic dopamine levels [16–18] and have been used as markers of the dopamine terminals [32]. A reduced number of cell membrane DATs may possibly reflect pronounced striatal dopamine terminal loss or the brain dopaminergic function impairment which has been found in substance-related addiction [21–23]. PET imaging studies have found increased release of dopamine in the striatum during the video game [33]. Patients with pathological gambling also demonstrated high level of dopamine in the ventral striatum during gambling [34]. Because increased extracellular dopamine in the striatum is associated with subjective descriptors of reward (high, euphoria) [11, 35], individuals with IAD may also experience euphoria as the extracellular dopamine in the striatum increases. However, long-time and high concentrations of dopamine have been shown to cause a selective lesion of dopamine terminals [32, 36] and decreased size of dopaminergic cell bodies [20]. Taken together, the reduced DATs found in our study may indicate the neuropathologic damage to the dopaminergic neural system caused by IAD.

According to our knowledge, this is the first imaging study to examine the abnormality of DAT in the brain of IAD subjects. Furthermore, the imaging results of the present study provide the objective proofs that long-term maladaptive use internet might cause serious problems. However, for complete interpretation of the results of the present study, some limitations should be noted. Firstly, the small sample size of our study may limit the generalizability of our results. Those positive associations in our study might have been due to chance or a stratification effect in the sample collection, and further studies in independent samples or a larger population are required. Secondly, the IAD subjects in the present study reported different desired activities when they are sitting in front of the monitor (including chatting with cyber friends, playing online games, watching online pornographies or adult movies, etc.). Our study can not determine whether the different types of Internet behaviors may cause different brain DAT changes. Therefore, the present study can only be recognized as exploratory and primary, and more research work should be done before we get the most definitive conclusion.

5. Conclusion

The results from this study provide evidence that IAD may induce significant DAT losses in the brain and these findings suggest that IAD is associated with dysfunctions in the dopaminergic brain systems and are consistent with previous reports in various types of addictions either with or without substances [21–23, 37]. Our findings support the claim that IAD may share similar neurobiological abnormalities with other addictive disorders [15].

Author's contribution

H. Hou and S. Jia are contributed equally to this work.

Acknowledgments

This work is partly sponsored by Grants from the Zhejiang Provincial Natural Science Foundation of China (Z2110230), Health Bureau of Zhejiang Province (2010ZA075, 2011ZDA013), National Science Foundation of China (NSFC) (no. 81101023, 81170306, 81173468), and Ministry of Science and Technology of China (2011CB504400, 2012BAI13B06).

References

- [1] C. H. Ko, J. Y. Yen, S. H. Chen, M. J. Yang, H. C. Lin, and C. F. Yen, "Proposed diagnostic criteria and the screening and diagnosing tool of Internet addiction in college students," *Comprehensive Psychiatry*, vol. 50, no. 4, pp. 378–384, 2009.
- [2] C. Flisher, "Getting plugged in: an overview of Internet addiction," *Journal of Paediatrics and Child Health*, vol. 46, no. 10, pp. 557–559, 2010.
- [3] M. A. Moreno, L. Jelenchick, E. Cox, H. Young, and D. A. Christakis, "Problematic internet use among US youth: a systematic review," *Archives of Pediatrics and Adolescent Medicine*, vol. 165, no. 9, pp. 797–805, 2011.
- [4] K. S. Young, "Internet addiction: the emergence of a new clinical disorder," *Cyberpsychology and Behavior*, vol. 1, no. 3, pp. 237–244, 1998.
- [5] S. Byun, C. Ruffini, J. E. Mills et al., "Internet addiction: meta-synthesis of 1996–2006 quantitative research," *Cyberpsychology and Behavior*, vol. 12, no. 2, pp. 203–207, 2009.
- [6] K. W. Beard, "Internet addiction: a review of current assessment techniques and potential assessment questions," *Cyberpsychology and Behavior*, vol. 8, no. 1, pp. 7–14, 2005.

- [7] J. J. Block, "Issues for DSM-V: internet addiction," *American Journal of Psychiatry*, vol. 165, no. 3, pp. 306–307, 2008.
- [8] E. Aboujaoude, L. M. Koran, N. Gamel, M. D. Large, and R. T. Serpe, "Potential markers for problematic internet use: a telephone survey of 2,513 adults," *CNS Spectrums*, vol. 11, no. 10, pp. 750–755, 2006.
- [9] N. A. Shapira, T. D. Goldsmith, P. E. Keck, U. M. Khosla, and S. L. McElroy, "Psychiatric features of individuals with problematic internet use," *Journal of Affective Disorders*, vol. 57, no. 1–3, pp. 267–272, 2000.
- [10] D. L. Sun, Z. J. Chen, N. Ma, X. C. Zhang, X. M. Fu, and D. R. Zhang, "Decision-making and prepotent response inhibition functions in excessive internet users," *CNS spectrums*, vol. 14, no. 2, pp. 75–81, 2009.
- [11] N. D. Volkow, J. S. Fowler, G. J. Wang, R. Baler, and F. Telang, "Imaging dopamine's role in drug abuse and addiction," *Neuropharmacology*, vol. 56, no. 1, pp. 3–8, 2009.
- [12] H. S. Park, S. H. Kim, S. A. Bang, E. J. Yoon, S. S. Cho, and S. E. Kim, "Altered regional cerebral glucose metabolism in internet game overusers: a 18F-fluorodeoxyglucose positron emission tomography study," *CNS Spectrums*, vol. 15, no. 3, pp. 159–166, 2010.
- [13] S. H. Kim, S.-H. Baik, C. S. Park, S. J. Kim, S. W. Choi, and S. E. Kim, "Reduced striatal dopamine D2 receptors in people with Internet addiction," *NeuroReport*, vol. 22, no. 8, pp. 407–411, 2011.
- [14] D. H. Han, Y. S. Lee, K. C. Yang, E. Y. Kim, I. K. Lyoo, and P. F. Renshaw, "Dopamine genes and reward dependence in adolescents with excessive internet video game play," *Journal of Addiction Medicine*, vol. 1, no. 3, pp. 133–138, 2007.
- [15] M. N. Potenza, "Should addictive disorders include non-substance-related conditions?" *Addiction*, vol. 101, no. 1, pp. 142–151, 2006.
- [16] W. Schultz, "Predictive reward signal of dopamine neurons," *Journal of Neurophysiology*, vol. 80, no. 1, pp. 1–27, 1998.
- [17] T. Dohi, S. Kitayama, K. Kumagai, W. Hashimoto, and K. Morita, "Pharmacology of monoamine neurotransmitter transporters," *Folia Pharmacologica Japonica*, vol. 120, no. 5, pp. 315–326, 2002.
- [18] J. C. Dreher, P. Kohn, B. Kolachana, D. R. Weinberger, and K. F. Berman, "Variation in dopamine genes influences responsivity of the human reward system," *Proceedings of the National Academy of Sciences of the United States of America*, vol. 106, no. 2, pp. 617–622, 2009.
- [19] R. Simantov, "Chronic morphine alters dopamine transporter density in the rat brain: possible role in the mechanism of drug addiction," *Neuroscience Letters*, vol. 163, no. 2, pp. 121–124, 1993.
- [20] S. J. Kish, K. S. Kalasinsky, P. Derkach et al., "Striatal dopaminergic and serotonergic markers in human heroin users," *Neuropsychopharmacology*, vol. 24, no. 5, pp. 561–567, 2001.
- [21] S. W. Jia, W. Wang, Y. Liu, and Z. M. Wu, "Neuroimaging studies of brain corpus striatum changes among heroin-dependent patients treated with herbal medicine, U^{finer} capsule," *Addiction Biology*, vol. 10, no. 3, pp. 293–297, 2005.
- [22] J. Shi, L. Y. Zhao, M. L. Copersino et al., "PET imaging of dopamine transporter and drug craving during methadone maintenance treatment and after prolonged abstinence in heroin users," *European Journal of Pharmacology*, vol. 579, no. 1–3, pp. 160–166, 2008.
- [23] H. Hou, S. Yin, S. Jia et al., "Decreased striatal dopamine transporters in codeine-containing cough syrup abusers," *Drug and Alcohol Dependence*, vol. 118, no. 2–3, pp. 148–151, 2011.
- [24] P. Crits-Christoph, A. Newberg, N. Wintering et al., "Dopamine transporter levels in cocaine dependent subjects," *Drug and Alcohol Dependence*, vol. 98, no. 1–2, pp. 70–76, 2008.
- [25] H. F. Kung, H. J. Kim, M. P. Kung, S. K. Meegalla, K. Plössl, and H. K. Lee, "Imaging of dopamine transporters in humans with technetium-99m TRODAT-1," *European Journal of Nuclear Medicine*, vol. 23, no. 11, pp. 1527–1530, 1996.
- [26] M. P. Kung, D. A. Stevenson, K. Plössl et al., "[^{99m}Tc]TRODAT-1: a novel technetium-99m complex as a dopamine transporter imaging agent," *European Journal of Nuclear Medicine*, vol. 24, no. 4, pp. 372–380, 1997.
- [27] I. Goldberg, "Internet Addictive Disorder (IAD) Diagnostic Criteria," 1996, <http://www.psychom.net/iadcriteria.html>.
- [28] American-Psychiatric-Association, *Diagnostic and Statistical Manual of Mental Disorders*, American Psychiatric Press, Washington DC, USA, 4th edition, 1994.
- [29] P. Danos, S. Kasper, F. Grünwald et al., "Pathological regional cerebral blood flow in opiate-dependent patients during withdrawal: a HMPAO-SPECT study," *Neuropsychobiology*, vol. 37, no. 4, pp. 194–199, 1998.
- [30] L. T. Chang, "A method for attenuation correction in radionuclide computed tomography," *IEEE Transactions on Nuclear Science*, vol. 25, no. 1, pp. 638–643, 1977.
- [31] S. W. Jia, Z. M. Wu, H. E. Luo et al., "The value of dopamine transporter [^{99m}Tc] TRODAT-1 imaging for evaluating the therapeutic effects of Junfukang capsule on prevention and cure of drug addiction recurrence," *Chinese Journal of Nuclear Medicine*, vol. 24, no. 3, pp. 155–157, 2004.
- [32] N. D. Volkow, L. Chang, G. J. Wang et al., "Loss of dopamine transporters in methamphetamine abusers recovers with protracted abstinence," *Journal of Neuroscience*, vol. 21, no. 23, pp. 9414–9418, 2001.
- [33] M. J. Koeppe, R. N. Gunn, A. D. Lawrence et al., "Evidence for striatal dopamine release during a video game," *Nature*, vol. 393, no. 6682, pp. 266–268, 1998.
- [34] T. D. L. Steeves, J. Miyasaki, M. Zurowski et al., "Increased striatal dopamine release in Parkinsonian patients with pathological gambling: a [11C] raclopride PET study," *Brain*, vol. 132, no. 5, pp. 1376–1385, 2009.
- [35] W. C. Drevets, C. Gautier, J. C. Price et al., "Amphetamine-induced dopamine release in human ventral striatum correlates with euphoria," *Biological Psychiatry*, vol. 49, no. 2, pp. 81–96, 2001.
- [36] M. J. LaVoie and T. G. Hastings, "Dopamine quinone formation and protein modification associated with the striatal neurotoxicity of methamphetamine: evidence against a role for extracellular dopamine," *Journal of Neuroscience*, vol. 19, no. 4, pp. 1484–1491, 1999.
- [37] R. Cilia, J. H. Ko, S. S. Cho et al., "Reduced dopamine transporter density in the ventral striatum of patients with Parkinson's disease and pathological gambling," *Neurobiology of Disease*, vol. 39, no. 1, pp. 98–104, 2010.