

# *Rickettsia helvetica* in Patient with Meningitis, Sweden, 2006

Kenneth Nilsson, Karin Elfving, and Carl Pålsson

Pathogenicity of *Rickettsia helvetica* is relatively unknown. We isolated a spotted fever group rickettsial organism from a patient with subacute meningitis. Nucleotide sequences of the 16S rRNA, *ompB*, and 17kDa genes identified the isolate as *R. helvetica*. This organism may be associated with serious infections such as central nervous system disorders.

*Rickettsia helvetica*, a member of the spotted fever group Rickettsiae (SFGR), has been isolated from *Ixodes ricinus* ticks in many European and Asian countries. Although *I. ricinus* ticks are the main vector and natural reservoir, the organism has recently been found in *Dermacentor reticulatus* ticks (1–5). Serosurveys have found antibodies reactive to *R. helvetica* in 1.9%–12.5% of the population in Lao People's Democratic Republic, France, Italy, Denmark, and Sweden (1,4,6–8). The organism has mainly been considered nonpathogenic; several patients with a serologic diagnosis have had mild, self-limited disease with associated fever, headache, and myalgia. However, a more severe clinical disease has been demonstrated (1,9).

It is well known that Q fever and the rickettsial diseases typhus and spotted fever may cause central nervous system infection and that, of the SFGR, *R. rickettsii*, *R. conorii*, and *R. japonica* have a documented association with meningitis (10,11). We document a case of subacute meningitis caused by *R. helvetica*. The study was reviewed and approved by the Ethics Committee, Uppsala University, Sweden.

## The Case

In September 2006, a 56-year-old woman was hospitalized in Falun, Sweden, after 3 weeks of illness with gradually worsening headache and fever. She had no lymphadenopathy, rash, eschar, or history of tick bite or tick exposure. Radiographs showed a small, retrocardial pulmonary infiltrate, but the patient had few, if any, respiratory symptoms.

Author affiliations: Uppsala University Hospital, Uppsala, Sweden (K. Nilsson, K. Elfving,); Mälardalens University, Eskilstuna, Sweden (C. Pålsson); Center of Clinical Research Dalarna, Falun, Sweden (K. Nilsson); and Falu Hospital, Falun (K. Nilsson, K. Elfving)

DOI: 10.3201/eid1603.090184

Laboratory tests showed elevated C-reactive protein (56–128 mg/L), slightly elevated to reference-level leukocyte count (9,800–12,000 cells/ $\mu$ L), slightly low thrombocyte count (150,000 cells/ $\mu$ L), and reference values of hemoglobin and of aspartate and alanine aminotransferases. Cerebrospinal fluid (CSF) showed a slight pleocytosis (28 cells  $\times$  10<sup>8</sup>/L, of which 18  $\times$  10<sup>8</sup>/L were mononuclear cells) but was otherwise within reference limits. CSF was stored at –20°C in a regular freezer and thawed only when used 1 year later. Negative results were obtained for blood and CSF cultures and for investigation for herpesviruses, tick-borne encephalitis, and enteroviruses. Urine was negative for *Legionella* and pneumococcal antigens, and serum was negative for antibodies against *Borrelia burgdorferi*. Computed tomography images of the brain and sinuses were unremarkable.

Intravenous administration of cefuroxime had no effect on the fever. Because atypical pneumonia was suspected, treatment was changed after 3 days to doxycycline (100 mg 2 $\times$ /day). After 2–3 days the patient's fever was gone, and she slowly recovered. The treatment was continued for 10 days. At a follow-up visit 1 year later, the patient was still well but had been asthenic for several months. No antibodies against *Mycoplasma pneumoniae* or *Coxiella burnetii* were found at the follow-up visit, and no other possible causative agent was confirmed. After giving informed consent, the patient was retrospectively included in an ongoing project that involved searching for fastidious organisms.

The patient's previously frozen CSF was divided into 2 aliquots; bacterial DNA was extracted by using a MagNa Pure Kit (Roche Diagnostics GmbH, Mannheim, Germany) according to the manufacturer's instructions. A genus-specific real-time PCR, as described by Stenos et al. (12), was used to detect SFGR. The PCR was performed in a Lightcycler 1.0 Real-Time PCR System (Roche Diagnostics GmbH) by using an LC Taqman Master Kit (Roche Diagnostics GmbH), primers, and TaqMan probe targeting the citrate synthase gene (12). To minimize risk for contamination, 0.25  $\mu$ L LC uracil-DNA glycosylase (Roche Diagnostics GmbH) was included in each reaction. The positive control contained purified DNA of *R. helvetica* originally isolated from a domestic *I. ricinus* tick (3); the negative control contained sterile water. Positive samples were further analyzed by using 3 nested PCRs that amplify the 17kDa, outer membrane protein B (*ompB*), and 16S rRNA gene fragments as previously described (3,13,14) (Table). Amplification was conducted in a DNA thermal cycler (Hybaid, Ashford, UK) and a MJ Mini Gradient Thermal Cycler (Bio-Rad, Hercules, CA, USA), and expected fragment sizes were confirmed by gel electrophoresis in 2% agarose. Direct cycle sequencing analysis of both strands of nested PCR products was performed at the Center for Genomics and Bioinformatics, Karolinska Institutet, Stockholm, Sweden.

Rickettsial DNA was amplified by real-time PCR from both CSF aliquots. Positive samples were further examined by using nested PCRs. The sequences obtained were 165 (17 kDa) and 253 bp (*ompB*) and shared 100% similarity with the corresponding gene sequences of *R. helvetica* (GenBank accession nos. EU407139, EU407140).

To isolate the pathogen, we injected CSF from the frozen aliquot in volumes of 10 µL in a 25-cm<sup>3</sup> flask into confluent monolayers of Vero cells and 80 µL in the other (15). After incubation, the cell culture was maintained in Dulbecco modified Eagle medium containing 10% fetal calf serum and kept in a humid cell chamber in 5% CO<sub>2</sub>, at 32°C, to allow rickettsiae to multiply. All cell lines and reagents were checked weekly for growth or bacterial contamination. Detection of growing rickettsiae was monitored by using Gimenez staining and an immunofluorescence assay of cells collected after centrifuging the medium and staining with rabbit antirickettsial hyperimmuniserum and Alexa Fluor 488 goat antirabbit immunoglobulin (Ig) G (H+L) conjugate (Invitrogen, Carlsbad, CA, USA) as secondary antibody (Figure).

After 6 weeks, many intracellular bacteria were observed in the cells. Rickettsial DNA was verified by real-time PCR (12). The sequences obtained by nested PCR for the 17kDa and *ompB* genes in the isolate grown in Vero cells were identical to the sequences of the isolates obtained from the CSF (3,13,14). Amplification and partial sequencing of the 16S ribosomal RNA gene of the isolate produced fragments of 1,400 and 750 bp, respectively, which were 100% homologous to fragments of the deposited 16S ribosomal DNA sequence of *R. helvetica* from ticks (GenBank accession no. L36212).

SFGR antigen prepared from isolates grown in Vero cells of *R. helvetica* from an *I. ricinus* tick and from the patient was applied to each well of microscope slides. The antigen was dried, fixed in acetone, and incubated with serial dilutions of serum or CSF, as previously described (7). The positive control was serum from a patient with proven Mediterranean spotted fever and end-point IgG titers of 160 (provided by the Swedish Institute for Infectious Disease Control); the negative control was phosphate-buffered

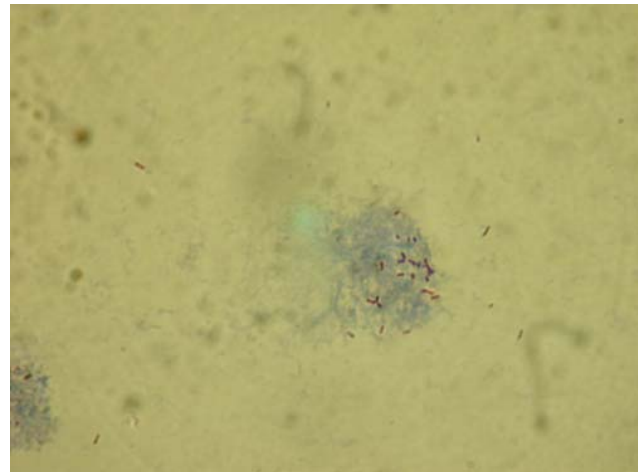


Figure. Rickettsiae in infected Vero cells. Sample from cerebrospinal fluid of patient with subacute meningitis, Sweden, 2006. Gimenez stain; original magnification ×1,000.

saline and serum from 3 healthy blood donors. IgG was detected by fluorescein isothiocyanate-conjugated γ-chain-specific polyclonal rabbit antihuman IgG (DakoCytomation A/S, Glostrup, Denmark). Microimmunofluorescence assay showed IgG end titers of 160 and 320 in the early-phase serum sample when the isolates of *R. helvetica* from tick and patient, respectively, were used as antigens. No antirickettsial IgG was detected in CSF when either isolate was used as antigen.

### Conclusions

For patients with fever and headache but no rash or eschar, diagnosis is difficult and can probably not be based only on epidemiologic, clinical, and standard laboratory criteria. It therefore seems that in SFGR-endemic areas, SFGR should routinely be included in the differential diagnosis of cause of meningitis. Appropriate antimicrobial drug therapy is essential for prompt recovery and prevention of complications.

SFGR isolation is usually not available in ordinary hospital laboratories and is too time-consuming to be a di-

Table. Selected inner primers and probe used to amplify genes from cerebrospinal fluid of patient with subacute meningitis, Sweden, 2006\*

Gene	Primers and probe	Nucleotide sequences, 5' → 3'	Product size, bp
<i>ompB</i>	<i>ompB</i> -IF	CCAATGGCAGGACTTAGCTACT	267
	<i>ompB</i> -IR	AGGCTGGCTGATACACGGAGTAA	
17 kDa	RH 17-IF	GCATTACTTGGTTCTCAATTGG	214
	RH 17-IR	AACCGTAATTGCCGTTATCCGG	
16SrDNA	Ric-F	TCTAGAACGAACGCTATCGGTAT	757
	Ric-R	TTTCATCGTTTAACGGCGTGGACT	
<i>gltA</i>	SFG-CS-F	TGCCAAATGTTACGGTACTTT	74
	SFG-CS-R	CACAATGGAAAGAAATGCACGA	
	SFG-CS-Probe	TGCAATAGCAAGAACCGTAGGCTGGATG	

\**ompB*, outer membrane protein B; *gltA*, citrate synthase.

agnostic alternative in clinical settings. Although this patient's CSF had been stored in a regular freezer for 1 year, the rickettsial organisms were still viable.

PCR seems to be the most practical way to diagnose a suspected central nervous system disorder such as meningitis. The amplified nucleotide sequences were long enough to exclude other related rickettsial species. For example, the differences from other related rickettsiae were 10 and 5 nt for the *R. monacensis* 17kDa and *ompB* gene fragments, respectively, and 8 nt for *R. slovaca ompB*. Our study suggests that *R. helvetica* may cause infection of the CNS. When seeking to diagnose possible agents of meningitis, the usefulness of PCR and the relevance of the broader clinical spectrum of acute febrile illness caused by *R. helvetica* should be considered.

The study was supported in part by grants from the Center of Clinical Research Dalarna (project no. 9028).

Dr Nilsson is a physician who works in infectious disease medicine and clinical microbiology at Uppsala University Hospital. His research interests include the clinical, diagnostic, and epidemiologic features of rickettsioses.

## References

1. Fournier PE, Grunnenberger F, Jaulhac B, Gastinger G, Raoult D. Evidence of *Rickettsia helvetica* infection in humans, eastern France. *Emerg Infect Dis.* 2000;6:389–92. DOI: 10.3201/eid0604.000412
2. Fournier PE, Fujita H, Takada N, Raoult D. Genetic identification of rickettsiae isolated from ticks in Japan. *J Clin Microbiol.* 2002;40:2176–81. DOI: 10.1128/JCM.40.6.2176-2181.2002
3. Nilsson K, Jaenson TG, Uhnöo I, Lindquist O, Pettersson B, Uhlén M, et al. Characterization of a spotted fever group *Rickettsia* from *Ixodes ricinus* ticks in Sweden. *J Clin Microbiol.* 1997;35:243–7.
4. Parola P, Raoult D. Ticks and tickborne bacterial diseases in humans: an emerging infectious threat. *Clin Infect Dis.* 2001;32:897–928. DOI: 10.1086/319347
5. Dobeč M, Golubic D, Punda-Polic V, Kaeppli F, Sievers F. *Rickettsia helvetica* in *Dermacentor reticulatus* ticks. *Emerg Infect Dis.* 2009;15:98–100. DOI: 10.3201/eid1501.080815
6. Phongmany S, Rolain JC, Phetsouvanh R, Blacksell S, Soukhaseum V, Rosachack B, et al. Rickettsial infections and fever, Vientiane, Laos. *Emerg Infect Dis.* 2006;12:256–8.
7. Elfving K, Lindblom A, Nilsson K. Seroprevalence of *Rickettsia* spp. infection among tick-bitten patients and blood donors in Sweden. *Scand J Infect Dis.* 2008;40:74–7. DOI: 10.1080/00365540701509907
8. Nielsen H, Fournier PE, Pedersen IS, Krarup H, Ejlersten T, Raoult D. Serological and molecular evidence of *Rickettsia helvetica* in Denmark. *Scand J Infect Dis.* 2004;36:559–63. DOI: 10.1080/00365540410020776
9. Nilsson K. Septicaemia with *Rickettsia helvetica* in a patient with acute febrile illness, rash and myasthenia. *J Infect.* 2009;58:79–82. Epub 2008 Jul 22. DOI: 10.1016/j.jinf.2008.06.005
10. Araki M, Takatsuka K, Kawamura J, Kanno Y. Japanese spotted fever Involving the central nervous system: two case reports and a literature review. *J Clin Microbiol.* 2002;40:3874–6. DOI: 10.1128/JCM.40.10.3874-3876.2002
11. Günther G, Haglund M. Tick-borne encephalopathies: epidemiology, diagnosis, treatment and prevention [review]. *CNS Drugs.* 2005;19:1009–32.
12. Stenos J, Graves S, Unsworth N. A highly sensitive and specific real-time PCR assay for the detection of spotted fever and typhus group rickettsiae. *Am J Trop Med Hyg.* 2005;73:1083–5.
13. Choi YJ, Lee SH, Park KH, Koh YS, Lee KH, Baik HS, et al. Evaluation of PCR-based assay for diagnosis of spotted fever group rickettsiosis in human serum samples. *Clin Diagn Lab Immunol.* 2005;12:759–63.
14. Leitner M, Yitzhaki S, Rzotkiewicz S, Keysari A. Polymerase chain reaction-based diagnosis of Mediterranean spotted fever in serum and tissue samples. *Am J Trop Med Hyg.* 2002;67:166–9.
15. La Scola B, Raoult D. Diagnosis of Mediterranean spotted fever by cultivation of *Rickettsia conorii* from blood and skin samples using the centrifugation shell-vial technique and by detection of *Rickettsia conorii* in circulating endothelial cells, a 6 year follow-up. *J Clin Microbiol.* 1996;34:2722–7.

Address for correspondence: Kenneth Nilsson, Department of Clinical Microbiology, Uppsala University Hospital, SE-751 85 Uppsala, Sweden; email: kenneth.nilsson@medsci.uu.se

# Like our podcasts?

Sign up to receive email announcements  
when a new podcast is available.

[www.cdc.gov/ncidod/eid/subscrib.htm](http://www.cdc.gov/ncidod/eid/subscrib.htm)

