

Renomedullary Antihypertensive Function in Accelerated (Malignant) Hypertension

OBSERVATIONS ON RENOMEDULLARY INTERSTITIAL CELLS

E. E. MUIRHEAD, B. BROOKS, J. A. PITCOCK, and P. STEPHENSON

*From the Departments of Pathology and Medicine, University of Tennessee
Medical Units, Memphis, Tennessee 38103*

ABSTRACT The antihypertensive function of the renal medulla was tested on accelerated (malignant) hypertension of the rabbit. A procedure for the development of accelerated hypertension of the rabbit of lethal proportions within 3 wk was established. This procedure consisted of the application of a rigid clip with a fixed and unyielding gap to the left renal artery and removal of the right kidney. Three additional manipulations, other than simple nephrectomy, were performed on the right kidney after application of the rigid clip to the left renal artery. These were: (a) a sham operation, (b) removal of the kidney and separation of the renal cortex and its autotransplantation in a fragmented state, and (c) removal of the kidney and separation of the renal medulla and its autotransplantation in a fragmented state. After the sham-operated kidney and autotransplanted renal medulla, the standardized accelerated hypertension did not develop, whereas after autotransplanted renal cortex it did. After a period of protection against accelerated hypertension, removal of either the sham-operated kidney or the renomedullary transplants was followed by a prompt rise in arterial pressure and death of the animal. Thus, the antihypertensive action of renomedullary tissue was similar to that of the whole kidney. The main cell type noted in the protective renomedullary transplants had the microscopic characteristics of the lipid-containing interstitial cells. These cells occurred

in clusters, often were near capillaries, and appeared hyperplastic. It is suggested that the renomedullary interstitial cell is the most eligible cell for exertion of the renomedullary antihypertensive action. Since vasoactive lipids are extractable from the renal medulla and its interstitial cells, the hypothesis that interstitial cells secrete antihypertensive substance(s) is attractive.

INTRODUCTION

An antihypertensive function of the normal kidney was proposed in relation to the Goldblatt experiment (1-5). During the past 15 years, results after renal transplantation (6-10) and renal perfusion (11-14) suggest a renal antihypertensive function by indicating a corrective influence of the normal donor kidney on the hypertensive state. On occasions, this corrective effect has occurred rapidly, suggesting a nonexcretory antihypertensive function.

The renal medulla appears to contribute to the renal antihypertensive function through a nonexcretory action as indicated by results with three experimental models (15-21). As a consequence of these observations, antihypertensive and vasoactive lipids were extracted from renomedullary tissue (22-26) and certain of these depressor lipids were demonstrated to belong to the prostaglandin family of compounds, namely, prostaglandins E₂ and A₂ (27-30).

The extraction of antihypertensive and vasoactive lipids from the renal medulla led Muehrcke and associates (31, 32) to evaluate the lipid-containing renomedullary interstitial cells in hypertensive states. These workers noted a significant reduction of the lipid granules of these cells in desoxycorticosterone (DOCA)-salt hypertension of the rat and malignant hypertension of

This work was presented in part at the Meeting of the American Physiological Society, Atlantic City, N. J., 14 April 1970, and the Southern Society of Clinical Investigation, New Orleans, La., 30 January 1971. This study appeared in abstract form, *Fed. Proc.* 1970. 29: 447, and *Clin. Res.* 1971. 19: 65.

Received for publication 26 April 1971 and in revised form 4 August 1971.

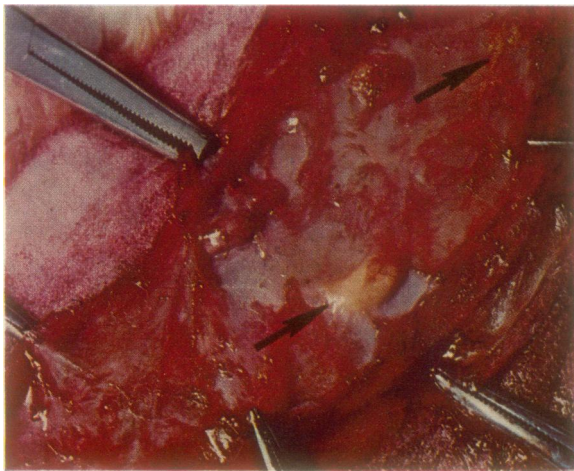


FIGURE 1 The tracts and nodules of autotransplanted renal medulla from the right kidney are shown *in situ* within the subcutaneous tissue before their surgical removal (rabbit of panel A, Fig. 4). Note the highly vascular surface (a vessel is seen along the long axis of the tract at upper arrow). The nodule in the center (lower arrow) had its vascular surroundings peeled off to display the yellow color. Other nodules of renomedullary transplants are present to the left of the one singled out by the arrow.

man. Tobian and associates (33) and Ishii and Tobian (34) observed a lowered interstitial cell granule count in salt-loading and Goldblatt hypertension of the rat. While these studies were in progress, Nissen and Andersen (35) demonstrated the presence of the prostaglandin precursor, arachidonic acid, within the renomedullary interstitial cells and Nissen and Bojesen (36) and Bohman and Maunsbach (37) isolated the interstitial cell vesicles and demonstrated the presence of vasodepressor lipid and apparently prostaglandin within them.

It is the purpose of this presentation to relate the prevention of accelerated (malignant) hypertension of the rabbit by autotransplanted renal medulla and to indicate support for the renomedullary interstitial cell as the main candidate for the performance of this anti-hypertensive action.

METHODS

The experimental model. The model used in these experiments was based on a precise production of accelerated (malignant) hypertension of the white rabbit. This was accomplished by the application to the left renal artery of a rigid silver clip having a fixed gap of 0.5 mm and the removal of the right kidney. The manufacture of this clip and the operative procedures used in its placement are described in detail elsewhere (38).

The mean arterial pressure was measured directly from the lower abdominal aorta by means of an indwelling polyethylene catheter brought out through the abdominal wall and beneath the skin to the back of the neck. The catheter

tip was placed between the aortic bifurcation and the renal arteries.

The aortic catheter was filled with physiologic saline and plugged with a metal obturator. Each day it was determined patent by the sudden injection of 0.5 ml of saline by means of a tuberculin-type plastic syringe. After this maneuver, free flow of blood was demonstrated by the back and forth movement of the plunger of the syringe. The actual pressure was derived through a Statham P23Dc transducer (Statham Instruments, Inc, Oxnard, Calif.) by either of two approaches. In one, the transducer was connected to a Grass polygraph (Grass Instrument Co, Quincy, Mass.) and while the animal remained quiet in a specially designed rabbit box, a free pulse wave was ascertained for 1 min, the mean pressure was determined for 1 min, and the free pulse wave was redetermined for an additional 1 min. In the second approach the rabbit was placed in the box and the aortic catheter and transducer were connected to a Grass continuous recording device. The rabbit's arterial pressure was recorded automatically for 5 min every hour for 3-4 hr. A 100 mm Hg standard recording was interjected periodically to check for voltage drift. The entire assembly, before use, was sterilized with 70% ethanol. Periodic blood cultures (Difco Thiol media, Difco Labs, Detroit, Mich.) of the rabbit indicated no bacteremia induced by the blood pressure measuring maneuvers. Both approaches, the manual and the automatic, gave rise to similar results.

For all experiments, male white rabbits, 14-16 wk old, weighing about 3 kg, were used. Under pentobarbital anesthesia and a transabdominal approach, the aortic catheter was inserted and brought to the surface and the left renal artery was isolated and constricted by the application of the rigid clip. Then the right kidney was either removed for the standard procedure or manipulated as described below for autotransplantation and sham operation. After each operative procedure, the animal was injected intramuscularly with 50,000 U of aqueous penicillin G each day for 3 days. The arterial pressure measurements were made approximately every 2 days. Body weight was determined periodically throughout the experiment.

After death or sacrifice during the terminal moribund state, tissue was obtained from the viscera and fixed in buffered formalin for light microscopy.

Autotransplantation of renal tissue. Under pentobarbital anesthesia, the aortic catheter was introduced and brought to the surface and the left renal artery was constricted with the narrow, rigid clip. Then the right kidney was removed and serially sectioned at 5 mm intervals with a razor blade. Either the entire medulla or an equivalent amount of outer cortex (2 g of tissue) was separated by sharp dissection. The separated medullary or cortical tissue was then minced into small fragments about 1 mm in size in a Petri dish with the razor blade. These fragments were placed in a 20 ml Waring Blendor containing 5 ml of 199 tissue culture media.¹ The blender was operated for 6 sec at low speed. The contents were poured into a 50 ml conical plastic centrifuge tube and spun off for 1 min at high speed. The supernatant was poured off and 5 ml of fresh 199 media were added. To this was added 0.02 ml of an antibiotic mixture containing 0.5 g of streptomycin, 400,000 U of penicillin, and 1000 U of bacitracin. After stirring, the fragments were injected either intraperitoneally or subcutaneously. Intraperitoneal injection was accomplished

¹ (10X) Media 199 without NaHCO₃. Available from Microbiological Associates, Inc., Bethesda, Md.

through the open abdominal wound. When injected subcutaneously, a 6 inch 17-gauge needle was used. The needle was inserted to the hilt along the subcutaneous tissue of the side of the abdomen up to the rib cage. It was slowly removed as the fragmented tissue was injected. At least four elongated tracts of tissue were made for each transplantation. Sterile operating room precautions were observed throughout. The entire procedure from nephrectomy to transplantation was completed in 15 min.

In four experiments wherein the fragmented medulla was injected as tracts subcutaneously, these tracts were removed surgically under pentobarbital anesthesia after 22–24 days in three animals and after 90 days in one animal. The pelt was shaved, the skin was prepared with Merthiolate, and a long incision was made opposite the tracts. The skin flaps were undermined and retracted. It was an easy matter to locate the medullary transplants and shell out each one (see Fig. 1). The skin incision was closed. The animals were followed subsequently by daily arterial pressure and body weight measurements. The recovered transplants were examined by light and electron microscopy. For light microscopy the tissues were sectioned at 5 μ and stained with hematoxylin and eosin, periodic-Schiff's reagent, Alcian blue, colloidal iron, oil red O, Sudan black B, and by the Shultz modification of the Liebermann-Burchardt method (39). For electron microscopy, the tissues were fixed in 3% glutaraldehyde in cocodylate buffer followed by treatment with osmium tetroxide and Epon embedding.

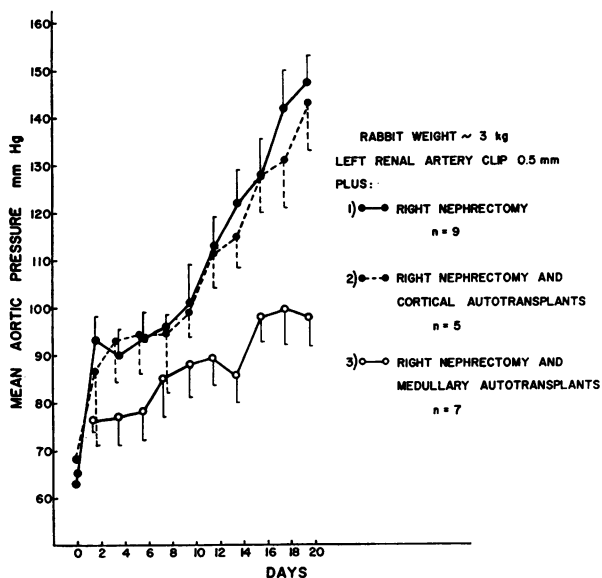


FIGURE 2 This figure depicts the mean value of the aortic blood pressure ± 1 SEM for three groups of animals. The animals of each group had the left renal artery constricted by the rigid clip. In addition, one group, indicated by 1), had a right nephrectomy; the second group, indicated by 2), had a right nephrectomy plus renocortical autotransplantation; and the third group, indicated by 3), had a right nephrectomy plus renomedullary autotransplantation. There was no difference in results between the first and second group while the third group had a significant blunting of arterial pressure. Thus, the renomedullary transplants protected against the accelerated (malignant) hypertension.

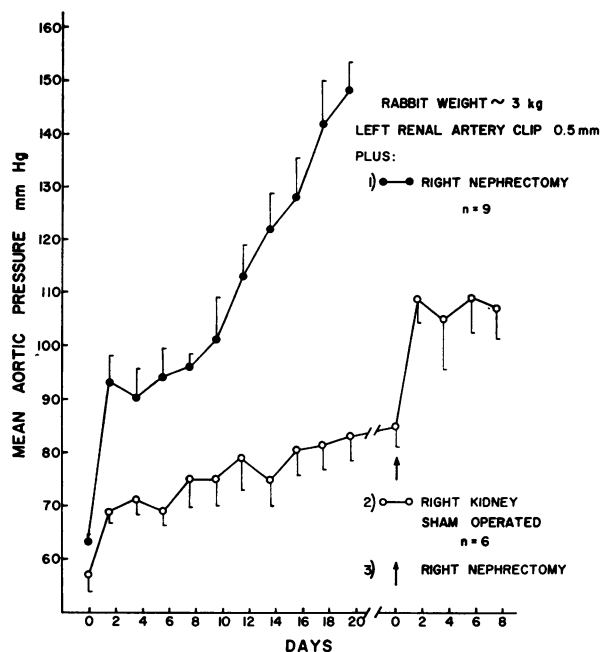


FIGURE 3 Results after application of the narrow clip to the left renal artery and sham operation of the right kidney are depicted for 20 days. There was a very modest elevation of the arterial pressure over a period of 20 days. After removal of the sham-operated kidney, the arterial pressure elevated sharply and the animals died within 1 wk. The results with the group having the same clip applied to the left renal artery and right nephrectomy are reproduced for comparison purposes. The values represent the mean and the SEM of the aortic blood pressure.

In addition, semithin sections (0.5 μ) were stained with toluidine blue.

Sham operation. In order to test the antihypertensive action of the normal kidney against the standardized accelerated (malignant) hypertension and to compare this action with those of the renomedullary and renocortical transplants, the right kidney was sham operated. Under pentobarbital anesthesia, the rigid narrow clip was applied to the left renal artery and the right kidney was freed to its pedicle, delivered, then replaced in its bed, and the peritoneum was sutured over it. The wound was closed and the animal was followed in the usual way.

In these six experiments, after 20–35 days, the sham-operated right kidney was removed and the animals were followed until demise.

Statistical analysis between groups was conducted by Student's *t* test.

RESULTS

The standardized, malignant hypertensive state (nine experiments, Fig. 2)

When the rigid clip was applied to the left renal artery and the right kidney was removed, the rise in arterial pressure was characteristic and reproducible. It entailed three phases. (a) In phase one, the mean

pressure rose from control levels of 60–70 mm Hg to 90–100 mm Hg over 2–5 days; (b) in phase two (plateau phase), the arterial pressure remained at 90–100 mm Hg until about days 10–12; (c) in phase three, the arterial pressure rose rapidly to lethal levels during the 3rd wk. Terminally, the animal collapsed and usually had seizures.

By light microscopy, the small arteries and arterioles of the viscera of all nine animals displayed fibrinoid necrosis. Thus, the designation of accelerated (malignant) hypertension was based on: (a) the rapid evolution of a severe hypertensive state as indicated by the rise of the mean arterial pressure to 140–160 mm Hg during the 3rd wk (the normal mean arterial pressure for this colony as determined by 54 measurements on five rabbits was found to be 63 mm Hg \pm 0.54 SE); (b) either a lethal state or an extreme moribund state at the time of sacrifice; and (c) the demonstration of fibrinoid necrosis of small arteries and arterioles of the viscera. The most outstanding degree of arteriolar disease was noted in the gastrointestinal tract. Often, multiple hemorrhages in the intestines were observed grossly.

Sham-operated right kidney (six experiments, Fig. 3)

When the rigid, narrow clip was applied to the left renal artery and the right kidney was sham-operated, the mean arterial pressure rose slightly over 20 days' time (average from 68 to 80 mm Hg). The differences between the arterial pressure of this group and the right nephrectomy group from the 13th to the 20th days were highly significant ($P < 0.001$). The body weight changes for this group and for the subsequent groups were the same. There was a slight lowering of weight during the 1st wk (from an average of 2.9–2.6 kg) and a return to the control weight by the end of the 2nd wk.

Sham-operated right kidney followed by its removal 20–35 days later (six experiments, Fig. 3)

Upon removal of the sham-operated right kidney which afforded protection against the accelerated (malignant) hypertension for 20 days in four experiments, 25 days in one and 35 days in another experiment, there was a sharp rise in arterial pressure and within

TABLE I
Mean Aortic Blood Pressure and Standard Error of the Mean
for 3rd Wk of Experiment

Group	n	Mean aortic pressure mm Hg \pm SEM P value vs. group I			
		Days			
		13–14	15–16	17–18	19–20
I Standard malignant hypertension	9	122 \pm 7	128 \pm 7	142 \pm 8	148 \pm 6
II Sham-operated right kidney	6	75 \pm 5 <0.001	81 \pm 5 <0.001	82 \pm 4.5 <0.001	83 \pm 4.5 <0.001
III Renocortical autotransplants	5	116 \pm 6.5 >0.05	128 \pm 6.5 >0.9	131 \pm 10 >0.4	143 \pm 10 >0.7
IV Renomedullary autotransplants	7	86 \pm 5.5 <0.005	98 \pm 5 <0.01	99 \pm 7 <0.005	98 \pm 6 <0.001

The mean aortic blood pressure and the standard error of the mean for the 3rd wk of the experiment are tabulated. In addition, the relationship of the values of the standard experiment (group I) to the other groups is analyzed statistically. Each group had the rigid, narrow clip applied to the left renal artery. In addition, group I had a right nephrectomy, Group II a sham operation of the right kidney, group III a right nephrectomy plus autotransplantation of the renal cortex and group IV a right nephrectomy plus autotransplantation of the renal medulla.

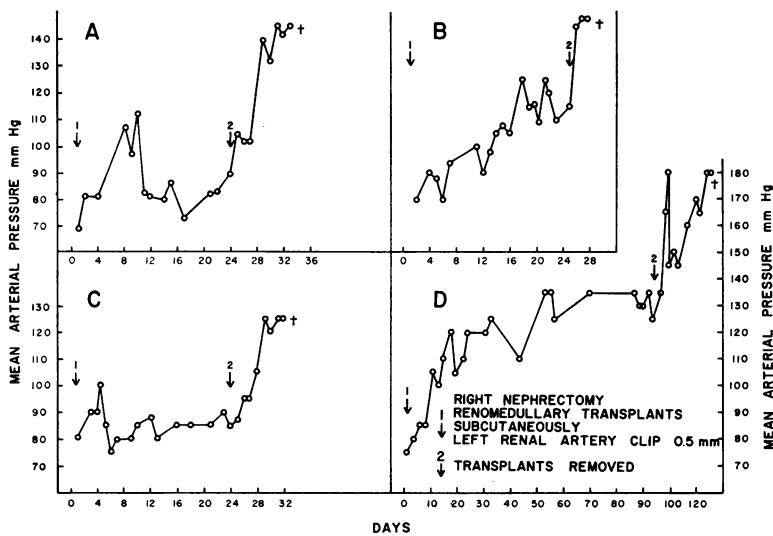


FIGURE 4 Each animal of these experiments had the left renal artery constricted by the narrow clip and the renal medulla of the right kidney fragmented and autotransplanted subcutaneously (arrow 1). Protection against the accelerated (malignant) hypertension was afforded for 22–24 days in three examples and for 90 days in one example. At these times, the renomedullary transplants were removed (arrow 2). In each case after ablation of the renomedullary transplants, the arterial pressure rose sharply over 3–21 days' time and the animal died.

1 wk the animal died. This experiment represents a modification of an earlier experiment by Pickering and Prinzmetal (4).

Autotransplantation of renal cortex (five experiments, Fig. 2)

The left renal artery was constricted by the narrow, rigid clip and the fragmented renal cortex (2 g) from the removed right kidney was autotransplanted intraperitoneally. There was no protection against the accelerated (malignant) hypertension. The three phases of progression of the hypertension were reproduced; namely, an early modest elevation, plateau, and late extreme elevation. The results were identical with those of the standardized experiment (see Table I).

Autotransplantation of renal medulla (seven experiments, Fig. 2)

The rigid, narrow clip was applied to the left renal artery and the fragmented renal medulla derived from the removed right kidney was autotransplanted either subcutaneously (four times) or intraperitoneally (three times). The mean arterial pressure rose from near 70 mm Hg to 88 mm Hg during 10 days' time. Between days 13 and 20, the arterial pressure remained between 85 and 100 mm Hg. The differences in arterial pressure of this group and the group of the standardized experiment between days 13 and 20 were highly sig-

nificant (see Table I). Thus, the renomedullary transplants protected against the accelerated (malignant) hypertension in a manner similar to that of the sham-operated kidney. It is emphasized that a lethal set of circumstances seemed averted between days 13 and 20 by the presence of the transplanted renal medulla.

There was no difference in results when the subcutaneous and intraperitoneal routes of transplantation were compared (P 0.5–0.8).

Autotransplanted renal medulla followed by removal of the renomedullary transplants after 22–90 days *in situ* within the subcutaneous tissue (four experiments, Fig. 4)

In these experiments, the left renal artery was constricted by the rigid, narrow clip and autogenous renomedullary transplants from the right kidney were injected subcutaneously. Protection against the accelerated (malignant) hypertension was afforded by the presence of these transplants for 22–24 days in three experiments and 90 days in one experiment. At these times, the renomedullary transplants were removed surgically. After ablation of these transplants, the arterial pressure rose sharply and the animals died within 3–21 days. The results after ablation of the renomedullary transplants resembled those after removal of the sham-operated kidney.

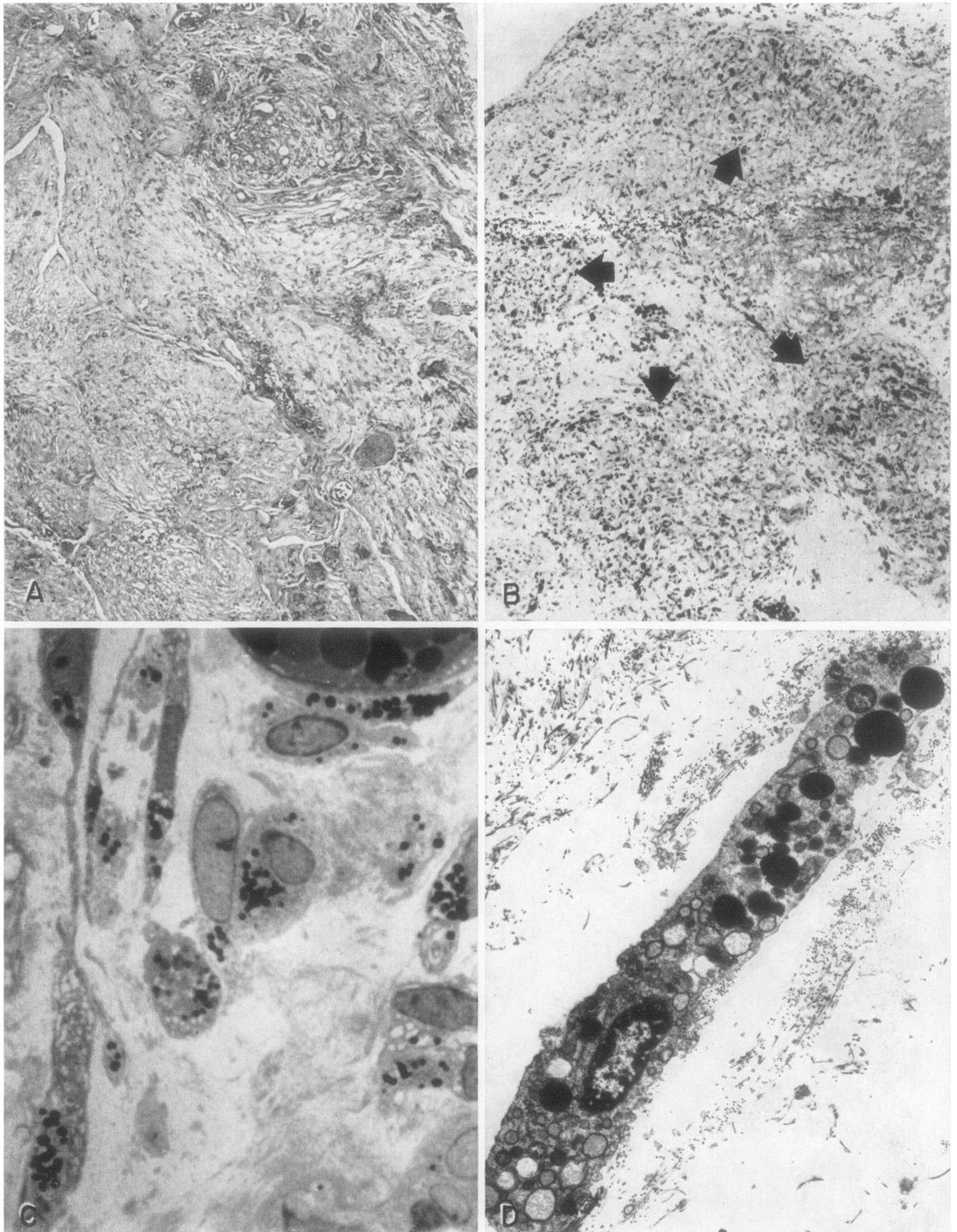


FIGURE 5 Microscopic appearance of the nodules protective toward accelerated (malignant) hypertension in the rabbit of Fig. 4 A is shown. A. Hematoxylin and eosin stain, $\times 100$: the

The renomedullary transplants protective toward the accelerated (malignant) hypertension were examined grossly and by light and electron microscopy.

Gross appearance of renomedullary transplants protective toward hypertension (Fig. 1)

The tracts and nodules of renomedullary tissue protective toward hypertension displayed highly vascular surroundings. The blood vessels were readily peeled away during the removal of the transplants. After removal of the vascular capsule the transplants were golden yellow in color. Upon removal from the body they were found to be firm, solid, and on section were yellow in color throughout.

Characteristics of the renomedullary transplants by light microscopy (Fig. 5A, B, and C)

Hematoxylin and eosin stain (Fig. 5A). The tissue displayed a separation into irregular lobules apparently due to the original fragmentation. It appeared as a nondescript connective tissue structure which was well vascularized by capillary-type vessels.

In addition, there were foci containing degenerated renal tubules and a few scattered macrophages, lymphocytes, and polymorphonuclear leukocytes. There was no overt inflammatory change and, as expected, no indication of rejection. The remaining tubules were either extremely atrophic or destroyed and calcified by dystrophic type of calcification.

Oil red O stain (Fig. 5B). The oil red O stain indicated the presence of many cells containing fine red droplets of lipid in their cytoplasm. These droplets were especially evident about the nucleus of the cell. The cells themselves appeared to concentrate in certain areas giving the impression of clustering. The high lipid content appeared to explain the gross yellow color, most likely due to carotinoid pigment as in other lipid-containing tissues.

Sudan black B stain. The cells which yielded oil red O positive droplets appeared to be the same cells containing many black droplets following the Sudan black B stain. These droplets were not evident when the tissue was pretreated with acetone, suggesting that they resulted from the presence of phospholipids.

Liebermann-Burchardt reaction. The Shultz modification of the Liebermann-Burchardt reaction indicated that cells within the transplants had granules yielding a green color. This suggested that the granules contained cholesterol.

Alcian blue and colloidal iron stains. The deep blue color of these stains indicated the presence of acid mucopolysaccharide of ground substance. The ground substance was in the form of pools among the fibrillar structure. Since acid mucopolysaccharide is present in normal renal medulla, these observations indicated the presence of cells capable of maintaining this structural pattern of the original tissue.

Periodic acid-Schiff reaction. This stain suggested the presence of much collapsed basement membrane material within the renomedullary transplants.

Semithin section and toluidine blue stain (Fig. 5C). Epon-embedded tissue was sectioned at 0.5μ and stained with toluidine blue. This stain gives the lipid vesicles of the renomedullary interstitial cell a purplish to greenish color. The cells occurring in clusters as noted with the oil red O stain had the typical appearance of renomedullary interstitial cells. The elongation and formation of cytoplasmic processes and the presence of many vesicles were especially noteworthy. These sections also indicated the presence of a great deal of basement membrane material most of which appeared collapsed. The latter, as in the PAS-stained preparation, is in keeping with the disappearance of most tubules leaving their basement membranes behind.

Characteristics of the renomedullary transplants by electron microscopy (Fig. 5D)

By electron microscopy, the main cell type encountered within the renomedullary transplants had the characteristics of the renomedullary interstitial cell. The nucleus of this cell was prominent and the cytoplasm extended out as elongated processes. Within the cytoplasm were prominent osmiophilic vesicles. These vesicles varied in the intensity of osmiophilia, a few being light gray but most being intensely black in color, suggesting a variation in lipid content. Perinuclear and other cisterns were noted. These cisterns were surrounded by ribosomal-like dark particles. In some cells mitochondria, smooth endoplasmic reticulum and

appearance is that of nondescript connective tissue having many capillaries. The lobular or fragmented appearance can be noted. At the upper right hand area there is a group of atrophic tubules. B. Oil red O stain of frozen section, $\times 40$: the dark staining cells are lipid-containing oil red O positive cells. The arrangement in clusters is indicated by the arrows. C. Semithin section stained with toluidine blue, $\times 1500$: the cells containing the dark staining or toluidine blue positive vesicles have the characteristics of interstitial cells. Note interstitial-type cells adherent to capillaries at the top and right corner of the figure. D. Electron microscopy, $\times 5600$: the elongated cells of Fig. 5C have the typical appearance of renomedullary interstitial cells by electron microscopy. Note the osmiophilic vesicles and scattered ER sacs.

Golgi apparatus, as described for the renomedullary interstitial cell in its natural habitat, were also noted. As expected from experience with the interstitial cell within the kidney itself (32), there was an inverse relationship between the number of osmiophilic vesicles and cistern formation. The interstitial cells were in close proximity to capillaries.

Occasionally, a cell having smooth endoplasmic reticulum and rare osmiophilic vesicles was encountered.

DISCUSSION

Results following the experimental model herein described and those of three other experimental models previously recorded (15–21) support the view that the renal medulla exerts an antihypertensive function. These models suggest that the renomedullary antihypertensive function results from the action of unique renomedullary cells. Examination of many sections from the subcutaneous transplants protective toward the accelerated (malignant) hypertension of the present study revealed the presence of eight cell types. These were: (a) endothelium of normal-appearing capillaries; (b) fibroblasts; (c) macrophages; (d) lymphocytes; (e) polymorphonuclear leukocytes; (f) either atrophic or calcified renal tubules; (g) a cell having smooth endoplasmic reticulum and rare osmiophilic vesicles; and (h) typical renomedullary interstitial cells with either many osmiophilic vesicles or few osmiophilic vesicles and prominent perinuclear and other cisterns. Of these cell types, the macrophages, lymphocytes, polymorphonuclear leukocytes, and fibroblasts were few and scattered. The cell with smooth endoplasmic reticulum was rare. There was little reason to suggest that ingrowing capillaries were unique and the remaining tubular epithelium was in a degenerated rather than regenerated and healthy-appearing state. The most common cell type had the characteristics of the renomedullary interstitial cell. Moreover, the interstitial cells appeared to be in groups or clusters suggesting a focal proliferation. Thus, it would seem that the interstitial cell was the most eligible cell for the exertion of the antihypertensive action of the renomedullary transplants.

The vasodepressor prostaglandins E_2 and A_2 (PGE_2 and PGA_2) (27–30) and an antihypertensive neutral lipid (25, 40, 41) have been extracted from the renal medulla. Prostaglandin E_2 exerts an antihypertensive effect in the hypertensive rat (42) and rabbit (41) when injected in large doses and prostaglandin A_2 drops the pressure of hypertensive man during continuous intravenous infusion (43). The antihypertensive neutral renomedullary lipid (ANRL) lowers the arterial pressure of the hypertensive dog (40) and rabbit (41) by means of relatively low doses when highly refined.

Two major hypotheses may be entertained relative to the antihypertensive renomedullary cellular action. One considers the secretion of depressor substances and the other the neutralization or suppression of pressor substances. As noted above, there are indications that the osmiophilic vesicles of the renomedullary interstitial cells contain prostaglandin (35–37). It remains to be demonstrated whether ANRL is also present in these cells. The interstitial cell does possess features of a secretory cell (44, 45.) Prostaglandin-like substances, most likely PGE_2 , have been recovered from the renal venous effluent in renovascular hypertension (46, 47) and after the infusion of angiotension II (48). Thus, the possibility that the renomedullary interstitial cells secrete antihypertensive lipid(s), as suggested by Muehrcke, Mandal, and Volini (32), appears as the more attractive hypothesis at this time.

Why renomedullary cells seemingly exert an antihypertensive action as a transplant outside the kidney and do not do so within the Goldblatt kidney remains a problem. This suggests that the renal artery constriction by an unknown mechanism, such as hemodynamic, neutral, or biochemical, constrains the action of the renomedullary cells responsible for the antihypertensive action (21). According to the present observations, the cells most likely so affected are the renomedullary interstitial cells.

ACKNOWLEDGMENTS

This work was supported by U. S. Public Health Service Grant HE-09765, The Upjohn Company, Kalamazoo, Mich., and the McDermott Foundation, Dallas, Tex.

REFERENCES

1. Goldblatt, H., J. Lynch, R. F. Hanzal, and W. W. Summerville. 1934. Studies on experimental hypertension. I. The production of persistent elevation of systolic blood pressure by means of renal ischemia. *J. Exp. Med.* **59**: 347.
2. Goldblatt, H. 1938. Experimental hypertension induced by renal ischemia. *Bull. N. Y. Acad. Med.* **14**: 523.
3. Fasciolo, J. D., B. A. Houssay, and A. C. Taquini. 1938. The blood pressure raising secretion of the ischemic kidney. *J. Physiol. (London)*. **94**: 281.
4. Pickering, G. W., and M. Prinzmetal. 1938. Experimental hypertension of renal origin in the rabbit. *Clin. Sci. (London)*. **3**: 357.
5. Katz, L. N., M. Mendlowitz, and M. Friedman. 1938. A study of the factors concerned in renal hypertension. *Proc. Soc. Exp. Biol. Med.* **37**: 722.
6. Merrill, J. P., J. E. Murray, J. H. Harrison, and W. R. Guild. 1956. Successful homotransplantation of the human kidney between identical twins. *J. Amer. Med. Ass.* **160**: 277.
7. Muirhead, E. E., J. A. Stirman, W. Lesch, and F. Jones. 1956. The reduction of postnephrectomy hypertension by renal homotransplants. *Surg. Gynecol. Obstet.* **103**: 673.

8. Hume, D. M. 1964. Current results of organ homotransplantation in man and prospects for the future. Lewis A. Connor Mem. Lecture. *Circulation*. **30** (Suppl. 3): 37. (Abstr.)
9. Kolff, W. J., S. Nakamoto, E. F. Poutasse, R. A. Straffon, and J. E. Figueroa. 1964. Effect of bilateral nephrectomy and kidney transplantation on hypertension in man. *Circulation*. **30** (Suppl. 2): 23.
10. Ducrot, H., P. Jungers, J. L. Funk-Brentano, D. Perrin, J. Crosnier, and J. Hamburger. 1966. L'action de la transplantation renale humaine sur l'hypertension arterielle. In *L'Hypertension Arterielle*. P. Milliez and P. Tcherdakoff, editors. Expansion Scientifique Francaise, Paris. 208.
11. Kolff, W. J., and J. H. Page. 1954. Blood pressure reducing function of the kidney; reduction of renoprival hypertension by kidney perfusion. *Amer. J. Physiol.* **178**: 75.
12. Kolff, W. J. 1957. Reduction of experimental renal hypertension by kidney perfusion. *Univ. Mich. Med. Bull.* **23**: 238.
13. Gomez, A. H., S. W. Hoobler, and P. Blaquier. 1960. Effect of addition and removal of kidney transplant in renal and adrenocortical hypertensive rats. *Circ. Res.* **8**: 464.
14. Tobian, L., S. Schonning, and C. Siefeldt. 1964. The influence of arterial pressure on the antihypertensive action of a normal kidney: a biological servomechanism. *Ann. Intern. Med.* **60**: 378.
15. Muirhead, E. E., and J. A. Stirman. 1958. Protection by ureterocaval anastomosis with a study of kidneys so treated. *Amer. J. Pathol.* **34**: 561.
16. Muirhead, E. E., J. Vanatta, and A. Grollman. 1950. Papillary necrosis of the kidney. A clinical and experimental correlation. *J. Amer. Med. Ass.* **142**: 627.
17. Muirhead, E. E., F. Jones, and J. A. Stirman. 1960. Hypertensive cardiovascular disease of dog. Relation of sodium and dietary protein to ureterocaval anastomosis and ureteral ligation. *Arch. Pathol.* **70**: 122.
18. Muirhead, E. E. 1962. Protection against sodium-overload hypertensive disease. *Arch. Pathol.* **74**: 214.
19. Muirhead, E. E., J. A. Stirman, and F. Jones. 1960. Renal autoexplantation and protection against renoprival hypertensive disease and hemolysis. *J. Clin. Invest.* **39**: 266.
20. Muirhead, E. E., G. B. Brown, G. S. Germain, and B. E. Leach. 1970. The renal medulla as an antihypertensive organ. *Proc. Int. Congr. Nephrol. 4th.* **2**: 57.
21. Muirhead, E. E., G. B. Brown, G. S. Germain, and B. E. Leach. 1970. The renal medulla as an antihypertensive organ. *J. Lab. Clin. Med.* **76**: 641.
22. Muirhead, E. E., F. Jones, and J. A. Stirman. 1960. Antihypertensive property in renoprival hypertension of extract from renal medulla. *J. Lab. Clin. Med.* **56**: 167.
23. Lee, J. B., R. B. Hickler, C. A. Saravis, and G. W. Thorn. 1963. Sustained depressor effect of renal medullary extract in the normotensive rat. *Circ. Res.* **13**: 359.
24. Hickler, R. B., D. P. Lauer, C. A. Saravis, A. I. Vagnucci, G. Steiner, and G. W. Thorn. 1964. Vasodepressor lipid from renal medulla. *Can. Med. Ass. J.* **90**: 280.
25. Muirhead, E. E., E. G. Daniels, E. Booth, W. A. Freyburger, and J. W. Hinman. 1965. Renomedullary vaso-depression and antihypertensive function. *Arch. Pathol.* **80**: 43.
26. Lee, J. B., B. G. Covino, B. H. Takman, and E. R. Smith. 1965. Renomedullary vasodepressor substance medullin: isolation, chemical characterization, and physiological properties. *Circ. Res.* **17**: 57.
27. Lee, J. B., J. Z. Gougoutas, B. H. Takman, E. G. Daniels, M. F. Grostic, J. E. Pike, J. W. Hinman, and E. E. Muirhead. 1966. Vasodepressor and antihypertensive prostaglandins of PGE type with emphasis on identification of medullin as PGE₂-217. *J. Clin. Invest.* **45**: 1036.
28. Daniels, E. G., J. W. Hinman, B. E. Leach, and E. E. Muirhead. 1967. Identification of prostaglandin E₂ as the principal vasodepressor lipid of rabbit medulla. *Nature (London)*. **215**: 1298.
29. Lee, J. B., K. Crowshaw, B. H. Takman, K. A. Attrep, and J. Z. Gougoutas. 1967. The identification of prostaglandin E₂, F₂ and A₂ from rabbit kidney medulla. *Biochem. J.* **105**: 1251.
30. Crowshaw, K., J. C. McGiff, J. C. Strand, A. J. Lonigro, and N. A. Terragno. 1970. Prostaglandins in dog renal medulla. *J. Pharm. Pharmacol.* **22**: 302.
31. Muehrcke, R. C., A. K. Mandal, M. Epstein, and F. I. Volini. 1969. Cytoplasmic granularity of renal medullary interstitial cells in experimental hypertension. *J. Lab. Clin. Med.* **73**: 299.
32. Muehrcke, R. C., A. K. Mandal, and F. I. Volini. 1970. A pathophysiological review of the renal medullary interstitial cells and their relationship to hypertension. *Circ. Res.* **27**: 109.
33. Tobian, L., M. Ishii, and M. Duke. 1969. Relationship of cytoplasmic granules in renal papillary interstitial cells to "post-salt" hypertension. *J. Lab. Clin. Med.* **73**: 309.
34. Ishii, M., and L. Tobian. 1969. Interstitial cell granules in renal papilla and the solute composition of renal tissue in rats with Goldblatt hypertension. *J. Lab. Clin. Med.* **74**: 47.
35. Nissen, H. M., and H. Andersen. 1969. On the activity of a prostaglandin-dehydrogenase system in the kidney. A histochemical study during hydration/dehydration and salt-repletion/salt-depletion. *Histochemie*. **17**: 241.
36. Nissen, H. M., and I. Bojesen. 1969. On lipid droplets in renal interstitial cells. IV. Isolation and identification. *Z. Zellforsch. Mikrosk. Anat.* **97**: 274.
37. Bohman, S. O., and H. B. Maunsbach. 1969. Isolation of the lipid droplets from interstitial cells of the renal medulla. *J. Ultrastruct. Res.* **29**: 569.
38. Brooks, B., and E. E. Muirhead. 1971. Rigid clip for standardized hypertension in the rabbit. *J. Appl. Physiol.* **31**: 307.
39. Pearse, A. G. E. 1960. *Histochemistry, Theoretical and Applied*. Little, Brown and Company, Boston. 2nd edition. 234, 256, 259, 304-306, 320, 773-949.
40. Muirhead, E. E., B. Brooks, M. Kosinski, E. G. Daniels, and J. W. Hinman. 1966. Renomedullary antihypertensive principle in renal hypertension. *J. Lab. Clin. Med.* **67**: 778.
41. Muirhead, E. E., B. E. Leach, L. W. Byers, B. Brooks, E. G. Daniels, and J. W. Hinman. 1971. Antihypertensive neutral renomedullary lipids (ANRL). In *Kidney Hormones*. J. W. Fisher, editor. Academic Press Inc. Ltd., London. 2nd edition. 485.
42. Muirhead, E. E., B. Leach, B. Brooks, G. B. Brown, E. G. Daniels, and J. W. Hinman. 1968. Antihypertensive action of prostaglandin E₂. In *Prostaglandins*.

- Symposium of the Worcester Foundation for Experimental Biology. P. W. Ramwell and J. E. Shaw, editors. Interscience Publishers, New York. 183.
43. Lee, J. B. 1968. Cardiovascular implications of the renal prostaglandins. *In* Prostaglandins. Symposium of the Worcester Foundation for Experimental Biology. P. W. Ramwell and J. W. Shaw, editors. Interscience Publishers, New York. 131.
 44. Osvaldo, L., and H. Latta. 1966. Interstitial cells of the renal medulla. *J. Ultrastruct. Res.* 15: 589.
 45. Osvaldo-Decima, L., and H. Latta. 1970. The renal medulla of diuretic and antidiuretic rats studied by electron microscopy. *Proc. Int. Congr. Nephrol.* 4th. 2: 116.
 46. Edwards, W. G., Jr., C. G. Strong, and J. C. Hunt. 1969. A vasodepressor lipid resembling prostaglandin E₂ (PGE₂) in the renal venous blood of hypertensive patients. *J. Lab. Clin. Med.* 74: 389.
 47. McGiff, J. C., K. Crowshaw, N. A. Tenagro, A. J. Lonigro, J. C. Strand, M. A. Williamson, J. B. Lee and K. R. Ng. 1970. Prostaglandin-like substances appearing in canine renal venous blood during renal ischemia. *Circ. Res.* 27: 765.
 48. McGiff, J. C., K. Crowshaw, N. A. Terragno, and A. J. Lonigro. 1970. Release of a prostaglandin-like substance into renal venous blood in response to angiotensin II. *Circ. Res.* 27 (Suppl. I): 121.