

CASE REPORT

Ameloblastic carcinoma: Secondary dedifferentiated carcinoma of the mandible: Report of a rare entity with a brief review

Siddharth Pundir, Susmita Saxena, Vanita Rathod, Pooja Aggrawal

Department of Oral and Maxillofacial Pathology, Subharti Dental College, Meerut, India

Address for correspondence:

Dr. Siddharth Pundir,
House No: 8 Sector-11, Shastri Nagar,
Meerut, India.
E-mail: sidpundir2002@yahoo.co.in

ABSTRACT

Epithelial odontogenic tumors arise from odontogenic epithelial structures. Malignant epithelial odontogenic tumors are extremely rare. Ameloblastic carcinomas may present denovo, ex ameloblastoma or ex odontogenic cyst. Most ameloblastic carcinomas are presumed to present denovo. To date less than 45 cases of ameloblastoma with metastasis have been reported. It occurs primarily in the mandible in a wide range of age groups; no sex or race predilection has been noted. It may present as a cystic lesion with benign clinical features or as a large tissue mass with ulceration, significant bone resorption, and tooth mobility. The lesion is usually found unexpectedly after an incisional biopsy or the removal of a cyst. Histologic features of ameloblastic carcinoma shows tumor cells that resemble the cells seen in ameloblastoma, but they show cytologic atypia. Moreover, they lack the characteristic arrangement seen in ameloblastoma. The clinical course of ameloblastic carcinoma is typically aggressive, with extensive local destruction. Here we describe a rare case of ameloblastic carcinoma (secondary dedifferentiated carcinoma) of mandible in a 40-year-old female patient. Ameloblastic carcinoma: Secondary dedifferentiated carcinoma of the mandible.

Key words: Ameloblastic carcinoma, cytologic atypia, *de novo*

INTRODUCTION

Epithelial odontogenic tumors arise from odontogenic epithelial structures. Malignant epithelial odontogenic tumors are extremely rare. Malignant ameloblastoma, ameloblastic carcinoma, primary intraosseous squamous cell carcinoma, clear cell odontogenic carcinoma, are the entity lesions of this group. Ameloblastic carcinoma is an aggressive tumor with a poor prognosis. To date less than 45 cases of ameloblastoma with metastasis have been reported, out of which most of the cases were denovo.^[1] In the literature, ameloblastic carcinoma arising from preexisting ameloblastoma is very rare. Here we present an interesting and unusual presentation of ameloblastic carcinoma arising at the site of previously operated ameloblastoma.

CASE REPORT

A 40-year-old female patient reported to the Department of Oral Pathology and Microbiology, Subharti Dental College, Meerut, with a complaint of pain and swelling on the right side of the face. The patient gave the history of previously treated ameloblastoma 6 months back in the same area. The previous postsurgical biopsy report was ameloblastoma as mentioned by the patient and details of histopathology were not available.

On extra oral examination swelling was firm, fixed extending from right corner of mouth anteriorly to pinna posteriorly and superiorly from zygomatic arch to neck inferiorly [Figure 1].

On intra oral examination, a pedunculated gingival mass with irregular surface was seen on the lower-right side extending from 44 to 48. Spontaneous bleeding was also noticed [Figure 2].

On radiographic evaluation, alveolar bone resorption associated with displacement of the roots of adjacent teeth was seen. Incisional biopsy was performed for diagnostic purpose [Figure 3].

Access this article online**Quick Response Code:****Website:**

www.jomfp.in

DOI:

10.4103/0973-029X.84501

A computed tomographic examination revealed tumor perforated the cortex coronally and lingually on the lower-right side extending from 44 to 48.

A provisional diagnosis of malignant ameloblastoma and non-Hodgkin's lymphoma was made.

The excised tissue macroscopically consisted of multiple bits of soft tissue, creamish brown in color measuring approximately 1 × 1 cm in diameter, irregular surface, and firm in consistency [Figure 4].

Microscopic examination of H and E stained sections from received specimen showed proliferating sheets of tumor cells, which were arranged in sheets and follicles in most of the areas.

The tumor appeared to be divided into lobules by connective tissue septa, which was compressed and minimal with mature collagen fibers and spindly fibrocytes. The follicles appeared to have tall columnar cells with palisading arrangement of outer cell layer [Figure 5].

Tumor cells were cuboidal in shape with enlarged vesicular nuclei showing hyperchromatism and pleomorphism. Nuclear material was granular with frequent mitotic figures and prominent nucleoli. Some of the cells appeared empty with nuclei pushed to one side giving a clear cell-like appearance. Stellate reticulum-like tissue was appreciable in one area only in the given sections [Figures 6-8].

Microscopic features were suggestive of ameloblastic carcinoma (Secondary dedifferentiated carcinoma).

Histologically a tumor that must be considered in the differential diagnosis of ameloblastic carcinoma is the primary intra-alveolar epidermoid carcinoma although the primary intralveolar carcinoma and the ameloblastic carcinoma exhibit some clinical differences; their histologic features are similar enough to suggest a histogenetic relationship.^[2]

Salivary gland neoplasm's metastatic to invading or arising centrally within the jaws may be mistaken for ameloblastic carcinoma. These include pseudo adamantine adenocarcinoma, ductal carcinoma, and high-grade mucoepidermoid carcinoma.^[3]

Metastatic carcinoma to the jaws from primary locations such as lung, breast, and the gastrointestinal tract may mimic ameloblastic carcinoma and must always be ruled out clinically before the diagnosis is made.^[3]

The patient was treated symptomatically and hemimandibulectomy was advised, as radiotherapy and chemotherapy seem to be of a limited value. Close follow up of the case is done till date.

DISCUSSION

Ameloblastoma is a histologically benign neoplasm that arises from the odontogenic apparatus and constitutes only 1% of tumors and cysts in the jaws. The malignant form of ameloblastoma has been controversial for many years. The term "malignant ameloblastoma" implies that lesions metastasize despite their benign histology. The term "ameloblastic carcinoma" is reserved for an ameloblastoma with a malignant morphologic appearance, regardless of the presence of metastasis. Ameloblastic carcinomas are extremely rare malignant odontogenic epithelial neoplasms and may arise *de novo* or from a pre-existing odontogenic lesion.^[4]

The incidence of ameloblastic carcinoma is greater than that of malignant ameloblastoma by a ratio of 2:1.^[5]

Ameloblastic carcinoma occurs in a range of 15-84 years as reported, but the average age is around 30-50 years, which is in agreement with that reported for ameloblastomas and supports our case also.^[3]

There is no apparent sex predilection: 1:1 gender distribution has been reported.^[6]

The most commonly involved area is the posterior portion of the mandible as was the site in the present case. Involvement of the maxilla by ameloblastic carcinoma seems to be less frequent than that of the mandible.^[7]

Although symptoms include swelling with associated pain, rapid growth, trismus, and dysphonia, the patient reported with the complaint of swelling and no other symptom.

Drevelengas *et al*, reported about nineteen cases surgically and pathologically confirmed of ameloblastoma, which included 15 cases of ameloblastoma of the mandible and four of the maxilla. There were 11 male and eight female patients, aged 18-79 years (average 37 years). Four cases represented recurrences of surgically treated tumors.^[8]

Slootweg and Muller (1984) reviewed the literature and reclassified 69 reported cases into 46 ameloblastic carcinomas and 23 malignant ameloblastomas, indicating that the incidence of ameloblastic carcinoma may be twice as that of malignant ameloblastoma.^[7]

Whether ameloblastoma may transform biologically and histologically from a classic ameloblastoma to a malignant lesion is controversial. This lesion exhibits histologic evidence of malignancy, regardless of whether it has metastasized. Although various authors have shown that metastasizing ameloblastomas are histologically indistinguishable from classic ameloblastomas, others have identified unequivocal malignant features in the recurrent or metastatic tumor, usually many years after repeated surgical excisions.^[9]

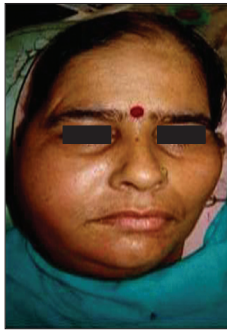

Figure 1: Extraoral photograph showing swelling which was firm, fixed extending from right corner of mouth anteriorly to pinna posteriorly and superiorly from zygomatic arch to neck inferiorly

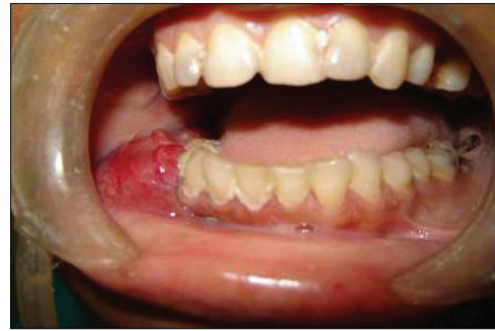

Figure 2: Intraoral examination showing a pedunculated gingival mass with irregular surface was seen on the lower-right side extending from 44 to 48

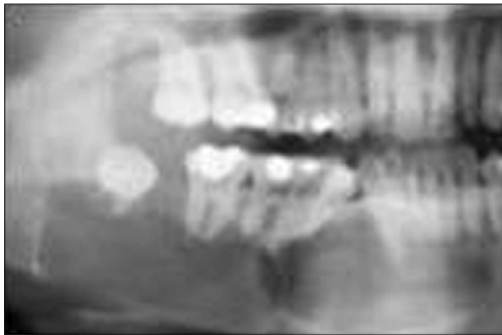

Figure 3: OPG showing unilocular radiolucency in lower-right posterior region in relation to 44 to 48 along with root resorption in the same region

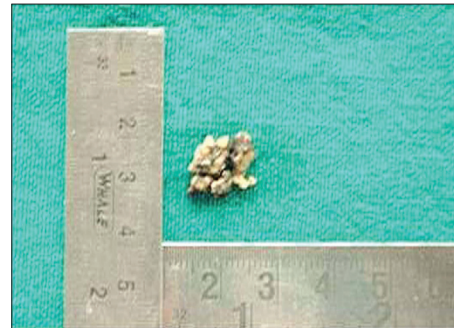

Figure 4: Gross appearance of received specimen

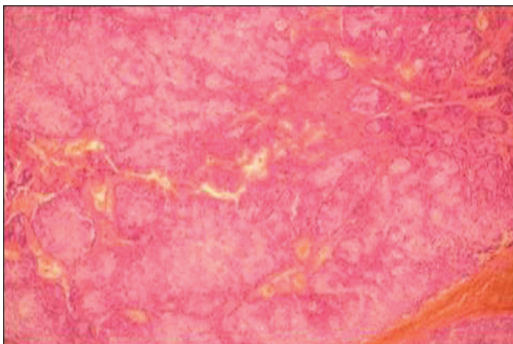


Figure 5: Sheets of tumor cells arranged in follicles separated by minimal connective tissue stroma (H and E, 4x)

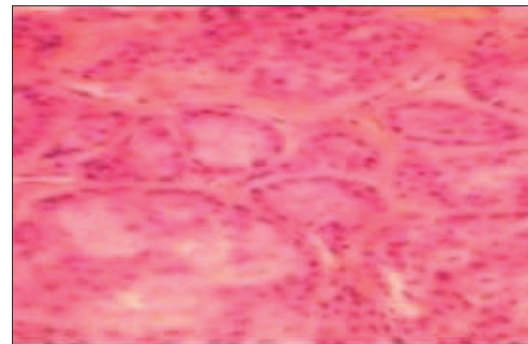


Figure 6: Follicles showing peripheral palisading arrangement of low cuboidal shaped cells and centrally hypercellular and disorderly arranged cells (H and E, 40x)

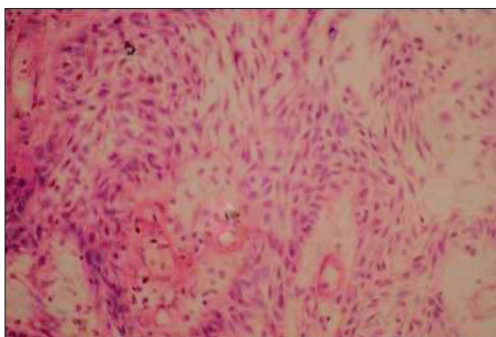


Figure 7: Follicles showing normal stellate reticulum like cells (H and E, 40x)

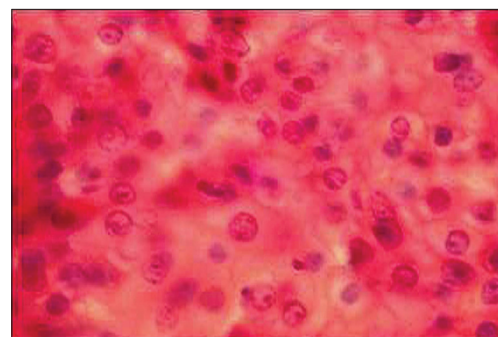


Figure 8: Tumor cell showing hyperchromatism and few mitotic figures (Stain: H and E, 40x)

It has been suggested that the high rate of recurrence is due to its mode of growth and surgical mismanagement rather than any inherent malignant properties and metastases are exceedingly rare.

Mathew *et al* recently described five cases (three primary mandibular tumors and two cases of metastases) in which ameloblastoma was diagnosed by fine-needle aspiration cytology. The smears were hypercellular and occasionally showed tissue fragments of basaloid cells with peripheral palisading. A distinct, 2-cell population was seen, consisting of small, hyperchromatic, basaloid-type cells, and scattered larger cells with more open chromatin.^[10]

Thus, the term ameloblastic carcinoma can be applied to our case, which showed clusters or nests and islands of epithelium within a collagenous stroma, which are composed of a peripheral layer of polarized cells enclosing stellate to basaloid cells in the early transition or de-differentiation stage. Individual cellular features include pleomorphism, frequent mitotic figures, indistinct cell membranes, focal necrosis, loss of cellular cohesion, and infiltration were seen.

When the diagnosis of an ameloblastic carcinoma is made, an assessment of nodal metastasis and evidence of distant metastasis is required. A staged work-up consisting of a neck examination, a CT scan of the area, and a chest radiograph becomes necessary.^[11]

The treatment of ameloblastic carcinoma is controversial, but the recommended surgical treatment usually requires jaw resection with 2- to 3-cm bony margins and consideration of contiguous neck dissection, both prophylactic and therapeutic. Documented case reports with meaningful follow-up are rare. Meticulous follow-up is essential because recurrence and metastasis in the lung and regional lymph nodes have been reported.^[12]

Presurgical radiation therapy has been suggested to decrease the tumor size, but chemotherapy is as yet unproven.^[13]

Reconstruction of the postresection defect may proceed, as one would normally expect following any head or neck carcinoma resection. Sufficient time should be allotted before reconstruction because of potential tumor recurrence.^[3]

We have had no report of metastasis in the case presented, although we must bear in mind the possibility that this may yet occur. In the literature, there are a limited number of cases of ameloblastic carcinoma arising from an ameloblastoma; however, instructions regarding clinical and histopathologic progress are sufficient for the general use.^[5]

CONCLUSION

It is reasonable to assume that this case illustrates the malignant portion in the spectrum of ameloblastomas. It is possible that ameloblastoma shows a variety of histological and biological behaviors ranging from benignity to frank malignancy. Cases of ameloblastoma should thus be studied carefully, correlating their histologic pattern with biologic behavior to detect subtle changes in histology that may predict an aggressive behavior.

REFERENCES

1. Cizmecý O, Aslan A, Onel D, Demiryont M. Ameloblastic Carcinoma ex ameloblastoma of the mandible: Case Report. *Otolaryngol Head Neck Surg* 2004;130:633-4.
2. Ozluedik S, Ozcan M, Basturk O, Deren O, Kaptanoglu E, Adanali G, *et al.* Ameloblastic carcinoma from anterior skull base: An interdisciplinary approach. *Skull Base* 2005;15: 269-73 .
3. Regezi JA, Kerr DA, Courtney RM. Odontogenic tumors: Analysis of 706 cases. *J Oral Surg* 1978;36:771-8.
4. Corio LR, Goldblatt LI, Edwards PA, Hartman KS. Ameloblastic carcinoma: A clinicopathologic study and assessment of eight cases. *Oral Surg Oral Med Oral Pathol* 1987;64:570-6.
5. Lee L, Maxymiw WG, Wood RE. Ameloblastic carcinoma of the maxilla metastatic to the mandible. Case report. *J Craniomaxillofac Surg* 1990;18:247-50.
6. Slootweg PJ, Müller H. Malignant ameloblastoma or ameloblastic carcinoma. *Oral Surg Oral Med Oral Pathol* 1984;57:168-76.
7. Drevelengas A, Eleftheriadis J, Kalaitzoglou I, Palladas P, Lazaridis N. Imaging of maxillomandibular ameloblastoma. *Eur Radiol* 1994;4:203-10.
8. Avon SL, McComb J, Clokie C. Ameloblastic carcinoma: Case report and literature review. *J Can Dent Assoc* 2003;69:573-6.
9. Mathew S, Rappaport K, Ali SZ, Busseniers AE, Rosenthal DL. Ameloblastoma. Cytologic findings and literature review. *Acta Cytol* 1997;41:955-60.
10. Marx RE, Stern D. *Oral and maxillofacial pathology. A rationale for diagnosis and treatment.* Illinois: Quintessence Publishing Co, Inc; 2003. p. 657.
11. Cox DP, Muller S, Carlson GW, Murray D. Ameloblastic carcinoma ex ameloblastoma of the mandible with malignancy-associated hypercalcemia. *Oral Surg Oral Med Oral Pathol Oral Radiol Endod* 2000;90:716-22.
12. Bruce RA, Jackson IT. Ameloblastic carcinoma. Report of an aggressive case and review of the literature. *J Craniomaxillofac Surg* 1991;19:267-71.
13. Datta R, Winston JS, Diaz-Reyes G, Loree TR, Myers L, Kuriakose MA, *et al.* Ameloblastic carcinoma: Report of an aggressive case with multiple bony metastases. *Am J Otolaryngol* 2003;24:64-9.

How to cite this article: Pundir S, Saxena S, Rathod V, Aggrawal P. Ameloblastic carcinoma: Secondary dedifferentiated carcinoma of the mandible: Report of a rare entity with a brief review. *J Oral Maxillofac Pathol* 2011;15:201-4.

Source of Support: Nil. **Conflict of Interest:** None declared.