

Homocystine-Induced Arteriosclerosis

THE ROLE OF ENDOTHELIAL CELL INJURY AND PLATELET RESPONSE IN ITS GENESIS

LAURENCE A. HARKER, RUSSELL ROSS, SHERRILL J. SLICHTER, and
C. RONALD SCOTT

From the Departments of Medicine, Pathology, Pediatrics, and the Regional Primate Research Center, University of Washington School of Medicine, Harborview Medical Center and the Puget Sound Blood Center, Seattle, Washington 98104

ABSTRACT The atherogenic mechanism of homocystinemia has been defined by measuring endothelial cell loss and regeneration, platelet consumption, and intimal lesion formation in a primate model. Three groups of baboons were studied: (a) 8 control animals; (b) 15 animals after 3 mo of continuous homocystinemia; and (c) 11 animals after 3 mo of combined homocystinemia and oral treatment with dipyridamole.

Experimental homocystinemia caused patchy endothelial desquamation comprising about 10% of the aortic surface despite a 25-fold increase in endothelial cell regeneration. Neither endothelial cell loss nor regeneration was changed significantly by dipyridamole. Homocystine-induced vascular deendothelialization produced a threefold increase in platelet consumption that was interrupted by dipyridamole inhibition of platelet function.

All homocystinemic animals developed typical arteriosclerotic or preatherosclerotic intimal lesions composed of proliferating smooth muscle cells averaging 10–15 cell layers surrounded by large amounts of collagen, elastic fibers, glycosaminoglycans, and sometimes lipid. Intimal lesion formation was prevented by dipyridamole therapy. We conclude that homocystine-induced endothelial cell injury resulted in arteriosclerosis through platelet-mediated intimal proliferation of smooth muscle cells that can be prevented by drug-induced platelet dysfunction.

INTRODUCTION

Lesions of atherosclerosis, identical to those found in man, are readily produced in the subhuman primate

(1–4). Intimal proliferative smooth muscle cell lesions, identical in appearance to the fibromusculoelastic lesion considered to be the precursor of atherosclerosis in man, are transiently produced in the arteries of nonhuman primates by a variety of methods including mechanical deendothelialization (5–8). Furthermore, the addition of a fatty diet, either alone or in combination with mechanical injury, can produce the classic lesions of atherosclerosis, the fatty streak and the fibrous plaque (9, 10). The genesis of these lesions may involve: (a) endothelial injury leading to focal desquamation of cells; (b) adherence and aggregation of platelets to exposed subendothelial connective tissue; (c) local release of platelet constituents, including a platelet mitogenic factor (11), and passage of plasma constituents into the underlying artery wall; (d) migration of smooth muscle cells through fenestrae of the internal elastic lamina into the intima and platelet-mediated intimal proliferation of smooth muscle cells; (e) formation of connective tissue matrix by the smooth muscle cells through synthesis and secretion of collagen, elastic fiber proteins, and glycosaminoglycans; and (f) intracellular and extracellular lipid accumulation. Maximal lesion formation occurs within 3 mo after mechanical injury. The lesions appear to regress once the overlying endothelium has regenerated, and resolution is virtually complete 3 mo later in normocholesterolemic monkeys (6). This formulation suggests that repeated or chronic endothelial cell loss may be the first event leading to atherosclerosis.

In this study we test the proposition that chronic, chemically induced endothelial cell injury produces arteriosclerosis through platelet-mediated intimal proliferation of smooth muscle cells and that drug-induced platelet dysfunction is capable of preventing the smooth muscle proliferative response.

Received for publication 18 December 1975 and in revised form 15 April 1976.

METHODS

Baboon homocysteine vascular model. 34 normal male baboons (*Papio cynocephalus*) were studied: 8 controls, 15 chronic homocysteine infusion animals, and 11 animals receiving both chronic homocysteine infusions and dipyridamole. The animals weighed 10–12 kg and had hematocrits of $40\pm 3\%$, leukocyte counts of $5,000\pm 1,200/\mu\text{l}$, and platelet counts of $279,000\pm 59,000/\mu\text{l}$. They were free of tuberculosis, dewormed, and observed to be disease-free for at least 6 wk before use. To facilitate continuous intravenous infusion and repeated blood sampling, the animals were maintained in restraining chairs during the period of observation. In addition, a femoral arteriovenous Silastic shunt was used, 0.24 cm internal diameter and 25 cm in length, with Dacron sewing cuffs at skin exit sites (12–14).

A solution of *l*-homocysteine (Aldrich Chemical Co., Inc., Milwaukee, Wis.) or a control solution alone was infused continuously by femoral AV shunt throughout a 3-mo period using a roller infusion pump (Holter pump, model 921, Extracorporeal Medical Specialties, Inc., King of Prussia, Pa.) and a T-tube connector. 0.3 g of homocysteine per kg body weight was infused per day (3 g dissolved in 100 ml 0.15 M NaCl solution at pH 7.4 and sterilized by filtration). The homocysteine infusion was given at a rate of about 4 ml/h and produced plasma homocysteine levels of 0.1–0.2 mM due to the endogenous transformation of homocysteine to homocystine. Homocysteine concentrations were measured each week. Platelet and fibrinogen concentration, survival and turnover, were measured before and at monthly intervals during the infusion period. Plasma cholesterol levels were obtained before the infusion studies and before sacrifice.

Treatment. Dipyridamole was given orally to 11 animals throughout the 3-mo period of homocysteine infusion in doses of 30 mg/kg per day (in three divided doses). This dose, which is a threefold increase over that used in the acute studies (14), was required to normalize the platelet consumption produced by the level of chronic homocystinemia used in this study.

Laboratory studies. Platelet counts were measured with an electronic particle counter on peripheral blood collected in EDTA by a previously described method (15, 16). The mean platelet count of 50 normal baboons was $279,000\pm 59,000/\mu\text{l}$ (± 1 SD). Platelet survival was determined from the disappearance of radioactivity from blood sampled 5–10 times after injection of autologous ^{51}Cr -labeled platelets (14, 16). In this procedure 100 ml autologous whole blood was collected directly into a plastic plasma pack (Fenwall TA-6, Fenwall Laboratories, Inc., Morton Grove, Ill.) containing 20 ml ACD anticoagulant, and centrifuged at 200 *g* for 10 min at room temperature. The supernatant, platelet-rich plasma was transferred to a second transfer bag by a plasma extractor, and the pH was adjusted to 6.5 with 0.15 M citric acid (about 0.1 ml/10 ml plasma). Platelets were then formed into a pellet by centrifuging at 3,000 *g* for 15 min. The supernatant plasma was removed except for 2–3 ml residual plasma into which the platelets were carefully resuspended. This platelet suspension was then incubated with 50 μCi of radiochromium (New England Nuclear, Boston, Mass.) for 20 min. About 40 ml nonradioactive platelet-poor plasma and about 50 ml sterile air were then added, and the pellet reformed by centrifuging at 3,000 *g* for 15 min. The residual radioactive platelet-poor plasma was completely decanted without disturbing the pellet. 10 ml nonradioactive platelet-poor plasma was carefully layered over the platelet pellet and then discarded by decantation.

This maneuver washed the bag of more than 95% of the residual nonplatelet-bound ^{51}Cr . The presence of air in the bag facilitated this step by maintaining the overall configuration of the bag during decantation. The labeled platelet pellet was gently suspended in about 2 ml nonradioactive platelet-poor plasma. Contaminating erythrocytes were largely removed by a final slow centrifugation of 100 *g* for 5 min. A known amount of ^{51}Cr -labeled platelet suspension was administered to the animal by intravenous injection after the preparation of a standard. 3-ml samples of whole blood, collected in EDTA twice daily for 3 days and daily for an additional 3 days, were lysed with 0.1 ml sodium dodecyl sulfate and counted for radioactivity in a gamma spectrometer (Nuclear-Chicago, Des Plaines, Ill.). Platelet survival time was determined by computer least squares fitting to a gamma function as described by Paulus (17) and Murphy et al. (18–20). The proportion of labeled platelets remaining within the systemic circulation after infusion (i.e., "recovery") was calculated from the platelet activity per milliliter extrapolated to zero time, multiplied by the estimated blood volume, and divided by the platelet ^{51}Cr activity injected. Platelet consumption, measured as platelet turnover per microliter of blood per day, was calculated from the peripheral platelet count divided by the platelet survival time in days and corrected for recovery. In 24 normal male baboons, platelet survival was 5.5 ± 0.3 days. Platelet recovery averaged $85\pm 5\%$ and platelet turnover was $59,000\pm 7,000$ platelets/ μl per day.

For calculating fibrinogen turnover, the concentration of fibrinogen was estimated by a spectrophotometric method in which the optical density of thrombin-clottable protein was determined after collection on a glass rod and subsequent solution in alkaline urea (21). The fibrinogen concentration in 24 normal animals was 2.71 ± 0.22 mg/ml. Labeling of normal fibrinogen with ^{125}I was performed by the method of Takeda (22). This technique involved repeated precipitation of fibrinogen with 25% ammonium sulfate saturation followed by dissolving the precipitate in 0.005 M sodium citrate, labeling with [^{125}I]Cl (monoiodochloride) and removal of unbound ^{125}I . The solution was maintained at 4°C for 1 h and then centrifuged at 20,000 *g* for 30 min at 4°C to remove any cryoprecipitable material. It was sterilized by filtration. In our preparations, the molar ratio of iodine to fibrinogen was always less than 0.25; the fibrinogen was 95% clottable (range, 92–98%). For survival measurements sufficient labeled fibrinogen was prepared for several months use. Individual doses were flash frozen and stored at -85°C . Survival did not change significantly during the time of storage. Fibrinogen survival, determined from the half-time disappearance and divided by the natural logarithm of 2, averaged 2.6 ± 0.2 days in 24 normal animals. Fibrinogen turnover, used as a measure of fibrinogen consumption, was calculated from the concentration of plasma fibrinogen divided by its mean survival time. In 24 normal animals fibrinogen turnover averaged 1.00 ± 0.10 mg/ml per day.

Platelet function was measured by bleeding time, glass-bead retention test, and aggregation induced by ADP (0.5, 1.0, 1.5, 2.0, and 10.0 μM final concentration), collagen (5 $\mu\text{g}/\text{ml}$), and epinephrine (2.5 $\mu\text{g}/\text{ml}$). The bleeding time was measured by the standardized template technique (23), the mean value in 24 normal baboons was 4.0 ± 1.2 min. Platelet retention by glass-bead columns was measured by the Bowie modification of the Salzman method (24), blood being drawn by a two-syringe technique without anticoagulant and immediately passed through the standard column of beads by constant infusion at the rate of 2 ml/min. The

delay between drawing and initiation of flow through the beads was less than 10 s. Platelet aggregation was estimated from changes in optical transmission of 0.02 M sodium citrated plasma at 37°C with a concentration of 300,000 platelets/ μ l (14, 25, 26). Plastic equipment was used throughout, and plasma freshly drawn was kept at room temperature during the 30–70 min before testing.

Homocystine was quantified by column chromatography using a modified procedure of Spackman et al. (27). Plasma samples were deproteinized by addition of an equal volume of 6% sulfosalicylic acid buffered to pH 2. Homocystine was separated on a 55-cm column of PA28 resin (Beckman Instruments, Inc., Palo Alto, Calif.) with use of 0.38 M sodium citrate buffer at pH 4.40. Temperature was maintained at 62°C with a buffer flow rate of 60 ml/h and the amino acid was eluted 62 min after addition of buffer. Homocystine is not detectable in the plasma of normal animals.

Morphological procedures. Three types of vessel preparation were obtained: (a) lower abdominal aorta, iliac and femoral arteries for light and electron microscopic examination of lesion formation; (b) carotid arteries for [3 H]thymidine incorporation by endothelial cells; (c) thoracic and upper abdominal aorta for silver stain quantitation of endothelial coverage. Specimens were obtained under general (halothane) anesthesia and assisted respiration in the following way. After opening the abdomen, the aorta and inferior vena cava were carefully freed by sharp dissection without affecting flow. The inferior vena cava was then cannulated to establish isolated venous drainage from the lower limbs and immediately thereafter the aorta was cannulated, flushed free of blood elements with 5% glucose solution at 100 mm Hg of hydrostatic pressure, and perfuse-fixed with buffered half-strength Karnovsky's fixative (28) under 100 mm Hg pressure for 20 min in vivo. Once perfusion fixation of the distal arteries was underway, the carotid arteries were freed by sharp dissection, isolated, and carefully removed. The artery segments were gently flushed free of blood with saline, and excess adventitia removed for [3 H]thymidine studies. Immediately after removing the carotid arteries, the chest was entered (thereby interrupting respiration), the arch of the aorta quickly cannulated, and drainage outflow was established above the renal arteries. The aorta was then cleared of blood using 5% glucose solution at 100 mm Hg pressure. In vivo fixation was then carried out by perfusion-fixation of the thoracic and upper abdominal aorta with 0.3% silver nitrate solution at a pressure of 100 mm Hg for 20 min (29). After perfusion-fixation, the vessels were removed by sharp dissection. The foregoing procedure ensured the procurement of three different artery preparations from a single living animal while using isolated regional pressure-perfusion fixation.

Intimal lesion score. At the time of sacrifice the aorta was cannulated below the renal vessels, flushed free of blood with 5% glucose solution, and then perfuse-fixed with buffered half-strength Karnovsky's fixative (28) under 100 mm Hg hydrostatic pressure for 20 min in vivo. Vessels were subsequently removed by sharp dissection and placed in half-strength Karnovsky's fixative for 6 h at 4°C. Segments from abdominal aorta, and each iliac artery were removed for scanning electron micrographs. The remaining vascular tissues were subsequently cut into approximately 1-mm rings and returned to the fixative for another hour at 4°C. They were then washed in 0.1 M cacodylate buffer containing 0.2 M sucrose (pH 7.3) and subsequently post-fixed in 1% osmium tetroxide buffered with ϵ -collidine or

with phosphate buffer (pH 7.3) for 1½ h, followed by en bloc staining with 2% uranyl acetate for ½ h. After embedding in epoxy resin, 1- μ m thick sections were cut as circles, and stained with a combination of basic fuchsin and azure II-methylene blue for light microscopy (30). Selected thin sections were cut at approximately 800 Å thickness for transmission electron microscopy. These sections were stained with lead citrate followed by uranyl acetate. All of the sections for electron microscopy were examined in an AEI801 electron microscope (AEI Scientific Apparatus Inc., Elmsford, N. Y.).

Five random sections were prepared for each of five vessels (abdominal aorta, right and left iliac arteries, right and left femoral arteries) for light microscopic scoring of intimal lesions. The lesions were graded by two observers in a 'blind' manner according to the cell layer depth of intimal smooth muscle cells: grade 0—only occasional intimal smooth muscle cells; grade 1—1–5 cells deep; grade 2—6–10 cells; grade 3—11–15 cells; grade 4—16–20 cells; grade 5—>20 cells deep. The overall score was calculated for each animal by summing the scores of all 25 sections examined (possible range of scores was 0–125).

[3 H]Thymidine labeling index. Both carotid arteries were removed by sharp dissection, flushed with saline, and cut into 20-mm lengths. Whole segments were placed in 3–4 ml medium TC 199 containing 1 μ Ci [3 H]thymidine/ml and incubated at 37°C for 4 h. The vessel segments were removed, trimmed, opened longitudinally, and mounted flat for fixing 24 h in 10% neutral buffered formaldehyde (31). The endothelium was prepared for autoradiography by the method of Schwartz and Benditt (32) which involved the following procedures. The luminal surface of the specimen was embedded in collodion onto a slide leaving the adventitial surface exposed. The adventitial surface was then embedded in gelatin and bonded to a gelatin-coated slide by fixation with formaldehyde while the specimen and the coated slide were held together under pressure. Subsequently the collodion overlying the endothelial cells was removed with ether and alcohol thereby exposing the luminal surface of endothelial cells for coating with autoradiographic emulsion. Autoradiography was performed by hand dipping endothelial mounts in Kodak NTB-2 emulsion, 2-wk exposure, followed by Kodak D-19 developer and rapid fixer (Eastman Kodak Co., Rochester, N. Y.). The preparations were stained with Harris' hematoxylin and mounted.

About 80% of the mounts were complete, containing over 90% of the endothelial cells intact and countable. All of the endothelial cells from each mount, i.e., 15,000 cells each, were scored as labeled or unlabeled, and the [3 H]thymidine labeling index represented the ratio of these values expressed as a percentage.

Endothelial cell loss. Pressure-perfusion fixation was carried out on the thoracic and upper abdominal aorta with 0.3% silver nitrate solution at the time of sacrifice in vivo. The entire endovascular surface of whole-aorta mounts was then examined morphometrically by means of a grid micrometer, and the proportion of the surface not covered by endothelial cells was determined.

RESULTS

Endothelial cell injury. Endothelial cell coverage was completely intact (Fig. 1a) in the eight control animals when the vessels were prepared by pressure-perfusion fixation in vivo using either 0.3% AgNO₃ staining or scanning electron microscopy. Patchy endothelial cell

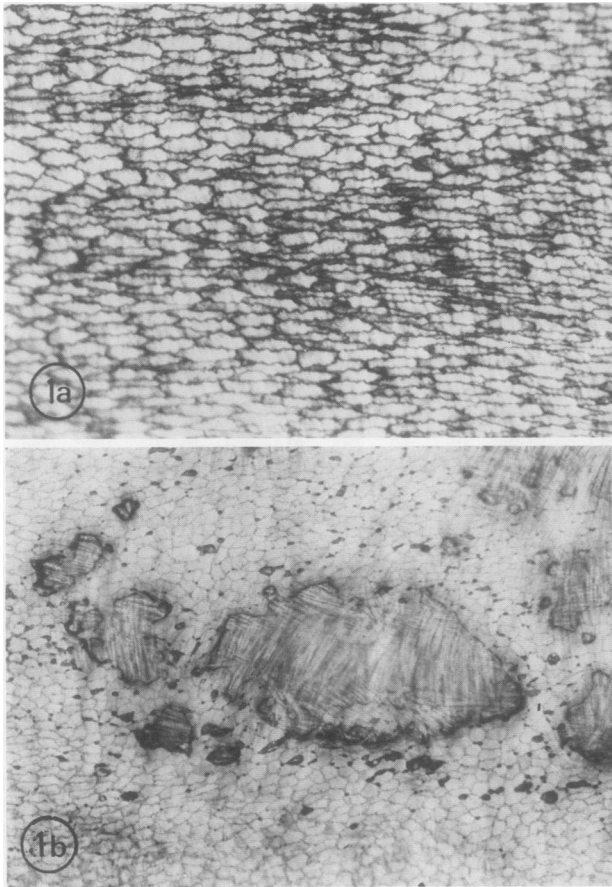


FIGURE 1 (a) Light micrograph demonstrating an *en face* view of the aortic endothelium of a control baboon that was perfuse-fixed with 0.3% silver nitrate. The longitudinal direction and the intact state of the endothelial cells can be clearly seen in this micrograph. The edges of the micrograph are out of focus because of curvature of the vessel. Magnification $\times 220$. (b) The aorta of a baboon that was homocystinemic for 3 mo. The patchy loss of the endothelium, and individual discrete areas of intense staining with silver nitrate demonstrate both focal desquamation of the endothelium, individual cell loss, and sites of alterations in the junctions between the cells. Magnification $\times 200$.

loss was observed in all animals made homocystinemic by continuous infusions of homocysteine (Fig. 1b). When viewed by scanning electron microscopy, platelets were found to accumulate at some sites of endothelial cell loss (Fig. 2), although platelets were not regularly observed on the chronically denuded areas when prepared by silver staining for direct microscopic examination. The overall loss of aortic endothelium in the group of 15 homocystinemic animals averaged $9.6 \pm 2.2\%$ ¹ of the aortic surface and corresponded with a mean plasma homocystine concentration before sacrifice of 0.17 ± 0.01 mM (Table I). A linear relationship was observed be-

¹ In results variation about the mean is given at ± 1 SEM.

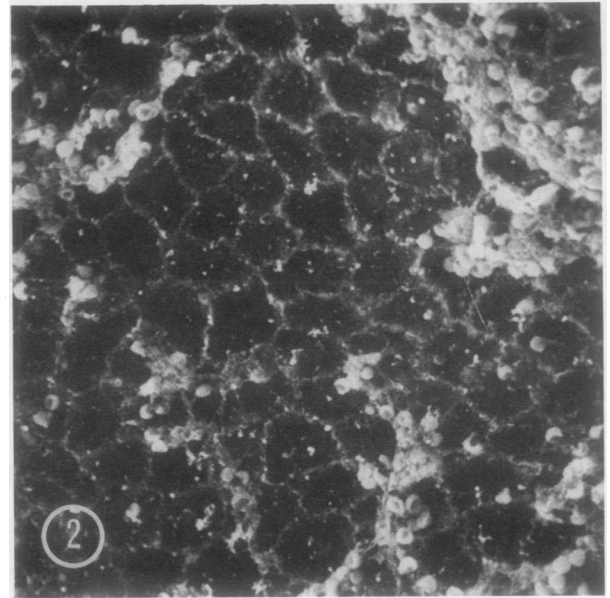


FIGURE 2 Scanning electron micrograph of an area of endothelial desquamation with adherent platelets and erythrocytes at these foci in an homocystinemic animal. The individual platelets are obscured in the micrograph due to the relatively low magnification. However, their size can be estimated by comparing them with the erythrocytes which are clearly visible. Magnification $\times 500$.

tween endothelial cell loss and homocystine concentration (Fig. 3) with $r = 0.965$. The regression line, represented by $y = 88.5x - 5.23$, had an SD of 2.001, and

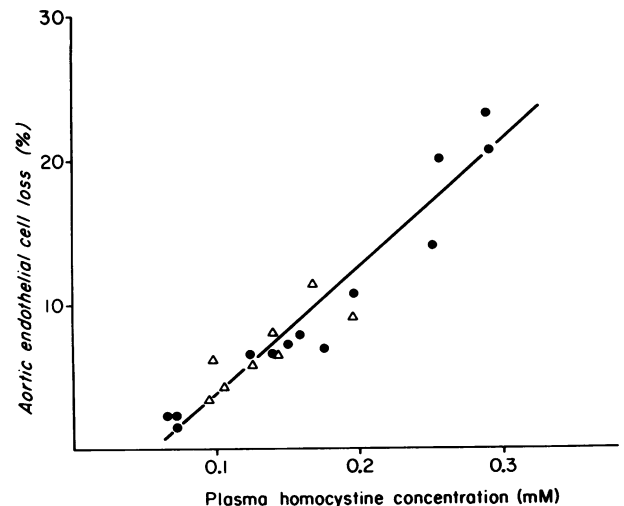


FIGURE 3 Correlation between homocystine level and endothelial cell loss. The desquamation of aortic endothelial cells was directly related to the plasma concentration of homocystine (●) with $r = 0.965$ and $P < 0.001$. The computed regression line is shown ($y = 88.5x - 5.23$). Dipyridamole treatment (Δ) did not alter the relationships between homocystine concentration and endothelial cell desquamation.

TABLE I
Homocystine-Induced Endothelial Cell Desquamation, Platelet Consumption, and Endothelial Regeneration

Baboons	Plasma homocystine concentration mM	Endothelial cell loss %	Platelet		[³ H]thymidine-labeling index %
			Survival days	Turnover plat/ μ /day	
Control (8)	<0.001	0	5.4 \pm 0.1*	63,000 \pm 4,000	0.0011 \pm 0.0001
Homocystinemic (15)	0.170 \pm 0.019	9.6 \dagger \pm 2.2	2.8 \dagger \pm 0.3	183,000 \dagger \pm 17,000	0.0296 \dagger \pm 0.0087
Dipyridamole-treated homocystinemic (11)	0.127 \pm 0.011	7.0 \dagger \pm 0.9	4.8 \pm 0.2	76,000 \pm 11,000	0.0162 \dagger \pm 0.0051

* Variation about the mean given as ± 1 SE.

\dagger Significantly different from base line at $P < 0.001$.

an SD of slope and intercept of 7.205 and 1.359, respectively.

In the 11 homocystinemic animals treated with oral dipyridamole (30 mg/kg per day), 7.0 \pm 0.9% of the aortic endothelial cells was absent with a mean plasma homocystine concentration before sacrifice of 0.13 \pm 0.01 mM (Table I). The relationship between homocystine level and endothelial cell desquamation was not changed by dipyridamole treatment ($P > 0.75$).

Platelet consumption. Platelet survival in the homocystinemic animals was reduced to 2.8 \pm 0.3 days compared with 5.4 \pm 0.1 days in the control group (Table I). Reciprocally, platelet turnover was increased threefold in the homocystinemic animals, i.e., 183,000 \pm 17,000 platelets/ μ l per day compared with 63,000 \pm 4,000 platelets/ μ l per day in the control group. Platelet survival times were related to the logarithm of the homocystine concentration (Fig. 4A). $r = 0.965$, $P < 0.001$, and the regression line was represented by $y = 0.453e^{-0.368x}$.

Determinations of platelet survival also correlated with the logarithm of aortic endothelial cell loss (Fig. 4B). $r = 0.958$, $P < 0.001$, and the regression line was represented by $y = 44.0e^{-0.647x}$.

Platelet survival times were significantly prolonged by dipyridamole treatment (4.8 \pm 0.2 days compared with 2.8 \pm 0.3 days, $P < 0.001$) despite continued homocystinemia (Fig. 4A and 4B). Platelet turnover was also returned to near normal values (Table I, $P < 0.001$).

In homocystinemic animals fibrinogen survival and turnover were not changed significantly from control values, i.e., 2.4 \pm 0.2 days and 1.2 \pm 0.2 mg/ml per day, respectively, compared with 2.5 \pm 0.2 days and 1.1 mg/ml per day in control animals. Fibrinogen kinetics were not altered by dipyridamole treatment (2.4 \pm 0.2 days and 1.3 \pm 0.3 mg/ml per day, respectively).

Platelet aggregation to ADP, epinephrine, and collagen was not significantly different in six dipyridamole-treated animals compared with six untreated homocystinemic animals. Similarly, the bleeding time was not significantly prolonged by dipyridamole therapy (4.8 \pm 2.5 min compared with 4.2 \pm 2.0 min). However, dipyridamole treatment reduced platelet retention by

glass-bead columns from 43 \pm 12% retained in homocystinemic animals to 26 \pm 9% in treated animals ($P < 0.05$).

Endothelial cell regeneration. In control animals the [³H]thymidine-labeling index of endothelial cells averaged 0.0011 \pm 0.0001%. Animals with induced homocystinemia showed a greater than 25-fold increase in the endothelial cells incorporating [³H]thymidine, i.e., 0.0296 \pm 0.0087%, $P < 0.001$. Dipyridamole-treated animals had a 15-fold increase in [³H]thymidine-labeling index (0.0162 \pm 0.0051%, $P < 0.001$).

Intimal lesion formation. For every animal studied, five random sections from each of five different arteries were graded 0–5 (see Methods). Single intimal smooth muscle cells were occasionally observed in control animals (Fig. 5, scores averaged 4 \pm 1, range 1–9).

All of the homocystinemic animals developed eccentric fibromusculoelastic lesions (Fig. 6). 5–10% of the proliferation regions contained intracellular lipid or foam cells deep in the lesions. The intimal lesion scores for

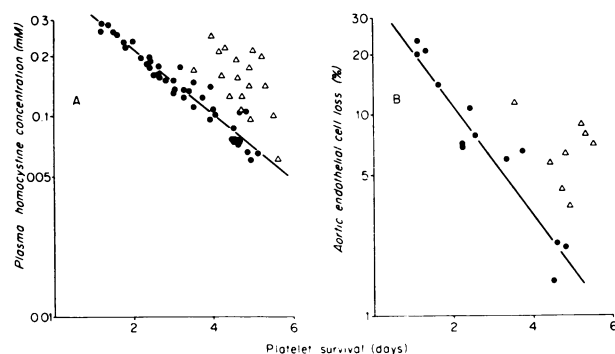


FIGURE 4 The relationships of platelet survival and plasma homocystine level and endothelial cell loss. Platelet survival time correlated with the logarithm of the plasma homocystine concentration (●, Fig. 4A) with $r = 0.965$, $P < 0.001$, and regression line represented by $y = 0.453e^{-0.368x}$. Measurements of platelet survival time also correlated with the logarithm of endothelial cell loss (●, Fig. 4B) with $r = 0.958$, $P < 0.001$, and a regression line represented by $y = 44.0e^{-0.647x}$. Dipyridamole treatment (Δ) produced significant prolongation of platelet survival ($P < 0.001$).




FIGURE 5 A light micrograph of a section of the iliac artery of a control animal that was fixed and prepared for electron microscopy, embedded in epoxy resin, and sectioned at 1 μm thickness. The thin intima is demarcated by the internal elastic lamina (arrow). The endothelial cells (e) are barely visible. The media (m) and adventitia (a) are clearly visible in this micrograph. Magnification $\times 220$.

the homocystinemic animals averaged 63 ± 5 , range 35–98 (Table II). The lesion score correlated directly with the overall mean homocystine concentration (Fig. 8). $r = 0.956$, $P < 0.001$, and the regression line was $y = 0.375x - 12.7$.

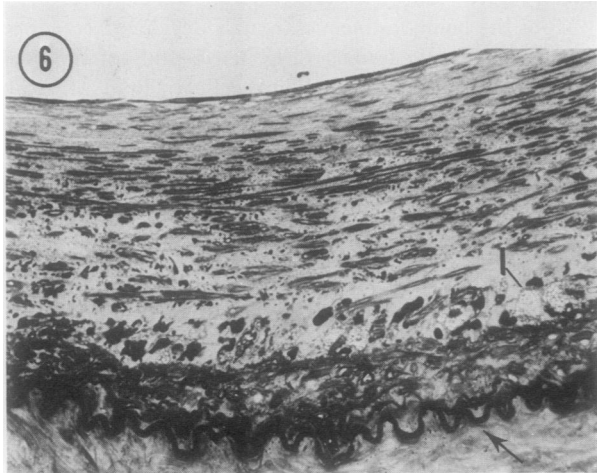


FIGURE 6 A light micrograph with magnification comparable with that of Fig. 5 and demonstrating a characteristic lesion seen in the homocystinemic animals. The internal elastic lamina (arrow) is present at the bottom of this micrograph, and the lumen of the vessel at the top. In comparison with Fig. 5, it can be seen that the intima occupies essentially all of this micrograph demonstrating the marked increase in thickness, smooth muscle proliferation, and connective tissue formation that has occurred. Several lipid-laden cells (1) are present near the base of this lesion. A small portion of the media is present at the bottom of the micrograph. Magnification $\times 220$.

TABLE II

Prevention of Intimal Smooth Muscle Proliferative Lesions

Baboons	Aortic endothelial cell loss	Intimal lesion score
	%	
Control (8)	0	$4 \pm 1^*$
Homocystinemic (15)	$9.6 \dagger \pm 2.2$	$63 \dagger \pm 5$
Dipyridamole treated (11)	$7.0 \dagger \pm 0.9$	16 ± 2

* Variance given as ± 1 SE.

† Different from controls at $P < 0.001$.

The fine structure of the lesions (Fig. 9) was typical of early lesion formation similar to the fibromusculo-elastic lesions in man (9). They demonstrated the presence of numerous smooth muscle cells surrounded by large amounts of small collagen fibers and elastic fibers rich in microfibrils, suggesting that the elastic fibers were relatively immature (33). In many regions the luminal surface of the lesions had no endothelial cell cover, while in other regions cells appeared to be in the process of attempting to cover the surface.

Effect of dipyridamole on intimal lesion formation. In the group of 11 animals receiving oral dipyridamole throughout the 3-mo period of homocystinemia, the mean intimal lesion score was 16 ± 2 (range 7–25), compared with 4 ± 1 in control animals and 63 ± 5 in untreated homocystinemic animals (Figs. 7 and 8, Table II). The difference in the intimal lesion scores between the dipyridamole-treated and untreated homocystinemic




FIGURE 7 A light micrograph of a segment of the iliac artery of a homocystinemic-dipyridamole treated animal (cf. Figs. 5 and 6). It can be seen that the intima is nearly as thin as that of the control animal, and that the media and adventitia are both visible in this micrograph in comparison with the markedly thickened intima demonstrated in the homocystinemic animals in Fig. 6. Magnification $\times 220$.

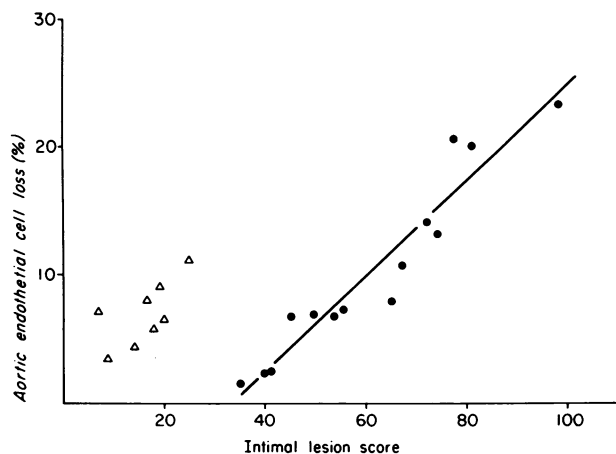


FIGURE 8 The formation of intimal smooth muscle lesions and endothelial cell desquamation. A linear relationship was observed between the intimal proliferative lesion score and the loss of aortic endothelial cells (●). $r = 0.956$, with significance of $P < 0.001$. The regression line was represented by $y = 0.375x - 12.7$. Dipyridamole treatment (△) markedly reduced the intimal lesion score ($P < 0.001$).

animals was significant at $P < 0.001$. This effect corresponded with the dipyridamole interruption of platelet consumption but was observed despite the absence of aortic endothelial cells (Table I). The intimal lesion score in the dipyridamole-treated animals (Fig. 7) is, however, also significantly greater than in control animals ($P < 0.01$).

Serum cholesterol concentrations for the control, homocystinemic, and treated group were 99 ± 6 , 106 ± 7 , 96 ± 6 , respectively. No correlation was observed in these animals between cholesterol levels and either lesion scores or the presence of lipid within the lesions.

DISCUSSION

The effects of homocystine. This study was designed to clarify the mechanism responsible for the markedly accelerated atherosclerosis found in patients with chronic homocystinemia. The clinical syndrome of homocystinuria, an inborn deficiency of cystathionine synthase is characterized by atherosclerotic occlusion of myocardial, cerebral, renal, and pulmonary arteries, often resulting in fatal infarction before the 3rd decade of life (34–39). It has been reported on the basis of repeated subcutaneous injection of homocystine into rabbits that homocystine stimulates the synthesis of connective tissue elements in the artery wall. These studies, however, have been difficult to reproduce presumably because of the lack of continuous homocystinemia (40–42).

In an earlier acute study continuous-infusion homocystinemia in primates was shown to induce patchy loss of arterial endothelium (14). The present study demonstrates that homocystinemia maintained over 3 mo produces sustained endothelial cell loss in proportion to the

level of plasma homocystine when the concentration exceeds about 0.06 mM (Fig. 3). The inability to detect measurable deficiencies in endothelial cell coverage at lower homocystine concentrations may be explained by compensatory coverage achieved by increased endothelial regeneration (Table I).

Although we find no evidence to implicate hypercholesterolemia or hypertriglyceridemia in homocystine-induced lesions, the importance of lipids in the genesis of atherosclerosis has long been emphasized (4) but poorly understood. Clearly, lipid accumulation, both within the smooth muscle cells and in the surrounding matrix, is important in preventing lesion regression (10). Both the smooth muscle cells and the matrix proteoglycans they form have a marked affinity for lipoproteins (43). Of equal interest are observations suggesting that chronic (9 mo or longer) sustained hypercholesterolemia will result in endothelial "injury" and focal denudation similar to that observed in the homocystinemic animals in the present study (44). Thus, lipids may exert in part a similar effect to that seen in homocystinemia.

The role of platelets in lesion formation. Platelets accumulate on exposed subendothelial connective tissue surface by adhesion and aggregation to form platelet thrombi (45–48). Adherent platelets undergo the release reaction as evidenced morphologically by degranulation (6, 45–51). At least one constituent released from platelets is a mitogenic factor that stimulates the proliferation of smooth muscle cells (11). This platelet factor was initially discovered from the observation that arterial smooth muscle cells in culture neither synthesize DNA nor divide in medium containing serum made from platelet-free plasma. In contrast, medium containing whole blood serum, or platelet-free plasma serum containing a supernate derived from exposure of a plasma-free preparation of platelets to purified thrombin, are identical in their ability to elicit a mitogenic response from the cells (11).

The present studies provide *in vivo* evidence that platelets are important in the process of arteriosclerosis by demonstrating that platelet consumption correlates with intimal lesion formation and that the interruption of platelet consumption using a known inhibitor of platelet function prevents lesion formation. Interestingly, direct morphology evidences only minimal platelet accumulation at sites of chronic endothelial loss which is also in accord with the late findings after mechanical desquamation (46, 48).

The role of platelets in atherogenesis is further evidenced by several additional recent studies. Moore et al. (52) were able to prevent arteriosclerotic lesion formation induced by chronic indwelling arterial catheters in animals made severely thrombocytopenic with



FIGURE 9 An electron micrograph of a portion of one of the lesions observed in the homocystinemic animals. The junction between the two lining cells which may be endothelium is incomplete (arrow). Beneath the lining luminal cells can be seen numerous smooth muscle cells that have proliferated within the lesion. These are surrounded by large numbers of collagen fibrils (c) and newly formed elastic fibers (el). Magnification $\times 8,500$.

antiplatelet serum. Similarly, Friedman and Stemmerman (personal communication) prevented balloon catheter-induced lesion formation by severe thrombocytopenia. And finally, a retrospective study in pigs affected with von Willebrand's disease, a genetic defect in platelet-surface interaction (53), reported a reduced frequency of atherosclerosis in the adult animals (54).

The intimal proliferative smooth muscle lesion contains the connective tissue matrix components of elastic fibers, collagen, and glycosaminoglycans, all of which

are secretory products of the proliferating smooth muscle cells (55, 56). This lesion is characteristic of arteriosclerosis. The intra- and extracellular accumulations of lipid by intimal smooth muscle cells and concomitant formation of connective tissue appear to be facilitated by disruption of the endothelial cell barrier and exposure of the artery wall to platelets and plasma factors.

Role of antiplatelet agents. Inhibition of platelet adhesion, aggregation, and release are variably produced

by a wide variety of pharmacologic agents (50, 51, 57-59). These include a group of nonsteroidal anti-inflammatory drugs such as acetylsalicylic acid and sulfinpyrazone. Although their mode of action has not yet been fully determined, these drugs characteristically inhibit the platelet release reaction and the secondary phase of ADP or epinephrine-induced aggregation with little or no effect on primary ADP aggregation. These drugs appear to be less useful for interrupting adhesion-related effects, e.g., acetylsalicylic acid fails to reduce the adhesion and degranulation of platelets to subendothelium (53). Correlation between in vitro effects on platelet function tests and in vivo antithrombotic effects is variable. For example, in man treatment with sulfinpyrazone normalizes platelet survival and reduces thrombus formation without showing any measurable effect on in vitro tests of platelet function (60).

A second group of drugs, the pyrimido-pyrimidine compounds, inhibits both primary and secondary ADP- or epinephrine-induced aggregation and platelet release, aggregation induced by thrombin or collagen, and platelet retention by glass-bead columns. These drugs appear to affect platelet cAMP by enhancing adenylcyclase and inhibiting phosphodiesterase activity (50, 51, 57-59). Included in this class of agents is dipyridamole. Interestingly, dipyridamole interrupts platelet consumption and thromboembolism in man at concentrations that do not effect platelet function tests in vitro (61, 62). This discrepancy between in vivo and in vitro effects is further evidenced by a recent comparison of in vivo and in vitro collagen-induced platelet aggregation that showed the inhibitory effect of dipyridamole in vivo to be enhanced many times over that observed in vitro (63).

Consideration must be given to the possibility that dipyridamole may have produced its beneficial effect on lesion formation by protecting the endothelium from injury, by modifying the thrombogenicity of the subendothelium, or by inhibiting the proliferation of smooth muscle cells. The data in Table I and Fig. 1 indicate that homocystine-induced endothelial cell loss remained quantitatively unchanged by dipyridamole therapy. The drug therefore appears to have no protective effect on the endothelium. Furthermore, smooth muscle cell proliferation also appears to be unaffected because smooth muscle cells proliferate normally in culture with dipyridamole concentrations as great as 10^{-5} M (unpublished observation). Since the only measurable effect of dipyridamole appears to be on platelet consumption, we conclude that the drug effect is mediated through platelet-related mechanisms. Our observation that dipyridamole-treated animals show reduced platelet retention by glass-bead columns suggests that the effect involves pharmacologic inhibition of platelet function rather than some alteration of the subendothelial surface.

On the basis of these studies we conclude that sustained chemically induced endothelial cell injury results in endothelial cell loss followed by platelet adherence and release and the development of progressive intimal arteriosclerotic lesions. The fundamental role of platelets in the genesis of these lesions is demonstrated by the capacity of an inhibitor of platelet function to prevent intimal smooth muscle proliferation, and consequent lesion formation. These observations imply potential therapeutic benefit of antiplatelet drugs in the prevention or interruption of atherogenesis in man.

ACKNOWLEDGMENTS

We are indebted to Tom Kirkman, Norma Joy, Beverly Kariya, and Cellini Chen for their technical assistance which made this study possible. We also wish to thank Drs. Hazard and Kushwaha of the Northwest Lipid Research Clinic for performing the cholesterol determinations according to standardized, equality-controlled Lipid Research Clinic procedures (Lipid Research Clinics Program, Manual of Laboratory Operations. 1974. Volume 1).

Statistical analysis was carried out through the PROPHET System developed by the Chemical Biological Information Handling Program of the Biotechnology branch of the Division of Research Resources, National Institute of Health.

This work was supported by research grants (HL-11775, RR-00166 HL-14832, HL-14860, and HD-04665) from the U. S. Public Health Service.

REFERENCES

1. Geer, J. C., C. Catsulis, H. C. McGill, Jr., and J. P. Strong. 1968. Fine structure of the baboon aortic fatty streak. *Am. J. Pathol.* **52**: 265-286.
2. Armstrong, M. L., E. D. Warner, and W. E. Connor. 1970. Regression of coronary atheromatosis in rhesus monkeys. *Circ. Res.* **27**: 59-67.
3. Ross, R., and J. Glomset. 1973. Atherosclerosis and the arterial smooth muscle cell. Proliferation of smooth muscle is a key event in the genesis of the lesions of atherosclerosis. *Science (Wash. D. C.)*. **180**: 1332-1339.
4. Wissler, R. W. 1974. Development of the atherosclerotic plaque. In *The Myocardium: Failure and Infarction*. E. Braunwald, editor. New York, HP Publishing Co., 155-166.
5. Baumgartner, H.-R., and A. Studer. 1966. Folgen des Gefässkatheterismus an normo- und hypercholesterinaemischen Kaninchen. *Pathol. Microbiol.* **29**: 393-405.
6. Stemerman, M. B., and R. Ross. 1972. Experimental arteriosclerosis. I. Fibrous plaque formation in primates: An electron microscope study. *J. Exp. Med.* **136**: 769-789.
7. Björkerud, S., and G. Bondjers. 1971. Arterial repair and atherosclerosis after mechanical injury. Part I. Permeability and light microscopic characteristics of endothelium in non-atherosclerotic and atherosclerotic lesions. *Atherosclerosis*. **13**: 355-363.
8. Christensen, B. C., and C. Garbarsch. 1973. Repair in arterial tissue. A scanning electron microscopic (SEM) and light microscopic study on the endothelium of rabbit thoracic aorta following a single dilatation injury. *Virchows Arch. Pathol. Anat. Physiol. klin. Med.* **360**:A: 93-106.
9. National Heart and Lung Institute Task Force on Arteriosclerosis. Arteriosclerosis. June 1971. Department

- of Health, Education and Welfare Publ. No. 72-219. National Institutes of Health, Bethesda, Md. 2: 4-27.
10. Ross, R., and J. Glomset. 1974. Studies of primate arterial smooth muscle cells in relation to atherosclerosis. *In Arterial Mesenchyme and Arteriosclerosis*. W. D. Wagner and T. B. Clarkson, editors. Plenum Publishing Corp., New York. 265-279.
 11. Ross, R., J. Glomset, B. Kariya, and L. Harker. 1974. A platelet-dependent serum factor that stimulates the proliferation of arterial smooth muscle cells *in vitro*. *Proc. Natl. Acad. Sci. U. S. A.* 71: 1207-1210.
 12. Storb, R., H. Ragde, and E. D. Thomas. 1969. Extracorporeal irradiation of the blood in baboons. *Radiat. Res.* 38: 43-54.
 13. Slichter, S. J., and L. A. Harker. 1971. Studies of platelet destruction due to prosthetic arterio-venous cannulae. *Clin. Res.* 19: 135. (Abstr.)
 14. Harker, L. A., S. J. Slichter, C. R. Scott, and R. Ross. 1974. Homocystinemia. Vascular injury and arterial thrombosis. *N. Engl. J. Med.* 291: 537-543.
 15. Bull, B. S., M. A. Schneiderman, and G. Brecher. 1965. Platelet counts with the Coulter counter. *Am. J. Clin. Pathol.* 44: 678-688.
 16. Harker, L. A., and C. A. Finch. 1969. Thrombokinetics in man. *J. Clin. Invest.* 48: 963-974.
 17. Paulus, J. M., editor. 1971. Platelet Kinetics: Radioisotopic, Cytological, Mathematical and Clinical Aspects. New York, American Elsevier Publishing Co., New York. 38-117.
 18. Murphy, E. A., and M. E. Francis. 1971. The estimation of blood platelet survival. II. The multiple hit model. *Thromb. Diath. Haemorrh.* 25: 53-80.
 19. Murphy, E. A. 1971. The estimation of blood platelet survival. III. The robustness of the basic models. *Thromb. Diath. Haemorrh.* 26: 431-448.
 20. Murphy, E. A., M. E. Francis, and J. F. Mustard. 1972. The estimation of blood platelet survival. IV. Characteristics of the residual errors from regression. *Thromb. Diath. Haemorrh.* 28: 447-456.
 21. Jacobsson, K. 1955. Studies on the determination of fibrinogen in human blood plasma. *Scand. J. Clin. Lab. Invest.* 7 (Suppl. 14): 3-54.
 22. Takeda, Y. 1966. Studies of the metabolism and distribution of fibrinogen in healthy men with autologous ¹²⁵I-labeled fibrinogen. *J. Clin. Invest.* 45: 103-111.
 23. Harker, L. A., and S. J. Slichter. 1972. The bleeding time as a screening test for evaluation of platelet function. *N. Engl. J. Med.* 287: 155-159.
 24. Bowie, E. J. W., C. A. Owen, Jr., J. H. Thompson, Jr., and P. Didisheim. 1969. A test of platelet adhesiveness. *Mayo Clin. Proc.* 44: 306-308.
 25. Born, G. V. R., and M. J. Cross. 1963. The aggregation of blood platelets. *J. Physiol. (Lond.)*. 168: 178-195.
 26. Mustard, J. F., B. Hegardt, H. C. Rowsell, and R. L. MacMillan. 1964. Effect of adenosine nucleotides on platelet aggregation and clotting time. *J. Lab. Clin. Med.* 64: 548-559.
 27. Spackman, D. H., W. H. Stein, and S. Moore. 1958. Automatic recording apparatus for use in the chromatography of amino acids. *Anal. Chem.* 30: 1190-1206.
 28. Haudenschild, C., H. R. Baumgartner, and A. Studer. 1972. Significance of fixation procedure for preservation of arteries. *Experientia (Basel)*. 28: 828-831.
 29. Poole, J. C. F., A. G. Saunders, and H. W. Florey. 1958. The regeneration of aortic endothelium. *J. Pathol. Bacteriol.* 75: 133-143.
 30. Huber, J. D., F. Parker, and G. F. Odland. 1968. A basic fuchsin and alkalinized methylene blue rapid stain for epoxy-embedded tissue. *Stain Technol.* 43: 83-87.
 31. Sade, R. M., and J. Folkman. 1972. En face stripping of vascular endothelium. *Microvasc. Res.* 4: 77-80.
 32. Schwartz, S. M., and E. P. Benditt. 1973. Cell replication in the aortic endothelium: A new method for study of the problem. *Lab. Invest.* 28: 699-707.
 33. Greenlee, T. K., Jr., R. Ross, and J. L. Hartman. 1966. The fine structure of elastic fibers. *J. Cell. Biol.* 30: 59-71.
 34. Carson, N. A. J., D. C. Cusworth, C. E. Dent, C. M. B. Field, D. W. Neill, and R. G. Westall. 1963. Homocystinuria: A new inborn error of metabolism associated with mental deficiency. *Arch. Dis. Child.* 38: 425-436.
 35. Gerritsen, T., and H. A. Waisman. 1964. Homocystinuria: Absence of cystathionine in the brain. *Science (Wash. D. C.)*. 145: 588.
 36. Gibson, J. B., N. A. J. Carson, and D. W. Neill. 1964. Pathological findings in homocystinuria. *J. Clin. Pathol.* 17: 427-437.
 37. Carson, N. A. J., C. E. Dent, and C. M. B. Field, and G. E. Gaull. 1965. Homocystinuria: Clinical and pathological review of ten cases. *J. Pediatr.* 66: 565-583.
 38. Schimke, R. N., V. A. McKusick, T. Huang, and A. D. Pollack. 1965. Homocystinuria. Studies of 20 families with 38 affected members. *J. Am. Med. Assoc.* 193: 711-719.
 39. Uhlendorf, B. W., and S. H. Mudd. 1968. Cystathionine synthase in tissue culture derived from human skin: Enzyme defect in homocystinuria. *Science (Wash. D. C.)*. 160: 1007-1009.
 40. McCully, K. S. 1969. Vascular pathology of homocystinemia: Implications for the pathogenesis of arteriosclerosis. *Am. J. Pathol.* 56: 111-128.
 41. McCully, K. S. 1972. Macromolecular basis for homocysteine-induced changes in proteoglycan structure in growth and arteriosclerosis. *Am. J. Pathol.* 66: 83-95.
 42. Donahue, S., J. A. Sturman, and G. Gaull. 1974. Arteriosclerosis due to homocyst(e)inemia. Failure to reproduce the model in weanling rabbits. *Am. J. Pathol.* 77: 167-174.
 43. Iverius, P-H. 1972. The interaction between human plasma lipoproteins and connective tissue glycosaminoglycans. *J. Biol. Chem.* 247: 2607-2613.
 44. Harker, L. A., S. J. Slichter, and L. R. Sauvage. 1976. Platelet consumption by arterial prostheses: The effects of endothelialization and pharmacologic inhibition of platelet function. *N. Engl. J. Med.* In press.
 45. Mustard, J. F., R. L. Kinlough-Rathbone, and M. A. Packham. 1974. Recent status of research in the pathogenesis of thrombosis. *Thromb. Diath. Haemorrh.* Suppl. 59: 157-188.
 46. Baumgartner, H. R., and C. Haudenschild. 1972. Adhesion of platelets to subendothelium. *Ann. N. Y. Acad. Sci.* 201: 22-36.
 47. Stemerman, M. B. 1974. Vascular intimal components: Precursors of thrombosis. *In Progress in Hemostasis and Thrombosis*. T. H. Spaet, editor. Vol. 2. Grune & Stratton, Inc., New York. 1-47.
 48. Baumgartner, H. R. 1974. The subendothelial surface and thrombosis. *In Thrombosis: Pathogenesis and Clinical Trials*. E. Deutsch, K. M. Brinkhous, K. Lechner, and S. Hinnom, editors. F. K. Schattauer-Verlag, Stuttgart. 91-105.

49. White, J. G. 1972. Platelet morphology and function. *In* Hematology. W. J. Williams, E. Beutler, A. J. Erslev, and R. W. Rundles, editors. McGraw-Hill Book Co., New York. 1023-1039.
50. Mustard, J. F., and M. A. Packham. 1970. Factors influencing platelet function: Adhesion, release and aggregation. *Pharmacol. Rev.* 22: 97-187.
51. Weiss, H. 1975. Platelets: Physiology and abnormalities of platelet function (first of two parts). *N. Engl. J. Med.* 293: 531-541.
52. Moore, S., R. J. Friedman, D. P. Singal, J. Gaudie, and M. Blajchman. 1976. Inhibition of injury-induced thromboatherosclerotic lesions by antiplatelet serum in rabbits. *Thromb. Diath. Haemorrh.* 35: 70-81.
53. Weiss, H. J., T. B. Tschopp, and H. R. Baumgartner. 1975. Impaired interaction (adhesion-aggregation) of platelets with the subendothelium in storage-pool disease and after aspirin ingestion. A comparison with Von Willebrand's disease. *N. Engl. J. Med.* 293: 619-623.
54. Bowie, E. J. W., V. Fuster, C. A. Owen, Jr., and A. L. Brown. 1975. Resistance to the development of spontaneous atherosclerosis in pigs with von Willebrand's disease. 5th Congress of the International Society on Thrombosis and Haemostasis, Paris.
55. Ross, R., and S. J. Klebanoff. 1971. The smooth muscle cell. I. In vivo synthesis of connective tissue proteins. *J. Cell. Biol.* 50: 159-171.
56. Ross, R. 1973. The smooth muscle cell in connective tissue metabolism and atherosclerosis. *In* Proceedings of the Sigrid Juselius Foundation Symposium in Turku, Finland. E. Kulonen, editor. Academic Press, London. 627-636.
57. Weiss, H. J. 1972. The pharmacology of platelet inhibition. *In* Progress in Hemostasis and Thrombosis. Vol. 1. T. H. Spaet, editor. Grune & Stratton, Inc., New York. 199-231.
58. Didisheim, P. T., T. Shimamoto, and H. Yamazaki. 1974. Platelets, thrombosis and inhibitors. *Thromb. Diath. Haemorrh.* Suppl. 60: 3-15.
59. Kinlough-Rathbone, R. L. 1975. The effects of some other drugs on platelet function. *In* Platelets, Drugs and Thrombosis. J. Hirsh, J. F. Cade, A. S. Gallus, and E. Schönbaum, editors. A. G. Karger, Basel, Switzerland. 124-131.
60. Steele, P. P., H. S. Weily, H. Davies, and E. Genton. 1973. Platelet function studies in coronary artery disease. *Circulation.* 48: 1194-1200.
61. Harker, L. A., and S. J. Slichter. 1970. Studies of platelet and fibrinogen kinetics in patients with prosthetic heart valves. *N. Engl. J. Med.* 283: 1302-1305.
62. Sullivan, J. M., D. E. Harken, and R. Gorlin. 1971. Pharmacologic control of thromboembolic complications of cardiac-valve replacement. *N. Engl. J. Med.* 284: 1391-1394.
63. Buchanan, M., and J. Hirsh. 1975. Comparison of in vivo and in vitro effects of platelet function suppressing drugs. *In* 5th Congress of the International Society on Thrombosis and Haemostasis, Paris. p. 182. (Abstr. no. 165)