

## Review Article

# Cytogenetics and Molecular Genetics of Myxoid Soft-Tissue Sarcomas

Jun Nishio,<sup>1</sup> Hiroshi Iwasaki,<sup>2</sup> Kazuki Nabeshima,<sup>2</sup> and Masatoshi Naito<sup>1</sup>

<sup>1</sup>Department of Orthopaedic Surgery, Faculty of Medicine, Fukuoka University, 7-45-1 Nanakuma, Jonan-ku, Fukuoka 814-0180, Japan

<sup>2</sup>Department of Pathology, Faculty of Medicine, Fukuoka University, Fukuoka 814-0180, Japan

Correspondence should be addressed to Jun Nishio, jnishio@cis.fukuoka-u.ac.jp

Received 21 March 2011; Accepted 6 June 2011

Academic Editor: José María Sayagués

Copyright © 2011 Jun Nishio et al. This is an open access article distributed under the Creative Commons Attribution License, which permits unrestricted use, distribution, and reproduction in any medium, provided the original work is properly cited.

Myxoid soft-tissue sarcomas represent a heterogeneous group of mesenchymal tumors characterized by a predominantly myxoid matrix, including myxoid liposarcoma (MLS), low-grade fibromyxoid sarcoma (LGFMS), extraskeletal myxoid chondrosarcoma (EMC), myxofibrosarcoma, myxoinflammatory fibroblastic sarcoma (MIFS), and myxoid dermatofibrosarcoma protuberans (DFSP). Cytogenetic and molecular genetic analyses have shown that many of these sarcomas are characterized by recurrent chromosomal translocations resulting in highly specific fusion genes (e.g., *FUS-DDIT3* in MLS, *FUS-CREB3L2* in LGFMS, *EWSR1-NR4A3* in EMC, and *COL1A1-PDGFB* in myxoid DFSP). Moreover, recent molecular analysis has demonstrated a translocation  $t(1;10)(p22;q24)$  resulting in transcriptional upregulation of *FGF8* and *NPM3* in MIFS. Most recently, the presence of *TGFBR3* and *MGEA5* rearrangements has been identified in a subset of MIFS. These genetic alterations can be utilized as an adjunct in diagnostically challenging cases. In contrast, most myxofibrosarcomas have complex karyotypes lacking specific genetic alterations. This paper focuses on the cytogenetic and molecular genetic findings of myxoid soft-tissue sarcomas as well as their clinicopathological characteristics.

## 1. Introduction

Myxoid soft-tissue sarcomas encompass a heterogeneous group of rare tumors characterized by a marked abundance of mucoïd/myxoid extracellular matrix. The main clinicopathological entities in this group are myxoid liposarcoma, low-grade fibromyxoid sarcoma, extraskeletal myxoid chondrosarcoma, myxofibrosarcoma, myxoinflammatory fibroblastic sarcoma, and myxoid dermatofibrosarcoma protuberans [1–4]. The correct classification of these sarcomas is important because of their distinct biological behaviors and potentially different treatments. However, it is often difficult to set apart many of these sarcomas due to overlapping histological features and lack of a distinct immunohistochemical profile. Moreover, the use of core needle biopsies to diagnose these sarcomas has become increasingly common, and this shift has created additional challenges.

Cytogenetic and molecular genetic assays are routinely used for diagnostic and prognostic purposes in molecular pathology laboratories [5]. Many of myxoid soft-tissue sarcomas are characterized by recurrent chromosomal

translocations resulting in highly specific fusion genes [6, 7]. Advances in knowledge of the genetics of these sarcomas are leading to more accurate diagnosis. This paper reviews the cytogenetic and molecular genetic findings in these sarcoma types and their relationship with clinicopathological features. The consistent genetic alterations are summarized in Table 1.

## 2. Approaches to the Genetics of Soft-Tissue Sarcomas

Conventional karyotyping is the most comprehensive method for spotting the various translocations and other structural or numerical aberrations. It is dependent on the availability of fresh, sterile tumor tissue, the success of tumor cell growth in culture, and quality of metaphase cell preparations. When dividing cells are not available for cytogenetic studies, molecular approaches such as fluorescence in situ hybridization (FISH), comparative genomic hybridization (CGH), reverse transcriptase-polymerase chain reaction (RT-PCR), or gene expression microarray can be used to evaluate genetic alterations.

TABLE 1: Chromosomal alterations and related molecular events in myxoid soft-tissue sarcomas.

Tumor type	Chromosomal alteration	Molecular event	Prevalence
Myxoid/round cell liposarcoma	<i>t</i> (12; 16)(q13; p11)	<i>FUS-DDIT3</i>	>90%
	<i>t</i> (12; 22)(q13; q12)	<i>EWSR1-DDIT3</i>	<5%
Low-grade fibromyxoid sarcoma	<i>t</i> (7; 16)(q32–34; p11)	<i>FUS-CREB3L2</i>	>95%
	<i>t</i> (11; 16)(p11; p11)	<i>FUS-CREB3L1</i>	<5%
	<i>t</i> (9; 22)(q22; q12)	<i>EWSR1-NR4A3</i>	75%
Extraskelatal myxoid chondrosarcoma	<i>t</i> (9; 17)(q22; q11)	<i>TAF15-NR4A3</i>	15%
	<i>t</i> (9; 15)(q22; q21)	<i>TCF12-NR4A3</i>	<1%
	<i>t</i> (3; 9)(q12; q22)	<i>TFG-NR4A3</i>	<1%
Myxofibrosarcoma	Complex karyotype	Not known	Not applicable
Myxoinflammatory fibroblastic sarcoma	<i>t</i> (1; 10)(p22; q24)	Deregulation of <i>FGF8</i> and <i>NPM3</i>	Not applicable
		Rearrangement of <i>TGFBR3</i> and <i>MGEA5</i>	Not applicable
Myxoid dermatofibrosarcoma protuberans	<i>t</i> (17; 22)(q22; q13)*	<i>COL1A1-PDGFB</i>	>90%

\*Rearrangement also frequently seen as a ring chromosome.

FISH is the most helpful method for identifying specific gene rearrangements. It is more adaptable to formalin-fixed, paraffin-embedded tissues although imprint slides are preferred. Interphase FISH is particularly useful to assess intratumoral genetic heterogeneity as long as adequate combination of probes are used. FISH probes are readily available for a variety of relevant gene targets, including *DDIT3* (12q13), *FUS* (16p11), *EWSR1* (22q12), *FKHR* (13q14), *SYT* (18q11.2), and *ALK* (2p23) (Abbott Molecular Inc., Des Plaines, Ill, USA). It has been realized that FISH is a valuable adjunct in the diagnosis of myxoid soft-tissue tumors [8].

CGH is a method for genome-wide analysis of DNA sequence copy number in a single experiment. It maps the origins of amplified and deleted DNA sequences on normal chromosomes, thereby highlighting regions harboring potential oncogenes and tumor suppressor genes. However, CGH cannot detect rearrangements such as balanced translocations or inversions. Recently, a higher resolution version of CGH, so-called array CGH, has been made available. A distinct advantage of array CGH is the ability to directly map the copy number changes to the genome sequence. Similar to array CGH, single nucleotide polymorphism (SNP) array is capable of identifying small regions of chromosomal gains and losses at a high resolution. Also, SNP array can provide information regarding loss of heterozygosity.

RT-PCR is the most sensitive method to detect small numbers of translocation-bearing cells that are mixed within a tissue consisting of largely nonneoplastic cells. Sensitivity levels of 1 in a 100,000 cells are typically achieved. It may be suitable for the detection or monitoring of minimal residual disease [9]. However, the diagnostic success rate is variable and dependent on multiple factors. First, RNA quality may be inadequate because of RNA degradation. The second impediment of this methodology is the high risk of reagent contamination, mainly with PCR products, particularly in small laboratory spaces.

Microarray is a method for genome-wide monitoring of gene expression in a single experiment. A variety of commercial and noncommercial platforms can be used to perform global gene expression profiling. It is hoped that application

of this technology will afford increased understanding of sarcoma biology and facilitate the development of new diagnostic markers and therapeutic agents [10–12].

Approximately one-third of all soft tissue sarcomas exhibit a nonrandom chromosomal translocation. In addition, a subset of soft-tissue tumors carries specific oncogenic mutations (e.g., *KIT* or *PDGFRA* mutations in gastrointestinal stromal tumor). FISH and RT-PCR are commonly applied for the detection of specific genetic alterations in the differential diagnosis of soft-tissue sarcomas.

### 3. Myxoid Liposarcoma

The working group of the World Health Organization (WHO) for classification of tumors of soft-tissue and bone combined myxoid and round cell liposarcomas under myxoid liposarcoma (MLS) [13]. MLS is the second most common subtype of liposarcoma, representing approximately one-third of all liposarcomas. MLS occurs predominantly in the deep soft-tissues of lower extremities and has a peak incidence in the fourth and fifth decades of life with no gender predilection. Pure MLS is considered low-grade and has a 5-year survival rate of 90% [14]. In contrast, MLS containing a greater than 5% round cell component is considered high-grade and has a worse prognosis. The clinical outcome of multifocal MLS is poor [15]. In contrast to other soft-tissue sarcomas, MLS tends to metastasize to unusual sites such as retroperitoneum, opposite extremity, and bone.

Histologically, pure MLS is composed of primitive mesenchymal cells in a myxoid matrix, often featuring mucinous pools (Figure 1(a)). Lipoblasts are most often univacuolated, small, and tend to cluster around vessels or at the periphery of the lesion. A delicate plexiform capillary vascular network is present and provides an important clue for distinguishing MLS from intramuscular myxoma [16]. A subset of MLS shows histological progression to hypercellular or round cell morphology. The round cell areas are characterized by solid sheets of primitive round cells with a high nuclear/cytoplasmic ratio and a prominent nucleolus. Pure round cell liposarcoma is extremely rare and may be confused with

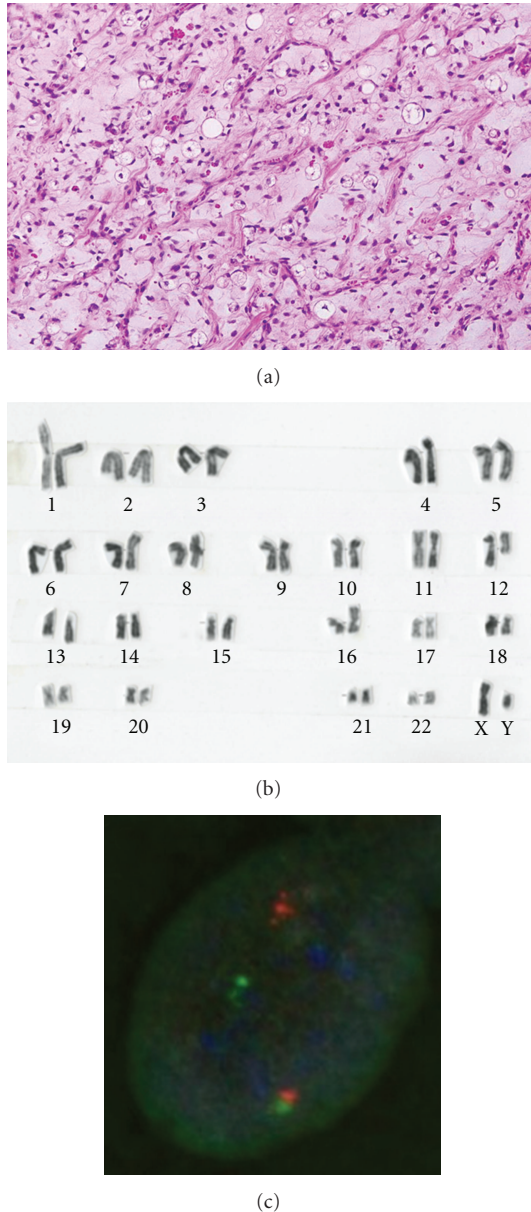


FIGURE 1: (a) Myxoid liposarcoma with a myxoid background containing a delicate arborizing capillary vascular network, small uniform mesenchymal cells, and lipoblasts. (b) G-banded karyotype showing a 12;16 translocation as the sole aberration. (c) Fluorescence in situ hybridization analysis using a *DDIT3* (12q13) break-apart probe shows a split of the orange and green signals, indicating a disruption of the *DDIT3* locus.

other round cell sarcomas such as Ewing sarcoma/primitive neuroectodermal tumor, rhabdomyosarcoma, and poorly differentiated synovial sarcoma.

MLS is characterized by a recurrent translocation  $t(12;16)(q13;p11)$  in more than 90% of cases (Figure 1(b)), which fuses the 5' portion of the *FUS* gene on chromosome 16 with entire reading frame of the *DDIT3* gene on chromosome 12 [17–19]. A small percentage of cases carry a variant translocation  $t(12;22)(q13;q12)$  resulting in an *EWSR1-DDIT3* fusion gene [15, 20–28]. The presence of these translocations

and molecular alterations is highly sensitive and specific for MLS. Therefore, cytogenetics is an excellent analytic method for the initial workup of a suspected MLS. FISH and RT-PCR can also be used to provide support for the diagnosis of MLS (Figure 1(c)) [8, 29–32]. In addition, several nonrandom secondary alterations have been identified, including 6q deletion, isochromosome 7q10, trisomy 8, and unbalanced 1;16 translocation [17, 24, 33–35]. Conventional and array CGH studies have shown gains of 8p21–23, 8q, and 13q [36–38].

To date, 12 *FUS-DDIT3* and four *EWSR1-DDIT3* variants of fusion transcripts have been described in MLS [22, 26, 28, 39, 40]. Most cases of MLS are one of three different *FUS-DDIT3* fusion transcript types, including varying portions of *FUS*. The *FUS-DDIT3* fusion transcript type does not appear to have a significant impact on clinical outcome [22, 26]. On the other hand, Suzuki et al. [28] reported that MLS with a type 1 *EWSR1-DDIT3* fusion transcript may show more favorable clinical behavior than MLS with other types of fusion transcripts. Interestingly, clinical data suggest that the fusion transcript type may influence response to therapy with trabectedin [41].

Several receptor tyrosine kinases (RTKs) are highly expressed in MLS, including RET, MET, and IGF1R [42, 43]. These RTKs promote cell survival and cell proliferation through the PI3K/AKT and the Ras-Raf-ERK/MAPK pathways [42]. Recently, Barretina et al. [44] demonstrated that mutation of *PIK3CA*, encoding the catalytic subunit of PI3K, is associated with AKT activation and poor clinical outcome. AKT activation functions as a master switch to generate a plethora of intracellular signals and intracellular responses and is more frequent in the round cell variant [43]. It has also been shown that the NF- $\kappa$ B pathway is highly active in MLS [40]. Moreover, Göransson et al. [45] showed that NF- $\kappa$ B is a major factor controlling *IL8* transcription in *FUS-DDIT3*-expressing cells. NF- $\kappa$ B is an inducible cellular transcription factor that regulates a variety of cellular genes, including those involved in immune regulation, inflammation, cell survival, and cell proliferation. These findings will help to develop new potential therapeutic strategies for MLS patients with advanced disease.

#### 4. Low-Grade Fibromyxoid Sarcoma

Low-grade fibromyxoid sarcoma (LGFMS), first described by Evans [46] in 1987, is a rare but distinctive fibromyxoid variant of fibrosarcoma. It includes the tumor originally designed as hyalinizing spindle cell tumor with giant rosettes [47]. LGFMS occurs primarily in young to middle-aged adults with a male predominance, but this tumor may affect children [48, 49]. LGFMS typically presents as a slowly growing, painless mass in the deep soft-tissues of lower extremities or trunk. Local recurrence and metastatic rates are 9%–21% and 6%–27%, respectively [49, 50]. The overall prognosis for superficial LGFMS appears to be better than that for deep LGFMS [48].

Histologically, LGFMS shows alternating fibrous and myxoid areas with bland spindle-shaped cells arranged in a whorled pattern (Figure 2). Cellularity is variable but generally low and mitoses are scarce. There is often a prominent



network of branching capillary-sized blood vessels reminiscent of myxoid liposarcoma. Approximately 40% of cases have giant collagen rosettes characterized by a central zone of eosinophilic collagen surrounded by a palisade of round to oval tumor cells [13]. This variant was originally termed hyalinizing spindle cell tumor with giant rosettes [47]. Immunohistochemically, the tumor cells are diffusely positive for vimentin and focally for epithelial membrane antigen (EMA) [48, 50]. Immunostains for S-100 protein, desmin, and CD34 are typically negative.

LGFMS is characterized by a recurrent balanced translocation  $t(7;16)(q34;p11)$  resulting in an *FUS-CREB3L2* fusion gene [50–53]. This same translocation was identified in cases of hyalinizing spindle cell tumor with giant rosettes [54, 55], suggesting a pathogenetic link between these two entities. A small percentage of cases carry a variant translocation  $t(11;16)(p11;p11)$  leading to a fusion of the *FUS* and *CREB3L1* genes [50, 53]. Interestingly, supernumerary ring chromosomes have been observed as the sole anomaly in a subset of LGFMS [52, 56, 57]. FISH and CGH studies have demonstrated that ring chromosomes are composed of material from chromosomes 7 and 16 [56, 57]. Bartuma et al. [57] showed that the *FUS-CREB3L2* fusion gene can be present in ring chromosomes.

The breakpoints in the fusion transcripts are mostly at exon 6 or 7 of *FUS* and exon 5 of *CREB3L2* or *CREB3L1* [50–53, 58]. *CREB3L2* is a member of CREB3 family of transcription factors and contains a basic DNA-binding and leucine zipper dimerization domain, highly similar to that in *CREB3L1*. Panagopoulos et al. [59] suggested that the *FUS-CREB3L2* fusion protein is a more potent transcriptional activator than the native *CREB3L2* and may contribute to the pathogenesis of LGFMS through the deregulation of its target genes. The molecular variability of fusion transcripts in LGFMS does not appear to have a significant impact on microscopic appearances or clinical outcome [53].

## 5. Extraskeletal Myxoid Chondrosarcoma

Extraskeletal myxoid chondrosarcoma (EMC) is categorized by the WHO as a tumor of uncertain differentiation, because there is a paucity of convincing evidence of cartilaginous differentiation [13]. Most EMCs arise in the deep soft-tissues of the proximal extremities and limb girdles, especially the thigh and popliteal fossa, similar to MLS. EMC has a peak incidence in the fifth and sixth decades of life with a male predominance. Only a few cases have been encountered in children and adolescents [60–62]. Patients typically present with a slowly growing mass that causes pain or tenderness in approximately one-third of cases [16]. Local recurrence and metastatic rates are 48% and 46%, respectively [61]. EMC has a 10-year survival rate of 63%–88%, but a 10-year disease-free survival is much lower, ranging from 14% to 36% [61, 63–66]. Large tumor size (especially >10 cm), advanced age, and proximal tumor location appear to be poor prognostic factors in EMC [61, 63, 67].

Histologically, EMC is characterized by multinodular growth of a cord-like or lace-like arrangement of round or slightly elongated cells in an abundant myxoid matrix (Fig-

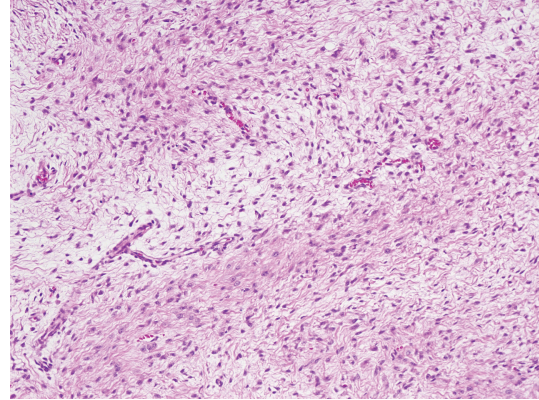


FIGURE 2: Low-grade fibromyxoid sarcoma with alternating fibrous and myxoid areas.

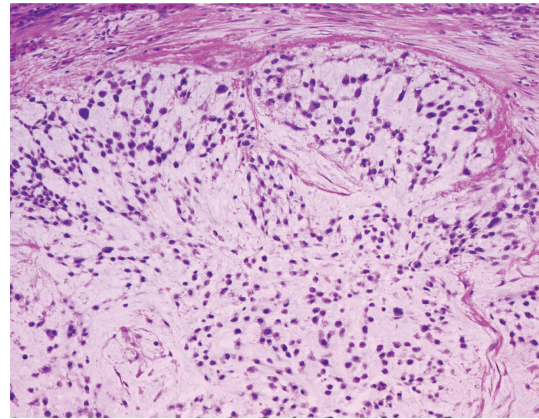


FIGURE 3: Extraskeletal myxoid chondrosarcoma with an abundant myxoid matrix containing round or slightly elongated cells with small hyperchromatic nuclei.

ure 3). The tumor cells have small hyperchromatic nuclei and a narrow rim of deeply eosinophilic cytoplasm. Occasional cells show cytoplasmic vacuolization [16]. Mitotic figures are rare in most cases. In contrast to the bland-looking or low-grade morphology, cellular or high-grade EMC has also been described [61, 68, 69]. Some authors have suggested that the cellular or high-grade EMC is likely to have a worse prognosis than conventional EMC [63, 68, 70] although its prognostic significance has not yet been established [67]. Immunohistochemically, vimentin is the only marker consistently positive in EMC. S-100 protein is expressed in approximately 30% of cases [67], often with focal and weak immunoreactivity. Only a small percentage of cases may show scattered cells that are EMA positive [67]. Recent immunohistochemical and ultrastructural studies have demonstrated that some EMCs may have neuroendocrine differentiation [63, 69, 71].

EMC is characterized by a recurrent translocation  $t(9;22)(q22;q12)$  in approximately 75% of cases, which fuses the *EWSR1* gene on 22q12 with the *NR4A3* gene on 9q22 [72–78]. A second variant translocation,  $t(9;17)(q22;q11)$ , has been detected in approximately 15% of EMC and results in a *TAF15-NR4A3* fusion gene [78–82]. In addition, two

additional variant translocations,  $t(9;15)(q22;q21)$  resulting in a *TCF12-NR4A3* fusion gene and  $t(3;9)(q12;q22)$  resulting in a *TFG-NR4A3* fusion gene, have also been identified, each only in a single case [83, 84]. Because these fusion genes have not yet been described in any other tumor type, they represent useful diagnostic markers. Moreover, several nonrandom secondary alterations have been identified in approximately 50% of cytogenetically analyzed cases, including gain of 1q and trisomy for chromosomes 7, 8, 12, and 19 [77, 78]. The biological significance of these chromosomal alterations remains unknown.

Two main *EWSR1-NR4A3* fusion transcript types have been reported for the  $t(9;22)(q22;q12)$  in EMC [69, 77, 78]. The most common fusion transcript contains exon 12 of *EWSR1* fused to exon 3 of *NR4A3* (type 1), whereas exon 7 of *EWSR1* is fused to exon 2 of *NR4A3* in the type 2 fusion transcript. In the *TAF15-NR4A3* fusion transcript, exon 6 of *TAF15* is fused exclusively to exon 3 of *NR4A3* [77]. *NR4A3* is a member of *NR4A* subfamily within the nuclear receptor superfamily and contains a zinc finger DNA-binding domain. The *EWSR1-NR4A3* fusion protein is thought to function as a potent transcriptional activator for *NR4A3*-target genes [85, 86]. It has also been shown that the *TAF15-NR4A3* fusion protein functions as a strong transcriptional activator [87]. It is unclear whether the fusion transcript type is associated with particular morphological features or clinical outcome.

Gene expression profiling studies of EMC have revealed overexpression of the *CHI3L1*, *METTL1*, *RELB*, *MYB*, *NMB*, *DKK1*, *DNER*, *CLCN3*, *DEF6*, *NDRG2*, and *PPARG* genes [78, 88, 89]. In addition, several genes encoding neural-neuroendocrine markers have been expressed, including *SCG2*, *NEF3*, *GFAP*, *GAD2*, *ENO2*, *SYP*, *CHGA*, *NEF3*, and *INSM1* [78, 88]. *CHI3L1* encodes a glycoprotein member of the glycosyl hydrolase 18 family, which is secreted by activated chondrocytes, macrophages, neutrophils, and synovial cells. Sjögren et al. [78] suggested that *CHI3L1* may be useful as a serum marker monitoring disease progression in EMC patients. *NMB* is a member of bombesin-related peptide family in mammals and a secreted protein involved in stimulation of smooth muscle contraction [90]. Subramanian et al. [88] suggested that *NMB* may prove to be a serological marker of EMC recurrence. *DKK1* encodes a protein that is a member of the dickkopf family. *DKK1* is involved in embryonic development through its inhibition of the WNT signaling pathway. Because *DKK1* is a secreted protein, it may serve as a prognostic marker for evaluation of EMC. *PPARG* encodes a member of the peroxisome proliferator-activated receptor subfamily of nuclear receptors. *PPARG* is known as a regulator of adipocytic differentiation [91]. Interestingly, Filion et al. [89] demonstrated that *PPARG* is the first direct transcriptional target of the *EWSR1-NR4A3* fusion protein. These findings will lead to the development of molecularly targeted therapies for patients with advanced EMC.

## 6. Myxofibrosarcoma

Myxofibrosarcoma, formerly known as myxoid malignant fibrous histiocytoma (MFH), is now defined as a distinct

histological entity [13]. It is one of the most common soft-tissue sarcomas in elderly patients. Most myxofibrosarcomas arise in the dermal and subcutaneous tissues of the limbs (especially lower limbs) and limb girdles. Myxofibrosarcoma has a peak incidence in the sixth to eighth decades of life with a slight male predominance. Patients typically present with a slowly growing, painless mass. Recently, an epithelioid variant of myxofibrosarcoma with an aggressive course has been described [92].

Grading of myxofibrosarcoma is somewhat controversial. Myxofibrosarcoma has been subdivided into three or four grades based on the degree of cellularity, nuclear pleomorphism, and mitotic activity [93, 94]. Local recurrences occur in up to 50% to 60% of cases [93–95], irrespective of histological grade. Whereas low-grade myxofibrosarcomas usually do not metastasize, intermediate and high-grade lesions may develop metastases in approximately 16% to 38% of cases [93–95]. Importantly, low-grade myxofibrosarcomas may become higher grade in subsequent recurrences and acquire metastatic potential. The overall 5-year survival rate is 60%–70% [13].

Histologically, myxofibrosarcoma is characterized by multinodular growth of spindle or stellate-shaped cells within variably myxoid stroma containing elongated, curvilinear blood vessels (Figure 4). The tumor cells have slightly eosinophilic cytoplasm and mildly atypical, hyperchromatic nuclei. Vacuolated cells with cytoplasmic acid mucin, mimicking lipoblasts, are also seen [13]. Mitotic figures are rare in low-grade lesions. In contrast, high-grade myxofibrosarcomas are composed of solid sheets and fascicles of atypical spindled and pleomorphic tumor cells with hemorrhagic and necrotic areas. Bizarre, multinucleated giant cells are also occasionally found. Mitotic figures, including abnormal mitoses, are frequent. At least focally, however, areas of a lower grade neoplasm with a prominent myxoid matrix are present [13]. Intermediate-grade myxofibrosarcomas are more cellular than low-grade lesions and often contain minute solid areas showing flank pleomorphism. Immunohistochemically, the tumor cells are diffusely positive for vimentin and occasionally for muscle specific actin and  $\alpha$ -smooth muscle actin, suggestive of focal myofibroblastic differentiation.

Data on the cytogenetics and molecular genetics of myxofibrosarcoma are difficult to evaluate, because the diagnostic criteria for this tumor have changed with time. In general, myxofibrosarcomas are associated with highly complex karyotypes lacking specific structural aberrations [96–98]. The only recurrent gain involves chromosome 7, whereas losses primarily affect chromosomes 1, 3, 5, 6, 10, 12, 16, 17, and 19 [7]. The presence of ring chromosomes has been described in some cases of low-grade myxofibrosarcoma (or myxoid MFH) [98–100]. In addition, homogeneously staining regions, double minutes, and marker chromosomes have been found. Recently, Willems et al. [98] proposed the concept of progression of myxofibrosarcoma as a multistep genetic process ruled by genetic instability.

A conventional CGH study of 22 myxofibrosarcomas showed gains of 19p and 19q, losses of 1q, 2q, 3p, 4q, 10q, 11q, and 13q, and high-level amplifications of the central



regions of chromosome 1, 5p, and 20q [101]. Interestingly, gain of 5p and loss of 4q are not observed in low-grade myxofibrosarcomas as opposed to higher grade neoplasms, suggesting that these aberrations are late events in the oncogenesis of myxofibrosarcoma. In addition, array CGH studies showed gains of 7p21-22, 7q31-35, and 12q15-21 and losses of 10p13-14, 10q25-26, and 13q14-34 [38, 102, 103]. These findings suggest that loss of chromosome 13q is the most frequent genomic imbalance in myxofibrosarcoma, leading to inactivation of the RB pathway.

Recently, Lee et al. [103] reported that MET is expressed in approximately two-third of cases and its overexpression is highly related to deep location, higher grades, and more advanced stages. The authors suggested that MET may represent a target of choice to develop novel therapeutic strategies for myxofibrosarcoma.

A recent gene expression analysis has shown that the *WISP2*, *GPR64*, and *TNXB* genes are upregulated in myxofibrosarcoma compared with other spindle cell and pleomorphic sarcomas [104]. *WISP2* encodes a member of the WNT1 inducible signaling pathway protein subfamily, which belongs to the connective tissue growth factor family. *WISP2* is a secreted protein involved in several important human diseases or conditions that are marked by aberrant cell proliferation and migration [105]. *GPR64* is a highly conserved, tissue-specific, seven-transmembrane receptor of the human epididymis [106]. *TNXB* encodes a member of the tenascin family of extracellular matrix glycoproteins. *TNXB* is thought to function in matrix maturation during wound healing, and its deficiency is associated with the connective tissue disorder Ehlers-Danlos syndrome [107]. Nakayama et al. [104] suggested that these genes may serve as novel diagnostic markers for myxofibrosarcoma. Most recently, Barretina et al. [44] demonstrated that *NFI* is mutated or deleted in 10.5% of myxofibrosarcomas.

## 7. Myxoinflammatory Fibroblastic Sarcoma

Myxoinflammatory fibroblastic sarcoma (MIFS), also known as inflammatory myxohyaline tumor of the distal extremities with virocyte or Reed-Sternberg-like cells, is a recently described soft-tissue tumor entity [108, 109]. MIFS occurs predominantly in the subcutaneous tissues of distal extremities and has a peak incidence in the fourth and fifth decades of life with no gender predilection. Patients typically present with a slowly growing, painless, ill-defined mass. The preoperative diagnosis in most cases is benign and may include tenosynovitis, ganglion cyst, and giant cell tumor of tendon sheath [13]. Local recurrence and metastatic rates are 31.3% and 3.1%, respectively [110].

Histologically, MIFS is multinodular, poorly delineated, and characterized by a prominent myxoid matrix containing numerous inflammatory cells, including lymphocytes, plasma cells, neutrophils, and eosinophils [109]. Germinal centers are occasionally encountered. Neoplastic cells include spindle-shaped and epithelioid cells with mild to moderate nuclear atypia, large polygonal and bizarre ganglion-like cells, Reed-Sternberg-like cells with huge inclusion-like

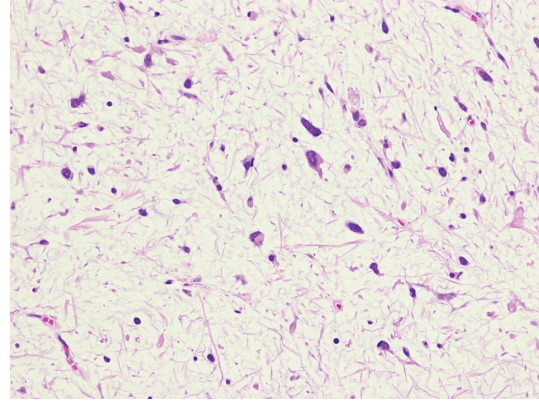


FIGURE 4: Myxofibrosarcoma with a myxoid stroma containing spindle or stellate-shaped cells with mildly atypical, hyperchromatic nuclei.

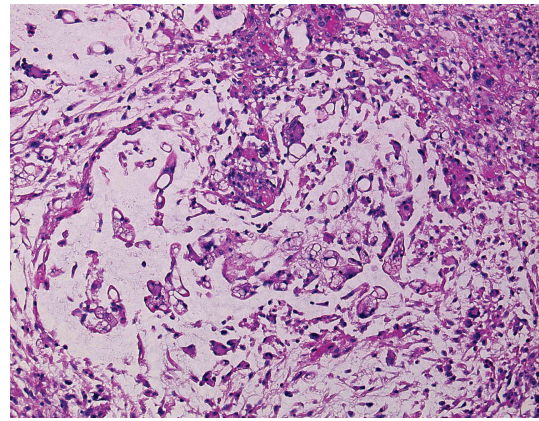


FIGURE 5: Myxoinflammatory fibroblastic sarcoma with a myxoid background containing spindle-shaped and epithelioid cells, inflammatory cells, and pseudolipoblasts.

nucleoli, and multivacuolated lipoblast-like cells (Figure 5). Hemosiderin deposition may be conspicuous. Mitotic activity is usually low, and necrosis is rarely present. Immunohistochemically, the tumor cells are diffusely positive for vimentin and focally for CD68 and CD34 [16]. Occasional cases may show scattered cells that stain for cytokeratin or  $\alpha$ -smooth muscle actin. Immunostains for S-100 protein, HMB-45, desmin, EMA, leukocyte common antigen, CD15, and CD30 are typically negative.

Cytogenetic and molecular cytogenetic studies have identified the frequent presence of a balanced or unbalanced  $t(1;10)(p22;q24)$  translocation and ring chromosomes containing amplified material from the 3p11-12 region in MIFS [111-113]. A balanced translocation,  $t(2;6)(q31;p21.3)$ , has also been described as the sole anomaly in a single case [114]. Most recently, Antonescu et al. [115] demonstrated the presence of *TGFBR3* (1p22) and *MGEA5* (10q24) gene rearrangements by FISH in a subset of MIFS. It is of interest that the  $t(1;10)$  translocation and these gene rearrangements have also been identified in hemosiderotic fibrolipomatous tumor (HFLT) [113, 115-117]. These findings suggest that

MIFS and HFLT may represent different morphologic variants of the same entity.

Conventional and array CGH studies showed amplification of 3p11-12 [113, 118]. Notably, Hallor et al. [113] demonstrated that 3p11-12 amplification is associated with an increased expression of *VGLL3* and *CHMP2B*. *VGLL3* encodes a protein that is a cofactor of transcription factors of the TEAD family. It has also been shown that *VGLL3* is amplified and overexpressed in myxofibrosarcoma, undifferentiated pleomorphic sarcoma, and dedifferentiated liposarcoma [119]. These findings strongly suggest that *VGLL3* is the main target of 3p11-12 amplification and this genetic event plays an important role in the development and progression of certain subsets of soft-tissue sarcomas.

A recent gene expression analysis has shown that the *FGF8* and *NPM3* genes are upregulated in the *t*(1;10) - positive tumors compared with tumors without such a translocation [113]. These two genes downstream of *MGEA5* have been mapped to 10q24. *FGF8*, a member of the fibroblast growth factor family, is a secreted heparin-binding protein, which has transforming potential. *FGF8* is widely expressed during embryonic development. Overexpression of *FGF8* has been shown to increase tumor growth and angiogenesis [120]. Hallor et al. [113] suggested that deregulation of *FGF8* may constitute an important event in the development of a subset of MIFS.

## 8. Myxoid Dermatofibrosarcoma Protuberans

Myxoid dermatofibrosarcoma protuberans (DFSP) is a rare but distinctive variant of DFSP with a prominent myxoid matrix. Clinically, myxoid DFSP is similar to typical DFSP [121–123]. DFSP occurs primarily young to middle-aged adults with a male predominance, but this tumor may affect children, including congenital occurrence [124]. It typically presents as a slowly growing, plaque-like or small nodular lesion. The most common location is the trunk, followed by the limbs and head and neck. Local recurrence and metastatic rates are 0%–52% and 0%–1.7%, respectively [125]. The overall prognosis of typical DFSP is excellent if completely excised with negative microscopic margins. Reimann and Fletcher [122] stated that myxoid DFSP appears to have a similarly good prognosis. Recognition of this DFSP variant is important to avoid misdiagnosis of more or less aggressive myxoid soft-tissue tumors.

Histologically, myxoid DFSP is characterized by a sheet-like to vaguely lobular proliferation of bland spindle cells in an abundant myxoid stroma (Figure 6). The tumor cells have slightly eosinophilic cytoplasm and stellate to oval nuclei with indistinct nucleoli. Branching, thin-walled blood vessels are frequently present. All cases display at least focally a strikingly infiltrative growth pattern, with trapping of subcutaneous adipose tissue in the characteristic honeycomb manner also observed in typical DFSP [122]. Mitotic activity is usually low. Immunohistochemically, the tumor cells are diffusely positive for vimentin and CD34. Immunostains for S-100 protein, desmin, muscle specific actin,  $\alpha$ -smooth muscle actin, cytokeratin, and EMA are typically negative. Apolipoprotein D (APOD) has been found

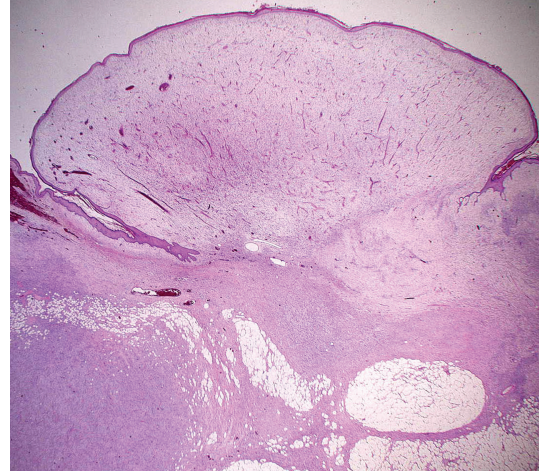


FIGURE 6: Typical example of a myxoid dermatofibrosarcoma protuberans.

to be highly expressed in DFSP and its histological variants [126].

DFSP is characterized by an unbalanced translocation *t*(17;22)(q22;q13), which fuses the *COL1A1* gene on 17q21-22 with the *PDGFB* gene on 22q13 [127–130]. The same molecular event is also seen in supernumerary ring chromosomes derived from the *t*(17;22) [129, 130]. Identical genetic changes have also been shown in the histological variants, including myxoid DFSP [123], pigmented DFSP (Bednar tumor) [131], Granular cell DFSP [132], juvenile variant of DFSP (giant cell fibroblastoma) [128], and fibrosarcomatous variant of DFSP [133, 134]. Other rare translocations, including *t*(X;7), *t*(2;7), *t*(9;22), and *t*(5;8), have also been described [135–138]. Moreover, several secondary nonrandom alterations have been identified, including trisomy 5 and trisomy 8 [130]. The clinical and biological implications of these chromosomal alterations are virtually unknown.

Conventional and array CGH studies showed gain or high-level amplification of 17q and 22q in most cases [139–141]. DFSP is occasionally misdiagnosed as benign lesions such as dermatofibroma, leading to improper primary management. We suggested that CGH may be a useful diagnostic tool for distinguishing DFSP from dermatofibroma [140]. The presence of gain in 8q was also observed [140–142]. Interestingly, FISH and CGH studies have indicated an association between an increased number of *COL1A1-PDGFB* genomic copies and fibrosarcomatous transformation in a subset of DFSP [139, 143, 144]. Most recently, Salgado et al. [145] reported that the majority of DFSP harbor the *COL1A1-PDGFB* fusion and FISH should be recommended as a routine diagnostic tool.

The breakpoint of *PDGFB* is remarkably constant (exon 2). In contrast, the *COL1A1* breakpoint may occur in any of the exons in the  $\alpha$ -helical coding region (exons 6–49). The most frequently rearranged *COL1A1* exons are exon 25, 32, and 47 [146]. *PDGFB* encodes the  $\beta$  chain of platelet-derived growth factor. *PDGFB* is a potent mitogen for



a variety of cells [147]. *COL1A1* encodes the pro- $\alpha 1$  chains of type I collagen whose triple helix comprises two  $\alpha 1$  chains and one  $\alpha 2$  chain. Type I collagen is a major structural protein found in the extracellular matrix of connective tissue such as skin, bone, and tendon. The *COL1A1*-*PDGFB* fusion protein is posttranslationally processed to a functional PDGFB, and results in PDGFB-mediated autocrine and/or paracrine activation of PDGFRB [128, 148]. Inhibitors of PDGFRB, such as imatinib mesylate, have been reported to show clinical activity for metastatic or locally advanced DFSP [149–151]. These results support the concept that DFSP cells are dependent on aberrant activation of PDGFRB for cellular proliferation and survival. No correlation between the molecular subtype of *COL1A1*-*PDGFB* fusion gene and the clinicopathological features has been established [146, 152].

Gene expression profiling studies of DFSP have revealed overexpression of the *PDGFB*, *PDGFRB*, *APOD*, *SPRY2*, *NRP1*, *EGR2*, and *MEOX1* genes [10, 153]. *SPRY2* encodes a protein belonging to the sprouty family and is involved in the regulation of the EGF, FGF, and Ras/MAPK signaling pathways. NRP1 is a membrane-bound coreceptor to a tyrosine kinase receptor for both vascular endothelial growth factor and semaphorin family members and plays a role in angiogenesis, cell survival, migration, and invasion. *EGR2* is a transcription factor with three tandem C2H2-type zinc fingers and plays a role in the PTEN-induced apoptotic pathway [154]. *MEOX1* has been mapped to 17q21 and encodes a member of a subfamily of nonclustered, diverged, antennapedia-like homeobox-containing genes. The homeobox genes are involved in early embryonic development and the determination of cell fate. Linn et al. [153] proposed the possibility that DFSP are derived from early embryonic mesenchymal cells.

## 9. Conclusions

It is important to be familiar with the clinicopathological and molecular genetic features of myxoid soft-tissue sarcomas for their accurate diagnosis and appropriate treatment. In our experience, FISH is a valuable ancillary diagnostic tool for these sarcomas, especially on limited tissue samples. Novel diagnostic and/or prognostic molecular markers as well as promising therapeutic targets have gradually been recognized. In the future, treatment decisions and prognosis assessment for myxoid soft-tissue sarcomas will increasingly be based on a combination of histological criteria and molecular identification of genetic alterations indicative of biological properties.

## Acknowledgment

This work was supported in part by Kaibara Morikazu Medical Science Promotion Foundation, Japan Orthopaedics and Traumatology Foundation, Fukuoka Cancer Society, Clinical Research Foundation, and a Grant-in-Aid for Young Scientists (B) (21791424) from the Ministry of Education, Culture, Sports, Science, and Technology of Japan.

## References

- [1] J. F. Graadt van Roggen, P. C. W. Hogendoorn, and C. D. M. Fletcher, "Myxoid tumours of soft tissue," *Histopathology*, vol. 35, no. 4, pp. 291–312, 1999.
- [2] S. M. Willems, Y. M. Schrage, J. J. Baelde et al., "Myxoid tumours of soft tissue: the so-called myxoid extracellular matrix is heterogeneous in composition," *Histopathology*, vol. 52, no. 4, pp. 465–474, 2008.
- [3] S. M. Willems, A. Van Remoortere, R. Van Zeijl, A. M. Deelder, L. A. McDonnell, and P. C. Hogendoorn, "Imaging mass spectrometry of myxoid sarcomas identifies proteins and lipids specific to tumour type and grade, and reveals biochemical intratumour heterogeneity," *Journal of Pathology*, vol. 222, no. 4, pp. 400–409, 2010.
- [4] S. M. Willems, M. Wiweger, J. F. G. van Roggen, and P. C. W. Hogendoorn, "Running GAGs: myxoid matrix in tumor pathology revisited: what's in it for the pathologist," *Virchows Archiv*, vol. 456, no. 2, pp. 181–192, 2010.
- [5] J. A. Bridge, "Advantages and limitations of cytogenetic, molecular cytogenetic, and molecular diagnostic testing in mesenchymal neoplasms," *Journal of Orthopaedic Science*, vol. 13, no. 3, pp. 273–282, 2008.
- [6] H. Iwasaki, K. Nabeshima, J. Nishio et al., "Pathology of soft-tissue tumors: daily diagnosis, molecular cytogenetics and experimental approach: review Article," *Pathology International*, vol. 59, no. 8, pp. 501–521, 2009.
- [7] F. Mertens, I. Panagopoulos, and N. Mandahl, "Genomic characteristics of soft tissue sarcomas," *Virchows Archiv*, vol. 456, no. 2, pp. 129–139, 2010.
- [8] E. Downs-Kelly, J. R. Goldblum, R. M. Patel et al., "The utility of fluorescence in situ hybridization (FISH) in the diagnosis of myxoid soft tissue neoplasms," *American Journal of Surgical Pathology*, vol. 32, no. 1, pp. 8–13, 2008.
- [9] F. Willeke and J. W. Sturm, "Minimal residual disease in soft-tissue sarcomas," *Seminars in Surgical Oncology*, vol. 20, no. 4, pp. 294–303, 2001.
- [10] K. Baird, S. Davis, C. R. Antonescu et al., "Gene expression profiling of human sarcomas: insights into sarcoma biology," *Cancer Research*, vol. 65, no. 20, pp. 9226–9235, 2005.
- [11] T. O. Nielsen, "Microarray analysis of sarcomas," *Advances in Anatomic Pathology*, vol. 13, no. 4, pp. 166–173, 2006.
- [12] A. H. Beck, R. B. West, and M. van de Rijn, "Gene expression profiling for the investigation of soft tissue sarcoma pathogenesis and the identification of diagnostic, prognostic, and predictive biomarkers," *Virchows Archiv*, vol. 456, no. 2, pp. 141–151, 2010.
- [13] C. D. M. Fletcher, K. K. Unni, and F. Mertens, *World Health Organization Classification of Tumours. Pathology and Genetics of Tumours of Soft Tissue and Bone*, IARC Press, Lyon, France, 2002.
- [14] Y. Nishida, S. Tsukushi, H. Nakashima, and N. Ishiguro, "Clinicopathologic prognostic factors of pure myxoid liposarcoma of the extremities and trunk wall," *Clinical Orthopaedics and Related Research*, vol. 468, no. 11, pp. 3041–3046, 2010.
- [15] C. R. Antonescu, A. Elahi, J. H. Healey et al., "Monoclonality of multifocal myxoid liposarcoma: confirmation by analysis of TLS-CHOP or EWS-CHOP rearrangements," *Clinical Cancer Research*, vol. 6, no. 7, pp. 2788–2793, 2000.
- [16] S. W. Weiss and J. R. Goldblum, *Enzinger and Weiss's Soft Tissue Tumors*, Mosby, Philadelphia, Pa, USA, 5th edition, 2008.



- [17] A. A. Sandberg, "Updates on the cytogenetics and molecular genetics of bone and soft tissue tumors: liposarcoma," *Cancer Genetics and Cytogenetics*, vol. 155, no. 1, pp. 1–24, 2004.
- [18] R. Conyers, S. Young, and D. M. Thomas, "Liposarcoma: molecular genetics and therapeutics," *Sarcoma*, vol. 2011, Article ID 483154, 13 pages, 2011.
- [19] J. Nishio, "Contributions of cytogenetics and molecular cytogenetics to the diagnosis of adipocytic tumors," *Journal of Biomedicine and Biotechnology*, vol. 2011, Article ID 524067, 9 pages, 2011.
- [20] I. Panagopoulos, M. Höglund, F. Mertens, N. Mandahl, F. Mitelman, and P. Åman, "Fusion of the EWS and CHOP genes in myxoid liposarcoma," *Oncogene*, vol. 12, no. 3, pp. 489–494, 1996.
- [21] P. Dal Cin, R. Sciot, I. Panagopoulos et al., "Additional evidence of a variant translocation t(12;22) with EWS/CHOP fusion in myxoid liposarcoma: clinicopathological features," *Journal of Pathology*, vol. 182, no. 4, pp. 437–441, 1997.
- [22] C. R. Antonescu, S. J. Tschernyavsky, R. Decuseara et al., "Prognostic impact of P53 status, TLS-CHOP fusion transcript structure, and histological grade in myxoid liposarcoma: a molecular and clinicopathologic study of 82 cases," *Clinical Cancer Research*, vol. 7, no. 12, pp. 3977–3987, 2001.
- [23] T. Hosaka, Y. Nakashima, K. Kusuzaki et al., "A novel type of EWS-CHOP fusion gene in two cases of myxoid liposarcoma," *Journal of Molecular Diagnostics*, vol. 4, no. 3, pp. 164–171, 2002.
- [24] N. C. Birch, C. R. Antonescu, M. Nelson et al., "Inconspicuous insertion 22;12 in myxoid/round cell liposarcoma accompanied by the secondary structural abnormality der(16)t(1;16)," *Journal of Molecular Diagnostics*, vol. 5, no. 3, pp. 191–194, 2003.
- [25] Y. Matsui, T. Ueda, T. Kubo et al., "A novel type of EWS-CHOP fusion gene in myxoid liposarcoma," *Biochemical and Biophysical Research Communications*, vol. 348, no. 2, pp. 437–440, 2006.
- [26] B. Bode-Lesniewska, S. Frigerio, U. Exner, M. T. Abdou, H. Moch, and D. R. Zimmermann, "Relevance of translocation type in myxoid liposarcoma and identification of a novel EWSR1-DDIT3 fusion," *Genes Chromosomes and Cancer*, vol. 46, no. 11, pp. 961–971, 2007.
- [27] R. Alaggio, C. M. Coffin, S. W. Weiss et al., "Liposarcomas in young patients: a study of 82 cases occurring in patients younger than 22 years of age," *American Journal of Surgical Pathology*, vol. 33, no. 5, pp. 645–658, 2009.
- [28] K. Suzuki, Y. Matsui, K. Endo et al., "Myxoid liposarcoma with EWS—CHOP type 1 fusion gene," *Anticancer Research*, vol. 30, no. 11, pp. 4679–4683, 2010.
- [29] M. R. Tanas and J. R. Goldblum, "Fluorescence in situ hybridization in the diagnosis of soft tissue neoplasms: a review," *Advances in Anatomic Pathology*, vol. 16, no. 6, pp. 383–391, 2009.
- [30] M. R. Tanas, B. P. Rubin, R. R. Tubbs, S. D. Billings, E. Downs-Kelly, and J. R. Goldblum, "Utilization of fluorescence in situ hybridization in the diagnosis of 230 mesenchymal neoplasms: an institutional experience," *Archives of Pathology and Laboratory Medicine*, vol. 134, no. 12, pp. 1797–1803, 2010.
- [31] K. Thway, S. Rockcliffe, D. Gonzalez et al., "Utility of sarcoma-specific fusion gene analysis in paraffin-embedded material for routine diagnosis at a specialist centre," *Journal of Clinical Pathology*, vol. 63, no. 6, pp. 508–512, 2010.
- [32] C. R. Antonescu, A. Elahi, M. Humphrey et al., "Specificity of TLS-CHOP rearrangement for classic myxoid/round cell liposarcoma: absence in predominantly myxoid well-differentiated liposarcomas," *Journal of Molecular Diagnostics*, vol. 2, no. 3, pp. 132–138, 2000.
- [33] C. Sreekantaiah, C. P. Karakousis, S. P. L. Leong, and A. A. Sandberg, "Trisomy 8 as a nonrandom secondary change in myxoid liposarcoma," *Cancer Genetics and Cytogenetics*, vol. 51, no. 2, pp. 195–205, 1991.
- [34] Z. Gibas, M. Miettinen, J. Limon et al., "Cytogenetic and immunohistochemical profile of myxoid liposarcoma," *American Journal of Clinical Pathology*, vol. 103, no. 1, pp. 20–26, 1995.
- [35] K. Mrozek and C. D. Bloomfield, "Der(16)t(1;16) is a secondary chromosome aberration in at least eighteen different types of human cancer," *Genes Chromosomes and Cancer*, vol. 23, no. 1, pp. 78–80, 1998.
- [36] F. Parente, J. Grosgeorge, J. M. Coindre, P. Terrier, O. Vilain, and C. Turc-Carel, "Comparative genomic hybridization reveals novel chromosome deletions in 90 primary soft tissue tumors," *Cancer Genetics and Cytogenetics*, vol. 115, no. 2, pp. 89–95, 1999.
- [37] H. Schmidt, F. Bartel, M. Kappler et al., "Gains of 13q are correlated with a poor prognosis in liposarcoma," *Modern Pathology*, vol. 18, no. 5, pp. 638–644, 2005.
- [38] T. Ohguri, M. Hisaoka, S. Kawauchi et al., "Cytogenetic analysis of myxoid liposarcoma and myxofibrosarcoma by array-based comparative genomic hybridisation," *Journal of Clinical Pathology*, vol. 59, no. 9, pp. 978–983, 2006.
- [39] M. P. Powers, W. L. Wang, V. S. Hernandez et al., "Detection of myxoid liposarcoma-associated FUS-DDIT3 rearrangement variants including a newly identified breakpoint using an optimized RT-PCR assay," *Modern Pathology*, vol. 23, no. 10, pp. 1307–1315, 2010.
- [40] S. M. Willems, Y. M. Schrage, I. H. B. Bruijn, K. Szuhai, P. C. W. Hogendoorn, and J. V. M. G. Bovée, "Kinome profiling of myxoid liposarcoma reveals NF-kappaB-pathway kinase activity and Casein Kinase II inhibition as a potential treatment option," *Molecular Cancer*, vol. 9, article 257, 2010.
- [41] F. Grosso, R. L. Jones, G. D. Demetri et al., "Efficacy of trabectedin (ecteinascidin-743) in advanced pretreated myxoid liposarcomas: a retrospective study," *The Lancet Oncology*, vol. 8, no. 7, pp. 595–602, 2007.
- [42] H. Cheng, J. Dodge, E. Mehl et al., "Validation of immature adipogenic status and identification of prognostic biomarkers in myxoid liposarcoma using tissue microarrays," *Human Pathology*, vol. 40, no. 9, pp. 1244–1251, 2009.
- [43] T. Negri, E. Virdis, S. Brich et al., "Functional mapping of receptor tyrosine kinases in myxoid liposarcoma," *Clinical Cancer Research*, vol. 16, no. 14, pp. 3581–3593, 2010.
- [44] J. Barretina, B. S. Taylor, S. Banerji et al., "Subtype-specific genomic alterations define new targets for soft-tissue sarcoma therapy," *Nature Genetics*, vol. 42, no. 8, pp. 715–721, 2010.
- [45] M. Göransson, M. K. Andersson, C. Forni et al., "The myxoid liposarcoma FUS-DDIT3 fusion oncoprotein deregulates NF-κB target genes by interaction with NFKBIZ," *Oncogene*, vol. 28, no. 2, pp. 270–278, 2009.
- [46] H. L. Evans, "Low-grade fibromyxoid sarcoma. A report of two metastasizing neoplasms having a deceptively benign appearance," *American Journal of Clinical Pathology*, vol. 88, no. 5, pp. 615–619, 1987.

- [47] K. L. Lane, R. J. Shannon, and S. W. Weiss, "Hyalinizing spindle cell tumor with giant rosettes: a distinctive tumor closely resembling low-grade fibromyxoid sarcoma," *American Journal of Surgical Pathology*, vol. 21, no. 12, pp. 1481–1488, 1997.
- [48] S. D. Billings, G. Giblen, and J. C. Fanburg-Smith, "Superficial low-grade fibromyxoid sarcoma (Evans tumor): a clinicopathologic analysis of 19 cases with a unique observation in the pediatric population," *American Journal of Surgical Pathology*, vol. 29, no. 2, pp. 204–210, 2005.
- [49] A. L. Folpe, K. L. Lane, G. Paull, and S. W. Weiss, "Low-grade fibromyxoid sarcoma and hyalinizing spindle cell tumor with giant rosettes: a clinicopathologic study of 73 cases supporting their identity and assessing the impact of high-grade areas," *American Journal of Surgical Pathology*, vol. 24, no. 10, pp. 1353–1360, 2000.
- [50] L. Guillou, J. Benhattar, C. Gengler et al., "Translocation-positive low-grade fibromyxoid sarcoma: clinicopathologic and molecular analysis of a series expanding the morphologic spectrum and suggesting potential relationship to sclerosing epithelioid fibrosarcoma—a study from the French sarcoma group," *American Journal of Surgical Pathology*, vol. 31, no. 9, pp. 1387–1402, 2007.
- [51] C. T. Storlazzi, F. Mertens, A. Nascimento et al., "Fusion of the FUS and BBF2H7 genes in low grade fibromyxoid sarcoma," *Human Molecular Genetics*, vol. 12, no. 18, pp. 2349–2358, 2003.
- [52] I. Panagopoulos, C. T. Storlazzi, C. D. M. Fletcher et al., "The chimeric FUS/CREB3L2 gene is specific for low-grade fibromyxoid sarcoma," *Genes Chromosomes and Cancer*, vol. 40, no. 3, pp. 218–228, 2004.
- [53] F. Mertens, C. D. M. Fletcher, C. R. Antonescu et al., "Clinicopathologic and molecular genetic characterization of low-grade fibromyxoid sarcoma, and cloning of a novel FUS/CREB3L1 fusion gene," *Laboratory Investigation*, vol. 85, no. 3, pp. 408–415, 2005.
- [54] P. A. Bejarano, T. A. Padhya, R. Smith, R. Blough, J. J. Devitt, and L. Gluckman, "Hyalinizing spindle cell tumor with giant rosettes—a soft tissue tumor with mesenchymal and neuroendocrine features: an immunohistochemical, ultrastructural, and cytogenetic analysis," *Archives of Pathology and Laboratory Medicine*, vol. 124, no. 8, pp. 1179–1184, 2000.
- [55] R. Reid, M. V. C. de Silva, L. Paterson, E. Ryan, and C. Fisher, "Low-grade fibromyxoid sarcoma and hyalinizing spindle cell tumor with giant rosettes share a common t(7;16)(q34;p11) translocation," *American Journal of Surgical Pathology*, vol. 27, no. 9, pp. 1229–1236, 2003.
- [56] A. Mezzelani, G. Sozzi, M. Nessling et al., "Low grade fibromyxoid sarcoma: further low-grade soft tissue malignancy characterized by a ring chromosome," *Cancer Genetics and Cytogenetics*, vol. 122, no. 2, pp. 144–148, 2000.
- [57] H. Bartuma, E. Möller, A. Collin et al., "Fusion of the FUS and CREB3L2 genes in a supernumerary ring chromosome in low-grade fibromyxoid sarcoma," *Cancer Genetics and Cytogenetics*, vol. 199, no. 2, pp. 143–146, 2010.
- [58] A. Matsuyama, M. Hisaoka, S. Shimajiri et al., "Molecular detection of FUS-CREB3L2 fusion transcripts in low-grade fibromyxoid sarcoma using formalin-fixed, paraffin-embedded tissue specimens," *American Journal of Surgical Pathology*, vol. 30, no. 9, pp. 1077–1084, 2006.
- [59] I. Panagopoulos, E. Möller, A. Dahlén et al., "Characterization of the native CREB3L2 transcription factor and the FUS/CREB3L2 chimera," *Genes Chromosomes and Cancer*, vol. 46, no. 2, pp. 181–191, 2007.
- [60] Y. Hachitanda, M. Tsuneyoshi, Y. Daimaru et al., "Extraskeletal myxoid chondrosarcoma in young children," *Cancer*, vol. 61, no. 12, pp. 2521–2526, 1988.
- [61] J. M. Meis-Kindblom, P. Bergh, B. Gunterberg, and L. G. Kindblom, "Extraskeletal myxoid chondrosarcoma: a reappraisal of its morphologic spectrum and prognostic factors based on 117 cases," *American Journal of Surgical Pathology*, vol. 23, no. 6, pp. 636–650, 1999.
- [62] J. W. Yi, Y. K. Park, Y. M. Choi, H. P. Hong, and S. G. Chang, "Bulbous urethra involved in perineal extraskeletal myxoid chondrosarcoma in a child," *International Journal of Urology*, vol. 11, no. 6, pp. 436–439, 2004.
- [63] A. M. Oliveira, T. J. Sebo, J. E. McGrory, T. A. Gaffey, M. G. Rock, and A. G. Nascimento, "Extraskeletal myxoid chondrosarcoma: a clinicopathologic, immunohistochemical, and ploidy analysis of 23 cases," *Modern Pathology*, vol. 13, no. 8, pp. 900–908, 2000.
- [64] J. E. McGrory, M. G. Rock, A. G. Nascimento, and A. M. Oliveira, "Extraskeletal myxoid chondrosarcoma," *Clinical Orthopaedics and Related Research*, no. 382, pp. 185–190, 2001.
- [65] S. Kawaguchi, T. Wada, S. Nagoya et al., "Extraskeletal myxoid chondrosarcoma: a multi-institutional study of 42 cases in Japan," *Cancer*, vol. 97, no. 5, pp. 1285–1292, 2003.
- [66] A. D. Drilon, S. Papat, G. Bhuchar et al., "Extraskeletal myxoid chondrosarcoma: a retrospective review from 2 referral centers emphasizing long-term outcomes with surgery and chemotherapy," *Cancer*, vol. 113, no. 12, pp. 3364–3371, 2008.
- [67] M. Hisaoka and H. Hashimoto, "Extraskeletal myxoid chondrosarcoma: updated clinicopathological and molecular genetic characteristics," *Pathology International*, vol. 55, no. 8, pp. 453–463, 2005.
- [68] D. R. Lucas, C. D. M. Fletcher, N. V. Adsay, and M. M. Zalupski, "High-grade extraskeletal myxoid chondrosarcoma: a high-grade epithelioid malignancy," *Histopathology*, vol. 35, no. 3, pp. 201–208, 1999.
- [69] S. Okamoto, M. Hisaoka, T. Ishida et al., "Extraskeletal myxoid chondrosarcoma: a clinicopathologic, immunohistochemical, and molecular analysis of 18 cases," *Human Pathology*, vol. 32, no. 10, pp. 1116–1124, 2001.
- [70] Y. Oshiro, H. Shiratsuchi, S. Tamiya, Y. Oda, S. Toyoshima, and M. Tsuneyoshi, "Extraskeletal myxoid chondrosarcoma with rhabdoid features, with special reference to its aggressive behavior," *International Journal of Surgical Pathology*, vol. 8, no. 2, pp. 145–152, 2000.
- [71] Y. W. Goh, D. V. Spagnolo, M. Platten et al., "Extraskeletal myxoid chondrosarcoma: a light microscopic, immunohistochemical, ultrastructural and immuno-ultrastructural study indicating neuroendocrine differentiation," *Histopathology*, vol. 39, no. 5, pp. 514–524, 2001.
- [72] R. Sciò, P. Dal Cin, C. Fletcher et al., "T(9;22)(q22-31;q11-12) is a consistent marker of extraskeletal myxoid chondrosarcoma: evaluation of three cases," *Modern Pathology*, vol. 8, no. 7, pp. 765–768, 1995.
- [73] G. Stenman, H. Andersson, N. Mandahl, J. M. Meis-Kindblom, and L. G. Kindblom, "Translocation t(9;22)(q22;q12) is a primary cytogenetic abnormality in extraskeletal myxoid chondrosarcoma," *International Journal of Cancer*, vol. 62, no. 4, pp. 398–402, 1995.
- [74] Y. Labelle, J. Zucman, G. Stenman et al., "Oncogenic conversion of a novel orphan nuclear receptor by chromosome translocation," *Human Molecular Genetics*, vol. 4, no. 12, pp. 2219–2226, 1995.

- [75] J. Clark, H. Benjamin, S. Gill et al., "Fusion of the EWS gene to CHN, a member of the steroid/thyroid receptor gene superfamily, in a human myxoid chondrosarcoma," *Oncogene*, vol. 12, no. 2, pp. 229–235, 1996.
- [76] R. I. Brody, T. Ueda, A. Hamelin et al., "Molecular analysis of the fusion of EWS to an orphan nuclear receptor gene in extraskeletal myxoid chondrosarcoma," *American Journal of Pathology*, vol. 150, no. 3, pp. 1049–1058, 1997.
- [77] I. Panagopoulos, F. Mertens, M. Isaksson et al., "Molecular genetic characterization of the EWS/CHN and RBP56/CHN fusion genes in extraskeletal myxoid chondrosarcoma," *Genes Chromosomes and Cancer*, vol. 35, no. 4, pp. 340–352, 2002.
- [78] H. Sjögren, J. M. Meis-Kindblom, C. Örndal et al., "Studies on the molecular pathogenesis of extraskeletal myxoid chondrosarcoma—cytogenetic, molecular genetic, and cDNA microarray analyses," *American Journal of Pathology*, vol. 162, no. 3, pp. 781–792, 2003.
- [79] I. Panagopoulos, M. Mencinger, C. U. Dietrich et al., "Fusion of the RBP56 and CHN genes in extraskeletal myxoid chondrosarcomas with translocation t(9;17)(q22;q11)," *Oncogene*, vol. 18, no. 52, pp. 7594–7598, 1999.
- [80] C. Attwooll, M. Tariq, M. Harris, J. D. Coyne, N. Telford, and J. M. Varley, "Identification of a novel fusion gene involving hTAF(II)68 and CHN from a t(9;17)(q22;q11.2) translocation in an extraskeletal myxoid chondrosarcoma," *Oncogene*, vol. 18, no. 52, pp. 7599–7601, 1999.
- [81] H. Sjögren, J. Meis-Kindblom, L. G. Kindblom, P. Åman, and G. Stenman, "Fusion of the EWS-related gene TAF2N to TEC in extraskeletal myxoid chondrosarcoma," *Cancer Research*, vol. 59, no. 20, pp. 5064–5067, 1999.
- [82] M. Harris, J. Coyne, M. Tariq et al., "Extraskeletal myxoid chondrosarcoma with neuroendocrine differentiation: a pathologic, cytogenetic, and molecular study of a case with a novel translocation t(9;17)(q22;q11.2)," *American Journal of Surgical Pathology*, vol. 24, no. 7, pp. 1020–1026, 2000.
- [83] H. Sjögren, B. Wedell, J. M. Meis Kindblom, L. G. Kindblom, and G. Stenman, "Fusion of the NH2-terminal domain of the basic helix-loop-helix protein TCF12 to TEC in extraskeletal myxoid chondrosarcoma with translocation t(9;15)(q22;q21)," *Cancer Research*, vol. 60, no. 24, pp. 6832–6835, 2000.
- [84] M. Hisaoka, T. Ishida, T. Imamura, and H. Hashimoto, "TFG is a novel fusion partner of NOR1 in extraskeletal myxoid chondrosarcoma," *Genes Chromosomes and Cancer*, vol. 40, no. 4, pp. 325–328, 2004.
- [85] Y. Labelle, J. Bussi eres, F. Courjal, and M. B. Goldring, "The EWS/TEC fusion protein encoded by the t(9;22) chromosomal translocation in human chondrosarcomas is a highly potent transcriptional activator," *Oncogene*, vol. 18, no. 21, pp. 3303–3308, 1999.
- [86] N. Ohkura, Y. Nagamura, and T. Tsukada, "Differential transactivation by orphan nuclear receptor NOR1 and its fusion gene product EWS/NOR1: possible involvement of poly(ADP-ribose) polymerase I, PARP-1," *Journal of Cellular Biochemistry*, vol. 105, no. 3, pp. 785–800, 2008.
- [87] S. Kim, J. L. Hye, J. J. Hee, and J. Kim, "The hTAFII68-TEC fusion protein functions as a strong transcriptional activator," *International Journal of Cancer*, vol. 122, no. 11, pp. 2446–2453, 2008.
- [88] S. Subramanian, R. B. West, R. J. Marinelli et al., "The gene expression profile of extraskeletal myxoid chondrosarcoma," *Journal of Pathology*, vol. 206, no. 4, pp. 433–444, 2005.
- [89] C. Filion, T. Motoi, A. B. Olshen et al., "The EWSRI/NR4A3 fusion protein of extraskeletal myxoid chondrosarcoma activates the PPAR $\gamma$  nuclear receptor gene," *Journal of Pathology*, vol. 217, no. 1, pp. 83–93, 2009.
- [90] H. Ohki-Hamazaki, "Neuromedin B," *Progress in Neurobiology*, vol. 62, no. 3, pp. 297–312, 2000.
- [91] B. M. Forman, P. Tontonoz, J. Chen, R. P. Brun, B. M. Spiegelman, and R. M. Evans, "15-deoxy- $\Delta$ 12, 14-prostaglandin J2 is a ligand for the adipocyte determination factor PPAR $\gamma$ ," *Cell*, vol. 83, no. 5, pp. 803–812, 1995.
- [92] A. F. Nascimento, F. Bertoni, and C. D. M. Fletcher, "Epithelioid variant of myxofibrosarcoma: expanding the clinicomorphologic spectrum of myxofibrosarcoma in a series of 17 cases," *American Journal of Surgical Pathology*, vol. 31, no. 1, pp. 99–105, 2007.
- [93] C. Merck, L. Angervall, L. G. Kindblom, and A. Od en, "Myxofibrosarcoma. A malignant soft tissue tumor of fibro-blastic histiocytic origin. A clinicopathologic and prognostic study of 110 cases using multivariate analysis," *Acta Pathologica, Microbiologica et Immunologica Scandinavica—Supplementum*, vol. 282, pp. 1–40, 1983.
- [94] T. Mentzel, E. Calonje, C. Wadden et al., "Myxofibrosarcoma: clinicopathologic analysis of 75 cases with emphasis on the low-grade variant," *American Journal of Surgical Pathology*, vol. 20, no. 4, pp. 391–405, 1996.
- [95] H. Y. Huang, P. Lal, J. Qin, M. F. Brennan, and C. R. Antonescu, "Low-grade myxofibrosarcoma: a clinicopathologic analysis of 49 cases treated at a single institution with simultaneous assessment of the efficacy of 3-tier and 4-tier grading systems," *Human Pathology*, vol. 35, no. 5, pp. 612–621, 2004.
- [96] F. Mertens, C. D. M. Fletcher, P. Dal Cin et al., "Cytogenetic analysis of 46 pleomorphic soft tissue sarcomas and correlation with morphologic and clinical features: a report of the champ study group," *Genes Chromosomes and Cancer*, vol. 22, no. 1, pp. 16–25, 1998.
- [97] H. Kawashima, A. Ogose, W. Gu et al., "Establishment and characterization of a novel myxofibrosarcoma cell line," *Cancer Genetics and Cytogenetics*, vol. 161, no. 1, pp. 28–35, 2005.
- [98] S. M. Willems, M. Debiec-Rychter, K. Szuhai, P. C. W. Hogendoorn, and R. Sciot, "Local recurrence of myxofibrosarcoma is associated with increase in tumour grade and cytogenetic aberrations, suggesting a multistep tumour progression model," *Modern Pathology*, vol. 19, no. 3, pp. 407–416, 2006.
- [99] A. M. Meloni-Ehrig, Z. Chen, X. Y. Guan et al., "Identification of a ring chromosome in a myxoid malignant fibrous histiocytoma with chromosome microdissection and fluorescence in situ hybridization," *Cancer Genetics and Cytogenetics*, vol. 109, no. 1, pp. 81–85, 1999.
- [100] M. Nilsson, L. A. Meza-Zepeda, F. Mertens, A. Forus, O. Myklebost, and N. Mandahl, "Amplification of chromosome 1 sequences in lipomatous tumors and other sarcomas," *International Journal of Cancer*, vol. 109, no. 3, pp. 363–369, 2004.
- [101] A. Idbah, J. M. Coindre, J. Derr e et al., "Myxoid malignant fibrous histiocytoma and pleomorphic liposarcoma share very similar genomic imbalances," *Laboratory Investigation*, vol. 85, no. 2, pp. 176–181, 2005.
- [102] S. H. Kresse, H. O. Ohnstad, B. Bjerkehaugen, O. Myklebost, and L. A. Meza-Zepeda, "DNA copy number changes in human malignant fibrous histiocytomas by array comparative genomic hybridisation," *PLoS ONE*, vol. 5, no. 11, article e15378, 2010.



- [103] J. C. Lee, C. F. Li, F. M. Fang et al., "Prognostic implication of MET overexpression in myxofibrosarcomas: an integrative array comparative genomic hybridization, real-time quantitative PCR, immunoblotting, and immunohistochemical analysis," *Modern Pathology*, vol. 23, no. 10, pp. 1379–1392, 2010.
- [104] R. Nakayama, T. Nemoto, H. Takahashi et al., "Gene expression analysis of soft tissue sarcomas: characterization and reclassification of malignant fibrous histiocytoma," *Modern Pathology*, vol. 20, no. 7, pp. 749–759, 2007.
- [105] J. W. Russo and J. J. Castellot, "CCN5: biology and pathophysiology," *Journal of Cell Communication and Signaling*, vol. 4, no. 3, pp. 119–130, 2010.
- [106] H. Obermann, A. Samalecos, C. Osterhoff, B. Schröder, R. Heller, and C. Kirchhoff, "HE6, a two-subunit heptahelical receptor associated with apical membranes of efferent and epididymal duct epithelia," *Molecular Reproduction and Development*, vol. 64, no. 1, pp. 13–26, 2003.
- [107] G. H. Burch, Y. Gong, W. Liu et al., "Tenascin-X deficiency is associated with Ehlers-Danlos syndrome," *Nature Genetics*, vol. 17, no. 1, pp. 104–108, 1997.
- [108] E. A. Montgomery, K. O. Devaney, T. J. Giordano, and S. W. Weiss, "Inflammatory myxohyaline tumor of distal extremities with virocyte or Reed-Sternberg-like cells: a distinctive lesion with features simulating inflammatory conditions, Hodgkin's disease, and various sarcomas," *Modern Pathology*, vol. 11, no. 4, pp. 384–391, 1998.
- [109] J. M. Meis-Kindblom and L. G. Kindblom, "Acral myxoinflammatory fibroblastic sarcoma: a low-grade tumor of the hands and feet," *American Journal of Surgical Pathology*, vol. 22, no. 8, pp. 911–924, 1998.
- [110] A. Tejwani, W. Kobayashi, Y. L. E. Chen et al., "Management of acral myxoinflammatory fibroblastic sarcoma," *Cancer*, vol. 116, no. 24, pp. 5733–5739, 2010.
- [111] I. Lambert, M. Debiec-Rychter, P. Guelinckx, A. Hagemeyer, and R. Sciot, "Acral myxoinflammatory fibroblastic sarcoma with unique clonal chromosomal changes," *Virchows Archiv*, vol. 438, no. 5, pp. 509–512, 2001.
- [112] A. Mansoor, N. Fidda, E. Himoe, M. Payne, H. Lawce, and R. E. Magenis, "Myxoinflammatory fibroblastic sarcoma with complex supernumerary ring chromosomes composed of chromosome 3 segments," *Cancer Genetics and Cytogenetics*, vol. 152, no. 1, pp. 61–65, 2004.
- [113] K. H. Hallor, R. Sciot, J. Staaf et al., "Two genetic pathways, t(1;10) and amplification of 3p11-12, in myxoinflammatory fibroblastic sarcoma, haemosiderotic fibrolipomatous tumour, and morphologically similar lesions," *Journal of Pathology*, vol. 217, no. 5, pp. 716–727, 2009.
- [114] C. M. Ida, K. A. Rolig, R. L. Hulshizer et al., "Myxoinflammatory fibroblastic sarcoma showing t(2;6)(q31;p21.3) as a sole cytogenetic abnormality," *Cancer Genetics and Cytogenetics*, vol. 177, no. 2, pp. 139–142, 2007.
- [115] C. R. Antonescu, L. Zhang, G.P. Nielsen, A.E. Rosenberg, P. Dal Cin, and C.D. Fletcher, "Consistent t(1;10) abnormality in both myxoinflammatory fibroblastic sarcoma (MIFS) and hemosiderotic fibrolipomatous tumor (HFLT)," *Modern Pathology*, vol. 24, supplement 1, p. 9A, 2011.
- [116] G. R. Wetzach, L. J. Boyd, H. J. Lawce, R. E. Magenis, and A. Mansoor, "Cytogenetic analysis of a hemosiderotic fibrolipomatous tumor," *Cancer Genetics and Cytogenetics*, vol. 182, no. 2, pp. 140–143, 2008.
- [117] C. P. Elco, A. Mariño-Enríquez, J. A. Abraham, P. Dal Cin, and J. L. Hornick, "Hybrid myxoinflammatory fibroblastic sarcoma/hemosiderotic fibrolipomatous tumor: report of a case providing further evidence for a pathogenetic link," *American Journal of Surgical Pathology*, vol. 34, no. 11, pp. 1723–1727, 2010.
- [118] D. Baumhoer, K. Glatz, H. J. Schulten et al., "Myxoinflammatory fibroblastic sarcoma: investigations by comparative genomic hybridization of two cases and review of the literature," *Virchows Archiv*, vol. 451, no. 5, pp. 923–928, 2007.
- [119] Z. Hélias-Rodzewicz, G. Pérot, F. Chibon et al., "YAP1 and VGLL3, encoding two cofactors of TEAD transcription factors, are amplified and overexpressed in a subset of soft tissue sarcomas," *Genes Chromosomes and Cancer*, vol. 49, no. 12, pp. 1161–1171, 2010.
- [120] M. M. Mattila and P. L. Härkönen, "Role of fibroblast growth factor 8 in growth and progression of hormonal cancer," *Cytokine and Growth Factor Reviews*, vol. 18, no. 3-4, pp. 257–266, 2007.
- [121] H. F. Frierson and P. H. Cooper, "Myxoid variant of dermatofibrosarcoma protuberans," *American Journal of Surgical Pathology*, vol. 7, no. 5, pp. 445–450, 1983.
- [122] J. D. R. Reimann and C. D. M. Fletcher, "Myxoid dermatofibrosarcoma protuberans: a rare variant analyzed in a series of 23 cases," *American Journal of Surgical Pathology*, vol. 31, no. 9, pp. 1371–1377, 2007.
- [123] T. Mentzel, L. Schäfer, D. V. Kazakov, and M. Michal, "Myxoid dermatofibrosarcoma protuberans: clinicopathologic, immunohistochemical, and molecular analysis of eight cases," *American Journal of Dermatopathology*, vol. 29, no. 5, pp. 443–448, 2007.
- [124] G. Maire, S. Fraitag, L. Galmiche et al., "A clinical, histologic, and molecular study of 9 cases of congenital dermatofibrosarcoma protuberans," *Archives of Dermatology*, vol. 143, no. 2, pp. 203–210, 2007.
- [125] M. Fiore, R. Miceli, C. Mussi et al., "Dermatofibrosarcoma protuberans treated at a single institution: a surgical disease with a high cure rate," *Journal of Clinical Oncology*, vol. 23, no. 30, pp. 7669–7675, 2005.
- [126] R. B. West, J. Harvell, S. C. Linn et al., "Apo D in soft tissue tumors: a novel marker for dermatofibrosarcoma protuberans," *American Journal of Surgical Pathology*, vol. 28, no. 8, pp. 1063–1069, 2004.
- [127] F. Pedeutour, M. P. Simon, F. Minoletti et al., "Translocation, t(17;22)(q22;q13), in dermatofibrosarcoma protuberans: a new tumor-associated chromosome rearrangement," *Cytogenetics and Cell Genetics*, vol. 72, no. 2-3, pp. 171–174, 1996.
- [128] M. P. Simon, F. Pedeutour, N. Sirvent et al., "Deregulation of the platelet-derived growth factor B-chain gene via fusion with collagen gene COL1A1 in dermatofibrosarcoma protuberans and giant-cell fibroblastoma," *Nature Genetics*, vol. 15, no. 1, pp. 95–98, 1997.
- [129] A. A. Sandberg and J. A. Bridge, "Updates on the cytogenetics and molecular genetics of bone and soft tissue tumors: dermatofibrosarcoma protuberans and giant cell fibroblastoma," *Cancer Genetics and Cytogenetics*, vol. 140, no. 1, pp. 1–12, 2003.
- [130] N. Sirvent, G. Maire, and F. Pedeutour, "Genetics of dermatofibrosarcoma protuberans family of tumors: from ring chromosomes to tyrosine kinase inhibitor treatment," *Genes Chromosomes and Cancer*, vol. 37, no. 1, pp. 1–19, 2003.

- [131] J. Nishio, H. Iwasaki, M. Ishiguro et al., "Supernumerary ring chromosome in a Bednar tumor (pigmented dermatofibrosarcoma protuberans) is composed of interspersed sequences from chromosomes 17 and 22: a fluorescence in situ hybridization and comparative genomic hybridization analysis," *Genes Chromosomes and Cancer*, vol. 30, no. 3, pp. 305–309, 2001.
- [132] G. Maire, F. Pédeutour, and J. M. Coindre, "COL1A1-PDGFB gene fusion demonstrates a common histogenetic origin for dermatofibrosarcoma protuberans and its granular cell variant," *American Journal of Surgical Pathology*, vol. 26, no. 7, pp. 932–937, 2002.
- [133] J. Wang, Y. Morimitsu, S. Okamoto et al., "COL1A1-PDGFB fusion transcripts in fibrosarcomatous areas of six dermatofibrosarcomas protuberans," *Journal of Molecular Diagnostics*, vol. 2, no. 1, pp. 47–52, 2000.
- [134] H. Mahajan, R. Sharma, A. Darmanian, and G. B. Peters, "Fibrosarcomatous variant of dermatofibrosarcoma protuberans showing COL1A1-PDGFB gene fusion, detected using a novel and disease-specific RT-PCR protocol," *Pathology*, vol. 42, no. 5, pp. 488–491, 2010.
- [135] R. D. Craver, H. Correa, Y. Kao, and T. Van Brunt, "Dermatofibrosarcoma protuberans with 46,XY,t(X;7) abnormality in a child," *Cancer Genetics and Cytogenetics*, vol. 80, no. 1, pp. 75–77, 1995.
- [136] J. Sinovic and J. A. Bridge, "Translocation (2;17) in recurrent dermatofibrosarcoma protuberans [1]," *Cancer Genetics and Cytogenetics*, vol. 75, no. 2, pp. 156–157, 1994.
- [137] H. Sonobe, M. Furihata, J. Iwata et al., "Dermatofibrosarcoma protuberans harboring t(9;22)(q32;q12.2)," *Cancer Genetics and Cytogenetics*, vol. 110, no. 1, pp. 14–18, 1999.
- [138] L. Bianchini, G. Maire, B. Guillot et al., "Complex t(5;8) involving the CSPG2 and PTK2B genes in a case of dermatofibrosarcoma protuberans without the COL1A1-PDGFB fusion," *Virchows Archiv*, vol. 452, no. 6, pp. 689–696, 2008.
- [139] S. Kiuru-Kuhlefelt, W. El-Rifai, J. Fanburg-Smith, J. Kere, M. Miettinen, and S. Knuutila, "Concomitant DNA copy number amplification at 17q and 22q in dermatofibrosarcoma protuberans," *Cytogenetics and Cell Genetics*, vol. 92, no. 3-4, pp. 192–195, 2001.
- [140] J. Nishio, H. Iwasaki, Y. Ohjimi et al., "Overrepresentation of 17q22~qter and 22q13 in dermatofibrosarcoma protuberans but not in dermatofibroma: comparative genomic hybridization study," *Cancer Genetics and Cytogenetics*, vol. 132, no. 2, pp. 102–108, 2002.
- [141] S. Kaur, H. Vauhkonen, T. Böbling, F. Mertens, N. Mandahl, and S. Knuutila, "Gene copy number changes in dermatofibrosarcoma protuberans—a fine-resolution study using array comparative genomic hybridization," *Cytogenetic and Genome Research*, vol. 115, no. 3-4, pp. 283–288, 2006.
- [142] J. Nishio, H. Iwasaki, Y. Ohjimi et al., "Supernumerary ring chromosomes in dermatofibrosarcoma protuberans may contain sequences from 8q11.2~qter and 17q21~qter: a combined cytogenetic and comparative genomic hybridization study," *Cancer Genetics and Cytogenetics*, vol. 129, no. 2, pp. 102–106, 2001.
- [143] J. J. Abbott, M. Erickson-Johnson, X. Wang, A. G. Nascimento, and A. M. Oliveira, "Gains of COL1A1-PDGFB genomic copies occur in fibrosarcomatous transformation of dermatofibrosarcoma protuberans," *Modern Pathology*, vol. 19, no. 11, pp. 1512–1518, 2006.
- [144] S. Segura, R. Salgado, A. Toll et al., "Identification of t(17;22)(q22;q13) (COL1A1/PDGFB) in dermatofibrosarcoma protuberans by fluorescence in situ hybridization in paraffin-embedded tissue microarrays," *Human Pathology*, vol. 42, no. 2, pp. 176–184, 2011.
- [145] R. Salgado, B. Llombart, R. M. Pujol et al., "Molecular diagnosis of dermatofibrosarcoma protuberans: a comparison between reverse transcriptase-polymerase chain reaction and fluorescence in situ hybridization methodologies," *Genes Chromosomes and Cancer*, vol. 50, no. 7, pp. 510–517, 2011.
- [146] D. Giaccherio, G. Maire, P. A. S. Nuin et al., "No correlation between the molecular subtype of COL1A1-PDGFB fusion gene and the clinico-histopathological features of dermatofibrosarcoma protuberans," *Journal of Investigative Dermatology*, vol. 130, no. 3, pp. 904–907, 2010.
- [147] C. H. Heldin, A. Östman, and L. Rönnstrand, "Signal transduction via platelet-derived growth factor receptors," *Biochimica et Biophysica Acta*, vol. 1378, no. 1, pp. F79–F113, 1998.
- [148] A. Shimizu, K. P. O'Brien, T. Sjöblom et al., "The dermatofibrosarcoma protuberans-associated collagen type I $\alpha$ 1/platelet-derived growth factor (PDGF) B-chain fusion gene generates a transforming protein that is processed to functional PDGF-BB," *Cancer Research*, vol. 59, no. 15, pp. 3719–3723, 1999.
- [149] R. G. Maki, R. A. Awan, R. H. Dixon, S. Jhanwar, and C. R. Antonescu, "Differential sensitivity to imatinib of 2 patients with metastatic sarcoma arising from dermatofibrosarcoma protuberans," *International Journal of Cancer*, vol. 100, no. 6, pp. 623–626, 2002.
- [150] P. Rutkowski, M. Van Glabbeke, C. J. Rankin et al., "Imatinib mesylate in advanced dermatofibrosarcoma protuberans: pooled analysis of two phase II clinical trials," *Journal of Clinical Oncology*, vol. 28, no. 10, pp. 1772–1779, 2010.
- [151] D. Kéro, R. Porcher, O. Vérola et al., "Imatinib mesylate as a preoperative therapy in dermatofibrosarcoma: results of a multicenter phase II study on 25 patients," *Clinical Cancer Research*, vol. 16, no. 12, pp. 3288–3295, 2010.
- [152] B. Llombart, O. Sanmartín, J. A. López-Guerrero et al., "Dermatofibrosarcoma protuberans: clinical, pathological, and genetic (COL1A1-PDGFB) study with therapeutic implications," *Histopathology*, vol. 54, no. 7, pp. 860–872, 2009.
- [153] S. C. Linn, R. B. West, J. R. Pollack et al., "Gene expression patterns and gene copy number changes in dermatofibrosarcoma protuberans," *American Journal of Pathology*, vol. 163, no. 6, pp. 2383–2395, 2003.
- [154] M. Unoki and Y. Nakamura, "Growth-suppressive effects of BPOZ and EGR2, two genes involved in the PTEN signaling pathway," *Oncogene*, vol. 20, no. 33, pp. 4457–4465, 2001.