

Can a high acromion index predict rotator cuff tears?

Jung Ryul Kim · Keun Jung Ryu · In Tae Hong ·
Byung Kook Kim · Jae Hwa Kim

Received: 19 December 2011 / Accepted: 16 January 2012 / Published online: 8 February 2012
© Springer-Verlag 2012

Abstract

Purpose The purpose of this study was to identify the relationship between an acromion index (AI) and the size of a rotator cuff tear. The hypothesis of our study was that an AI will be higher in patients with a full-thickness tear than in patients with a partial-thickness articular-side tear, and that it can be used as a predictor for the size of a rotator cuff tear.

Methods We included 284 patients who had been diagnosed with rotator cuff tears and had undergone arthroscopic rotator cuff repair at our institute. All patients were divided into five distinct groups (partial-thickness articular side tear, and four subgroups of full-thickness tears) depending on the size of the rotator cuff tear on arthroscopy. In each patient, an AI was measured on the pre-operative oblique coronal MR images and then analysed to determine the difference between groups.

Results There were statistically significant differences between the partial-thickness articular side rotator cuff tear and large-to-massive rotator cuff tear groups ($p < 0.01$), and the mean value of an AI was highest in the large-sized full-thickness tear group. The AI of the partial-thickness articular-side rotator cuff tear group was statistically different from the large-to-massive rotator cuff tear groups.

Conclusions The AI can be a predictor which can differentiate a partial-thickness articular-side tear and a large-to-massive rotator cuff tear pre-operatively. However the AI could not provide useful guidance on predicting the differences in tear size in full-thickness tear patients. We suggest that a high AI can be one of the associated factors for progression to large-to-massive rotator cuff tears in a rotator cuff disease.

Introduction

Since Neer [1] first described the impingement syndrome in 1972, several authors have investigated and described the morphology of an acromion, with regards to its shape [2], anterior slope [3], lateral acromion angle [4], and relationship with rotator cuff disease. Recently, Nyffeler et al. [5] introduced an acromion index (AI), the lateral extension of an acromion above the humeral head, as a new biomechanical value and hypothesized that a large lateral extension of an acromion predisposes the supraspinatus tendon to degenerate because of its impingement between an acromion and the higher ascending force of a deltoid muscle. Torrens et al. [6] also reported a relationship between the large coverage of a humeral head by an acromion and the rotator cuff tears, and it had similar results to Nyffeler's study [5]. The importance of an AI was strengthened by Zumstein et al. [7], who found that the patients with re-tear following rotator cuff repair had higher AI than the patients without re-tear.

From this point of view, we can presume that a high AI favours not only a rotator cuff tear, but also a progression of a size of rotator cuff tear itself. This study is to identify the difference of an AI among the patients with the partial-thickness, full-thickness, or massive rotator cuff tears.

J. R. Kim · K. J. Ryu · I. T. Hong · J. H. Kim (✉)
Department of Orthopaedic Surgery, CHA Bundang Medical
Center, CHA University School of Medicine,
351 Yatap-dong, Bundang-gu,
Sung-nam, South Korea
e-mail: Ddolmania@yahoo.com

B. K. Kim
Department of Orthopaedic Surgery, CHA Gumi Medical Center,
CHA University School of Medicine,
855 Hyungkok-dong, 12 Sinsi-ro 10gil, Gumi-si,
Kyungsangbuk-do, Republic of Korea

Methods

We performed a retrospective study based on magnetic resonance imaging (MRI) and surgical records of 284 patients who had been diagnosed with a rotator cuff tear, verified by pre-operative MRI and intra-operative arthroscopic findings, and had undergone arthroscopic rotator cuff repair at our institution between January 2007 and December 2009. To eliminate the effect of the patients' age on AI, we limited age to between 45 and 65 years. Patients who had a history of trauma, inflammatory disease, or previous surgery on the acromion of the affected side were excluded from the study. Patients showing an arthritic change in the glenohumeral joint or a collapse of a humeral head were also excluded, because such changes can produce outliers to the AI.

Postoperatively, the patients were divided into five groups according to the classification of DeOrio and Cofield [8], which was based on the size of the rotator cuff tear (group A, partial-thickness articular side tears; group B, full-thickness small-sized tears; group C, full-thickness medium-sized tears; group D, full-thickness large-sized tears; group E, massive tears).

In order to avoid the influence of the rotation of the scapula or humeral head, the AI was measured on the pre-operative oblique coronal MR images done by Nyffeler et al. [5] described for a true anteroposterior shoulder radiograph. Each patient was positioned supine with the humerus in neutral rotation and the arm adducted to the side. Oblique coronal images were obtained by aligning the image plane in the course of the supraspinatus tendon, as identified on the axial image. Standardized MR images were obtained in all patients with two 1.5-T superconducting magnets (Magenetom Vision and Sonata, Siemens Medical System, Erlangen, Germany).

Both the distance from the glenoid to the acromion (GA) and from the glenoid to the lateral aspect of the humeral head (GT) were measured in all patients. Next, the AI, which is the ratio of these two distances (GA/GT) was calculated (Fig. 1). All measurements were performed by two independent investigators at our institution.

All measurements were tested for normality using the Shapiro-Wilk test and accepted as having a normal assumption. Measurements were expressed as mean \pm standard deviation with its range for all continuous variables. Pearson correlation analysis was used to see the relationship between the measured AIs and the patients' age. Student t-test was performed to calculate the difference in the AIs between sexes. Also, an analysis of variance (ANOVA) was performed to determine if there was any significant difference in AI between the five distinct groups. Tukey's multiple comparison analysis was conducted for further sub-categorization of the five distinct groups. The statistical software, MedCalc (ver. 11.6 MedCalc Software,

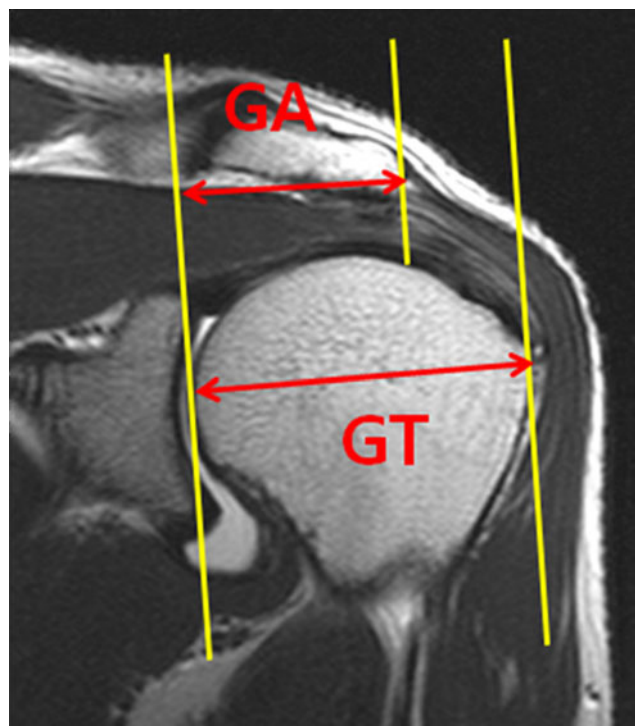


Fig. 1 Measuring of an acromion index (AI). An AI, i.e. lateral extension of an acromion, can be measured by dividing the distance from the glenoid plane to the acromial end (GA) with the distance from the glenoid plane to the most lateral part of the humeral head (GT) on oblique coronal MR image

Broekstraat 52, 9030, Mariakerke, Belgium) and R (ver. 2.12 Comprehensive R Archive Network, GNU General Public License, Massachusetts, USA) were used for all statistical analyses. $P \leq 0.05$ was considered significant. Post hoc power analysis showed that the sample size of our study was large enough to fulfill 80% of the power and 0.05 of the alpha. This study was authorized by the Institutional Review Board at our institution.

Results

The inter-observer correlation was found to be excellent (Cronbach's alpha, 0.893). The mean and maximum differences between the measurements of the two observers were 0.00 ± 0.03 and 0.09, respectively. The average age of patients was 55.14 years (range 46–65, SD 5.540). The measured AI had an average of 0.666 cm (range 0.487–0.794, SD 0.062) and had no relationship with the patient's age (Pearson correlation coefficient $r=0.052$, $p=0.192$) (Fig. 2). Among 284 patients, there were 132 females and 152 males. Student t-test was used to analyse the difference of the AI between sexes, and the result showed that the AI was not significantly different between sexes ($p=0.423$) (Fig. 3).

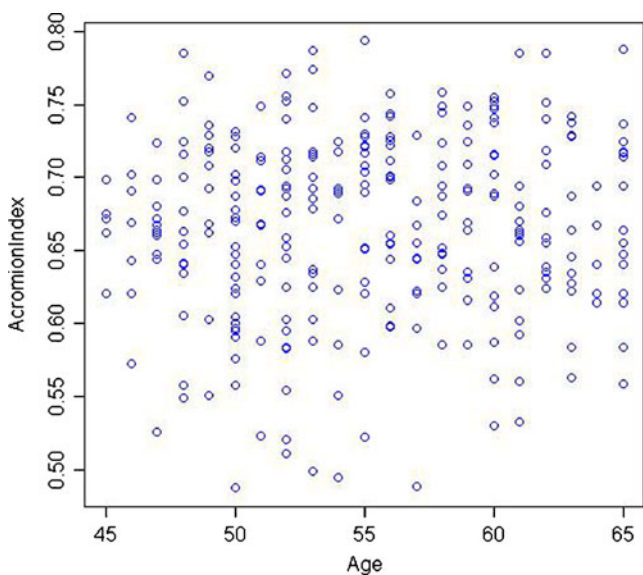


Fig. 2 Scatter plot of an acromion index (AI) with the patients' age. An AI has no relationship with the patients' age (Pearson correlation coefficient is not statistically significant, $r=0.052$, $p=0.192$; AI is measured in centimetres; age is given in years)

However, the AI was significantly different between the five distinct groups which had different rotator cuff tear sizes ($p<0.01$) (Fig. 4). The measured AI and the number of patients in each group are shown in Table 1. The average AI increased as the tear size of the rotator cuff tendon increased (from group A to group D), peaked in group D and slightly decreased in group E. Tukey's multiple comparison

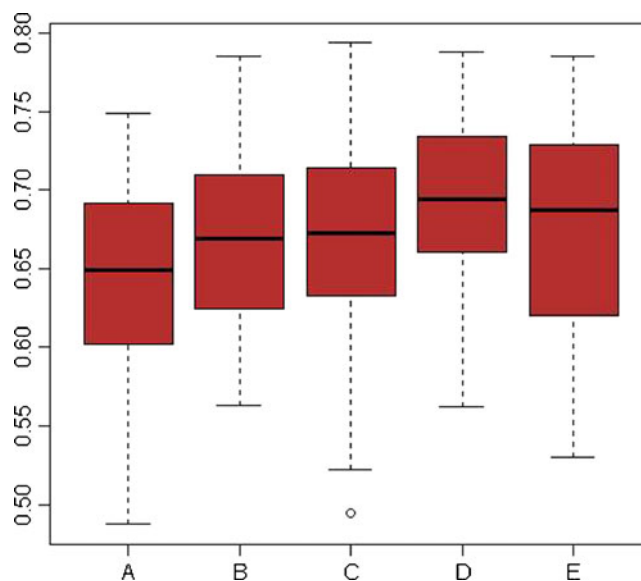


Fig. 4 Boxplot of an acromion index (AI) for each group. An AI is significantly different between groups ($p<0.01$ via analysis of variance). The vertical axis is AI and the horizontal axis is the five distinct tear size groups, i.e. A partial-thickness articular side tear group, B small-sized full-thickness tear group, C medium-sized full-thickness tear group, D large-sized full-thickness tear group, E massive tear group (AI is measured in centimetres)

analysis was performed to sub-categorize these five groups based on AIs. It showed that there was a significant difference between groups A and D. There was also a significant difference between groups A and E. However, there was no significant difference between groups A, B, and C. Likewise there was no significant difference between groups D and E (Fig. 5).

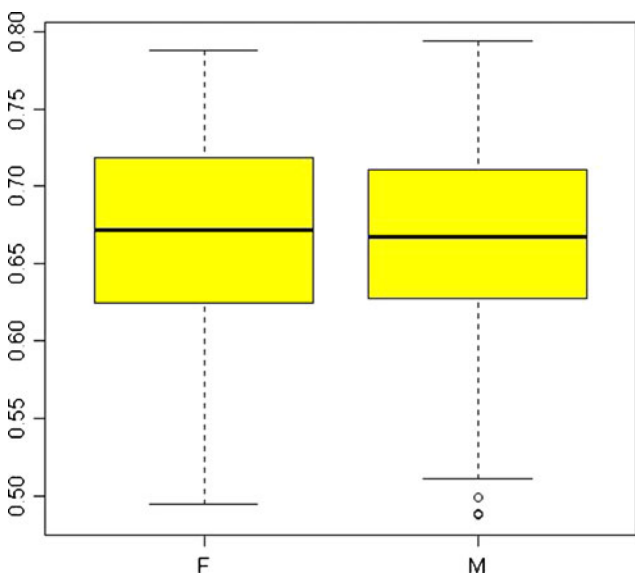


Fig. 3 Boxplot of an acromion index with respect to the patient's sex. An acromion index (AI) is not significantly different between sexes ($p=0.423$ via t-test) (vertical axis: AI; horizontal axis: female [F], male [M]; AI is measured in centimetres)

Discussion

As far as we know, this is the first report that shows the quantitative relationship between an AI and tear size of the rotator cuff tendon. In this study, there are two important clinical findings. First, the AI was statistically different in the partial-thickness articular side rotator cuff tear group and the large-to-massive rotator cuff tear groups. Second, the differences among full-thickness tear groups had no statistical significance

The pathogenesis of rotator cuff tears has been considered the result of a combination of intrinsic and extrinsic factors, yet it has not been fully elucidated. Degenerative change [9], hypovascularity [10], and micro-structural collagen fibre abnormalities [11] are recognized as the intrinsic factors, and subacromial impingement [12, 13], tensile overload [14], and the repetitive use [15] are recognized as the extrinsic factors.

Table 1 Acromion index (AI) and the number of patients in each group. The average AI in the large-sized full-thickness tear group is higher than in any other group (AI is measured in centimetres)

Group	N	Acromion Index (mean \pm SD, range)
A (partial-thickness tear)	68	0.640 \pm 0.064 (0.487–0.749)
B (small-sized tear)	44	0.667 \pm 0.052 (0.563–0.786)
C (medium-sized tear)	88	0.667 \pm 0.060 (0.494–0.794)
D (large-sized tear)	43	0.693 \pm 0.053 (0.562–0.788)
E (massive tear)	41	0.675 \pm 0.067 (0.530–0.786)

Since Neer [1, 16] reported the impingement theory of the rotator cuff tears, there have been numerous detailed studies [2, 9, 12, 13, 17–21] on the association of the morphologic features of an acromion and glenoid axis with rotator cuff disease. However, whether these are the real risk factors that cause rotator cuff pathology or whether these features are the true cause or effect of rotator cuff tears is still an ongoing debate.

In a case report about a spur recurrence after acromioplasty, Anderson and Bowen [22] proposed that morphologic features of an acromion may be a reactive change that attributes to a primary cuff lesion. On the other hand, Panni et al. [23] and Bonsell et al. [24] suggested that a spur is a degenerative change that increases with age, and is not associated with rotator cuff tears.

Recently, Nyffeler et al. [5] introduced the AI as a new biomechanical value which described the lateral extension of an acromion above the humeral head. They assumed that the force vector of deltoid muscle can increase the joint contraction and may induce subacromial abrasion of the rotator cuff tendons when the acromion extends more laterally. They found that the lateral extension of the acromion was significantly larger in patients with rotator cuff tears than in patients without tears. In contrast to

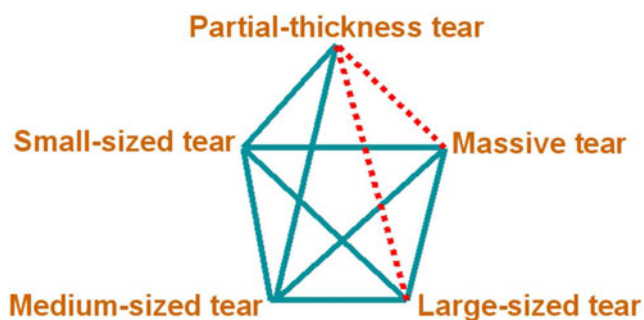


Fig. 5 Diagram showing the result of Tukey's multiple comparison between the five groups. An acromion index (AI) of the partial-thickness articular side rotator cuff tear group can be differentiated from the ones in large-sized full-thickness tear or massive rotator cuff tear groups. (Continuous line indicates no significant difference in AI between two groups. Dotted line indicates significant difference in AI between two groups)

these findings, Kappe et al. [25] found that the acromion index was not different among patients with calcifying tendinitis, partial-thickness or full-thickness rotator cuff tears. Although it is debatable whether the acromion index is the cause of a rotator cuff tear or not, evaluation of the relationship between the AI and rotator cuff tears could be important because the AI could provide useful guidance on the diagnosis and treatment of rotator cuff tears.

From the above findings, evaluating the quantitative relationship between an AI and the size of rotator cuff tears could be meaningful and we can assume that an AI could provide useful guidance on the pre-operative planning and postoperative rehabilitation.

In pathologic studies, Iannotti et al. [26] and Ko et al. [27] showed that partial-thickness articular side tears were mainly associated with intrinsic pathology of the rotator cuff, whereas bursal side tears were associated with subacromial impingement and underlying intrinsic degenerative changes of the rotator cuff. In this study, the mean AI of 0.64 was almost identical in patients with partial-thickness articular side tear (group A), which served as a control for full-thickness tears groups.

In this study, a higher AI on oblique coronal MR images was detected more frequently in patients with large-to-massive rotator cuff tears than in patients with partial-thickness articular side rotator cuff tears. There was a significant difference between group A and group D, and between group A and group E. Though the average AI in group E was slightly smaller than group D, it was not statistically significant. Due to the concavity of the glenoid, it could be assumed that the superior migration of the humeral head is associated with a slight lateral displacement of the humeral head. However, there was no significant difference among full-thickness rotator cuff tears groups. Therefore it could be concluded that an AI could not provide useful guidance on predicting the tear size in full-thickness tear patients. However, judging from the fact that higher AI was detected more frequently in patients with large-to-massive rotator cuff tears, we consider a higher AI can be one of the associated factors for progression to large-to-massive rotator cuff tears in rotator cuff disease.

Moreover, a higher AI was detected more frequently in patients with large-sized full-thickness and massive rotator cuff tears than in patients with partial-thickness articular side rotator cuff tears on oblique coronal MR images. Accordingly, a high AI can be a risk factor for advanced rotator cuff tears and can also be a predictor for differentiating large-to-massive rotator cuff tears from partial-thickness articular side tears.

The strength of our study is that we included large numbers of rotator cuff tear patients and used MRI scan

measuring AI. We believe it is difficult to obtain consistent images from an anteroposterior view of plain shoulder X-rays, because the projection angle can vary easily depending on the patient's posture, which gives distorted images.

There are certain limitations to our study. First, previously described morphologic parameters of an acromion, such as its shape [2], anterior slope [3], and the lateral acromion angle [4] were not assessed in this study. Moreover, the influence of an AI on joint reaction forces acts only in the frontal plane theoretically, but not in the sagittal or transverse planes. Although the role of these parameters in the pathogenesis of rotator cuff disease is still a matter of debate, we believe that there are complex interactions between these parameters, including the AI, and that these are closely associated with rotator cuff tears. Additional studies through a three-dimensional imaging or biomechanical research are required to further understand the relationship between the morphology of an acromion and the rotator cuff tears. Second, our control group is comprised of patients with partial-thickness articular side rotator cuff tears confirmed by MRI and arthroscopy. Although it is difficult to obtain MRI or arthroscopic findings from healthy subjects, data from an age-matched healthy population would be better to confirm the relationship between the AI and rotator cuff tears. Third, it is possible that partial-thickness rotator cuff tears may progress to full-thickness tears in longer-term follow-up. Therefore, future long-term follow-up studies are needed to reach a firm conclusion.

Conclusions

This study showed that a higher AI was detected more frequently in patients with large-to-massive rotator cuff tears than in patients with partial-thickness articular side tears on MRI, but the AI has no significant differences among full-thickness tears groups. Although AI could not provide useful guidance on predicting the tear size among full-thickness tears groups, a higher AI can be one of the associated factors for progression to large-to-massive sized rotator cuff tears in rotator cuff disease.

References

1. Neer CS 2nd (1972) Anterior acromioplasty for the chronic impingement syndrome in the shoulder: a preliminary report. *J Bone Joint Surg Am* 54(1):41–50
2. Bigliani LU, Morrison DS, April EW (1986) The morphology of the acromion and its relationship to rotator cuff tears. *Orthop Trans* 10:228
3. Aoki M, Ishii S, Usui M (1986) The slope of the acromion and rotator cuff impingement. *Orthop Trans* 10:228
4. Banas MP, Miller RJ, Totterman S (1995) Relationship between the lateral acromion angle and rotator cuff disease. *J Should Elbow Surg* 4(6):454–461
5. Nyffeler RW, Werner CM, Sukthankar A, Schmid MR, Gerber C (2006) Association of a large lateral extension of the acromion with rotator cuff tears. *J Bone Joint Surg Am* 88(4):800–805. doi:10.2106/JBJS.D.03042
6. Torrens C, Lopez JM, Puente I, Caceres E (2007) The influence of the acromial coverage index in rotator cuff tears. *J Should Elbow Surg* 16(3):347–351. doi:10.1016/j.jse.2006.07.006
7. Zumstein MA, Jost B, Hempel J, Hodler J, Gerber C (2008) The clinical and structural long-term results of open repair of massive tears of the rotator cuff. *J Bone Joint Surg Am* 90(11):2423–2431. doi:10.2106/JBJS.G.00677
8. DeOrto JK, Cofield RH (1984) Results of a second attempt at surgical repair of a failed initial rotator-cuff repair. *J Bone Joint Surg Am* 66(4):563–567
9. Ozaki J, Fujimoto S, Nakagawa Y, Masuhara K, Tamai S (1988) Tears of the rotator cuff of the shoulder associated with pathological changes in the acromion. A study in cadavera. *J Bone Joint Surg Am* 70(8):1224–1230
10. Chansky HA, Iannotti JP (1991) The vascularity of the rotator cuff. *Clin Sports Med* 10(4):807–822
11. Nixon JE, DiStefano V (1975) Ruptures of the rotator cuff. *Orthop Clin North Am* 6(2):423–447
12. Bigliani LU, Ticker JB, Flatow EL, Soslowsky LJ, Mow VC (1991) Relationship of acromial architecture and diseases of the rotator cuff. *Orthopade* 20(5):302–309
13. Toivonen DA, Tuite MJ, Orwin JF (1995) Acromial structure and tears of the rotator cuff. *J Should Elbow Surg* 4(5):376–383
14. Hayes PR, Flatow EL (2002) Attrition sign in impingement syndrome. *Arthroscopy* 18(9):E44
15. Ouellette H, Labis J, Bredella M, Palmer WE, Sheah K, Torriani M (2008) Spectrum of shoulder injuries in the baseball pitcher. *Skeletal Radiol* 37(6):491–498. doi:10.1007/s00256-007-0389-0
16. Neer CS 2nd (1983) Impingement lesions. *Clin Orthop Relat Res* 173:70–77
17. Hirano M, Ide J, Takagi K (2002) Acromial shapes and extension of rotator cuff tears: magnetic resonance imaging evaluation. *J Should Elbow Surg* 11(6):576–578. doi:10.1067/mse.2002.127097
18. Nicholson GP, Goodman DA, Flatow EL, Bigliani LU (1996) The acromion: morphologic condition and age-related changes. A study of 420 scapulas. *J Should Elbow Surg* 5(1):1–11
19. Ogawa K, Yoshida A, Inokuchi W, Naniwa T (2005) Acromial spur: relationship to aging and morphologic changes in the rotator cuff. *J Should Elbow Surg* 14(6):591–598. doi:10.1016/j.jse.2005.03.007
20. Tucker TJ, Snyder SJ (2004) The keeled acromion: an aggressive acromial variant—a series of 20 patients with associated rotator cuff tears. *Arthroscopy* 20(7):744–753. doi:10.1016/j.arthro.2004.06.018
21. Dogan M, Cay N, Tosun O, Karaoglanoglu M, Bozkurt M (2011) Glenoid axis is not related with rotator cuff tears—a magnetic resonance imaging comparative study. *Int Orthop*. doi:10.1007/s00264-011-1356-x
22. Anderson K, Bowen MK (1999) Spur reformation after arthroscopic acromioplasty. *Arthroscopy* 15(7):788–791
23. Panni AS, Milano G, Lucania L, Fabbriani C, Logroscino CA (1996) Histological analysis of the coracoacromial arch: correlation between age-related changes and rotator cuff tears. *Arthroscopy* 12(5):531–540
24. Bonsel S, Pearsall AWT, Heitman RJ, Helms CA, Major NM, Speer KP (2000) The relationship of age, gender, and degenerative changes observed on radiographs of the shoulder in asymptomatic individuals. *J Bone Joint Surg Br* 82(8):1135–1139

25. Kappe T, Cakir B, Lippacher S, Reichel H, Elsharkawi M (2011) Intraarticular lesions in calcifying tendinitis: incidence and association with the acromion index. *Arch Orthop Trauma Surg* 131(3):325–329. doi:[10.1007/s00402-011-1263-z](https://doi.org/10.1007/s00402-011-1263-z)
26. Iannotti JP, Zlatkin MB, Esterhai JL, Kressel HY, Dalinka MK, Spindler KP (1991) Magnetic resonance imaging of the shoulder. Sensitivity, specificity, and predictive value. *J Bone Joint Surg Am* 73(1):17–29
27. Ko JY, Huang CC, Chen WJ, Chen CE, Chen SH, Wang CJ (2006) Pathogenesis of partial tear of the rotator cuff: a clinical and pathologic study. *J Shoulder Elbow Surg* 15(3):271–278. doi:[10.1016/j.jse.2005.10.013](https://doi.org/10.1016/j.jse.2005.10.013)