

Thyroid associated orbitopathy

Rajat Maheshwari^{1,2}, Ezekiel Weis¹

Thyroid associated orbitopathy, also known as Graves' orbitopathy, is typically a self-limiting autoimmune process associated with dysthyroid states. The clinical presentation may vary from very mild disease to severe irreversible sight-threatening complications. Despite ongoing basic science and clinical research, the pathogenesis and highly effective therapeutic strategies remain elusive. The present article reviews the pathophysiology, clinical presentation, and management of this common, yet poorly understood disease, which remains a challenge to the ophthalmologist.

Key words: Orbit, proptosis, thyroid

Access this article online

Website:
www.ijo.in

DOI:
10.4103/0301-4738.94048

Quick Response Code:



Graves' disease is an autoimmune condition in which autoantibodies target the thyroid-stimulating hormone receptor (TSH-R) displayed on thyrocytes, inducing the production of excess thyroid hormone.^[1] In addition to the hyperthyroidism, up to 40% of patients with Graves' disease develop a manifestation localizing to the orbit, called thyroid associated orbitopathy (TAO) or Graves' orbitopathy (GO).^[2] The most significant pathological findings in TAO include glycosaminoglycan (GAG) deposition (accompanied by swelling resulting from the hydrophilic capacity of these macromolecules), fibrosis affecting the extraocular muscles, and adipogenesis in the orbit.^[3-6] To date, there are no effective means of preventing the disease or reliably altering its course. Current therapeutic options include corticosteroids, external beam radiation and steroid-sparing immunosuppressive agents for reducing the inflammation during active disease, and surgery for correcting the residual abnormalities secondary to fibrosis in the inactive state of the disease. These interventions are aimed at the consequences of the disease rather than targeting its cause.^[3,4] Unfortunately, these treatments do not prevent or reverse the pathological changes in the orbital tissues.^[7] The present article reviews our current understanding of the disease and the management protocol.

Epidemiology

TAO is the most common disease affecting the orbit.^[8] It is detectable in approximately 25% of unselected patients with Graves' disease if eyelid signs are excluded, and 40% if eyelid

signs are included.^[9,10] TAO patients are older than patients with Graves' hyperthyroidism without orbitopathy.^[11] The estimated incidence of GO in the general population is 16 females and 3 males per 100,000 person years,^[12] with severe forms accounting for no more than 3–5% of the cases. Tellez *et al.* reported a 6.4 times risk for development for orbitopathy in Europeans compared to Asians. They also found that the prevalence of TAO in patients with hyperthyroidism was significantly higher in Europeans (42%) compared to Asians (7.7%).^[13]

Although TAO is more common in women, the proportion of men increases as severity increases. The female to male ratio was 9.3:1 in patients with mild ophthalmopathy, 3.2:1 in those with moderate ophthalmopathy, and 1.4:1 with severe ophthalmopathy.^[9-12] The risk and severity of ophthalmopathy in patients with Graves' disease may be increased by several other factors including tobacco use, genetics, type of treatment for hyperthyroidism, TSH receptor antibody levels, advanced age, and stress.^[14] Cigarette smoking is the strongest modifiable risk factor for developing TAO. There is strong evidence for a causal association between smoking and development of TAO.^[13,15]

Other related autoimmune diseases including myasthenia gravis, which is 50 times more common in patients with TAO when compared to normal population, signify worse prognosis.^[14] Similarly, patients with TAO and diabetes mellitus seem to have a higher incidence of dysthyroid optic neuropathy (DON).^[16,17]

Pathogenesis

Autoimmunity

The increase in size of the extraocular muscles and orbital fat results from interaction between orbital fibroblast, cytokines, immune cells, autoantibodies, environmental and genetic factors.^[18] The question of which antigen(s) are involved in TAO is still unknown, but because of the unique association of TAO with hyperthyroidism, it is hypothesized that the thyroid and orbital tissue share a common antigen. These antigens could

¹Department of Ophthalmology, Royal Alexandra Hospital, University of Alberta, Edmonton, Alberta, Canada T5H 3V9, ²Orbit, Oculoplasty and Ocular Oncology, Netraseva Eye Associates, Jalna, Maharashtra, India

Correspondence to: Dr. Rajat Maheshwari, Orbit, Oculoplasty and Ocular Oncology, Netraseva Eye Associates, Jalna – 431 203, Maharashtra, India. E-mail: rajat.oculoplasty@gmail.com

Manuscript received: 19.04.10; **Revision accepted:** 28.12.11

be thyroglobulin, the TSH receptor, insulin like growth factor (IGF-1) receptor, or extraocular muscle antigens.

Lehman and colleagues summarized a plausible pathway for fibroblast activation in TAO.^[19] They proposed that binding and activation of orbital fibroblasts by autoantibodies triggers thyroid eye disease. Activated orbital fibroblasts release chemokines that recruit T-lymphocytes into the orbit. These lymphocytes then interact with fibroblasts, potentially activating each other, further promoting cytokine production and secretion of T-cell activating factors. The interaction of fibroblasts with T cells results in the deposition of extracellular matrix molecules, fibroblast proliferation, and adipogenesis [Fig. 1].

Smoking

Smoking increases the incidence and severity of GO. Graves' disease patients who smoke have a 5 times higher risk of developing TAO than those who do not.^[14] Cawood and colleagues have established that orbital fibroblasts when exposed to cigarette extract have a dose-dependent statistically significant increase in GAGs' production and adipogenesis.^[20] There is evidence to suggest that smoking cessation reduces the risk of worsening of the orbitopathy, increasing the chance of having a favorable response to treatment.^[21]

Genetic predisposition

Genetic factors may play a role in the pathogenesis of Graves' disease. Twenty to sixty percent of affected individuals have a positive family history of thyroid disease. A population-based study of Danish monozygotic twins showed a 35% concordance rate.^[22] Patients with Graves' disease also express certain human leukocyte antigens (HLAs) more often than control subjects without the disease. HLA-B8, DR3, and DQA1*0501 haplotypes may increase susceptibility to the disease, and HLA-DR β 1*07 may offer protection.^[23] Akaishi *et al.*^[24] studied the frequency of the class II major histocompatibility complex (MHC) HLA alleles in 81 Brazilian TAO patients and 161 normal controls. TAO patients with major extraocular muscle involvement were found to have a higher frequency of the HLA-DRB1*16 allele, whereas patients with minor extraocular muscle involvement were found to have a higher frequency of the HLA-DRB1*03 allele.

Clinical Manifestations

Approximately 80% of cases of TAO occur in association with hyperthyroidism, yet the onset may not coincide with the onset of the hyperthyroid state. In relation to hyperthyroidism, TAO may present well before the onset of thyroid dysfunction, during thyroid dysfunction, or when the patient is euthyroid following therapy.^[25] Five to ten percent of patients with TAO do not develop hyperthyroidism and are called euthyroid TAO,^[2] and 10% of TAO patients have primary autoimmune hypothyroidism.^[26]

The most frequent sign in TAO is eyelid retraction, which affects 90–98% of patients^[27,28] and frequently varies with attentive gaze^[29] (Kocher's sign). Contour of the retracted upper eyelid often shows lateral flare, an appearance that is almost pathognomonic for TAO.^[30] Lid retraction is multifactorial and is due to increased sympathetic stimulation of Muller's muscle, contraction of the levator muscle, and scarring between the lacrimal gland fascia and levator, which specifically gives rise

to the lateral flare.^[31,32] The excursion of the upper eyelid often lags behind eyeball movement on vertical downward pursuit (lid lag) and remains high. Another common finding in patients with TAO is incomplete eyelid closure (lagophthalmos). Most patients develop exposure symptoms (foreign body sensation, grittiness, photophobia, and lacrimation). These are secondary to the wide palpebral aperture combined with poor blinking, leading to increased tear evaporation.^[33]

The inflammation and secondary GAG deposition previously described, causes tissue swelling resulting in proptosis, visible edema, and erythema. In the muscles, this leads to dysfunction due to failure of relaxation limiting movement, causing diplopia.

Orbital swelling at the apex can cause pressure on the optic nerve leading to DON. DON is only seen in severe disease with crowding of the orbit apex by enlarged extraocular muscles and it affects only 5% of clinical TAO patients.^[14] Less common signs include superior limbic keratoconjunctivitis.

Disease Activity and Severity

During the course of TAO, the disease passes through several phases. From the onset, the first phase involves worsening of symptoms and signs in the active/inflammatory phase. Phases of gradual improvement in the inflammatory signs and symptoms follow until eventually no further changes occur. Permanent abnormalities in both function and appearance may remain in the stable inactive state.

Over the past decade, the concepts of disease severity and activity pertaining to thyroid eye disease have been defined more explicitly, although difficulties in definition and assessment remain. "Active" disease implies the presence of inflammatory features and suggests the potential for response to anti-inflammatory treatments. "Inactive" disease defines the phase when no inflammation is present, yet residual fibrosis and its secondary effects persist. In the inactive phase, only surgical treatment can alter the outcome [Fig. 2a and b].

Hence, activity refers to presence of inflammation while severity of GO describes the degree of functional or cosmetic deficit at any stage.^[31] It is important to determine the phase of GO for formulating an appropriate management plan. This is because immunomodulation therapy can be only effective while there is active inflammation.^[8,31]

Vision, Inflammation, Strabismus, and Appearance Classification for Grave's Orbitopathy

One of the challenges in GO is to classify and grade its various clinical manifestations. Most ophthalmologists are familiar with Dr. Werner's NO SPECS classification that graded various symptoms and signs associated with the disease.^[34] In 1987, Drs Bahn and Gorman emphasized the importance of using objective and reproducible criteria when evaluating therapies.^[35] In 1989, Mourits, Koorneef, Wiersinga, and colleagues in The Netherlands introduced a Clinical Activity Score (CAS) to stage and grade the inflammatory phase of the disease.^[36]

Dolman and Rootman devised a classification system based on the International working group's suggestion based on four

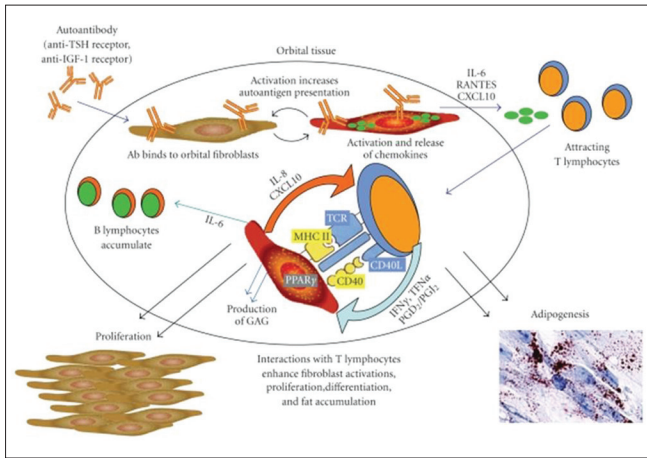


Figure 1: According to Lehmann *et al.*,^[18] TED is triggered by binding and activation of orbital fibroblasts by autoantibodies. Activated orbital fibroblasts release chemokines which recruit T lymphocytes into the orbit. These lymphocytes then interact with fibroblasts, potentially activating each other, further promoting cytokine production and secretion of T cell activating factors by the fibroblasts. The interactions of fibroblasts with T cells result in the deposition of extracellular matrix molecules, fibroblast proliferation, and fat accumulation

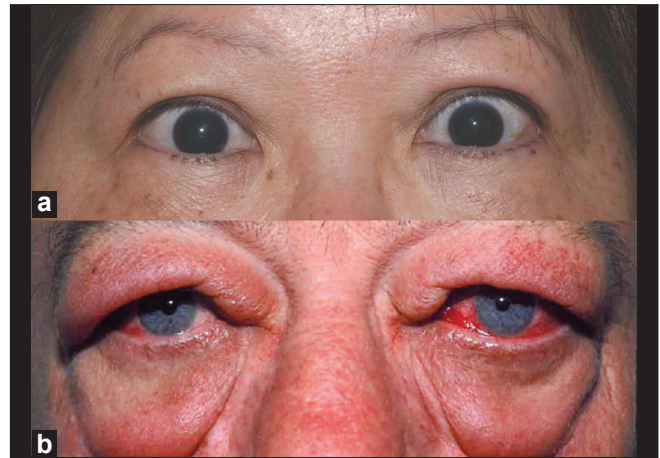

Figure 2: (a) Image of a patient with inactive disease showing no inflammation but severe eye lid retraction; (b) image of a patient showing active disease as manifested by eyelid hyperemia, eyelid edema, conjunctival injection, and caruncular edema

disease endpoints that can be used in the office setting to record changes and to guide and assess therapy.^[37] These clinical points include Vision, Inflammation, Strabismus, and Appearance (VISA)/exposure; these can be remembered by the acronym VISA. Each section records subjective and measurable objective inputs that aid in planning ancillary testing and treatment. The VISA classification helps direct appropriate management for patients with GO in a logical sequence, depending on which aspects of the disease are affecting them at any point in the course of their disease [Table 1].

Vision

The primary goal of this section is to rule out optic neuropathy. Subjectively, this is described early on as episodes of graying out with and without color desaturation. On examination, abnormalities in visual acuity, color vision assessment, relative afferent papillary defect, or peripheral visual field assessment may be detected.

Inflammation

The CAS, described and validated by Mourits and the Amsterdam Orbitopathy group, was modified and used to grade the severity of activity. The CAS includes pain, redness, swelling, and impaired visual function, which may signal acute inflammation. The CAS consists of two conjunctival signs, two eyelid signs, and two orbital signs. Each of these signs is assigned points depending on the severity at presentation [Table 1]. The maximum score is thus 8. The worst scores from any of the four eyelids are recorded. A score of 3 or less is considered as inactive and 4 or more is active eye disease and thus is supposedly more likely to respond to immunosuppression. The disadvantage of CAS is it is still very subjective in nature with a large inter-observer variation. The advantage of CAS is it is inexpensive and can be done instantly in a clinic.

Strabismus

The symptoms for strabismus include a progression from no

diplopia, diplopia in horizontal or vertical gaze, intermittent diplopia in primary gaze, and constant diplopia in primary gaze. Ocular ductions can be graded from 0° to >45° in four directions, using the Hirschberg principle. Strabismus can be measured objectively by prism cover testing in different gaze directions.

Appearance/exposure

Objective measures of appearance change include eyelid retraction, proptosis, and documentation of redundant skin and fat prolapse. Measures of exposure include corneal staining or ulceration. Photographs can document the appearance changes.

Orbital Imaging

Computed tomography (CT) is the most commonly utilized imaging technique for evaluating GO. CT is more sensitive than magnetic resonance imaging (MRI) in identifying enlarged extraocular muscles.^[38] Findings on CT scanning may include muscle belly enlargement that typically spares the tendinous insertions, an apparent increase in orbital fat volume, and crowding of the optic nerve at the orbital apex.

Imaging studies may be particularly helpful when radiation therapy or decompressive surgery is planned, as they allow the degree of extraocular muscle and orbital fat involvement to be defined and sinus and skull base anatomy to be delineated clearly before intervention.

Treatment

General considerations

From the endocrine perspective, the goal of treatment for patients with Graves' disease is the achievement of a euthyroid state. Patients should be counseled regarding the risks of smoking and the benefits of smoking cessation.

The decision on whether ophthalmopathy must be treated and requires what type of treatment relies on activity and severity of the disease [Table 2]. The sequence of the sections (V-I-S-A) described earlier reflects the order in which the problems should be managed.

Table 1: Vision, Inflammation, Strabismus, and Appearance Classification

VISA CLASSIFICATION:

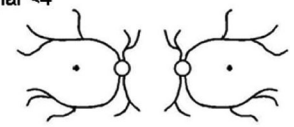
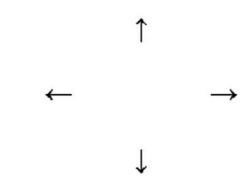

Date: _____ Visit #: _____

ORBITOPATHY THYROID
 Time since onset: _____ Time since onset: _____
 Progress: _____ Progress: _____
 Tempo: _____ Status: _____
 Symptoms: _____ Symptoms: _____

Therapy: _____ Anti-thyroid meds: _____
 Radioactive iodine: _____

Patient Label: _____

GENERAL
 Smoking: _____
 Family Hx: _____
 Medical Hx: _____
 Allergies: _____
 Meds: _____

SUBJECTIVE	OBJECTIVE	OD	OS	
VISION				Refractions
Vision: n / abn	Central vision: sc / cc / ph with manifest	20/____ 20/____	20/____ 20/____	Wearing _____ + _____ X _____ _____ + _____ X _____ Manifest _____ + _____ X _____ _____ + _____ X _____
Color vis: n / abn	Color vision errors (AO) Pupils (afferent defect)	y / n	y / n	Normal <4
Fundus	Optic nerve: Edema Pallor	y / n y / n	y / n y / n	
Progress: s / b / w				
INFLAMMATORY				Inflammatory Index (worst eye/eyelid)
Retrobulbar ache At rest (0-1) With gaze (0-1) Lid swelling AM: y / n	Chemosis (0-2) Conjunctival injection (0-1) Lid injection (0-1) Lid edema Upper (0-2) Lower (0-2)			Chemosis (0-2): Conjunctival injection (0-1): Lid injection (0-1): Lid edema (0-2): Retrobulbar ache (0-2): Total (8):
Progress: s / b / w				
STRABISMUS/ MOTILITY				Prism Measure:
Diplopia: None (0) With gaze (1) Intermittent (2) Constant (3) Head turn: y / n	Ductions (degrees): Restriction > 45° 30-45° 15-30° < 15°	+ 0 1 2 3	+ 0 1 2 3	
Progress: s / b / w				
APPEARANCE/ EXPOSURE				Fat prolapse and eyelid position:
Lid retraction y / n	Lid retraction (upper): MRD-4 (lower scleral show): Levator function Lagophthalmos	mm mm mm mm	mm mm mm mm	
Proptosis y / n	Exophthalmometry (Hertel)	y / n	y / n	Base:
Tearing y / n	Corneal erosions	y / n	y / n	
FB Sensation y / n	Corneal ulcers	y / n	y / n	
Progress: s / b / w	IOP -straight -up	mmHg mmHg	mmHg mmHg	

DISEASE GRADING	Grade	Progress / Response
V (optic neuropathy)	y / n	s / b / w
I (inflammation) 0-8	/ 8	s / b / w
S (strabismus) 0-3	/ 3	s / b / w
(restriction) 0-3	/ 3	s / b / w
A (appearance/exposure)	mild / mod / severe	s / b / w

MANAGEMENT

FOLLOW-UP INTERVAL:

Vision dysfunction from optic neuropathy is the first priority and, depending on whether inflammation is present, might be treated with corticosteroids, radiotherapy, and/or orbital decompression. Inflammation is the next priority and may be treated with conservative measures, corticosteroids, steroid-sparing immunosuppressives and/or radiotherapy. Strabismus and appearance changes are usually managed medically and expectantly (with patching or Fresnel prisms) until the signs of inflammation and disease progression have subsided. Once this has occurred, strabismus can be managed with ground-in prisms or surgery, whereas proptosis, eyelid retraction, dermatochalasis, and fat prolapse can be managed surgically [Fig. 3].

Most patients with Graves' disease have mild ocular manifestation. Simple local supportive measures are usually sufficient to obtain symptomatic relief [Table 3].

Glucocorticoids

Glucocorticoids have been employed with the rationale for their anti-inflammatory and immunosuppressive actions.^[39] In a review by Rajendram *et al.*, glucocorticoids' response rate has been found to range from 63 to 77%.^[40] Higher effectiveness and fewer side effects of intravenous glucocorticoids compared to oral have resulted in IV steroids as the mainstay of treatment.^[41,42] The cumulative dose of IV steroids should be no more than 6–8 g.^[14] Some centers recommended routine liver assessment during treatment with IV steroids to rule out liver toxicity during and after treatment. Recurrences are not infrequent, thus repeated dosing is often required.

Radiation therapy

Evidence regarding the efficacy of radiation therapy in the management of GO is limited, owing to methodologic weaknesses of available studies. The rationale for the use of radiotherapy for TAO resides both in its nonspecific anti-inflammatory effect and in the high radiosensitivity of lymphocytes infiltrating the orbit.^[43] Orbital radiotherapy is effective in patients who have active eye disease with recent progression. Patients with inactive GO do not respond to irradiation.^[44] The most common delivered dose is 20 Gy per eye; this cumulative dose is fractionated over a 2-week period. Orbital radiotherapy may be associated with transient exacerbations of inflammation, but this can typically be avoided with co-coverage with glucocorticoids. With modern techniques, there seems to be no increased risk of cataract, or secondary malignancies, and only a remote risk of retinopathy.^[45] In patients with diabetes mellitus, irradiation should be considered as a relative contraindication. Even though the efficacy of radiation therapy has been recently questioned, it remains widely used.^[46]

Steroid-sparing immunosuppressive drugs

The autoimmune nature of TAO prompted the attempt to use steroid-sparing immunosuppressive drugs for this disease. Cyclosporine has been thoroughly evaluated in the management of GO. It affects both cell-mediated and humoral immune reactions. But the effect of cyclosporine given as monotherapy was inferior to prednisone. A few controlled studies have proven that the use of cyclosporine in combination with prednisone is more effective than monotherapy with prednisone alone.^[47,48] Regular monitoring for side effects

Table 2: Suggested treatment for Graves Ophthalmopathy as function of disease severity and activity

Ocular involvement	Activity	Treatment
Nonsevere	Active	Supportive measures
Nonsevere	Inactive	Supportive measures
Severe	Active	Glucocorticoids Orbital radiotherapy Orbital decompression*
Severe	Inactive	Orbital decompression Strabismus surgery Eyelid retraction surgery

*Only in the setting of compressive optic neuropathy that has not resolved with maximal medical management, (Bartalena L, Pinchera A, Marcocci C. Management of Graves' ophthalmopathy: reality and perspectives. *Endocr Rev* 2000;21(2):168-99)

Management synopsis for patient with Thyroid Associated Orbitopathy

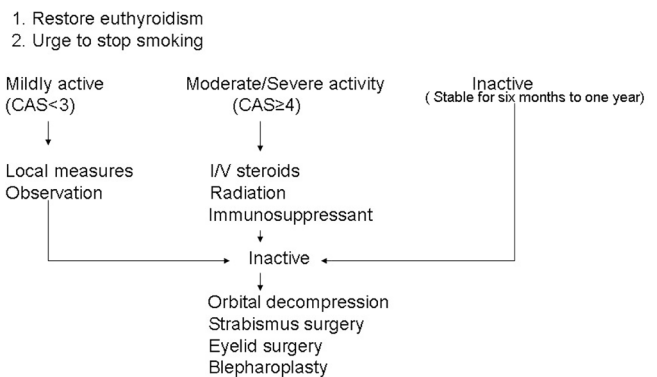


Figure 3: Management synopsis for patients with thyroid orbitopathy

Table 3: Local supportive measures for Thyroid associated Orbitopathy

Head elevation in sleep - Reduce periorbital edema
Sunglasses – Reduce photophobia
Artificial tears - to keep the ocular surface moist

during the course of cyclosporine is required while a patient is on treatment.

Methotrexate is given in doses of 5–25 mg once per week. It does not have randomized controlled trial data, but a case series^[49] and the authors' experience suggest this to be a promising drug.

Surgical Intervention

The indications for surgical intervention in thyroid-related orbitopathy include optic neuropathy, diplopia, corneal exposure, and cosmesis. Broadly speaking, surgical procedures may be directed toward orbital decompression, strabismus

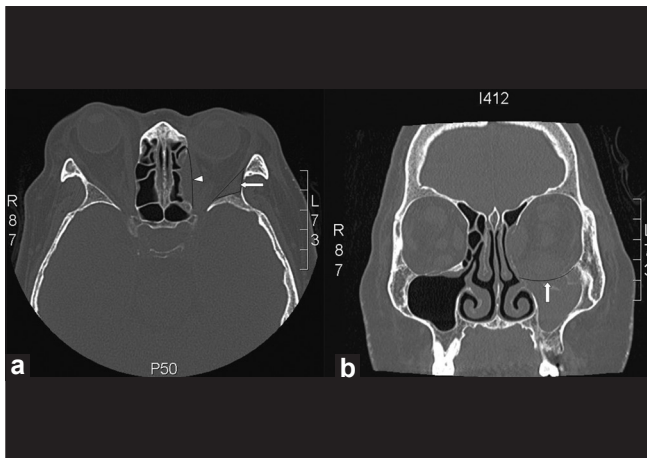


Figure 4: (a) CT scan showing the part of the posterolateral wall removed in lateral wall decompression (white arrow) and the medial wall osteotomy (white arrow head); (b) CT scan showing the orbital floor osteotomy (white arrow) for inferior wall decompression

repair, and the correction of eyelid abnormality. Traditionally, orbital decompression, if required, is performed initially, followed by strabismus surgery and then eyelid repair. This is because the nature and degree of strabismus may change after orbital surgery, and lid position may be altered following strabismus repair.

The timing of surgery is of significance. Decompression may be necessary on an urgent basis for compressive optic neuropathy or severe proptosis with corneal ulceration refractory to other treatment measures. Yet, most decompression surgery is performed when a patient has been stable in the inactive state for at least 6–8 months.^[14]

Orbital decompression

Any surgical procedure that enlarges the bony orbit and/or removes the orbital fat is defined as orbital decompression. A customized decompression depending on the specifics of each patient provides the highest quality of care. At present, the medial wall, the orbital floor, and/or the lateral wall continue to be addressed during bony decompression surgery [Fig. 4a and b].^[14] Preserving the medial orbital strut between the ethmoid cavity and the orbital floor may minimize the risk of globe dystopia and diplopia.^[50] The combination of bony decompression associated with fat removal has been gaining popularity in view of the low risks associated with fat decompression.^[51,52]

Eye muscle surgery

Ocular motility disorders in GO are typically due to a restrictive myopathy, and thus are typically non-concomitant. Usually, in TAO, extraocular muscle involvement is characterized by accumulation of inflammatory cells and fluid. Later, the muscle is replaced by fibrous tissue, which makes the muscle stiff and inextensible. Due to the often incomitant nature of strabismus, surgery in TAO is often aimed at resolution of diplopia in primary position and downgaze. Surgery should be performed on a patient who does not have active thyroid disease for at least 6 months, and typically involves release of the restricted muscle by recession rather than resection. The use of adjustable sutures is strongly recommended due to the variability in fibrosis, resulting in unpredictable results.

Eyelid surgery

The most common indication for lid surgery is upper lid retraction. Treatment consists of a graded Muller's and levator aponeurosis weakening. Criterion for successful correction is covering of 1–2 mm of the superior cornea. Lower lid lengthening is indicated in lower lid retraction. Recession of lower lid retractors alone is insufficient to correct more than 1 mm of lid retraction and an interposition graft or spacer is needed if there is significant lower lid retraction.

Blepharoplasty

Blepharoplasty is the final surgical procedure in the rehabilitation of the TAO patient. Skin excision in the lower lid should be done carefully to avoid ectropion and/or lower lid retraction.

Conclusion

TAO is a self-limiting autoimmune disease associated mainly with hyperthyroidism, but also with hypothyroid and euthyroid states. There are two distinct stages of the disease, an active inflammatory stage followed by inactive quiescent stage. There are no effective means of preventing the disease or reliably altering its course. Current therapeutic options include local supportive measures, corticosteroids, external beam radiation and steroid-sparing immunosuppressive agents for reducing the inflammation during active disease, and surgery for correcting the residual abnormalities secondary to fibrosis in the inactive state of the disease.

References

1. Prabhakar BS, Bahn RS, Smith TJ. Current perspective on the pathogenesis of Graves' disease and ophthalmopathy. *Endocr Rev* 2003;24:802-35.
2. Burch HB, Wartofsky L. Graves' ophthalmopathy: Current concepts regarding pathogenesis and management. *Endocr Rev* 1993;14:747-93.
3. Bahn RS, Heufelder AE. Pathogenesis of Graves' ophthalmopathy. *N Engl J Med* 1993;329:1468-75.
4. Feldon SE, Weiner JM. Clinical significance of extraocular muscle volumes in Graves' ophthalmopathy: A quantitative computed tomography study. *Arch Ophthalmol* 1982;100:1266-9.
5. Nunery WR, Nunery CW, Martin RT, Truong TV, Osborn DR. The risk of diplopia following orbital floor and medial wall decompression in subtypes of ophthalmic Graves' disease. *Ophthalm Plast Reconstr Surg* 1997;13:153-60.
6. Smith TJ, Hoa N. Immunoglobulins from patients with Graves' disease induce hyaluronan synthesis in their orbital fibroblasts through the self-antigen, insulin-like growth factor-I receptor. *J Clin Endocrinol Metab* 2004;89:5076-80.
7. Wiersinga WM, Prummel MF. Pathogenesis of Graves' ophthalmopathy--Current understanding. *J Clin Endocrinol Metab* 2001;86:501-3.
8. Rootman J. *Diseases of the Orbit. A Multidisciplinary Approach*. Hagerstown: Lippincott Williams and Wilkins; 2003.
9. Bartalena L, Pinchera A, Marcocci C. Management of Graves' ophthalmopathy: Reality and perspectives. *Endocr Rev* 2000;21:168-99.
10. Wiersinga WM, Bartalena L. Epidemiology and prevention of Graves' ophthalmopathy. *Thyroid* 2002;12:855-60.
11. Perros P, Kendall-Taylor P. Natural history of thyroid eye disease. *Thyroid* 1998;8:423-5.
12. Bartley GB, Fatourehchi V, Kadrmas EF, Jacobsen SJ, Ilstrup DM,

- Garrity JA, *et al.* The incidence of Graves' ophthalmopathy in Olmsted County, Minnesota. *Am J Ophthalmol* 1995;120:511-7.
13. Tellez M, Cooper J, Edmonds C. Graves' ophthalmopathy in relation to cigarette smoking and ethnic origin. *Clin Endocrinol (Oxf)* 1992;36:291-4.
 14. Wiersinga WM, Kahaly GJ. Graves orbitopathy: A multidisciplinary approach. Basel: Karger; 2007.
 15. Hagg E, Asplund K. Is endocrine ophthalmopathy related to smoking? *Br Med J* 1987;295:634-5.
 16. Kalmann R, Mourits MP. Diabetes mellitus: A risk factor in patients with Graves' orbitopathy. *Br J Ophthalmol* 1999;83:463-5.
 17. Neigel JM, Rootman J, Belkin RI, Nugent RA, Drance SM, Beattie CW, *et al.* Dysthyroid optic neuropathy. The crowded orbital apex syndrome. *Ophthalmology* 1988;95:1515-21.
 18. Garrity JA, Bahn RS. Pathogenesis of graves ophthalmopathy: Implications for prediction, prevention, and treatment. *Am J Ophthalmol* 2006;142:147-53.
 19. Lehmann GM, Garcia-Bates TM, Smith TJ, Feldon SE, Phipps RP. Regulation of lymphocyte function by PPARgamma: Relevance to thyroid eye disease-related inflammation. *PPAR Res* 2008;2008:895901.
 20. Cawood TJ, Moriarty P, O'Farrelly C, O'Shea D. Smoking and thyroid-associated ophthalmopathy: A novel explanation of the biological link. *J Clin Endocrinol Metab* 2007;92:59-64.
 21. Krassas GE, Wiersinga W. Smoking and autoimmune thyroid disease: The plot thickens. *Eur J Endocrinol* 2006;154:777-80.
 22. Brix TH, Kyvik KO, Christensen K, Hegedus L. Evidence for a major role of heredity in Graves' disease: A population-based study of two Danish twin cohorts. *J Clin Endocrinol Metab* 2001;86:930-4.
 23. Lee HB, Rodgers IR, Woog JJ. Evaluation and management of Graves' orbitopathy. *Otolaryngol Clin North Am* 2006;39:923-42, 6.
 24. Akaiishi PM, Cruz AA, Silva FL, Rodrigues Mde L, Maciel LM, Donadi EA. The role of major histocompatibility complex alleles in the susceptibility of Brazilian patients to develop the myogenic type of Graves' orbitopathy. *Thyroid* 2008;18:443-7.
 25. Wiersinga WM, Smit T, van der Gaag R, Koornneef L. Temporal relationship between onset of Graves' ophthalmopathy and onset of thyroidal Graves' disease. *J Endocrinol Invest* 1988;11:615-9.
 26. Gleeson H, Kelly W, Toft A, Dickinson J, Kendall-Taylor P, Fleck B, *et al.* Severe thyroid eye disease associated with primary hypothyroidism and thyroid-associated dermatopathy. *Thyroid* 1999;9:1115-8.
 27. Bartley GB, Fatourechi V, Kadmas EF, Jacobsen SJ, Ilstrup DM, Garrity JA, *et al.* Clinical features of Graves' ophthalmopathy in an incidence cohort. *Am J Ophthalmol* 1996;121:284-90.
 28. Saks ND, Burnstine MA, Putterman AM. Glabellar rhytids in thyroid-associated orbitopathy. *Ophthal Plast Reconstr Surg* 2001;17:91-5.
 29. Velasco e Cruz AA, Vagner de Oliveira M. The effect of Mullerectomy on Kocher sign. *Ophthal Plast Reconstr Surg* 2001;17:309-15; discussion 15-6.
 30. Koornneef L. Eyelid and orbital fascial attachments and their clinical significance. *Eye (Lond)* 1988;2:130-4.
 31. Dickinson AJ, Perros P. Controversies in the clinical evaluation of active thyroid-associated orbitopathy: Use of a detailed protocol with comparative photographs for objective assessment. *Clin Endocrinol (Oxf)* 2001;55:283-303.
 32. Frueh BR, Musch DC, Garber FW. Lid retraction and levator aponeurosis defects in Graves' eye disease. *Ophthalmic Surg* 1986;17:216-20.
 33. Gilbard JP, Farris RL. Ocular surface drying and tear film osmolarity in thyroid eye disease. *Acta Ophthalmol (Copenh)* 1983;61:108-16.
 34. Werner SC. Classification of the eye changes of Graves' disease. *Am J Ophthalmol* 1969;68:646-8.
 35. Bahn RS, Gorman CA. Choice of therapy and criteria for assessing treatment outcome in thyroid-associated ophthalmopathy. *Endocrinol Metab Clin North Am* 1987;16:391-407.
 36. Mourits MP, Koornneef L, Wiersinga WM, Prummel MF, Berghout A, van der Gaag R. Clinical criteria for the assessment of disease activity in Graves' ophthalmopathy: A novel approach. *Br J Ophthalmol* 1989;73:639-44.
 37. Dolman PJ, Rootman J. VISA Classification for Graves orbitopathy. *Ophthal Plast Reconstr Surg* 2006;22:319-24.
 38. Polito E, Leccisotti A. MRI in Graves orbitopathy: Recognition of enlarged muscles and prediction of steroid response. *Ophthalmologica* 1995;209:182-6.
 39. Bartalena L, Marocci C, Bogazzi F, Bruno-Bossio G, Pinchera A. Glucocorticoid therapy of Graves' ophthalmopathy. *Exp Clin Endocrinol* 1991;97:320-7.
 40. Rajendram R, Lee RW, Potts MJ, Rose GE, Jain R, Olver JM, *et al.* Protocol for the combined immunosuppression and radiotherapy in thyroid eye disease (CIRTED) trial: A multi-centre, double-masked, factorial randomised controlled trial. *Trials* 2008;9:6.
 41. Kahaly GJ, Pitz S, Hommel G, Dittmar M. Randomized, single blind trial of intravenous versus oral steroid monotherapy in Graves' orbitopathy. *J Clin Endocrinol Metab* 2005;90:5234-40.
 42. Macchia PE, Bagattini M, Lupoli G, Vitale M, Vitale G, Fenzi G. High-dose intravenous corticosteroid therapy for Graves' ophthalmopathy. *J Endocrinol Invest* 2001;24:152-8.
 43. Kahaly GJ, Roesler HP, Kutzner J, Kutzner J, Pitz S, Müller-Forell W, *et al.* Radiotherapy for thyroid-associated orbitopathy. *Exp Clin Endocrinol Diabetes* 1999;107 Suppl 5:S201-7.
 44. Bartalena L, Marocci C, Pinchera A. Orbital radiotherapy for Graves' ophthalmopathy. *J Clin Endocrinol Metab* 2004;89:13-4.
 45. Marocci C, Bartalena L, Rocchi R, Marino M, Menconi F, Morabito E, *et al.* Long term safety of orbital radiotherapy for Grave's ophthalmopathy. *J Clin Endocrinol Metab* 2003;88:3561-6
 46. Bartley GB, Gorman CA. Perspective – Part 1: Then Mayo orbital radiotherapy for Graves' ophthalmopathy (ORGO) study: Lessons learnt. *Ophthal Plast Reconstr Surg* 2002;18:170-2.
 47. Kahaly G, Schrezenmeir J, Krause U, Schweikert B, Meuer S, Muller W, *et al.* Cyclosporine and prednisone v. prednisone in treatment of Graves' ophthalmopathy: A controlled, randomized and prospective study. *Eur J Clin Invest* 1986;16:415-22.
 48. Prummel MF, Mourits MP, Berghout A, Krenning EP, van der Gaag R, Koornneef L, *et al.* Prednisone and cyclosporine in the treatment of severe Graves' ophthalmopathy. *N Engl J Med* 1989;321:1353-9.
 49. Smith JR, Rosenbaum JT. A role for methotrexate in the management of non-infectious orbital inflammatory disease. *Br J Ophthalmol* 2001; 85:1220-4.
 50. Goldberg RA, Shorr N, Cohen MS. The medical orbital strut in the prevention of postdecompression dystopia in dysthyroid ophthalmopathy. *Ophthal Plast Reconstr Surg* 1992;8:32-4.
 51. Goldberg RA. The evolving paradigm of orbital decompression surgery. *Arch Ophthalmol* 1998;116:95-6.
 52. Unal M, Leri F, Konuk O, Hasanreisoglu B. Balanced orbital decompression combined with fat removal in Graves ophthalmopathy: Do we really need to remove the third wall? *Ophthal Plast Reconstr Surg* 2003;19:112-8.

Cite this article as: Maheshwari R, Weis E. Thyroid associated orbitopathy. *Indian J Ophthalmol* 2012;60:87-93.

Source of Support: Nil. **Conflict of Interest:** None declared.