

Case Report

Primary small cell carcinoma of the maxillary sinus: a case report with immunohistochemical and molecular genetic study involving *KIT* and *PDGFRA*

Tadashi Terada

Departments of Pathology, Shizuoka City Shimizu Hospital, Shizuoka, Japan

Received October 24, 2011; accepted February 15, 2012; Epub March 25, 2012; Published March 30, 2012

Abstract: Primary small cell carcinoma of the nose and paranasal sinuses is very rare; only a few reports are present in the English literature. The author herein reports a very rare case of primary small cell carcinoma of the maxillary sinus with an emphasis on immunohistochemistry and on *KIT* and *PDGFRA*. A 64-year-old man was admitted to our hospital because of left nasal obstruction. Endoscopy revealed three nasal polyps, and imaging modalities revealed an infiltrative tumor (45 x 45 mm) in the left maxillary sinus with invasion into nasal cavity. Multiple biopsies are taken from the nasal lesions. Histologically, the tumor consists of proliferation of malignant small epithelioid cells with hyperchromatic nuclei, fine chromatin, scant cytoplasm, molded nuclei, and absent nucleoli. Immunohistochemically, the malignant cells were positive for cytokeratin (CK) 18, synaptophysin, CD56, p53, Ki-67 (labeling=95%), bcl-2, *KIT*, and *PDGFRA*. However, they were negative for pancytokeratins, high molecular weight CK, CK5/6, CK7, CK 14, CK 19, CK20, vimentin, neuron-specific enolase, chromogranin, CD15, CD45, S100 protein, CEA, CA19-9, glial fibrillary acidic protein, neurofilaments, neuroblastoma, CD99, surfactant apoprotein A, melanosome, and TTF-1. The pathologic diagnosis was small cell carcinoma. A molecular genetic analysis using PCR-direct sequencing was performed using paraffin sections, and it showed no mutations of *KIT* (exons 9, 11, 13, and 17) and *PDGFRA* (exons 12 and 18) genes. Imaging modalities including CT, MRI and PET did not reveal any tumors, including the lung, other than the maxillary sinus tumor. The present case is the first of small cell carcinoma of the maxillary sinus with a comprehensive immunohistochemical examination and a gene analysis of *KIT* and *PDGFRA*.

Keywords: Small cell carcinoma, maxillary sinus, immunohistochemistry, *KIT*, *PDGFRA*

Introduction

KIT and *platelet-derived growth factor- α* (*PDGFRA*) genes are mapped to 4q12, and encode receptor tyrosine kinase oncoproteins called *KIT* (CD117) and *PDGFRA*, respectively [1, 2]. Both molecules are transmembranous oncoproteins involved in the tumorigenesis of some cancers, particularly in gastrointestinal stromal tumor [1, 2]. Primary small cell carcinoma of the nasal cavity and paranasal sinuses is very rare; only a few reports are recorded in the literature [3-5].

Recently, it has been identified that small cell lung carcinoma (SCLC) expresses *KIT* [6-13]. Small cell carcinoma can occur in any organ. Extrapulmonary small cell carcinoma also may express *KIT* and *PDGFRA* [14-16]. However,

protein expressions of *KIT* and *PDGFRA* have not been investigated in small cell carcinoma of the nasal cavity and paranasal sinuses. In addition, mutations of *KIT* and *PDGFRA* have not been investigated in small cell carcinoma of nasal cavity and paranasal sinuses. The author reports herein a case of small cell carcinoma of the left maxillary sinuses with an emphasis on immunohistochemistry and *KIT* and *PDGFRA*.

Case report

Clinical summary

A 64-year-old man was admitted to our hospital because of left nasal obstruction. Nasal endoscopy revealed three polypoid tumors in the left nasal cavity. Imaging modalities revealed a tumor (45 x 45 mm) in the left maxillary sinus

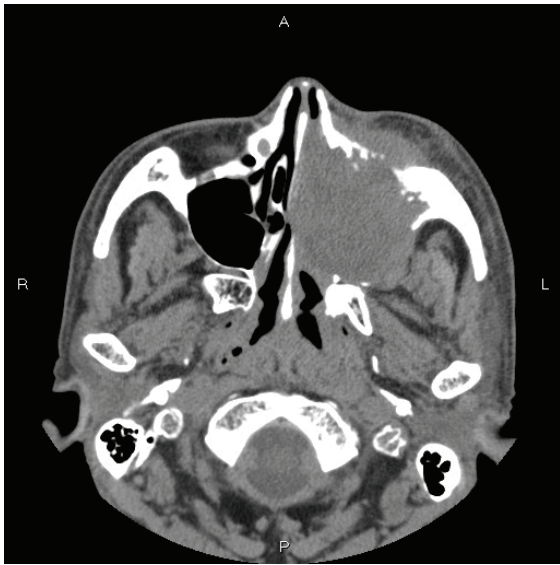


Figure 1. CT findings. The left maxillary sinus shows infiltrative tumor. Nasal cavity is also involved.

(**Figure 1**). The tumor was seen to invade the surrounding tissue including the left nasal cavity (**Figure 1**). Multiple biopsies were performed from the nasal tumor. After the pathological diagnosis, imaging modalities including X-P, CT, MRI, and PET were performed. They did not reveal any tumors other than the maxillary sinus tumor. The lungs were free from tumors.

Materials and methods

The biopsy samples were fixed in 10% formalin and were embedded in paraffin wax. Several 3- μ m sections were cut, and one of them were stained with hematoxylin and eosin. The remaining sections were immunohistochemically examined using Dako's Envision method, as previously reported [17, 18], for pancytokeratins (AE1/3 and polyclonal wide spectrum, Dako

Corp, Glostrup, Denmark, and KL-1, Immunotech, Marseille, France), high molecular weight cytokeratin (CK) (34 β E12, Dako), CK 5/6 (D5/16 B4, Dako), CK 7 (N1626, Dako), CK 14 (LL002, Novocastra, Newcastle upon Tyne, UK), CK 18 (DC10, Dako), CK 19 (RCK 108, Progen, Heidelberg, Germany), CK 20 (K20.8, Dako), vimentin (Vim 3B4, Dako), neuron-specific enolase (BBS/NC/H14, Dako), chromogranin (DAK-A3, Dako), synaptophysin (polyclonal, Dako), CD56 (UJ13A, Dako), p53 (DO-7, Dako), CD15 (C3D, Dako), CD45 (PD7/16+2B11, Dako), S100 (polyclonal, Dako), CEA (polyclonal, Kyowa, Tokyo, Japan), CA19-9 (TFB Lab., Tokyo, Japan), glial fibrillary acidic protein (GFAP) (polyclonal, Dako), neurofilaments (2F11, Dako), neuroblastoma (NB84a, Dako), CD99 (12E7, Dako), Ki-67 (MIB-I, Dako), melanosome (HMB-45, Dako), surfactant apoprotein A (PE10, Dako), bcl-2 (124, Dako), thyroid-transcriptional factor-1 (TTF-1) (8G7G3/1, Dako), KIT (polyclonal, Dako), and PDGFRA (polyclonal, Santa Cruz, CA, USA).

A molecular genetic analysis for *KIT* (exons 9, 11, 13, and 17) and *PDGFRA* (exons 12 and 18) genes was performed, using paraffin sections, by employing PCR-direct sequencing method, as previously described [19-27]. In brief, genomic DNA was extracted from paraffin blocks with proteinase K digestion and phenol/chloroform extraction, and subjected to PCR for 40 cycles (94°C for one minute, 52°C for one minute, 72°C for one minute), using a thermal cycler (GeneAmp PCR system 9700, Applied Biosystems, ABI, CA). The primers are shown in **Table 1**. The annealing temperature was 53°C. PCR products were extracted and subjected to a computed automatic DNA sequencer (ABI PRISM 3100 Genetic Analyzer, Applied Biosystems, ABI, CA). Two cases of gastric GISTs were used as positive controls, and two uterine leiomyomas as negative controls.

Table 1. Primer sequence

	Forward	Reverse
<i>KIT</i> exon 9	5'-TCC TAG AGT AAG CCA GGG CTT-3'	5'-TGG TAG ACA GAG CCT AAA CAT CC-3'
<i>KIT</i> exon11	5'-GAT CTA TTT TTC CCT TTC TC-3'	5'-AGC CCC TGT TTC ATA CTG AC-3'
<i>KIT</i> exon 13	5'-GCT TGA CAT CAG TTT GCC AG -3'	5'-AAA GGC AGC TTG GAC ACG GCT TTA-3'
<i>KIT</i> exon 17	5'-CTC CTC CAA CCT AAT AGT GT-3'	5'-GTC AAG CAG AGA ATG GGT AC-3'
<i>PDGFRA</i> exon12	5'-TTG GAT ATT CAC CAG TTA CCT GTC-3'	5'-CAA GGG AAA AGC TCT TGG-3'
<i>PDGFRA</i> exon 18	5'-ACC ATG GAT CAG CCA GTC TT-3'	5'-TGA AGG AGG ATG AGC CTG ACC-3'

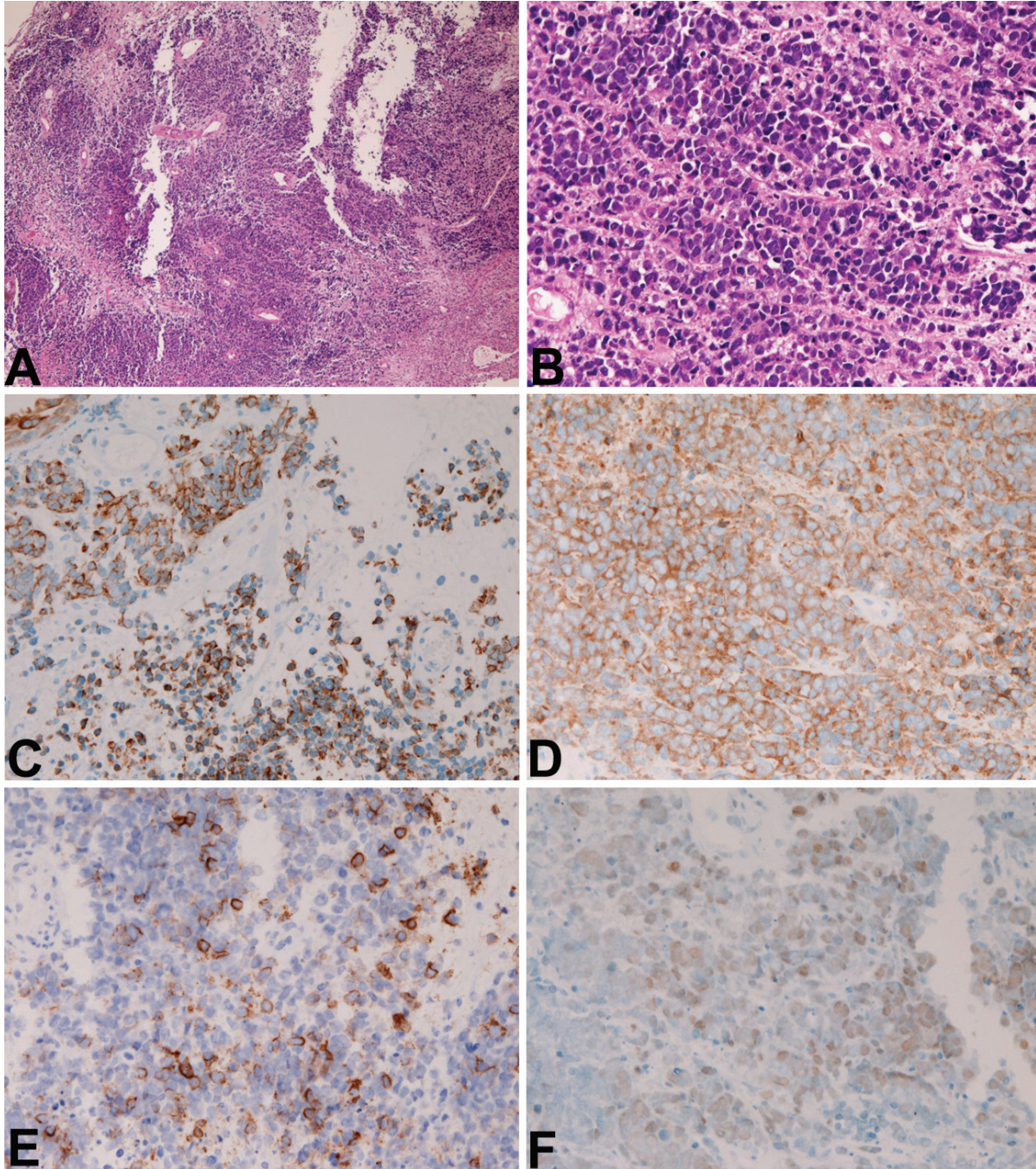
Maxillary small cell carcinoma

Results

No tumor formations were recognized by imaging modalities including X-P, CT, MRI, and PET other than the maxillary tumor. The lungs were free from tumors. Therefore, the maxillary sinus tumor is primary in the present case.

The biopsy specimens were composed of aggre-

gates of small carcinomatous cells with hyperchromatic nuclei, fine granular chromatin, molded nuclei, absent or inconspicuous nucleoli, and scant cytoplasm (**Figures 2A and 2B**). Many mitotic figures were recognized. Necrotic areas are present. No differentiation was recognized. No fibrillar elements suggestive of neuroblastoma were recognized. The histological diagnosis was small cell carcinoma, but olfactory



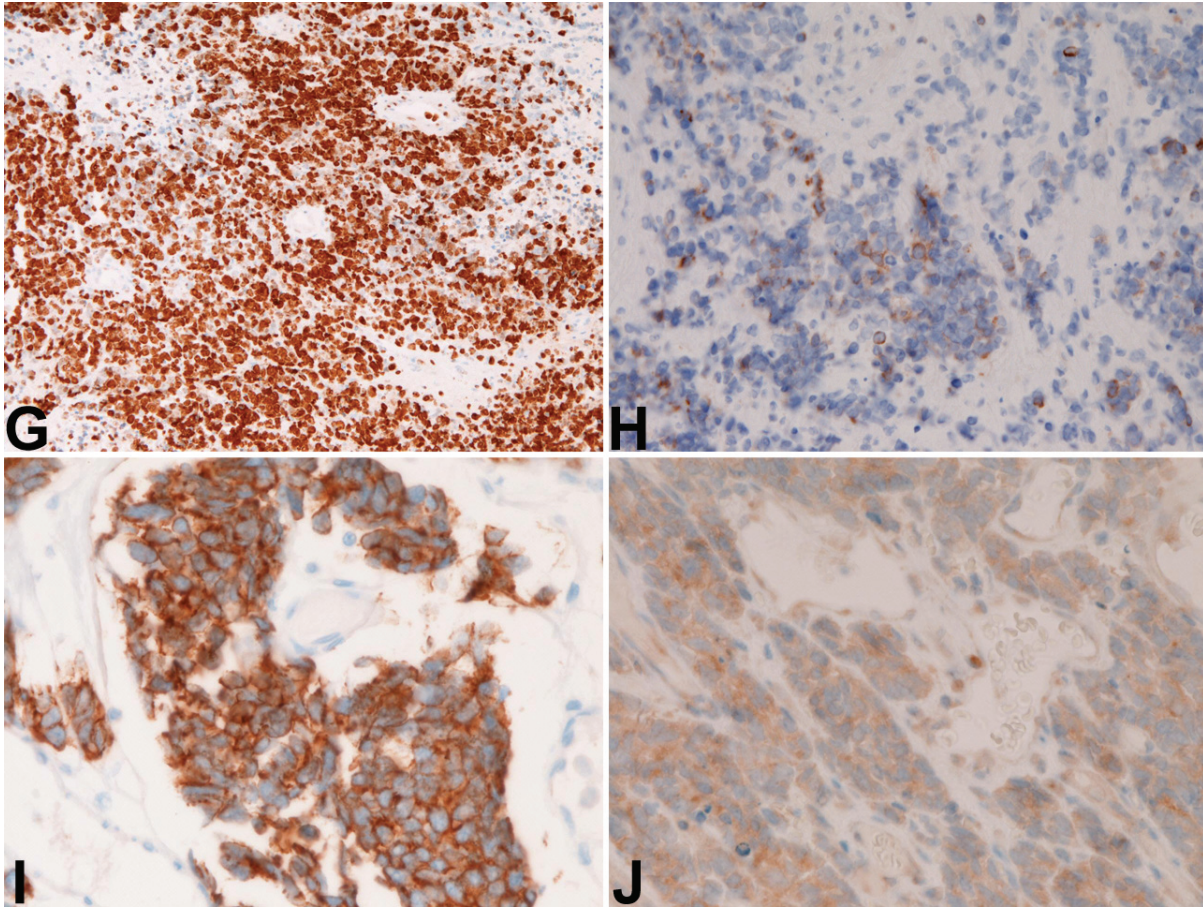


Figure 2. A. Low-power view of small cell carcinoma. HE, x200; B. High-power view of small cell carcinoma. HE, x200; C. Cytokeratin 18 is positive. Immunostaining, x200; D. Synaptophysin is positive. Immunostaining, x200; E. CD56 is positive. Immunostaining, x200; F. P53 protein is positive. Immunostaining, x200; G. K-67 antigen labeling is about 95%, Immunostaining, x200; H. Bcl-2 is positive. Immunostaining, x200; I. KIT is positive. Immunostaining, x200; J. PDGFRA is positive. Immunostaining, x400.

neuroblastoma could not be denied completely.

The immunohistochemical study showed positive reactions for CK 18 (**Figure 2C**), synaptophysin (**Figure 2D**), CD56 (**Figure 2E**), p53 (**Figure 2F**), Ki-67 (labeling=95%) (**Figure 2G**), bcl-2 (**Figure 2H**), KIT (**Figure 2I**) and PDGFRA (**Figure 2J**). However, it showed negative reactions for any types of pancytokeratins, high molecular weight CK, CK5/6, CK7, CK 14, CK 19, CK20, vimentin, neuron-specific enolase, chromogranin, CD15, CD45, S100 protein, CEA, CA19-9, GFAP, neurofilaments, neuroblastoma, CD99, surfactant apoprotein A, melanosome, and TTF-1. The pathologic diagnosis was small cell carcinoma.

The molecular genetic analysis using PCR-direct

sequencing showed no mutations of *KIT* (exons 9, 11, 13, and 17) and *PDGFRA* (exons 12 and 18) genes. The positive control of gastric GISTs showed a point mutation of *KIT*, and negative control of uterine leiomyomas showed no mutations of *KIT* and *PDGFRA*.

Discussion

According to WHO criteria [29], small cell carcinoma is defined as a malignant epithelial tumor consisting of small cells with scant cytoplasm, ill-defined cell borders, finely granular nuclear chromatin, and absent or inconspicuous nucleoli. The cells are round, oval and spindle-shaped, nuclear molding is prominent. Necrosis is typically extensive and mitotic count is high. The present case fulfills these criteria, and is

compatible with small cell carcinoma. Olfactory neuroblastoma and small round cell tumor such as PNET/Ewing tumor are unlikely in the histology as well as negative immunoreactions to GFAP, neurofilaments, neuroblastoma, and CD99.

More than 90 % of small cell carcinoma has neuroendocrine features [29]. The present case also showed neuroendocrine features (positive synaptophysin and CD56). Small cell carcinoma is positive for CK [30]. The present case was positive for only CK18 and negative for vimentin. This indicates that the present case is epithelial malignancy. CK profile is not well known in small cell carcinoma. More studies on CK profile are required in small cell carcinoma.

The present case was positive for bcl-2. Bcl-2 is expressed in 100% in KIT-positive SCLC [31]. The present case was negative for TTF-1. TTF-1 is expressed in 44% in extrapulmonary small cell carcinoma [11].

Small cell carcinoma can occur in any organ, although the vast majority occurs in the lung. In general, small cell carcinoma is a very aggressive tumor with a poor prognosis. In the present case, the patient now is treated with cisplatin-based chemotherapy and radiation. However, the prognosis seems poor.

KIT is expressed in various tumors including gastrointestinal stromal tumor (GIST), mast cell neoplasm, melanoma, germ cell tumor, hematopoietic malignancies and SCLC [1]. Results of protein expression in SCLC vary among researchers; it is reportedly 30%-100% [7-11]. KIT expression without *KIT* gene mutations is thought to be due to *KIT* gene amplification [9]. The prognostic implications of positive KIT protein in SCLC are controversial and no definite conclusions have been made [7-11]. If activating KIT mutations are present, treatment with imatinib mesylate may be effective [1].

KIT mutations are frequent in GIST, acute myeloid leukemia, and mast cell neoplasms [1]. *KIT* mutations have been reported to be none or few [5, 8] in SCLC. In extrapulmonary small cell carcinoma, *KIT* mutations have been reported to be negative [14-16].

There is only one study on *PDGFRA* mutation in small cell carcinoma. Sihto et al. [9] found no

PDGFRA mutations in 31 cases of SCLC. The present case also showed no *PDGFRA* mutations. In extrapulmonary small cell carcinoma, *PDGFRA* mutations have not been reported [14-16].

PDGFRA protein expression has not been reported in SCLC. The present case showed a weak expression of *PDGFRA*, suggesting that a small amount of *PDGFRA* is present in small cell carcinoma. In extrapulmonary small cell carcinoma, weak expression of *PDGFRA* has been reported [14-16]. Many more studies are necessary regarding *PDGFRA* expression and *PDGFRA* gene mutation.

Address correspondence to: Dr. Tadashi Terada, Department of Pathology, Shizuoka City Shimizu Hospital, Miyakami 1231 Shimizu-Ku, Shizuoka 424-8636, Japan Tel: 81-54-336-1111; Fax: 81-54-336-1315; E-mail: piyo0111jp@yahoo.co.jp

References

- [1] Miettinen M, Lasota J. KIT (CD117): a review on expression in normal and neoplastic tissue, and mutations and their clinicopathologic correlation. *Appl Immunohistochem Mol Morphol* 2005; 13: 205-220.
- [2] Hirota S, Isozaki K. Pathology of gastrointestinal stromal tumor. *Pathol Int* 2006; 56: 1-9.
- [3] Perez-Ordóñez B, Caruana SM, Huvos AG, Shah JP. Small cell neuroendocrine carcinoma of the nasal cavity and paranasal sinuses. *Hum Pathol* 1998; 29: 826-832.
- [4] Barin E, Rouleau V, Vedrine PO, Toussaint B, de Raucourt D, Malard O, Cosmidis A, Makaeieff M, Dehesdin D. Small cell neuroendocrine carcinoma of the nasal cavity and paranasal sinuses. *J Laryngol Otol* 2006; 120: 289-297.
- [5] Tarozzi M, Demarosi F, Lodi G, Sardella A, Carrassi A. Primary small cell carcinoma of the nasal cavity with an unusual oral manifestation. *J Oral Pathol Med* 2007; 36: 252-254.
- [6] Terada T. Primary small cell carcinoma of the pleura: A case report with immunohistochemical and molecular genetic analyses of *KIT* and *PDGFRA* genes. *Med Oncol* 2010; 27: 1119-1122.
- [7] Mojica WD, Saxena R, Starostik P, Cheney RT. CD117 + small cell lung cancer lacks the asp 816 val point mutation in exon 17. *Histopathology* 2005; 47: 517-522.
- [8] Boldrini L, Ursino S, Gisfredi S, Faviana P, Donati V, Camcci T, Lucchi M, Mussi A, Basolo F, Pingitore R, Fontanini G. Expression and mutational status of c-kit in small-cell lung cancer: prognostic relevance. *Clin Cancer Res* 2004; 15: 4101-4108.
- [9] Burger H, Den Bakker MA, Stoter G, Verweij J,

Maxillary small cell carcinoma

- Nooter K. Lack of c-kit exon 11 activating mutations in c-kit/CD117-positive SCLC tumor specimens. *Eur J Cancer* 2003; 39: 793-799.
- [10] Sihto H, Sarlomo-Rikara M, Tynniinen O, Tanner M, Andersson LC, Franssila K, Nupponen NN, Joensuu H. *KIT* and platelet-derived growth factor receptor alpha tyrosine kinase gene mutations and *KIT* amplifications in human solid tumors. *J Clin Oncol* 2005; 23: 49-57.
- [11] LaPoint RJ, Bourne PA, Wang HL, Xu H. Coexpression of c-kit and bcl-2 in small cell carcinoma and large cell neuroendocrine carcinoma of the lung. *Appl Immunohistochem Mol Morphol* 2007; 15: 401-406.
- [12] Lopes-Martin A, Ballenstin C, Garcia-Carbonero R, Castano A, Lopez-Rios F, Lopes-Encuentra A, Sanchez-Cespedes M, Castellano D, Bartolomes A, Cortes Funes H, Paz-Ares L. Prognostic value of *KIT* expression in small cell lung carcinoma. *Lung Cancer* 2007; 56: 405-413.
- [13] Micke P, Basral M, Faldum A, Bittinger F, Ronnstrand L, Blaukat A, Beeh KM, Oesch F, Fischer B, Buhl R, Hengstler JG. Characterization of c-kit expression in small cell lung carcinoma: prognostic and therapeutic implications. *Clin Cancer Res* 2003; 9: 188-194.
- [14] Terada T. Primary small cell carcinoma of the mediastinum: A case report with immunohistochemical and molecular genetic analyses of *KIT* and *PDGFRA* genes. *Med Oncol* 2009; 26: 247-250.
- [15] Terada T. Primary small cell carcinoma of the ureter: A case report involving immunohistochemical and molecular genetic analyses of *KIT* and *PDGFRA* genes. *Pathology* 2010; 42: 101-102.
- [16] Terada T. Autopsy case of primary small cell carcinoma of the urinary bladder: *KIT* and *PDGFRA* expression and mutations. *Pathol Int* 2009; 59: 247-250.
- [17] Terada T, Kawaguchi M. Primary clear cell adenocarcinoma of the peritoneum. *Tohoku J Exp Med* 2005; 206: 271-275.
- [18] Terada T, Kawaguchi M, Furukawa K, Sekido Y, Osamura Y. Minute mixed ductal-endocrine carcinoma of the pancreas with predominant intraductal growth. *Pathol Int* 2002; 52: 740-746.
- [19] Terada T. Gastrointestinal stromal tumor of the uterus: a case report with genetic analyses of c-kit and *PDGFRA* genes. *Int J Gynecol Pathol* 2009; 28: 29-34.
- [20] Terada T. Primary extragastrointestinal stromal tumors of the transverse mesocolon without c-kit mutations but with *PDGFRA* mutations. *Med Oncol* 2009; 26: 233-237.
- [21] Terada T. Primary multiple extragastrointestinal stromal tumors of the omentum with different mutations of c-kit gene. *World J Gastroenterol* 2008; 14: 7256-7259.
- [22] Terada T. Mediastinal seminoma with multiple *KIT* gene mutations. *Pathology* 2009; 41: 695-697.
- [23] Terada T. *KIT*-positive primary small cell carcinoma of the endometrium: A case report with immunohistochemical and molecular genetic analyses of *KIT* and *PDGFRA* genes. *Arch Gynecol Obstet* 2010; 282: 413-416.
- [24] Terada T. Large cell neuroendocrine carcinoma with sarcomatous changes of the endometrium: a case report with immunohistochemical studies and molecular genetic study of *KIT* and *PDGFRA*. *Pathol Res Pract* 2010; 206: 420-425.
- [25] Terada T. Low incidence of *KIT* gene mutations and no *PDGFRA* gene mutations in primary cutaneous melanoma: an immunohistochemical and molecular genetic study of Japanese cases. *Int J Clin Oncol* 2010; 15: 453-456.
- [26] Terada T. Neuroendocrine carcinoma of the esophagus: a case report with immunohistochemical and molecular genetic analysis of *KIT* and *PDGFRA*. *Med Oncol* 2011; 28: 509-512.
- [27] Terada T. Mutations and protein expression of *KIT* and *PDGFRA* genes in ipsilateral testicular seminomas: an immunohistochemical and molecular genetic study. *Appl Immunohistochem Mol Morphol* 2011; 19: 450-453.
- [28] Terada T. Protein expression and gene mutation status of *KIT* and *PDGFRA* in renal cell carcinoma. *Histol Histopathol* 2012; 27: 297-302.
- [29] Travis W, Petersen I, Nicholson S, Meyerson M, Hirsch FR, Hanash SM, Pugatch B, Jen J, Geisinger K, Takahashi K, Brambilla E, Fernandez EA, Gazdar A, Capron F. Small cell carcinoma. In: Travis WD, Brambilla E, Muller-Hermelink HK, Harris CC eds. *WHO Classification of tumours. Pathology and genetics, Tumours of the lung, pleura, thymus and heart*. IARC Press, Lyon. pp31-34.
- [30] Van Muijen GN, Ruiters DJ, van Leeuwen C, Prins FA, Rietsema K, Warnaar SO. Cytokeratin and neurofilament in lung carcinomas. *Am J Pathol* 1984; 116: 363-369.
- [31] Agoff SN, Lamps LW, Philip AT, Amin MB, Schmidt RA, True LD, Folpe AL. Thyroid transcription factor-1 is expressed in extrapulmonary small cell carcinomas but not in other extrapulmonary neuroendocrine tumors. *Mod Pathol* 2000; 13: 238-242.