

Comprehensive Management of Subclavian Vein Effort Thrombosis

Robert W. Thompson, M.D.^{1,2}

¹The Center for Thoracic Outlet Syndrome and the Department of Surgery, Section of Vascular Surgery

²Radiology, Washington University School of Medicine, St. Louis, Missouri

Semin Intervent Radiol 2012;29:44–51

Address for correspondence and reprint requests Robert W.

Thompson, M.D., Section of Vascular Surgery, Center for Thoracic Outlet Syndrome, Washington University School of Medicine, 5101 Queeny Tower, One Barnes-Jewish Hospital Plaza, Campus Box 8109, St. Louis, MO 63110 (e-mail: thompson@wudosis.wustl.edu).

Abstract

Keywords

- ▶ upper extremity venous thrombosis
- ▶ axillary-subclavian vein
- ▶ thoracic outlet syndrome
- ▶ thrombolysis
- ▶ first rib
- ▶ surgical treatment

Subclavian vein (SCV) effort thrombosis, also known as the Paget-Schroetter syndrome, is a relatively uncommon condition that affects young, active, otherwise healthy individuals. It is considered a form of thoracic outlet syndrome, arising as a consequence of compression and repetitive injury of the SCV between the first rib and the overlying clavicle, as well as the anterior scalene muscle, subclavius muscle, and costoclavicular ligament. Effort thrombosis is distinct from other forms of deep vein thrombosis with respect to pathophysiology, clinical presentation, and functional consequences, and it requires treatment considerations unique to effective management of thoracic outlet compression as well as the obstructed SCV. In this review the comprehensive management of SCV effort thrombosis is addressed, with an emphasis on current interventional radiology techniques used in conjunction with definitive surgical treatment, based on early catheter-based venography, thrombolytic therapy, and prompt paraclavicular thoracic outlet decompression with direct SCV reconstruction.

Objectives: Upon completion of this article, the reader should be able to list the pathophysiology and optimal initial management of subclavian vein effort thrombosis, as well as the indications, timing, and approaches used for surgical treatment of venous thoracic outlet syndrome.

Accreditation: Tufts University School of Medicine is accredited by the Accreditation Council for Continuing Medical Education to provide continuing medical education for physicians.

Credit: Tufts University School of Medicine designates this journal-based CME activity for a maximum of 1 *AMA PRA Category 1 Credit*[™]. Physicians should claim only the credit commensurate with the extent of their participation in the activity.

Pathophysiology

Subclavian vein (SCV) effort thrombosis is considered primarily a “mechanical” condition caused by venous compression, and unlike other forms of deep vein thrombosis (DVT) is not

associated with inactivity, obesity, advanced age, underlying coagulation disorders, surgery, or trauma.¹ The pathogenesis of effort thrombosis involves extrinsic compression of the SCV between the clavicle and first rib, as well as the anterior scalene muscle, the subclavius muscle, and the costoclavicular ligament. Venous compression is particularly noted during activities involving arm elevation or exertion.² With repetition over a long period of time, this type of focal venous injury leads to progressive fibrous stenosis of the SCV at the level of the first rib, involving scar tissue formation and contraction around the outside of the vein, as well as fibrosis and thickening within the wall of the vein itself. This initial phase of venous thoracic outlet syndrome (TOS) is usually prolonged and asymptomatic, due to the simultaneous expansion of dense collateral veins around the obstruction that facilitate drainage of the upper extremity. Thrombotic occlusion eventually occurs due to stagnant and turbulent blood flow in the narrowed segment of the SCV. Propagation and upstream extension of this thrombus into the axillary vein can then result in further obstruction of critical collateral

Issue Theme Venous Thromboembolism; Guest Editors, Suresh Vedantham, M.D., F.S.I.R., and Nael Saad, M.D.

Copyright © 2012 by Thieme Medical Publishers, Inc., 333 Seventh Avenue, New York, NY 10001, USA.
Tel: +1(212) 584-4662.

DOI <http://dx.doi.org/10.1055/s-0032-1302451>.
ISSN 0739-9529.

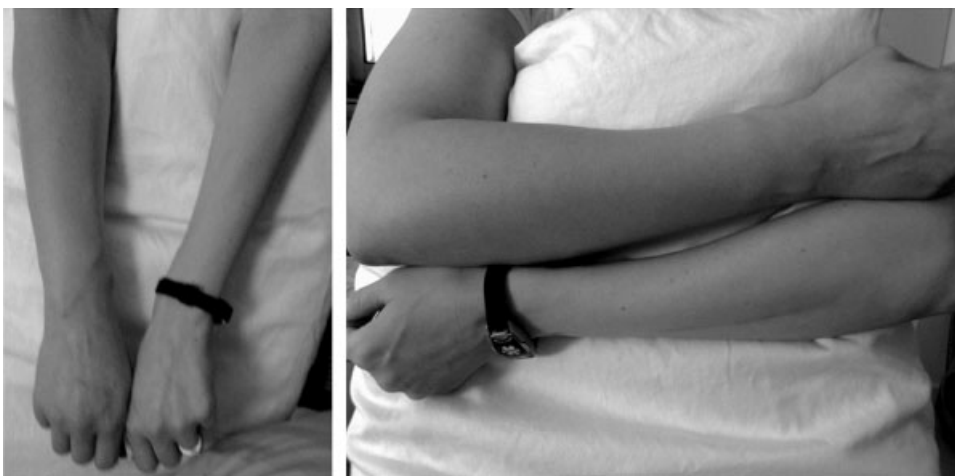

Figure 1 Clinical presentation of subclavian vein (SCV) effort thrombosis. Photographs depicting an otherwise healthy active young woman who had experienced the recent onset of right upper extremity swelling and cyanotic discoloration, extending from the shoulder to the hand, due to SCV effort thrombosis.

veins, resulting in the acute clinical presentation of the effort thrombosis syndrome.

Pulmonary embolism from the SCV may also occur and is currently estimated to occur in ~10 to 20% of patients with effort thrombosis; this is infrequent when compared with DVT in the lower extremities. Moreover, the mechanical obstruction of the SCV in venous TOS serves to prevent central embolization of any large clot from the more peripheral vein, and the amount of thrombus that might arise from the proximal portion of the SCV is typically small, such that the clot burden associated with pulmonary emboli from SCV effort thrombosis typically remains minimal and not life threatening.

Clinical Presentation and Diagnosis

SCV effort thrombosis is characterized by the abrupt, spontaneous swelling of the entire arm, often with cyanotic discoloration, heaviness, and pain (► **Fig. 1**).³ This condition most frequently occurs in individuals between 15 and 45 years of age, with an equal distribution between males and females. Most patients are physically active, with many engaged in work-related or recreational activities that involve vigorous use of the upper extremities in repetitive overhead positions and/or heavy lifting. The magnitude of arm swelling is usually quite substantial, with the diameter of the affected extremity increased as much as twice that of the opposite side. Most patients also describe fatigue, tightness, heaviness, and pain in the arm, especially with use or overhead positioning. Many exhibit enlarged subcutaneous veins in the upper arm, around the shoulder, or in the upper anterior chest wall. In the vast majority of situations, the clinical diagnosis of SCV effort thrombosis is apparent from the stereotypical history and physical examination findings. Thus, in the absence of an indwelling central venous catheter, any young healthy active individual presenting with the sudden onset of arm swelling and cyanotic discoloration should be suspected of having SCV effort thrombosis.

Once the diagnosis of SCV effort thrombosis is suspected, patients should be started on anticoagulation treatment with intravenous or subcutaneous heparin. This is important to help prevent the extension of venous thrombus, and it can be undertaken while additional diagnostic studies are being performed and/or prior to patient transfer from one hospital to another. Treatment with an antiplatelet agent, such as aspirin or clopidogrel, is often initiated. It has been reported that up to 70% of patients with venous TOS may have associated abnormalities in initial coagulation tests.⁴ Because such abnormalities may influence subsequent patient management, a panel of functional and genetic coagulation studies should usually be obtained either during the initial diagnostic evaluation or in follow-up. These further tests are typically negative and thereby add little to the initial diagnosis, consistent with the view that venous TOS is a “mechanical” anatomical problem rather than a procoagulant hematologic disorder.

Upper extremity duplex imaging is often used to evaluate patients with arm swelling because it is noninvasive, inexpensive, and readily available, and such studies are of confirmatory value if positive for axillary or subclavian vein obstruction. However, duplex imaging of the SCV is complicated by the superimposed clavicle and the depth of the vein in the neck, and it is highly technician dependent. Expanded collateral veins may also be mistaken for the SCV, and indirect hemodynamic measures of venous flow may not accurately reflect the status of the proximal SCV. Duplex imaging studies thereby have a false-negative rate as high as 30% for SCV effort thrombosis, making them insufficient to exclude the diagnosis of venous TOS.²

In current practice, contrast-enhanced computed tomography (CT) or magnetic resonance imaging (MRI) angiography are both used with greater frequency as the initial noninvasive diagnostic studies for SCV effort thrombosis. These studies are highly accurate in detecting axillary-subclavian vein occlusion and/or focal stenosis at the level of the first rib. They also provide information on the presence or absence of

enlarged collateral veins and the chronicity of any thrombus present, and they can be performed at rest and with elevated arm positions to elucidate positional SCV obstruction. Because these studies provide more anatomical information than venous duplex imaging, CT or MRI venography can be used to accurately exclude the diagnosis of venous TOS when ultrasound studies are negative.

The most direct and definitive means to confirm the diagnosis of SCV effort thrombosis is through catheter-directed contrast venography. This provides complete anatomical information regarding the site and extent of thrombosis, allows definitive evaluation of the collateral venous pathways, and is a necessary step toward the use of thrombolytic therapy, which is the preferred initial step in treatment for almost all patients presenting with SCV effort thrombosis. Indeed, in our current practice we do not rely on duplex studies or other noninvasive imaging tests but use catheter-based upper extremity venography as the most practical, efficient, and cost-effective approach to evaluating the patient with suspected SCV effort thrombosis.

Initial Interventional Management

The short- and long-term goals of treatment for SCV effort thrombosis are fourfold: (1) to provide prompt relief of acute upper extremity symptoms and prevent pulmonary embolism; (2) to reduce the likelihood of recurrent venous thrombosis following initial management, (3) to diminish or prevent the potential development of upper extremity post-thrombotic syndrome, and (4) to return to normal unrestricted use of the upper extremity without the need for chronic anticoagulation and other medications.

Current approaches to SCV effort thrombosis emphasize early diagnosis by contrast venography and prompt use of catheter-based thrombolytic therapy to reduce the amount of thrombus within the axillary and subclavian veins (►Fig. 2).^{1,5} Venous thrombolysis has traditionally been performed by continuous infusion of the thrombolytic agent through a multihole catheter placed directly within the axillary-subclavian vein thrombus at the time of the initial venogram. The thrombolytic agent is infused up to 24 to 48 hours with interval follow-up venograms until a maximum effect is achieved. This algorithm typically requires monitoring in an acute care setting for several days. Over the past several years it has become more efficacious to perform thrombolysis with catheter-based pharmacomechanical thrombectomy, in which a mechanical device is used to rapidly break up the clot, along with localized infusion of a much smaller amount of thrombolytic agent.⁶ The great advantage of this approach is that it can often be completed in fewer stages than infusion therapy, often within several hours, thereby avoiding a prolonged stay in a monitored hospital setting.

The goal of thrombolysis is to clear any fresh or recent clot from the axillary and subclavian veins, along with any occluded venous collaterals passing through the thoracic outlet space. This usually results in a marked improvement in the venographic appearance of the SCV as well as a prompt

reduction in symptoms of venous obstruction. Following successful thrombolysis, a focal occlusion or residual high-grade stenosis is usually identified in the proximal SCV at the level of the first rib (►Fig. 2C). It is important to recognize that this stenosis represents the underlying scar tissue caused by previous subclavian vein compression, injury, and tissue repair, rather than residual thrombus. In some cases balloon angioplasty may be used in an attempt to reduce the degree of stenosis in the SCV (►Fig. 2D and E). However, balloon angioplasty is often unsuccessful in this setting because the vein is obstructed by scar tissue as well as by external compression between the clavicle and first rib, and even when improvement is obtained it is usually short lived. It has become clear that indwelling endovascular stents should not be placed in the SCV, at least prior to surgical decompression, due to an inevitably high rate of failure.⁷ Following thrombolytic therapy, with or without adjunctive balloon angioplasty, the patient should remain on systemic anticoagulation while awaiting the definitive treatment.

Nonsurgical Management

Nonoperative management of SCV effort thrombosis includes chronic anticoagulation, intermittent arm elevation, long-term restrictions in arm activity, and the use of compression sleeves. This is done in the hope that thrombolysis will have created a sufficient venous channel to prevent recurrent thrombosis and that increased collateral development will eventually compensate for SCV obstruction. Unfortunately, long-term anticoagulation rarely results in symptom-free use of the arm, and it is associated with a significant incidence of chronic venous congestion, with considerable consequent limitations in young active patients.⁸⁻¹² Unlike lower extremity DVT, the proper duration of anticoagulation treatment for SCV effort thrombosis is not known. Because this condition is caused by compression of the vein rather than a disorder of blood clotting, many recommend lifelong anticoagulation. It is notable that there is still a significant risk of recurrent thrombosis following thrombolysis and anticoagulation alone, with estimates ranging from 50 to 70%.¹³ Surgical treatment therefore should be considered in almost all patients with venous TOS and SCV effort thrombosis as the most definitive management approach.

Timing of Surgical Treatment

Operative treatment for SCV effort thrombosis is centered on two goals: (1) decompression of the subclavian vein and collateral venous pathways through the thoracic outlet, by removal of the first rib and associated scalene and subclavius muscles, and (2) restoration and maintenance of normal blood flow through the SCV, by removing constricting scar tissue from around the vein, using either adjunctive balloon angioplasty or direct venous reconstruction. Although patients with SCV effort thrombosis are typically young and physically active, there are no intrinsic physical limitations imposed by removal of the first rib and associated scalene and subclavius muscles, such that a full return to recreational and

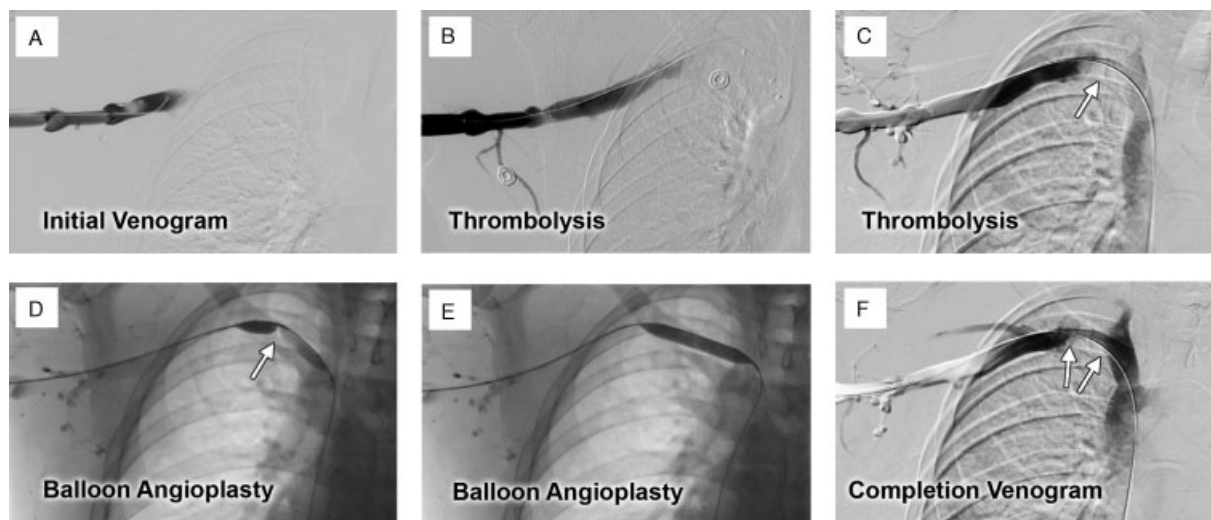


Figure 2 Initial management of subclavian vein (SCV) effort thrombosis. Initial interventional management of a young man with right-sided SCV effort thrombosis. (A) Initial venogram confirming axillary-subclavian vein occlusion, with venous obstruction extending to the lateral chest wall. Very few collaterals are noted, compatible with acute obstruction. (B) Partial resolution of thrombus following catheter-directed thrombolytic therapy, clearing much of the axillary vein. (C) Restoration of axillary-subclavian vein patency with further thrombolytic therapy, revealing a residual high-grade stenosis in the SCV at the level of the first rib (arrow). (D) Inflation of an angioplasty balloon across the area of SCV stenosis, demonstrating the focal nature of the lesion as evidenced by effacement of the midportion of the balloon (arrow). (E) Successful inflation of the angioplasty balloon across the area of SCV stenosis. (F) Completion venogram demonstrating improved patency of the SCV with an area of persistent venous stenosis at the first rib (arrows).

occupational activities can be anticipated following recovery from surgery; this is true even for highly competitive athletes.²

The vast majority of patients with recent SCV effort thrombosis are excellent candidates for surgical treatment, particularly within the first several weeks of undergoing successful thrombolytic therapy. However, patients with long-standing untreated subclavian vein occlusion or those who exhibit a long segment of residual venous occlusion extending into the axillary vein despite thrombolysis are often considered to be unsuitable for surgical treatment. This judgment depends in large part on the surgical experience available and the surgical approaches to venous TOS preferentially used in any particular medical center. Protocols for the management of SCV effort thrombosis have evolved considerably, particularly since the introduction of thrombolytic therapy for this condition.

The first widely used surgical protocol for SCV effort thrombosis was described by Machleder and colleagues, involving a 3-month period of anticoagulation followed by transaxillary first rib resection.¹⁴⁻¹⁶ Approximately, 70% of patients following this protocol required surgery for persistent symptoms after 3 months of anticoagulation, with up to 30% having had recurrent thrombosis. Clinical outcomes were also influenced by the status of the SCV following decompression; 90 to 95% of those with a patent SCV were free of symptoms, as compared with 64% of those with an occluded SCV. Reports from other centers indicated that the interval for reevaluation of patients on anticoagulation can be effectively decreased to 1 month following thrombolysis, to diminish the period of time during which rethrombosis might occur.^{17,18} Using this algorithm, Lee et al reported that 13 of 22 patients

(59%) had successful outcomes in both the operative and nonoperative treatment groups.¹⁷ However, in a later report of 64 patients, 29 required surgery within 3 months of thrombolysis and 8 conservatively managed patients had recurrent thrombosis requiring later surgical treatment, for an overall rate of 58% requiring surgery.¹⁸

With the recognition that most patients with SCV effort thrombosis will require surgical treatment within 1 to 3 months of thrombolytic therapy, efforts have been made to reduce the overall duration of treatment by proceeding with surgery within days to weeks after thrombolysis. This has been coupled with attempts to improve outcomes further by combining first rib resection with postoperative balloon angioplasty at various intervals after the operation.¹⁹⁻²¹ Excellent results have been reported with these strategies, but the actual outcome of delayed balloon angioplasty for venous TOS remains unclear. Indeed, a substantial number of patients may remain with residual SCV obstruction refractory to any intervention, for which long-term anticoagulation may be required.

Surgical Approaches

The most recent evolution in treatment for SCV effort thrombosis has involved wider use of anterior surgical approaches to thoracic outlet decompression and direct reconstruction of the SCV at the time of surgery.^{2,22-27} Molina and colleagues reported results with immediate surgery using subclavicular decompression and subclavian vein patch angioplasty in 114 patients.²⁶ Outcomes were uniformly successful in 97 of their patients (85%) who were treated within 2 weeks of symptoms; however, all 17 of their patients (15%) with a symptom

duration >2 weeks had developed progressive SCV fibrosis, with 12 of 17 (70%) having postoperative restenosis and 5 (30%) being considered inoperable. As an alternative, our group has advocated the use of paraclavicular thoracic outlet decompression to extend this strategy and to offer definitive surgical treatment to a broader spectrum of patients.^{2,22,27} This approach permits complete first rib resection and more thorough venous decompression than can be achieved through previous approaches, as well as optimal exposure to accomplish direct subclavian vein reconstruction. The paraclavicular approach also allows these steps to be accomplished during a single operative procedure and hospital stay, with excellent functional outcomes.

Transaxillary Thoracic Outlet Decompression

Transaxillary first rib resection remains a frequently used approach to the treatment of venous TOS, typically involving partial resection of the first rib and division of its scalene muscle attachments.²⁸ Because it is not feasible to fully expose or control the SCV from the transaxillary approach, direct evaluation and/or venous reconstruction is not performed. Rather, transaxillary first rib resection is usually coupled with intraoperative or postoperative venography,

balloon angioplasty, and/or stent placement, to deal with any residual SCV stenosis.²⁹ Current estimates indicate that 40 to 50% of patients will demonstrate a residual SCV stenosis requiring balloon angioplasty, even several weeks after first rib resection. Because these lesions are typically composed of dense scar tissue within and around the wall of the vein, balloon angioplasty may be relatively ineffective in this setting. Although placement of SCV stents may be considered, the long-term effectiveness of stents in this position is questionable. Long-term anticoagulation may therefore be needed to reduce the potential for recurrent venous thrombosis.³⁰ For these reasons we prefer more direct and complete surgical approaches in the management of patients with venous TOS.

Paraclavicular Thoracic Outlet Decompression

The paraclavicular approach combines the advantages of the supraclavicular exposure used for neurogenic and arterial forms of TOS with an infraclavicular incision that permits complete resection of the medial first rib, as well as wide exposure of the SCV to permit vascular reconstruction. With this approach we offer operative decompression to virtually all patients with symptomatic venous TOS or recent effort

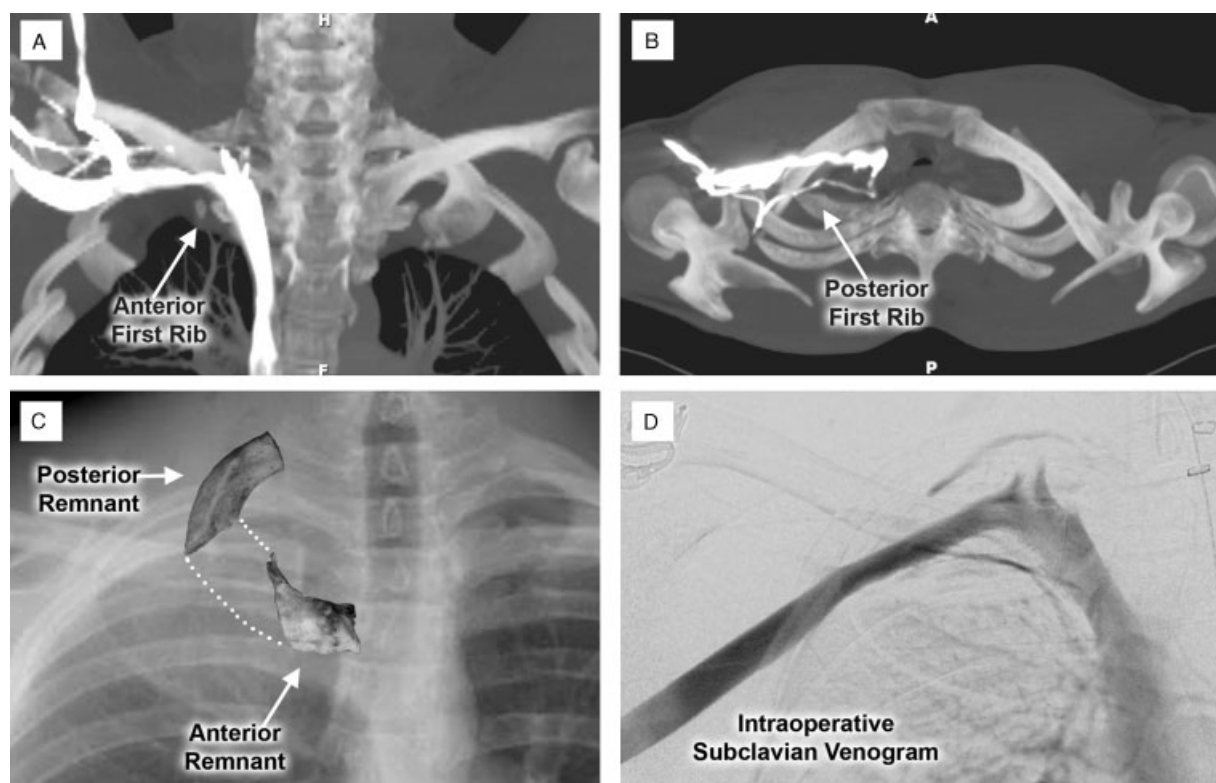


Figure 3 Paraclavicular approach for reoperative treatment of venous thoracic outlet syndrome. Images from an active young man who had developed right-sided subclavian vein (SCV) effort thrombosis and was treated by thrombolysis and first rib resection. Over the following year he continued to experience exertional right upper extremity swelling and pain, despite several attempts at SCV balloon angioplasty. (A) Maximal intensity projection coronal (MIP) images from a contrast-enhanced computed tomography study demonstrating a persistent focal stenosis in the proximal right SCV during arm elevation, located adjacent to a small remnant of the anterior first rib (arrow). (B) Axial MIP images demonstrating expanded collateral venous pathways passing through the thoracic outlet adjacent to a remnant of the posterior first rib (arrow). (C) Operative specimens of the anterior and posterior first rib remnants removed during paraclavicular decompression, superimposed on the plain chest radiograph (arrows). (D) Intraoperative contrast venogram obtained following first rib resection and external venolysis, demonstrating a widely patent SCV with minimal filling of collateral venous pathways.

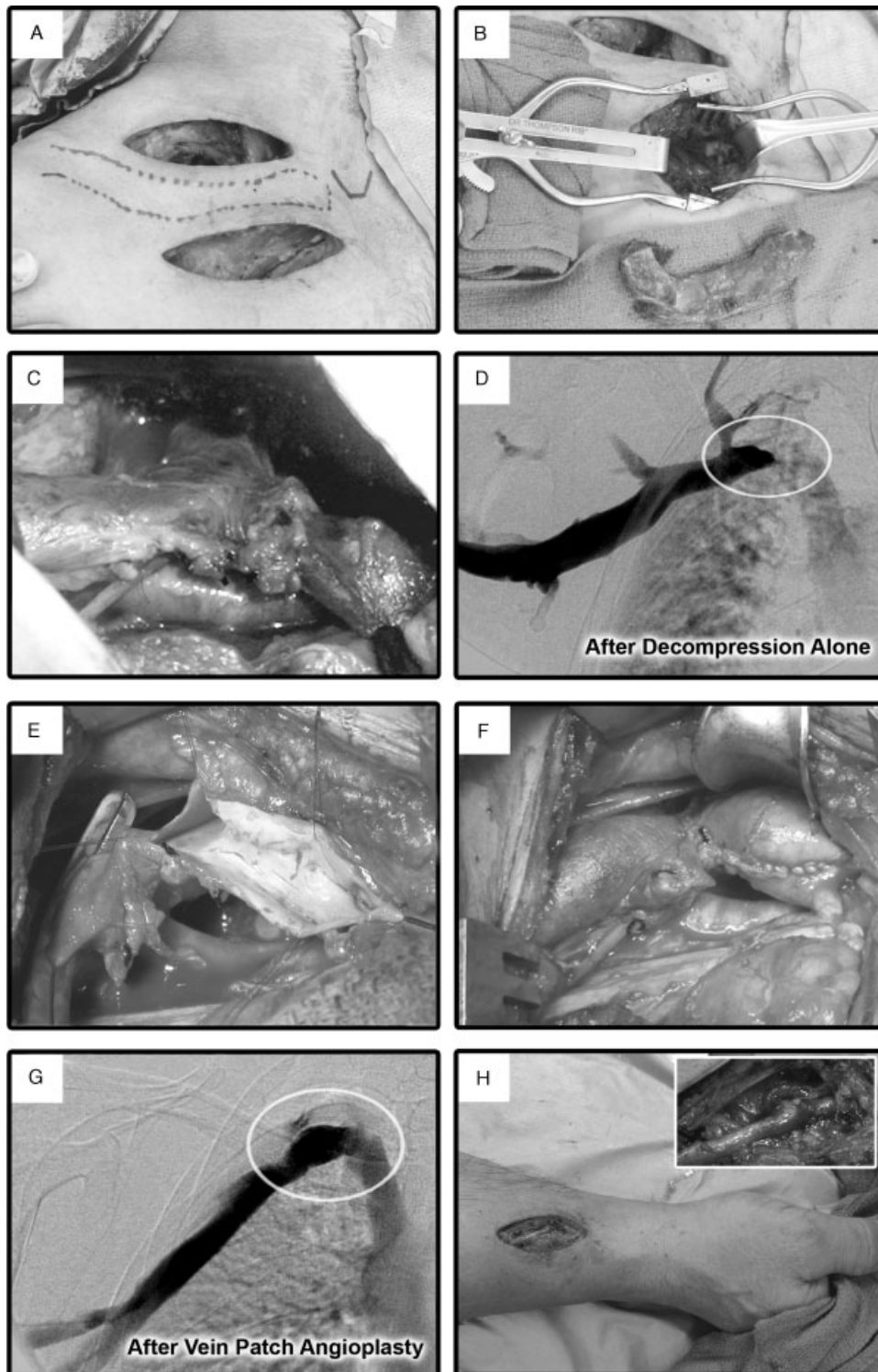


Figure 4 Surgical management of subclavian vein (SCV) effort thrombosis by paraclavicular thoracic outlet decompression and direct venous reconstruction. (A) Supraclavicular and infraclavicular incision locations for thoracic outlet decompression. (B) Following scalenectomy and division of the posterior first rib through the supraclavicular exposure, the medial first rib is exposed and divided at the level of the sternum through the infraclavicular exposure, and the entire first rib is removed as a single specimen. (C) Following resection of the subclavius muscle and exposure of the axillary vein through the infraclavicular incision, the proximal SCV is exposed through the supraclavicular incision. The SCV is dissected to its junction with the internal jugular and innominate veins, and fibrous scar tissue surrounding the SCV is resected. A focal area of persistent fibrosis in the proximal SCV is present despite external venolysis. (D) Intraoperative venogram following the decompression portion of the operation, demonstrating a residual high-grade obstruction of the proximal SCV (oval). (E) A longitudinal venotomy is created in the proximal SCV, extending through the site of the focal stenosis. The luminal surface of the SCV is free of thrombus or ulceration. (F) Construction of a vein patch angioplasty of the SCV, extending into the anterolateral aspect of the innominate vein. (G) Completion intraoperative venogram following vein patch angioplasty, demonstrating restoration of a widely patent SCV with no filling of venous collaterals. (H) Construction of an adjunctive radiocephalic arteriovenous fistula at the right wrist, which will be subsequently ligated 12 weeks after the primary operation.

thrombosis, regardless of the interval between initial diagnosis and referral, previous treatment, or adverse findings on contrast venography. This surgical approach is successful in restoring a patent venous system in ~50% of patients even without a more direct venous reconstruction. The flexibility of the paraclavicular exposure also allows definitive treatment even in challenging reoperative situations for patients who have had persistent or recurrent symptoms despite previous surgical treatment (►Fig. 3). We therefore believe that operative procedures based on paraclavicular exposure provide the most versatile, comprehensive, and safe approach to the treatment of venous TOS.^{2,27}

For paraclavicular decompression, two incisions are used: a supraclavicular exposure similar to that used in other operations for TOS and an infraclavicular exposure over the anteromedial first rib (►Fig. 4A).^{31,32} The cartilaginous portion of the first rib is divided adjacent to the sternum, with the first rib removed from the operative field as a single specimen (►Fig. 4B). Pathological changes in the central portion of the SCV are visually assessed, and any residual scar tissue surrounding the vein is completely excised (“circumferential external venolysis”) (►Fig. 4C). SCV reconstruction is performed when external venolysis does not alleviate subclavian vein obstruction or when intraoperative venography demonstrates a residual stenosis following external venolysis (►Fig. 4D). Following systemic anticoagulation and clamp control, a longitudinal venotomy is created along the superior aspect of the subclavian vein as visualized from the supraclavicular exposure (►Fig. 4E). If the luminal surface is smooth and free of thrombus and/or irregularity, a vein patch angioplasty is performed using a segment of cryopreserved femoral vein or autologous greater saphenous vein (►Fig. 4F). It is important to construct the patch to span the entire length of the affected subclavian vein, with extension into the anteromedial aspect of the normal innominate vein. When the SCV is occluded or its wall is thickened by dense fibrosis, the affected segment of SCV is excised and replaced by an interposition bypass graft, typically constructed from the unaffected distal axillary-subclavian vein to the anteromedial aspect of the innominate vein. We have found that SCV interposition bypass is most easily performed using a segment of cryopreserved femoral vein, which can be readily matched for the size of the SCV.

Intraoperative venography is used to confirm satisfactory SCV reconstruction, allowing any deficiencies to be immediately corrected (►Fig. 4G). Our operative approach also frequently includes construction of an arteriovenous fistula (AVF) at the wrist, between the end of the distal cephalic vein and the side of the radial artery (►Fig. 4H). This adjunctive AVF is used to increase upper extremity venous flow during the first several months after operation, and it is subsequently ligated under local anesthesia 12 weeks after surgical treatment. Follow-up contrast venography is also performed at that time.

Postoperative care for patients undergoing surgical interventions includes ample use of pain medications, muscle relaxants, and anti-inflammatory agents. Therapeutic anticoagulation (heparin/warfarin), with or without adjunctive

antiplatelet therapy (aspirin or clopidogrel), is initiated several days after the operation and then discontinued at 12 weeks. The potential complications of surgery are pneumothorax; pleural effusion; postoperative thoracic duct lymph leak; temporary or permanent brachial plexus, phrenic nerve, or long thoracic nerve injury/dysfunction; subclavian artery or vein injury; postoperative bleeding or wound hematoma (associated with excessive anticoagulation); residual SCV obstruction or early postoperative rethrombosis; and late postoperative axillary or subclavian vein obstruction, rethrombosis, and recurrent symptoms. The expected postoperative hospital stay is 5 to 6 days, with the closed-suction drain removed ~6 to 7 days after the operation. Inpatient physical therapy is started the day after the operation to maintain range of motion, with postoperative rehabilitation then overseen by a physical therapist with expertise in the management of TOS, and no restrictions placed on upper extremity activity beyond 12 weeks after surgery. Full recovery is typically complete within 3 months of the operation, and a return to previous levels of functional activity can usually be expected.

Acknowledgments

This work was supported in part by the Thoracic Outlet Syndrome Research and Education Fund, Barnes-Jewish Hospital Foundation, St. Louis, MO.

References

- Illig KA, Doyle AJ. A comprehensive review of Paget-Schroetter syndrome. *J Vasc Surg* 2010;51(6):1538–1547
- Melby SJ, Vedantham S, Narra VR, et al. Comprehensive surgical management of the competitive athlete with effort thrombosis of the subclavian vein (Paget-Schroetter syndrome). *J Vasc Surg* 2008;47(4):809–820; discussion 821
- Sanders RJ, Hammond SL. Venous thoracic outlet syndrome. *Hand Clin* 2004;20(1):113–118, viii
- Cassada DC, Lipscomb AL, Stevens SL, Freeman MB, Grandas OH, Goldman MH. The importance of thrombophilia in the treatment of Paget-Schroetter syndrome. *Ann Vasc Surg* 2006;20(5):596–601
- Rutherford RB. Primary subclavian-axillary vein thrombosis: the relative roles of thrombolysis, percutaneous angioplasty, stents, and surgery. *Semin Vasc Surg* 1998;11(2):91–95
- Schneider DB, Curry TK, Eichler CM, Messina LM, Gordon RL, Kerlan RK. Percutaneous mechanical thrombectomy for the management of venous thoracic outlet syndrome. *J Endovasc Ther* 2003;10(2):336–340
- Urschel HC Jr, Patel AN. Paget-Schroetter syndrome therapy: failure of intravenous stents. *Ann Thorac Surg* 2003;75(6):1693–1696; discussion 1696
- Adams JT, McEvoy RK, DeWeese JA. Primary deep venous thrombosis of the upper extremity. *Arch Surg* 1965;91:29–42
- Tilney ML, Griffiths HJG, Edwards EA. Natural history of major venous thrombosis of the upper extremity. *Arch Surg* 1970;101(6):792–796
- Donayre CE, White GH, Mehlinger SM, Wilson SE. Pathogenesis determines late morbidity of axillosubclavian vein thrombosis. *Am J Surg* 1986;152(2):179–184
- Gloviczki P, Kazmier FJ, Hollier LH. Axillary-subclavian venous occlusion: the morbidity of a nonlethal disease. *J Vasc Surg* 1986;4(4):333–337

- 12 Lindblad B, Tengborn L, Bergqvist D. Deep vein thrombosis of the axillary-subclavian veins: epidemiologic data, effects of different types of treatment and late sequelae. *Eur J Vasc Surg* 1988;2(3):161–165
- 13 Aziz S, Straehley CJ, Whelan TJ Jr. Effort-related axillosubclavian vein thrombosis. A new theory of pathogenesis and a plea for direct surgical intervention. *Am J Surg* 1986;152(1):57–61
- 14 Kunkel JM, Machleder HI. Spontaneous subclavian vein thrombosis: a successful combined approach of local thrombolytic therapy followed by first rib resection. *Surgery* 1989;106(1):114
- 15 Kunkel JM, Machleder HI. Treatment of Paget-Schroetter syndrome. A staged, multidisciplinary approach. *Arch Surg* 1989;124(10):1153–1157; discussion 1157–1158
- 16 Machleder HI. Evaluation of a new treatment strategy for Paget-Schroetter syndrome: spontaneous thrombosis of the axillary-subclavian vein. *J Vasc Surg* 1993;17(2):305–315; discussion 316–317
- 17 Lee WA, Hill BB, Harris EJ Jr, Semba CP, Olcott C IV. Surgical intervention is not required for all patients with subclavian vein thrombosis. *J Vasc Surg* 2000;32(1):57–67
- 18 Lee JT, Karwowski JK, Harris EJ, Haukoos JS, Olcott C IV. Long-term thrombotic recurrence after nonoperative management of Paget-Schroetter syndrome. *J Vasc Surg* 2006;43(6):1236–1243
- 19 Urschel HC Jr, Razzuk MA. Improved management of the Paget-Schroetter syndrome secondary to thoracic outlet compression. *Ann Thorac Surg* 1991;52(6):1217–1221
- 20 Angle N, Gelabert HA, Farooq MM, et al. Safety and efficacy of early surgical decompression of the thoracic outlet for Paget-Schroetter syndrome. *Ann Vasc Surg* 2001;15(1):37–42
- 21 Caparrelli DJ, Freischlag J. A unified approach to axillosubclavian venous thrombosis in a single hospital admission. *Semin Vasc Surg* 2005;18(3):153–157
- 22 Thompson RW, Schneider PA, Nelken NA, Skioldebrand CG, Stoney RJ. Circumferential venolysis and paraclavicular thoracic outlet decompression for “effort thrombosis” of the subclavian vein. *J Vasc Surg* 1992;16(5):723–732
- 23 Molina JE. Surgery for effort thrombosis of the subclavian vein. *J Thorac Cardiovasc Surg* 1992;103(2):341–346
- 24 Molina JE. Need for emergency treatment in subclavian vein effort thrombosis. *J Am Coll Surg* 1995;181(5):414–420
- 25 Azakie A, McElhinney DB, Thompson RW, Raven RB, Messina LM, Stoney RJ. Surgical management of subclavian-vein effort thrombosis as a result of thoracic outlet compression. *J Vasc Surg* 1998;28(5):777–786
- 26 Molina JE, Hunter DW, Dietz CA. Paget-Schroetter syndrome treated with thrombolytics and immediate surgery. *J Vasc Surg* 2007;45(2):328–334
- 27 Melby SJ, Thompson RW. Supraclavicular (paraclavicular) approach for thoracic outlet syndrome. In: Pearce WH, Matsumura JS, Yao JST, eds. *Operative Vascular Surgery in the Endovascular Era*. Evanston, IL: Greenwood Academic; 2008;434–445
- 28 Pin RH, DeLeon R, Freischlag JA. Axillary approach for thoracic outlet syndrome. In: Pearce WH, Matsumura JS, Yao JST, eds. *Vascular Surgery in the Endovascular Era*. Evanston, IL: Greenwood Academic; 2008;429–433
- 29 Urschel HC Jr, Razzuk MA. Paget-Schroetter syndrome: what is the best management? *Ann Thorac Surg* 2000;69(6):1663–1668; discussion 1668–1669
- 30 de León R, Chang DC, Busse C, Call D, Freischlag JA. First rib resection and scalenectomy for chronically occluded subclavian veins: what does it really do? *Ann Vasc Surg* 2008;22(3):395–401
- 31 Thompson RW, Petrinc D. Surgical treatment of thoracic outlet compression syndromes: diagnostic considerations and transaxillary first rib resection. *Ann Vasc Surg* 1997;11(3):315–323
- 32 Thompson RW, Petrinc D, Toursarkissian B. Surgical treatment of thoracic outlet compression syndromes. II. Supraclavicular exploration and vascular reconstruction. *Ann Vasc Surg* 1997;11(4):442–451