NIH Public Access
Author Manuscript
J Invest Dermatol. Author manuscript; available in PMC 2012 May 10.

Published in final edited form as:
J Invest Dermatol. 2010 March ; 130(3): 661–670. doi:10.1038/jid.2009.411.

Pseudoxanthoma Elasticum – Molecular Genetics and Putative Pathomechanisms

Jouni Uitto, **Qiaoli Li**, and **Qiujie Jiang**
Department of Dermatology and Cutaneous Biology, Jefferson Medical College and Jefferson Institute of Molecular Medicine, Thomas Jefferson University, Philadelphia, PA, USA

Abstract

Pseudoxanthoma elasticum (PXE), a prototypic heritable disorder with ectopic mineralization, manifests with characteristic skin findings, ocular involvement and cardiovascular problems, with considerable morbidity and mortality. The classic forms of PXE are due to loss-of-function mutations in the *ABCC6* gene, which encodes ABCC6, a transmembrane efflux transporter expressed primarily in the liver. Several lines of evidence suggest that PXE is a primary metabolic disorder which, in the absence of ABCC6 transporter activity, displays reduced plasma anti-mineralization capacity due to reduced fetuin-A and matrix gla-protein (MGP) levels. MGP requires to be activated by γ-glutamyl carboxylation, a vitamin K-dependent reaction, to serve in anti-mineralization role in the peripheral connective tissue cells. While the molecules transported from the hepatocytes to circulation by ABCC6 *in vivo* remain unidentified, it has been hypothesized that a critical vitamin K derivative, such as reduced vitamin K conjugated with glutathione, is secreted to circulation physiologically, but not in the absence of ABCC6 transporter activity. As a result, activation of MGP by γ-glutamyl carboxylase is diminished, allowing slow, yet progressive, mineralization of connective tissues characteristic of PXE. Understanding of the pathomechanistic details of PXE provides a basis for development of targeted molecular therapies for this, currently intractable, disease.

Keywords

Heritable skin diseases; animal models; ectopic mineralization; ABC transporters; elastic structures

PXE – THE DIAGNOSTIC CHALLENGE

Pseudoxanthoma elasticum (PXE), a multi-system heritable disorder characterized by ectopic mineralization of soft connective tissues, can pose a diagnostic challenge to practitioners, for several reasons (Neldner, 1988). From the historical perspective, the original descriptions of cutaneous manifestations in PXE, in association with elastic degeneration of the skin and heart, were given by French dermatologists under the general diagnosis of “xanthelasma” (Balzer, 1884; Chauffard, 1889). Subsequently, after extensive re-examination of the previously published cases, Darier, in 1896, proposed the name “pseudo-xanthome elastiqué” to differentiate this condition from xanthomas, hence “pseudoxanthoma” (Darier, 1896). In the late 1920's, Grönblad and Strandberg, an ophthalmologist and a dermatologist, both from Sweden, recognized the association of the

Correspondence: Jouni Uitto, MD, PhD Department of Dermatology and Cutaneous Biology Jefferson Medical College 233 S. 10th Street, Suite 450 BLSB Philadelphia, PA 19107 USA Tel: 215-503-5785 Jouni.uitto@jefferson.edu.

CONFLICT OF INTEREST
The authors have no conflict of interest.

NIH-PA Author Manuscript
NIH-PA Author Manuscript
NIH-PA Author Manuscript

NIH-PA Author Manuscript

NIH-PA Author Manuscript

NIH-PA Author Manuscript

characteristic skin manifestation with angioid streaks, thus establishing the eponym Grönblad-Strandberg Syndrome (Grönblad, 1929; Strandberg, 1929). The cardiovascular manifestations of PXE were not fully appreciated until some two decades later (Carlborg, 1944). More recently, identification of the gene defects underlying PXE has helped to clarify the clinical constellations and molecular genetics of this disorder (Chassaing *et* al., 2005; Miksch *et* al., 2005; Li *et al.*, 2009a).

PXE is an autosomal recessive disorder, but its precise prevalence is currently unknown. The estimates vary widely, but those in the range of 1 in 50,000 to 1 in 70,000 may be representative of the actual incidence. PXE is encountered in all ancestral backgrounds without racial predilection. In some areas (such as South Africa) the prevalence may be higher due to consanguinity and/or the presence of a founder effect (Le Saux *et al.*, 2002; Ramsey *et al.*, 2009). There appears to be a slight female preponderance, but the reasons for this phenomenon in an autosomal recessive disease with apparently full penetrance are not clear. Furthermore, adding to the diagnostic difficulty is that the clinical findings of PXE are rarely present at birth and the skin findings usually become recognizable not until during the second or third decade of life (Neldner, 1988; Pfendner *et al.*, 2007; Li *et al.*, 2009a; Naorui *et al.*, 2009). In many cases, the accurate diagnosis is not made until serious ocular or vascular complications develop in the third or fourth decade of life.

PHENOTYPIC SPECTRUM OF PXE

PXE is characterized by dystrophic mineralization of soft connective tissues in a number of organs, but the primary clinical manifestations in classic PXE center on three major organ systems, *viz.*, the skin, the eyes, and the cardiovascular system (Neldner, 1988).

Skin Manifestations

The primary cutaneous lesions are small, discrete yellowish papules that appear initially in the flexural areas, including lateral neck, antecubital and popiliteal fossae. These primary lesions progressively coalesce into larger plaques of inelastic and leathery skin which progressively extends to involve non-flexural sites as well. In the most extensive cases, essentially all skin can be involved with loss of elasticity and recoil. Mucosal membranes, particularly the inner lower lip, can become involved in a similar manner with yellow papules. The cutaneous findings present primarily a cosmetic problem and do not interfere with normal life activities. However, the presence of characteristic skin lesions signifies the risk for development of ocular and vascular complications that can be quite debilitating with considerable morbidity and even mortality.

Eye Findings

The characteristic ophthalmologic finding in the majority of patients with PXE is angioid streaks, and after the age of 30 their prevalence approaches 100 percent (Neldner, 1988). While angioid streaks may be detected in some cases as early as in the first decade of life, they frequently become symptomatic later in life, particularly after trauma to the eye. Angioid streaks derive from breaks upon aberrant mineralization of the elastic lamina of Bruch's membrane which separates the pigmented layer of the retina from the choroid of the eye. These fractures can lead to neovascularization from choriocapillaries, and subsequent leakage of newly formed vessels leads to hemorrhage and scarring (Georgalas *et al.*, 2009). Ultimately, these pathologic changes cause progressive loss of visual acuity and, relatively rarely, in central blindness. It should be noted, however, that angioid streaks, although characteristic for PXE, are not pathognomonic (Neldner, 1988). They can be encountered in a variety of metabolic and heritable disorders as well as in the setting of age-associated degenerative changes of the Bruch's membrane (Georgalas *et al.*, 2009).

NIH-PA Author Manuscript

NIH-PA Author Manuscript

NIH-PA Author Manuscript

Cardiovascular Involvement

PXE affects the cardiovascular system primarily by mineralization of mid-sized arteries of the extremities where progressive calcification of the elastic media and intima inflicts the vessel damage (Mendelsohn *et al.*, 1978; Kornet *et al.*, 2004). As a result of these changes, clinical manifestations, including intermittent claudication, loss of peripheral pulses, reno-vascular hypertension, angina pectoris, and rarely, myocardial infarction, can result. There is an increased risk for cerebral ischemic attacks, and mineralized blood vessels of the gastric and intestinal mucosa can rupture leading to gastrointestinal bleeding (Goral *et al.*, 2007). The vascular symptoms can cause significant morbidity and may even result in premature demise of the affected individual. Risk for cardiovascular complications is somewhat increased during pregnancy and labor. It should be noted, however, that in spite of extensive mineralization of placenta, PXE is not associated with markedly increased fetal loss or adverse obstetrical outcomes (Bercovitch *et al.*, 2004; Tan and Rodeck, 2008). Thus, with appropriate counseling, there is no basis for advising women with PXE to avoid becoming pregnant.

While in most severe cases PXE is associated with considerable morbidity and occasional mortality from cardiovascular complications, the phenotypic spectrum of this disease is highly variable, with both inter- and intra-familial heterogeneity (Neldner, 1988; Sakata *et al.*, 2007; Li *et al.*, 2009a). In some families, involvement of a given organ system may be predominant, so that in some families the major findings are in the skin, while in other families the ocular findings predominate with little skin involvement. In other families, cardiovascular symptoms may be the major cause of morbidity, with relatively little skin or eye involvement.

The Mode of Inheritance

Adding to the complexity and diagnostic challenge of PXE were early suggestions that both autosomal dominant and autosomal recessive forms of the disease exist (Pope, 1975). Recent advances of molecular genetics have established that PXE is exclusively an autosomal recessive disorder (Plomp *et al.*, 2004; Ringpfeil *et al.*, 2006). The early suggestions of the presence of autosomal dominant forms were based on clinical findings, mostly cutaneous, in individuals in two subsequent generations in some families, but this can in most cases be explained on basis of pseudo-dominance, often as a result of familial consanguinity (Ringpfeil *et al.*, 2000, 2006; Chassaing *et al.*, 2004). It should be noted that there are no fully documented reports of PXE in three subsequent generations, refuting the existence of classic Mendelian autosomal dominant inheritance. Obligate heterozygote carriers have essentially normal or very limited clinical phenotype but some cases have been reported to show microscopic changes of mineralization in the elastic fibers (Martin *et al.*, 2007). A recent study has suggested that heterozygous carriers may occasionally have serious manifestations, particularly affecting the eyes (Martin *et al.*, 2008). The carrier individuals may also be at increased risk for premature coronary artery disease (Trip *et al.*, 2002). These observations may suggest a role for modifying genes or environmental factors in the mineralization processes.

MOLECULAR GENETICS OF PXE

Because the primary histopathology of the skin in PXE was noted to involve elastic fibers, the genes participating in the synthesis and assembly of the elastic fiber network were initially considered as a candidate gene/protein systems for mutations in this disease. These included elastin (*ELN*) on chromosome 7q, the elastin-associated microfibrillar proteins, such as fibrillin-1 and fibrillin-2 (*FBN1* and *FBN2*) on chromosomes 15 and 5, and lysyloxidase (*LOX*), also on chromosome 15. However, with the cloning of the

NIH-PA Author Manuscript

NIH-PA Author Manuscript

NIH-PA Author Manuscript

corresponding genes, genetic linkage analyses excluded these chromosomal regions as the sites of PXE associated genes (Christiano *et al.*, 1992; Raybould *et al.*, 1994). Subsequently, the positional cloning approaches provided strong evidence for linkage to the short-arm of chromosome 16, and refinement of the critical interval focused on an ~500 kb region that contained four genes, none of which had an obvious connection to the extracellular matrix of connective tissues in general or to the elastic fiber network in particular (Le Saux *et al.*, 1999; Cai *et al.*, 2000). Systematic sequencing of these candidate genes resulted in identification of the *ABCC6* gene as the one harboring mutations in PXE (Ringpfeil *et al.*, 2000; Le Saux *et al.*, 2000; Bergen *et al.*, 2000; Struk *et al.*, 2000). This gene consists of 31 exons spanning approximately 75 kb of the human genome on chromosomal region 16p13.1 This region also contains two closely related, yet non-functional, 5'-pseudogenes which correspond to exons 1-9 and 1-4 of the coding gene, respectively (Pulkkinen *et al.*, 2001). A close sequence similarity (over 99%) between the two pseudogenes and the coding gene complicates mutation detection at the 5'-end of the gene, although allele-specific primer sets have been designed for each exon of the coding gene, thus facilitating analysis without interference from the pseudogene sequences (Pfendner *et al.*, 2007).

The ABCC6 Gene/Protein System

The *ABCC6* gene is transcribed into an approximately 5 kb mRNA, and translated into a 165 kDa protein of 1,503 amino acids. This protein, ABCC6 (also known as multi-drug resistance associated protein 6 – MRP6) is a member of the C-family of ATP-binding cassette (ABC) proteins (Borst and Elferink, 2002). ABCC6 has three hydrophobic transmembrane domains (TMD) consisting of 5, 6 and 6 transmembrane helices, as well as two intracellular nucleotide binding folds (NBFs) with highly conserved Walker motifs and ABC signature that are critical for the function of the protein in ATP-driven transmembrane transporters (Szakács *et al.*, 2008). On the basis of sequence homology with other members of the C-family of the ABC proteins, particularly the prototype ABCC1, the ABCC6 has been postulated to function as an efflux transporter, and it has been shown to transport polyanionic, glutathione-conjugated molecules in an *in vitro* inside-out vesicle system (Iliás *et al.*, 2002; Belinsky *et al.*, 2002). The precise role of ABCC6 and the substrate specificity of this putative transporter *in vivo* are currently unknown. Nevertheless, the critical role of the *ABCC6* gene in the pathogenesis of PXE has been confirmed by development of transgenic mice through targeted ablation of the corresponding mouse gene (Klement *et al.*, 2005; Gorgels *et al.*, 2005). The *Abcc6*$^{-/-}$ mice recapitulate the genetic, histopathologic and ultrastructural findings in patients with PXE, including progressive mineralization of connective tissues (Klement *et al.*, 2005; Jiang *et al.*, 2007). Moreover, an alternative splice variant in Abcc6, leading to a 5-bp deletion, has been identified in dystrophic cardiac calcification (DCC) susceptible mouse strain C3H/HR, DBA/2Y and 1295S_1/SVJ but not in DCC-resistant mouse C57BL/b, attesting to the role of the Abcc6 gene in mineralization processes (Aherrahrou *et al.*, 2008).

ABCC6 Mutations in PXE

Well over 300 distinct mutations representing over 1000 mutant alleles have been encountered in the *ABCC6* gene in patients with PXE (Miksch *et al.*, 2005; Pfendner *et al.*, 2007, 2008; Li *et al.*, 2009a). The types of mutations include missense and nonsense mutations in 28 of the 31 exons of *ABCC6*, intronic mutations causing mis-splicing, small deletions or insertions resulting in frame shift of translation, as well as large deletions spanning part or the entire coding region of the gene and sometimes including flanking genes as well (Chassaing *et al.*, 2007). Two recurrent mutations of high frequency have been identified: p.R1141X in exon 24 is the most common, particularly in Caucasian individuals, with a prevalence of approximately 30% of all pathologic PXE mutations (Pfendner *et al.*, 2007). In addition, a recurrent *Alu*I-mediated deletion of exons 23-29 (del23-29; p.A999-

NIH-PA Author Manuscript

NIH-PA Author Manuscript

NIH-PA Author Manuscript

S1403del) has been found at least in one allele in up to 20% in US and 12% of European patients (Ringpfeil *et al.*, 2001; Chassaing *et al.*, 2004; Pfendner *et al.*, 2007). Identification of additional recurrent nonsense mutations, as well as clustering of the missense mutations to exons 24 and 28 which code for the NBFs and on the domain-domain interfaces, have allowed the development of streamlined mutation detection strategies, with the overall detection rate of up to 99% (Hu *et al.*, 2004; Pfendner *et al.*, 2007; Fülöp *et al.*, 2009). Thus, mutation analysis is now readily available for individuals suspected to have or to be at risk for PXE. As in the case of other heritable disorders with extensive mutation database, identification of mutations in the *ABCC6* gene can be used for confirmation of the clinical diagnosis, carrier detection and presymptomatic identification of affected individuals. Although no specific treatment is presently available for PXE, early identification of the disease and increased surveillance for its sequela will undoubtedly improve the quality of life of the affected individuals.

PUTATIVE PATHOMECHANISMS OF PXE

Histopathologic evaluation of skin and other affected tissues in PXE reveals progressive mineralization of connective tissues, particularly elastic structures, as the characteristic feature, and accumulation of calcium/phosphate in these lesions is apparently responsible for clinical manifestations in the skin, the eyes, and the cardiovascular system. As indicated above, the classic forms of PXE are caused by mutations in the *ABCC6* gene, a putative efflux transporter. One of the early surprising observations was that this gene is primarily expressed in the liver, to a lesser extent in the proximal tubules of kidneys, and at very low level, if at all, in tissues clinically affected in PXE (Belinsky and Kruh, 1999; Scheffer *et al.*, 2002). These observations raised an apparent dilemma concerning the pathomechanisms of PXE. Specifically, how do mutations in the gene expressed primarily in the liver result in mineralization of connective tissues in the skin, the eyes, and the blood vessels? To explain the potential mechanisms leading from *ABCC6* mutations to ectopic mineralization in peripheral connective tissues in PXE, at least two general theories have been advanced. The "*metabolic hypothesis*" (Uitto *et al.*, 2001) postulates that absence of ABCC6 activity primarily in the liver results in deficiency of circulating factors that are physiologically required to prevent aberrant mineralization under normal calcium and phosphate homeostatic conditions (Figure 1) (Li *et al.*, 2009a). This postulate is predicated on previous identification of a number of proteins which serve as powerful anti-mineralization molecules in the circulation, including fetuin-A, matrix gla-protein (MGP), and ankylosis protein (ANK) (Jahnen-Dechent *et al.*, 1997; Luo *et al.*, 1997; Ryan *et al.*, 2001). The "*PXE cell hypothesis*" postulates that lack of *ABCC6* expression in the resident cells in clinically affected tissues, such as in skin fibroblasts or arterial smooth muscle cells, alters the biosynthetic expression profile and cell-cell and cell-matrix interactions, associated with changes in the proliferative capacity of these cells. Specifically, cultured skin fibroblasts from patients with PXE have been shown to display enhanced synthesis of elastin and glycosaminoglycan/proteoglycan complexes, and they also demonstrate enhanced degradative potential because of elevated matrix metalloproteinase-2 activity (Passi *et al.*, 1996; Quaglino *et al.*, 2000, 2005). Finally, in support of this postulate are observations that the elastic structures in the skin that become mineralized in PXE do not appear morphologically normal, and they have been suggested to contain elastin which differs from elastin isolated from normal skin (Lebwohl *et al.*, 1993; Sakuraoka *et al.*, 1994).

In support of the "metabolic hypothesis," it has been pointed out that clinical manifestations in patients with PXE are rarely present in early childhood, the onset of clinical findings is delayed, and the progression of the disease is slow, as reflected by accumulation of calcium/phosphate deposits in soft connective tissues of the affected organs. Serum from *Abcc6*$^{-/-}$ mice has been shown to lack the capacity to prevent calcium/phosphate precipitation in a

NIH-PA Author Manuscript

NIH-PA Author Manuscript

NIH-PA Author Manuscript

cell-based *in vitro* assay (Jiang *et al.*, 2007). Furthermore, serum from patients with PXE, when added to tissue culture medium of fibroblasts, has been shown to alter the expression of elastin, again suggesting the presence or absence of specific circulatory factors (Le Saux *et al.*, 2006).

Grafting and Parabiotic Mouse Models

We have recently addressed the "metabolic hypothesis" by taking advantage of the *Abcc6*$^{-/-}$ mouse model that recapitulates features of human PXE, including late-onset (5-6 weeks after the birth), yet progressive, mineralization of connective tissues (Klement *et al.*, 2005). In the first set of studies we performed skin grafting in which muzzle skin from *Abcc6*$^{-/-}$ (KO) mice or from their wild-type (WT) littermates, was grafted onto the back of *Abcc6*$^{+/+}$ and *Abcc6*$^{-/-}$ mice (Jiang *et al.*, 2009). The muzzle skin of mice contains vibrissae, and the connective tissue capsule surrounding the bulb of the vibrissae becomes reproducibly mineralized in *Abcc6*$^{-/-}$ mice at approximately 5 weeks, serving as an early and quantifiable biomarker of the mineralization process (Jiang *et al.*, 2007). When muzzle skin from WT mice was grafted onto the back of KO mice at 4 weeks of age, mineralization ensued in subsequent two months. In contrast, no mineralization was observed in the muzzle skin from KO mice transplanted onto the back of WT mice. Since the capillaries in the graft regress while new vascular ingrowth occurs from the recipient wound bed to replace the regressing vessels, the survival of the skin graft is dependent on the re-establishment of circulation from the recipient animal, and the graft supplied by blood from the recipient mouse (Capla *et al.*, 2006). As the *Abcc6*$^{-/-}$ mouse skin graft did not develop mineralization when placed on to *Abcc6*$^{+/+}$ mouse, but the skin from WT mouse showed mineralization after grafting on to KO mouse, these findings suggest that circulating factors in the recipient's blood play an active role in the degree of mineralization of the graft, irrespective of the graft genotype (Jiang *et al.*, 2009).

In another set of experiments, we have utilized parabiotic pairing, *i.e.*, surgical joining of two mice to create a shared circulation between various *Abcc6* genotypic mice (Jiang *et al.*, 2010a). To prevent immune reaction between the parabiotic animals, all mice were bred to be *Rag1*$^{-/-}$, *i.e.*, these mice lacked mature T- and B-cells while granulocytes and macrophages were intact, resulting in "non-leaky" severe combined immune deficiency. Parabiotic pairing of mice was performed at 4 weeks of age, at the time of weaning and just before histologically detectable mineralization in the vibrissae of the *Abcc6*$^{-/-}$ mice takes place. Subsequent histopathological observations of the mineralization process at 8 weeks confirmed that KO mice, when paired with WT mice, developed much less mineralization than KO mice in KO+KO pairs. At the same time, WT or heterozygous mice either in homogenetic pairings or in heterogenetic pairing with KO mice developed no evidence of mineralization up to three months of age (Jiang *et al.*, 2010a). Collectively, these experiments, combined with *in vitro* measurements of the anti-mineralization capacity of serum in KO mice, suggest that *Abcc6*$^{-/-}$ mice lack circulatory factors that in WT mice prevent precipitation of calcium/phosphate under normal homeostatic conditions.

PXE-LIKE CUTANEOUS FINDINGS AND VITAMIN K-DEPENDENT COAGULATION FACTOR DEFICIENCY

Adding to the diagnostic difficulties related to PXE, skin manifestations reminiscent of PXE can be found in a number of unrelated clinical conditions, both acquired and genetic (Neldner, 1988; Li *et al.*, 2009a). For example, PXE-like cutaneous changes, even with ocular findings, can be found in a number of patients with beta-thalassemia and sickle cell anemia, yet these individuals do not harbor mutations in the *ABCC6* gene (Baccarani-Conti *et al.*, 2001; Hamlin *et al.*, 2003). Recently, particularly intriguing observations with

NIH-PA Author Manuscript

NIH-PA Author Manuscript

NIH-PA Author Manuscript

potential pathomechanistic implications for PXE have been made in patients with PXE-like cutaneous findings in association with vitamin K-dependent multiple coagulation factor deficiency (Vanakker *et al.*, 2007; Li *et al.*, 2009b,c). These patients demonstrate primary cutaneous lesions similar to those seen in PXE, *i.e.*, small, yellowish papules and excessive folding and sagging of the skin with loss of recoil. These patients have been described as having combined clinical features of both PXE and cutis laxa (Vanakker *et al.*, 2007). However, cutaneous lesions in these patients depict characteristic mineralization of elastic structures similar to PXE, findings that are not present in patients with cutis laxa (Uitto and Ringpfeil, 2007).

Mutations in the *GGCX* Gene

Molecular analysis of some of the patients with PXE-like cutaneous and bleeding disorder has revealed mutations in the *GGCX* gene which encodes an enzyme responsible for γ -glutamyl-carboxylation of proteins, such as the vitamin K-dependent coagulation factors and matrix gla-protein (Figure 2) (Berkner, 2005). Some of these patients demonstrate inactivating missense mutations in both alleles of *GGCX*, and clinically they demonstrate both the PXE-like cutaneous findings and the bleeding tendency (Vanakker *et al.*, 2007; Li *et al.*, 2009c). In some cases, the *GGCX* mutations are heterozygous in combination with a heterozygous *ABCC6* mutation (Li *et al.*, 2009b). In a particularly illustrative family, individuals were shown to be heterozygous for a nonsense mutation (p.R1141X) in *ABCC6* and a missense mutation (p.V255M) in *GGCX*. These patients have cutaneous findings consistent with PXE but without any coagulation disorder, suggesting digenic inheritance of PXE in this family (Li *et al.*, 2009b).

The identification of missense mutations in *GGCX*, accompanied with PXE-like cutaneous changes and histopathologically demonstrable mineralization of elastic structures in the dermis, potentially provides insights into the pathomechanisms of classic PXE. One postulate revolves around vitamin K-dependent γ-glutamyl-carboxylation of matrix gla-protein (Shearer, 2000). This low-molecular weight protein has the capacity to prevent untowards mineralization under normal homeostatic levels of calcium and phosphorus, as demonstrated by development of the corresponding KO mouse, $Mgp^{-/-}$, characterized by extensive mineralization of connective tissues (Luo *et al.*, 1997). However, in order to be active in its anti-mineralization function, this protein has to be in a fully carboxylated form (cMGP), while under-carboxylated form of the protein (ucMGP) is inactive (Figure 2). Examination of cutaneous lesions in patients with PXE and in $Abcc6^{-/-}$ mice with specific antibodies that distinguish these two different forms of MGP has suggested that MGP is undercarboxylated in these clinical situations (Gheduzzi *et al.*, 2007; Li *et al.*, 2007). A potential explanation for under-carboxylation of MGP in classic PXE revolves around the possibility that the ABCC6 protein participates in transmembrane transport and redistribution of vitamin K derivatives, specifically its reduced form (KH_2), an obligatory co-factor of γ-glutamyl-carboxylase (Borst *et al.*, 2008; Li *et al.*, 2009a). More precisely, one could postulate that KH_2, especially when conjugated with glutathione which renders it soluble in aqueous environment, could serve as a transport substrate for ABCC6. In patients with PXE, the absence of ABCC6 transporter activity could result in reduced concentration of KH_2 in circulation and in peripheral cells, such as dermal fibroblasts, leading to deficient γ-carboxylation of MGP and allowing subsequent mineralization of the adjacent connective tissues (Figure 2). Because the concentrations of KH_2 inside the hepatocytes remain unaffected, the γ-carboxylation of vitamin K-dependent coagulation factors remains unperturbed and no bleeding tendency accompanies PXE due to mutations in *ABCC6*. It should be noted that if this postulate is proven correct, it would raise the possibility that administration of the critical form of vitamin K or its derivatives directly into circulation,

NIH-PA Author Manuscript

NIH-PA Author Manuscript

NIH-PA Author Manuscript

bypassing the liver, might counteract the progressive mineralization of connective tissues in PXE and might ameliorate, or even cure, this disease.

GENETIC AND ENVIRONMENTAL MODIFYING FACTORS

As indicated above, the classic forms of PXE are caused by mutations in the *ABCC6* gene, and well over 300 distinct mutations have been disclosed in different families. Careful examination of the mutation database in the context of clinical manifestations and phenotypic variability in different families has not provided clear-cut genotype/phenotype correlations (Pfendner *et al.*, 2007, 2008), and therefore, the reasons for the considerable phenotypic variability, both intra- and inter-familial, are not clear.

Genetic Modifiers

Recent studies examining the effects of different genetic backgrounds on the mineralization process in *Abcc6*$^{-/-}$ mouse model have shown that, besides the specific modulation by haploinsufficiency of the *Ggcx* gene, the general genetic background can delay the onset of the mineralization (Li and Uitto, 2010a). It is conceivable, therefore, that modifier genes may also exist in humans and that they modulate both the age of onset and the extent of mineralization in patients with PXE, providing partial explanation for the phenotypic variability. In addition to *GGCX*, recent studies have suggested genetic modulation of PXE in humans by a few other genes as well. For example, single nucleotide polymorphisms (SNPs) in the promoter region of the *secreted phosphoprotein 1* gene (*SPP1*, also known as osteopontin) were shown to be associated with PXE, contributing to the susceptibility to this disease (Hendig *et al.*, 2007). Osteopontin is a major local inhibitor of ectopic calcification that has been associated with Wnt signaling (Vattikuti and Towler, 2004). In other studies, polymorphisms of the xylosyltransferase genes were shown to be involved in the severity of the disease (Schön *et al.*, 2006). Specifically, variations in the XYLT were associated with higher internal organ involvement, while a specific missense variation (p.A115S) in the *XT-I* gene resulted in high serum xylosyltransferase activity, potentially reflecting increased remodeling of the extracellular matrix. Specific SNPs in the vascular endothelial growth factor gene (VEGFA) are associated with severe retinopathy (Zarbock *et al.*, 2009). Finally, genetic variations in the antioxidant genes are risk factors for early disease onset of PXE (Zarbock *et al.*, 2007). This observation is in concurrence with previous demonstrations that oxidative stress may play a role in the development of PXE (Li *et al.*, 2008; Pasquali-Ronchetti *et al.*, 2006).

The Role of Diet

In addition to genetic modifiers, several lines of evidence suggest that diet may affect the severity of the disease in PXE. First, early retrospective surveys suggested that individuals with history of extensive intake of dairy products, rich in calcium and phosphate, may demonstrate relatively severe disease later in life (Neldner *et al.*, 1988; Renie *et al.*, 1984). More recently, genetically controlled studies utilizing *Abcc6*$^{-/-}$ mice as a model system have demonstrated that the mineral content of their diet can clearly modulate the ectopic mineralization process (LaRusso *et al.*, 2008, 2009; Li *et al.*, 2010b). Specifically, magnesium carbonate, when added to the mouse diet in amounts that increase the magnesium concentration by 5-fold over that in standard diet, is able to prevent the ectopic mineralization noted in *Abcc6*$^{-/-}$ mice (Li *et al.*, 2010b). Conversely, an experimental diet with low magnesium was shown to accelerate the mineralization process in *Abcc6*$^{-/-}$ mice, as compared to the corresponding mice kept on a standard control diet (Li and Uitto, 2010a). These findings support the notion that changes in the diet can alter the age of onset and extent of mineralization in PXE. These observations also suggest that dietary magnesium might be helpful for treatment of patients with PXE, a notion that could be tested in

NIH-PA Author Manuscript

NIH-PA Author Manuscript

NIH-PA Author Manuscript

carefully controlled clinical trials. Collectively, the evidence indicating modulation of the PXE phenotype by genetic factors and diet support the notion that PXE is a metabolic disease at the genome-environment interface (Uitto *et al.*, 2001).

CLINICAL PERSPECTIVE – TOWARDS TREATMENT AND CURE

As summarized above, tremendous progress has been made in understanding the molecular genetics of PXE since report of the first pathogenic mutations in the *ABCC6* gene less than a decade ago (Ringpfeil *et al.*, 2000). The information on specific mutations has been helpful in confirming the diagnosis which is sometimes questionable on the basis of clinical findings only. This information has also been helpful in providing genetic counseling on the risk of recurrence in families with PXE, and the mutation analysis can be used for identification of affected individuals prior to development of overt clinical signs in families with previous history of this condition. Finally, development of animal models, and particularly the *Abcc6*$^{-/-}$ mice, that recapitulate the features of PXE, has been extremely helpful towards understanding the pathomechanistic details leading from mutations in the *ABCC6* gene to ectopic mineralization of peripheral connective tissues. In spite of this significant progress, however, the fact remains that there is no effective or specific treatment for PXE at the present.

Treatment of Ocular Neovascularization

Significant promise is offered by recent attempts to treat retinal manifestations of PXE. One of the most devastating complications of PXE is gradual loss of visual acuity which occasionally can lead to complete central blindness. These clinical symptoms are due to choroidal neovascularization secondary to the angiod streaks. Since vascular endothelial growth factor (VEGF) is a critical component of the neovascularization process in general, recent studies have tested the efficacy of intravitreal injection of pharmaceutical agents, such as bevacizumab (Avastin), an antagonist of VEGF and inhibitor of neovascularization. A number of preliminary reports have suggested that intravitreal bevacizumab may be a promising tool for the long-term control of choriod neovascularization in PXE (see Kovach *et al.*, 2009; Sawa *et al.*, 2009; Wiegand *et al.*, 2009). At the same time, other modalities and different strategies to treat retinal manifestations are being developed, including thermal laser coagulation, photodynamic therapy, and intravitreal injections of other drugs inhibiting VEGF (Finger *et al.*, 2009).

Development of Molecular Therapies

Different general approaches could be envisioned to be helpful towards finding a treatment, and perhaps cure, of PXE. For example, prevention of mineralization irrespective of its etiology could be helpful in lessening the clinical manifestations of PXE. It is apparent that the progressive mineralization of connective tissues, as for example, the mineralization of arterial blood vessels is responsible for the cardiovascular manifestations, and mineralization of the Bruch's membrane is the primary cause of the ocular findings. One potential way of preventing, and perhaps reversing, ectopic mineralization is the manipulation of diet. Specifically, experiments utilizing the *Abcc6*$^{-/-}$ animal model, have demonstrated that supplementation of the diet with magnesium is able to completely prevent the ectopic mineralization up to 6 months of age (LaRusso *et al.*, 2009; Li *et al.*, 2010b). Conversely, diet low in magnesium and high in phosphate, was shown to exacerbate the mineralization process in PXE mice (Li and Uitto, 2010a). Thus, further studies examining the precise role of different mineral components in the diet, using the preclinical animal models, might lead to clinical trials to test the feasibility of this approach towards treatment of PXE.

NIH-PA Author Manuscript

NIH-PA Author Manuscript

NIH-PA Author Manuscript

Another potentially effective way of preventing the ectopic mineralization revolves around the manipulation of anti-mineralization factors in the circulation. One of such molecules is fetuin-A, a powerful anti-mineralization factor that under normal physiologic calcium and phosphate homeostatic conditions is able to prevent aberrant mineralization. The concentrations of fetuin-A both in serum of patients with PXE as well as in the *Abcc6*$^{-/-}$ mouse have been shown to be reduced (Hendig *et al.*, 2006; Jiang *et al.*, 2007). The concept of fetuin-A serving as an anti-mineralization factor has been derived from observations that genetic KO mouse developed by targeted ablation of the fetuin-A gene demonstrates extensive mineralization of connective tissues, particularly of the arterial blood vessels (Jahnen-Dechent *et al.*, 1997). Furthermore, in an *in vitro* cell-based mineralization assay system, recombinant fetuin-A has been shown to prevent calcium/phosphate precipitation in a dose-dependent manner (Jiang *et al.*, 2007). These observations then raise the possibility that increasing the fetuin-A concentrations in the patients' blood may prevent excessive mineralization. This could be achieved by introduction of recombinant fetuin-A directly to the circulation of the patients with PXE. At this point, however, the half-life of fetuin-A is unknown, and other issues related to protein replacement therapy, such as antibody formation, need to be addressed in preclinical studies. Another potential approach to introduce fetuin-A to the circulation could utilize gene therapy or cell transfer approaches. For example, introduction of an expression vector containing a fetuin-A cDNA under liver specific promoter has been shown to increase the synthesis of fetuin-A with subsequent lessening of the mineralization in *Abcc6*$^{-/-}$ mice (Jiang *et al.*, 2010b). Again, details of such approaches need to be worked out in preclinical model systems prior to initiating clinical trials in patients with PXE.

Finally, strategies aimed at regeneration of liver or introduction of stem-cells with capability to differentiate into hepatocytes, could potentially result in restoration of functional ABCC6 transporter activity. In a straightforward manner, one would envision that liver transplant or a partial lobar replacement could result in restoration of the ABCC6 function. In the case of stem-cell therapy, it appears that a significant portion of the hepatocytes need to be replaced in order to achieve a functional ABCC6 transport system in the liver. Consideration of all these options has to include extensive preclinical animal studies, which are currently ongoing in several laboratories, as well as careful consideration of the risk/benefit ratios. Nevertheless, development of molecular strategies, as exemplified by progress in treatment of other heritable skin disease (Tamai *et al.*, 2009; Uitto, 2009), hopefully provides new avenues for treatment and eventually cure for PXE, a currently intractable disease.

Acknowledgments

The authors' original studies were supported by the United States Department of Health and Human Services, NIH/NIAMS Grants R01 AR28450, R01 AR52627, and R01 AR55225, and by the Dermatology Foundation. GianPaolo Guercio assisted in preparation of this publication.

Abbreviations

PXE	Pseudoxanthoma elasticum
KO	knock-out
WT	wild-type
MGP	matrix gla-protein

NIH-PA Author Manuscript

NIH-PA Author Manuscript

NIH-PA Author Manuscript

REFERENCES

Aherrahrou Z, Doegring LC, Ehlers E-M, Liptau H, Depping R, Linsel-Nitschke P, et al. An alternative splice variant in Abcc6, the gene causing dystrophic calcification, leads to protein deficiency in C3H/He Mice. J Biol Chem. 2008; 283:7608–7615. [PubMed: 18201967]

Baccarani-Contri M, Bacchelli B, Boraldi F, Quaglino D, Taparelli F, Carnevali E, et al. Characterization of pseudoxanthoma elasticum-like lesions in the skin of patients with beta-thalassemia. J Am Acad Dermatol. 2001; 44:33–39. [PubMed: 11148474]

Balzer F. Recherches sur les charactères anatomiques du xanthelasma. Arch Physiol. 1884; 4:65–80.

Belinsky MG, Kruh GD. MOAT-E (ARA) is a full length MRP/cMOAT subfamily transporter expressed in kidney and liver. Br J Cancer. 1999; 80:1342–1349. [PubMed: 10424734]

Belinsky MG, Chen ZS, Shchaveleva I, Zeng H, Kruh GD. Characterization of the drug resistance and transport properties of multi-drug resistance protein 6 (MRP6, *ABCC6*). Cancer Res. 2002; 62:6172–6177. [PubMed: 12414644]

Bercovitch L, Leroux T, Terry S, Weinstock MA. Pregnancy and obstetrical outcomes in pseudoxanthoma elasticum. Br J Dermatol. 2004; 151:1011–1018. [PubMed: 15541079]

Bergen AA, Plomp AS, Schuurman EJ, Terry S, Breuning M, Dauwerse H, et al. Mutations in *ABCC6* cause pseudoxanthoma elasticum. Nat Genet. 2000; 25:228–231. [PubMed: 10835643]

Berkner KL. The vitamin K-dependent carboxylase. Ann Rev Nutr. 2005; 25:127–149. [PubMed: 16011462]

Borst P, Elferink RO. Mammalian ABC transporters in health and disease. Annu Rev Biochem. 2002; 71:537–592. [PubMed: 12045106]

Borst P, van de Wetering K, Schlingemann R. Does the absence of ABCC6 (Multidrug Resistance Protein 6) in patients with pseudoxanthoma elasticum prevent the liver from providing sufficient vitamin K to the periphery? Cell Cycle. 2008; 7:1575–1579. [PubMed: 18469514]

Cai L, Struk B, Adams MD, Ji W, Haaf T, Kang HL, et al. A 500-kb region on chromosome 16p13.1 contains the pseudoxanthoma elasticum locus: high-resolution mapping and genomic structure. J Mol Med. 2000; 78:36–46. [PubMed: 10759028]

Capla JM, Ceradini DJ, Tepper OM, Callaghan MJ, Bhatt KA, Galiano RD, et al. Skin graft vascularization involves precisely regulated regression and replacement of endothelial cells through both angiogenesis and vasculogenesis. Plast Reconstr Surg. 2006; 117:836–844. [PubMed: 16525274]

Carlborg U. Study of circulatory disturbances, pulse wave velocity and pressure pulses in large arteries in cases of pseudoxanthoma elasticum and angioid streaks: a contribution to the knowledge of function of the elastic tissue and the smooth muscles in larger arteries. Acta Med Scand. 1944; 151:1–209.

Chassaing N, Martin L, Mazereeuw J, Barrié L, Nizard S, Bonafé JL, et al. Novel ABCC6 mutations in pseudoxanthoma elasticum. J Invest Dermatol. 2004; 122:608–613. [PubMed: 15086542]

Chassaing N, Martin L, Calvas P, Le Bert M, Hovnanian A. Pseudoxanthoma elasticum: a clinical, pathophysiological and genetic update including 11 novel ABCC6 mutations. J Med Genet. 2005; 42:881–892. [PubMed: 15894595]

Chassaing N, Martin L, Bourthoumieu S, Calvas P, Hovnanian A. Contribution of ABCC6 genomic rearrangements to the diagnosis of pseudoxanthoma elasticum in French patients. Hum. Mutat. 2007; 28:1046. [PubMed: 17823974]

Chauffard MA. Xanthelasma disséminé et symmétrique sans insufficiance hépatique. Bull Soc Med Hop Paris. 1889; 6:412–419.

Christiano AM, Lebwohl MG, Boyd CD, Uitto J. Workshop on pseudoxanthoma elasticum: molecular biology and pathology of the elastic fibers. Jefferson Medical College, Philadelphia, Pennsylvania. J Invest Dermatol. 1992; 99:660–663. [PubMed: 1431233]

Darier J. Pseudo-xanthome élastique. IIIe Congrès Intern de Dermat de Londres. 1896; 5:289–295.

Finger RP, Charbel Issa P, Ladewig MS, Götting C, Szliska C, Scholl HP, et al. Pseudoxanthoma elasticum: genetics, clinical manifestations and therapeutic approaches. Surv Ophthalmol. 2009; 54:272–285. [PubMed: 19298904]

NIH-PA Author Manuscript NIH-PA Author Manuscript NIH-PA Author Manuscript

Fülöp K, Barna L, Symmons O, Závodszky P, Váradi A. Clustering of disease-causing mutations on the domain-domain interfaces of ABCC6. Biochem Biophys Res Commun. 2009; 379:706–709. [PubMed: 19133228]

Georgalas I, Papaconstantinou D, Koutsandrea C, Kalantzis G, Karagiannis D, Georgopoulos G, et al. Angioid streaks, clinical course, complications, and current therapeutic management. Ther Clin Risk Manag. 2009; 5:81–89. [PubMed: 19436620]

Gheduzzi D, Boraldi F, Annovi G, DeVincenzi CP, Schurgers LJ, Vermeer C, et al. Matrix Gla protein is involved in elastic fiber calcification in the dermis of pseudoxanthoma elasticum patients. Lab Invest. 2007; 87:998–1008. [PubMed: 17724449]

Goral V, Demir D, Tuzun Y, Keklikci U, Buyulbayram H, Bayan K, et al. Pseudoxanthoma elasticum, as a repetitive upper gastrointestinal hemorrhage cause in a pregnant woman. World J Gastroenterol. 2007; 13:3897–3899. [PubMed: 17657851]

Gorgels TG, Hu X, Scheffer GL, van der Wal AC, Toonstra J, de Jong PT, et al. Disruption of *Abcc6* in the mouse: Novel insight in the pathogenesis of pseudoxanthoma elasticum. Hum Mol Genet. 2005; 14:1763–1773. [PubMed: 15888484]

Grönblad E. Angioid streaks – pseudoxanthoma elasticum. Acta Ophthalmol. 1929; 7:329.

Hamlin N, Beck K, Bacchelli B, Cianciulli P, Pasquali-Ronchetti I, Le Saux O. Acquired pseudoxanthoma elasticum-like syndrome in beta-thalassaemia patients. Br J Haematol. 2003; 122:852–854. [PubMed: 12930400]

Hendig D, Schulz V, Arndt M, Szaliska C, Kleesiek K, Götting C. Role of serum fetuin-A, a major inhibitor of systemic calcification, in pseudoxanthoma elasticum. Clin Chem. 2006; 52:227–234. [PubMed: 16384891]

Hendig D, Arndt M, Szliska C, Kleesiek K, Götting C. SPP1 promoter polymorphisms: identification of the first modifier gene for pseudoxanthoma elasticum. Clin Chem. 2007; 53:829–836. [PubMed: 17384004]

Hu X, Plomp A, Gorgels T, Brink JT, Loves W, Mannens M, et al. Efficient molecular diagnostic strategy for ABCC6 in pseudoxanthoma elasticum. Genet Test. 2004; 8:292–300. [PubMed: 15727254]

Iliás A, Urban Z, Seidl TL, Le Saux O, Sinkó E, Boyd CD, et al. Loss of ATP-dependent transport activity in pseudoxanthoma elasticum-associated mutants of human ABCC6 (MRP6). J Biol Chem. 2002; 277:16860–16867. [PubMed: 11880368]

Jahnen-Dechent W, Schinke T, Trindl A, Müller-Esterl W, Sablitzky F, Kaiser S, et al. Cloning and targeted deletion of the mouse fetuin gene. J Biol Chem. 1997; 272:31496–31503. [PubMed: 9395485]

Jiang Q, Li Q, Uitto J. Aberrant mineralization of connective tissues in a mouse model of pseudoxanthoma elasticum: systemic and local regulatory factors. J Invest Dermatol. 2007; 127:1392–4102. [PubMed: 17273159]

Jiang Q, Matsuzaki Y, Li K, Uitto J. Transcriptional regulation and characterization of the promoter region of the human *ABCC6* gene. J Invest Dermatol. 2006; 126:325–335. [PubMed: 16374464]

Jiang Q, Uitto J. Pseudoxanthoma elasticum: a metabolic disease? J Invest Dermatol. 2006; 126:1440–1441. [PubMed: 16778810]

Jiang Q, Endo M, Dibra F, Wang K, Uitto J. Pseudoxanthoma elasticum is a metabolic disease. J Invest Dermatol. 2009; 129:348–354. [PubMed: 18685618]

Jiang, Q.; Oldenburg, R.; Otsuru, S.; Grand-Pierre, AE.; Horwitz, EM.; Uitto, J. Parabiotic heterogenetic pairing of Abcc6-/-;Rag1-/- mice and their wild-type counterparts halts ectopic mineralization in a murine model of pseudoxanthoma elasticum.. 2010a. (submitted for publication)

Jiang Q, Dibra F, Li MD, Uitto J. Over-expression of fetuin-A counteracts ectopic mineralization in a mouse model of pseudoxanthoma elasticum ($Abcc6^{-/-}$). J Invest Dermatol. 2010b (in press).

Klement JF, Matsuzaki Y, Jiang Q-J, Terlizzi J, Choi HY, Fujimoto N, et al. Targeted ablation of the *ABCC6* gene results in ectopic mineralization of connective tissues. Mol Cell Biol. 2005; 25:8299–8310. [PubMed: 16135817]

Kornet L, Bergen AA, Hoeks AP, Cleutjens JP, Oostra RJ, Daemen MJ, et al. In patients with pseudoxanthoma elasticum a thicker and more elastic carotid artery is associated with elastin

NIH-PA Author Manuscript NIH-PA Author Manuscript NIH-PA Author Manuscript

fragmentation and proteoglycans accumulation. Ultrasound Med Biol. 2004; 30:1041–1048. [PubMed: 15474747]

Kovach JL, Schwartz SG, Hickey M, Puliafito CA. Thirty-two month follow-up of successful treatment of choroidal neovascularization from angioid streaks with intravitreal bevacizumab. Ophthalmic Surg Lasers Imaging. 2009; 40:77–79. [PubMed: 19205505]

LaRusso J, Jiang Q, Li Q, Uitto J. Ectopic mineralization of connective tissue in *Abcc6*$^{-/-}$ mice: Effects of dietary modifications and a phosphate binder – a preliminary study. Exp Dermatol. 2008; 17:203–207. [PubMed: 17979973]

LaRusso J, Li Q, Jiang Q, Uitto J. Elevated dietary magnesium prevents connective tissue mineralization in a mouse model of pseudoxanthoma elasticum (*Abcc6*$^{-/-}$). J Invest Dermatol. 2009; 129:1388–1394. [PubMed: 19122649]

Le Saux O, Urban Z, Göring HH, Csiszar K, Pope FM, Richards A, et al. Pseudoxanthoma elasticum maps to an 820-kb region of the p13.1 region of chromosome 16. Genomics. 1999; 62:1–10. [PubMed: 10585762]

Le Saux O, Urban Z, Tschuch C, Csiszar K, Bacchelli B, Quaglino D, et al. Mutations in a gene encoding an ABC transporter cause pseudoxanthoma elasticum. Nat Genet. 2000; 25:223–227. [PubMed: 10835642]

Le Saux O, Beck K, Sachsinger C, Treiber C, Göring HH, Curry K, et al. Evidence for a founder effect for pseudoxanthoma elasticum in the Afrikaner population of South Africa. Hum Genet. 2002; 111:331–338. [PubMed: 12384774]

Le Saux O, Bunda S, VanWart CM, Douet V, Got L, Martin L, et al. Serum factors from pseudoxanthoma elasticum patients alter elastic fiber formation in vitro. J Invest Dermatol. 2006; 126:1497–1505. [PubMed: 16543900]

Lebwohl M, Schwartz E, Lemlich G, Lovelace O, Shaikh-Bahai F, Fleischmajer R. Abnormalities of connective tissue components in lesional and non-lesional tissue of patients with pseudoxanthoma elasticum. Arch Dermatol Res. 1993; 285:121–126. [PubMed: 8503691]

Li Q, Jiang Q, Schurgers LJ, Uitto J. Pseudoxanthoma elasticum: Reduced gamma-glutamyl carboxylation of matrix gla protein in a mouse model (Abcc6-/-). Biochem Biophys Res Commun. 2007; 364:208–213. [PubMed: 17942075]

Li Q, Jiang Q, Uitto J. Pseudoxanthoma Elasticum: Oxidative Stress and Antioxidant Diet in a Mouse Model (Abcc6$^{-/-}$). J Invest Dermatol. 2008; 128:1160–1164. [PubMed: 18049453]

Li Q, Jiang Q, Pfendner E, Váradi A, Uitto J. Pseudoxanthoma elasticum: Clinical phenotypes, molecular genetics and putative pathomechanisms. Exp Derm. 2009a; 18:1–11. [PubMed: 19054062]

Li Q, Grange DK, Armstrong NL, Whelan AJ, Hurley MY, Rishavy MA. Mutations in the GGCX and ABCC6 genes in a family with pseudoxanthoma elasticum-like phenotypes. J Invest Dermatol. 2009b; 129:553–563. [PubMed: 18800149]

Li Q, Schrugers LJ, Smith ACM, Tsokos M, Uitto J, Cowen EW. Co-existent pseudoxanthoma elasticum and vitamin K-dependent coagulation factor deficiency. Am J Pathol. 2009c; 174:534–539. [PubMed: 19116367]

Li Q, Uitto J. The mineralization phenotype in Abcc6-/- mice is affected by Ggcx gene deficiency and genetic background – a model for pseudoxanthoma elasticum. J Mol Med. 2010a (in press).

Li, Q.; LaRusso, J.; Grand-Pierre, AE.; Uitto, J. Magnesium carbonate-containing phosphate binder prevents connective tissue mineralization in Abcc6-/- mice – potential for treatment of pseudoxanthoma elasticum.. 2010b. (submitted for publication)

Luo G, Ducy P, McKee MD, Pinero GJ, Loyer E, Behringer RR, et al. Spontaneous calcification of arteries and cartilage in mice lacking matrix GLA protein. Nature. 1997; 386:78–81. [PubMed: 9052783]

Martin L, Chassaing N, Delaite D, Esteve E, Maitre F, Le Bert M. Histological skin changes in heterozygote carriers of mutations in ABCC6, the gene causing pseudoxanthoma elasticum. J Eur Acad Dermatol Venereol. 2007; 21:368–373. [PubMed: 17309461]

Martin L, Maître F, Bonicel P, Daudon P, Verny C, Bonneau D, et al. Heterozygosity for a single mutation in the ABCC6 gene may closely mimic PXE: consequences of this phenotype overlap for the definition of PXE. Arch Dermatol. 2008; 144:301–306. [PubMed: 18347285]

NIH-PA Author Manuscript NIH-PA Author Manuscript NIH-PA Author Manuscript

Mendelsohn G, Bulkley BH, Hutchins GM. Cardiovascular manifestations of pseudoxanthoma elasticum. Arch Pathol Lab Med. 1978; 102:298–302. [PubMed: 580722]

Miksch S, Lunsden A, Guenther UP, Foernzler D, Christen-Zäch S, Daugherty C, et al. Molecular genetics of pseudoxanthoma elasticum: Type and frequency of mutations in *ABCC6*. Hum Mutat. 2005; 26:235–248. [PubMed: 16086317]

Naorui M, Boisseau C, Bonicel P, Daudon P, Bonneau D, Chassaing N, et al. Manifestations of pseudoxanthoma elasticum in childhood. Br J Dermatol. 2009; 161:635–639. [PubMed: 19519828]

Neldner KH. Pseudoxanthoma elasticum. Clin Dermatol. 1988; 6:1–159. [PubMed: 3359381]

Pasquali-Ronchetti I, Garcia-Fernandez MI, Boraldi F, Quaglino D, Gheduzzi D, De Vincenzi Paolinelli C, et al. Oxidative stress in fibroblasts from patients with pseudoxanthoma elasticum: possible role in the pathogenesis of clinical manifestations. J Pathol. 2006; 208:54–61. [PubMed: 16261549]

Passi A, Albertini R, Baccarani Contri M, de Luca G, de Paepe A, Pallavicini G, et al. Proteoglycan alterations in skin fibroblast cultures from patients affected with pseudoxanthoma elasticum. Cell Biochem Funct. 1996; 14:111–120. [PubMed: 8640951]

Pfendner EG, Vanakker OM, Terry SF, Vourthis S, McAndrew PE, McClain MR, et al. Mutation detection in the *ABCC6* gene and genotype-phenotype analysis in a large international case series affected by pseudoxanthoma elasticum. J Med Genet. 2007; 44:621–628. [PubMed: 17617515]

Pfendner E, Uitto J, Gerard GF, Terry SF. Pseudoxanthoma elasticum: Genetic diagnostic markers. Exp Opinion Med Diagn. 2008; 2:1–17.

Plomp AS, Hu X, De Jong PT, Bergen AA. Does autosomal dominant pseudoxanthoma elasticum exist? Am J Med Genet. 2004; 126:403–412. [PubMed: 15098239]

Pope FM. Historical evidence for the genetic heterogeneity of pseudoxanthoma elasticum. Br J Dermatol. 1975; 92:493–509. [PubMed: 1100089]

Pulkkinen L, Nakano A, Ringpfeil F, Uitto J. Identification of ABCC6 pseudogenes on human chromosome 16p: implications for mutation detection in pseudoxanthoma elasticum. Hum Genet. 2001; 109:356–365. [PubMed: 11702217]

Quaglino D, Boraldi F, Barbieri D, Croce A, Tiozzo R, Pasquali-Ronchetti I. Abnormal phenotype of in vitro dermal fibroblasts from patients with pseudoxanthoma elasticum (PXE). Biochim Biophys Acta. 2000; 1501:51–62. [PubMed: 10727849]

Quaglino D, Sartor L, Garbisa S, Boraldi F, Croce A, Passi A, et al. Dermal fibroblasts from pseudoxanthoma elasticum patients have raised MMP-2 degradative potential. Biochim Biophys Acta. 2005; 1741:42–47. [PubMed: 15955448]

Ramsay M, Greenberg T, Lombard Z, Labrum R, Lubbe S, Aron S, et al. Spectrum of genetic variation at the ABCC6 locus in South Africans: pseudoxanthoma elasticum patients and healthy individuals. J Dermatol Sci. 2009; 54:198–204. [PubMed: 19339160]

Raybould MC, Birley AJ, Moss C, Hultén M, McKeown CM. Exclusion of an elastin gene (ELN) mutation as the cause of pseudoxanthoma elasticum (PXE) in one family. Clin Genet. 1994; 45:48–51. [PubMed: 8149653]

Renie WA, Pyeritz RE, Combs J, Fine SL. Pseudoxanthoma elasticum: High calcium intake in early life correlates with severity. Am J Med Genet. 1984; 19:235–244. [PubMed: 6507474]

Ringpfeil F, Lebwohl MG, Christiano AM, Uitto J. Pseudoxanthoma elasticum: mutations in the MRP6 gene encoding a transmembrane ATP-binding cassette (ABC) transporter. Proc Natl Acad Sci USA. 2000; 97:6001–6006. [PubMed: 10811882]

Ringpfeil F, Nakano A, Uitto J, Pulkkinen L. Compound heterozygosity for a recurrent 16.5-kb Alu-mediated deletion mutation and single-base-pair substitutions in the ABCC6 gene results in pseudoxanthoma elasticum. Am J Hum Genet. 2001; 68:642–652. [PubMed: 11179012]

Ringpfeil F, McGuigan K, Fuchsel L, Kozic H, Larralde M, Lebwohl M, et al. Pseudoxanthoma elasticum is a recessive disease characterized by compound heterozygosity. J Invest Dermatol. 2006; 126:782–786. [PubMed: 16410789]

Ryan LM. The ank gene story. Arthitis Res. 2001; 3:77–79.

Sakata S, Su JC, Robertson S, Win M, Chow C. Varied presentations of pseudoxanthoma elasticum in a family. J Pediatr Child Health. 2006; 42:817–820.

NIH-PA Author Manuscript NIH-PA Author Manuscript NIH-PA Author Manuscript

Sakuraoka K, Tajima S, Nishikawa T, Seyama Y. Biochemical analyses of macromolecular matrix components in patients with pseudoxanthoma elasticum. J Dermatol. 1994; 21:98–101. [PubMed: 8182219]

Sawa M, Gomi F, Tsujikawa M, Sakaguchi H, Tano Y. Long-term results of intravitreal bevacizumab injection for choroidal neovascularization secondary to angioig streaks. Am J Ophthalmol. 2009 (in press: PMID: 19541288).

Scheffer GL, Hu X, Pijnenborg AC, Wijnholds J, Bergen AA, Scheper RJ. MRP6 (*ABCC6*) detection in normal human tissues and tumors. Lab Invest. 2002; 82:515–518. [PubMed: 11950908]

Schön S, Schulz V, Prante C, Hendig D, Szliska C, Kuhn J. Polymorphisms in the xylosyltransferase genes cause higher serum XT-I activity in patients with pseudoxanthoma elasticum (PXE) and are involved in a severe disease course. J Med Genet. 2006; 43:745–749. [PubMed: 16571645]

Shearer MJ. Role of vitamin K and Gla proteins in the pathophysiology of osteoporosis and vascular calcification. Curr Opin Clin Nutr Metab Care. 2000; 3:433–438. [PubMed: 11085828]

Strandberg J. Pseudoxanthoma elasticum. Z Haut Geschlechtskr. 1929; 31:689–694.

Struk B, Cai L, Zäch S, Ji W, Chung L, Lumsden A, et al. Mutations of the gene encoding the transmembrane transporter protein ABCC6 cause pseudoxanthoma elasticum. J Mol Med. 2000; 78:282–286. [PubMed: 10954200]

Szakács G, Váradi A, Ozvegy-Lacka C, Sarkadi B. The role of ABC transporters in drug absorption, distribution, metabolism, excretion and toxicity (ASME-Tox). Drug Discov Today. 2008; 13:379–393. [PubMed: 18468555]

Tamai K, Kaneda Y, Uitto J. Molecular therapies for heritable blistering diseases. Trends Mol Med. 2009; 15:285–292. [PubMed: 19581127]

Tan WC, Rodeck CH. Placental calcification in pseudoxanthoma elasticum. Ann Acad Med Singapaore. 2008; 37:598–600.

Trip MD, Smulders YM, Wegman JJ, Hu X, Boer JM, ten Brink JB, et al. Frequent mutation in the ABCC6 gene (R1141X) is associated with a strong increase in the prevalence of coronary artery disease. Circulation. 2002; 106:773–775. [PubMed: 12176944]

Uitto J. Progress in heritable skin diseases: translational implications of mutation analysis and prospects of molecular therapies. Act Derm Venereol. 2009; 89:228–235.

Uitto J, Pulkkinen L, Ringpfeil F. Molecular genetics of pseudoxanthoma elasticum – A metabolic disorder at the environment-genome interface? Trends Mol Med. 2001; 7:13–17. [PubMed: 11427982]

Uitto, J.; Ringpfeil, F. Heritable diseases affecting the elastic fibers: cutis laxa, pseudoxanthoma elasticum and related disorders.. In: Rimoin, DL.; Connor, JM.; Pyeritz, RE.; Korf, BR., editors. Principles and practice of genetics. Fifth Ed. Churchill Livingstone; Philadelphia: 2007. p. 3647-3670.

Vanakker OM, Martin L, Gheduzzi D, Leroy BP, Loeys BL, Guerci VI, et al. Pseudoxanthoma elasticum-like phenotype with cutis laxa and multiple coagulation factor deficiency represents a separate genetic entity. J Invest Dermatol. 2007; 27:581–587. [PubMed: 17110937]

Vattikuti R, Towler DA. Osteogenic regulation of vascular calcification: an early perspective. Am J Physiol Endocrinol Metab. 2004; 286:E686–E696. [PubMed: 15102615]

Wiegand TW, Rogers AH, McCabe F, Reichel E, Duker JS. Intravitreal bevacizumabf (Avastin) treatment of choroidal neovascularization in patients with angioid streaks. Br J Ophthalmol. 2009; 93:47–51. [PubMed: 18971238]

Zarbock R, Hendig D, Szliska C, Kleesiek K, Götting C. Pseudoxanthoma elasticum: genetic variations in antioxidant genes are risk factors for early disease onset. Clin Chem. 2007; 53:1734–1740. [PubMed: 17693525]

Zarbock R, Hendig D, Szliska C, Kleesiek K, Götting C. Vascular endothelial growth factor gene polymorphisms as prognostic markers for ocular manifestations in pseudoxanthoma elasticum. Hum Mol Genet. 2009; 18:3344–3351. [PubMed: 19483196]

NIH-PA Author Manuscript

NIH-PA Author Manuscript

NIH-PA Author Manuscript

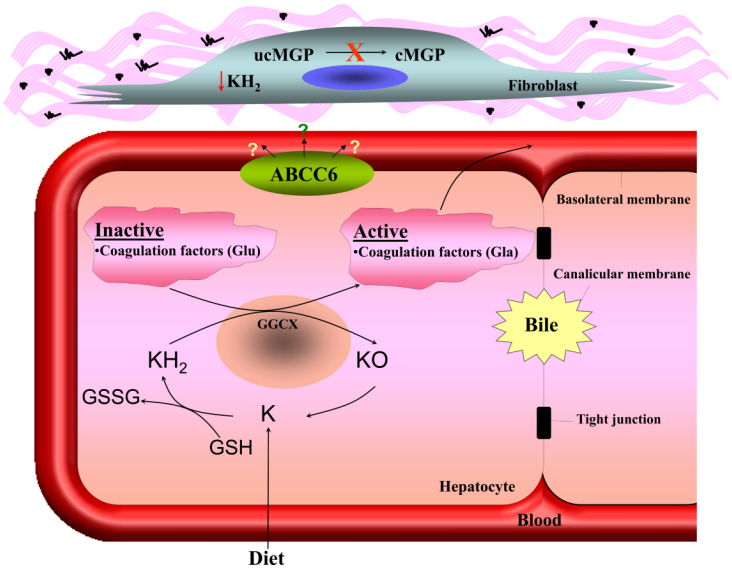

Figure 1. Illustration of the proposed "*metabolic hypothesis*" of PXE

Under physiologic conditions, the ABCC6 protein is expressed in high levels in the liver and serves as an efflux pump on the baso-lateral surface of hepatocytes transporting critical metabolites from the intracellular milieau to the circulation (right side of the panel). In the absence of ABCC6 transporter activity in PXE, reduced concentrations of such substrate molecules, which may serve as physiologic anti-mineralization factors, are found in the circulation, resulting in mineralization of connective tissues in a number of organs, such as the eye, the arterial blood vessels, the kidneys and the skin (middle panel). The presence of mineralization is illustrated by histopathologic examination (Alizarin red stain) of tissues in *Abcc6*$^{-/-}$ mice that recapitulate the features of human PXE. (Modified from Jiang and Uitto, 2006, with permission).

NIH-PA Author Manuscript

NIH-PA Author Manuscript

NIH-PA Author Manuscript

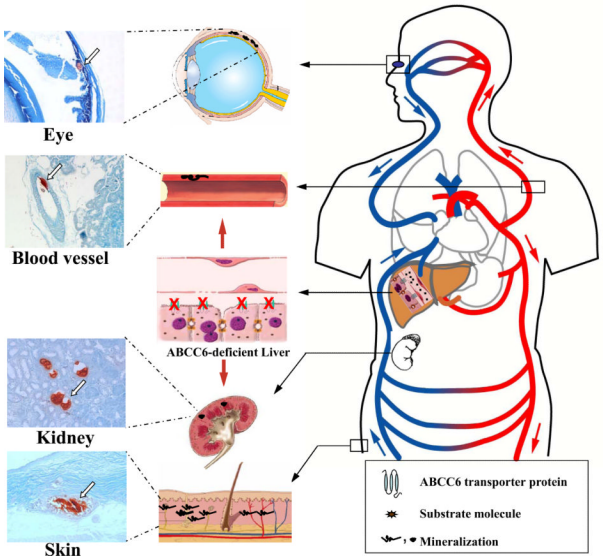

Figure 2. The role of vitamin K in activation of gla-proteins

Vitamin K serves as a co-factor of activation of blood coagulation factors and matrix gla-protein (MGP) by γ-glutamyl carboxylase encoded by the *GGCX* gene. The γ-glutamyl carboxylase activates coagulation factors (Glu→ Gla), the carboxylated forms are secreted into circulation from hepatocytes and are required for normal blood coagulation (lower panel). In peripheral connective tissue cells, such as fibroblasts, similar activation of uncarboxylated MGP (ucMGP) normally takes place resulting in carboxylated matrix gla-protein (cMGP) which is required for prevention of unwanted mineralization of peripheral tissues under normal calcium and phosphate homeostatic conditions (upper panel). It has been postulated that ABCC6 serves as a transporter molecule transporting vitamin K derivatives, such as the reduced form (KH_2) conjugated with glutathione (GSH). In the absence of ABCC6 transporter activity in PXE, the specific vitamin K co-factor concentrations in the serum and in fibroblasts are reduced resulting in deficient activation of MGP and allowing ectopic mineralization in the adjacent connective tissue to take place. (Modified from Li *et al.*, 2009a, with permission).