

Percutaneous transhepatic embolization of biliary leakage with N-butyl cyanoacrylate

Gianpaolo Carrafiello, Anna Maria Ierardi, Filippo Piacentino, Larissa N Cardim

Department of Radiology, University of Insubria, Varese, Italy

Correspondence: Prof. Gianpaolo Carrafiello, Viale Borri, 57 Varese (VA), 21100, Italy. E-mail: g.carraf@gmail.com

Abstract

Biliary leakage is a known complication after biliary surgery. In this report, we describe an uncommon treatment of a common biliary complication, wherein we used percutaneous transhepatic injection of N-butyl cyanoacrylate (NBCA) to treat a biliary leak in an 83-year-old patient.

Key words: Biliary drainage; biliary leakage; N-butyl cyanoacrylate; percutaneous embolization; transhepatic embolization

Introduction

Bile leakage is a well-known and dreaded complication of open or laparoscopic cholecystectomy (LC), major liver surgery, and blunt abdominal injury.^[1] With the advent of treatment by endoscopic sphincterotomy and drainage using either an endoprosthesis or nasobiliary catheter, surgery is now avoided in the majority of cases.^[2-7] However, up to 10% of patients with biliary leaks after LC do not respond to initial endoscopic therapy.^[8] Those with more severe ductal injury and large leaks are especially likely to require surgery.^[9] In the past few years, some alternatives to surgery have been used to control bile leakage, such as injection of fibrin and ethanol, but these have their own problems and complications.^[10,11] Recently, N-butyl-2-cyanoacrylate (NBCA) has been used with this intent. NBCA is a tissue glue monomer that instantly polymerizes and solidifies upon contact with body fluids at neutral pH.^[12] This substance is routinely used in plastic surgery, radiology, neurosurgery, and general surgery and was first used for obliteration of bleeding gastric varices.^[12] NBCA has recently been approved in Europe for endoscopic hemostasis and sealing of fistulae (Glubran 2™, GEM, Viareggio, Italy).^[13]

In the literature, only six cases have been reported of biliary leakage treated percutaneously with NBCA.^[14,15] We would like to discuss one patient where we used NBCA to seal a biliary leakage in a patient with a carcinoma of the papilla of Vater who did not respond to standard endoscopic drainage methods.

Case Report

An 83-year-old male with a carcinoma of the papilla of Vater was treated with a 10F polyethylene stenting (Olympus, Mt Waverley, Australia) of the main biliary duct during endoscopic retrograde cholangiopancreatography. When a stent release was attempted, it was not completely released and remained folded; it was not possible to remove it endoscopically. So a percutaneous transhepatic cholangiogram was performed through the puncture of right intrahepatic biliary system. It revealed an intrahepatic biliary dilatation of both distal systems. An external-internal drainage was positioned. After several cholangiogram controls, stent positioned by endoscopists was removed and two new covered stents (9 × 80 mm) were deployed (Smart, Cordis; Miami Lakes, FL). An internal drainage was maintained. A control cholangiogram revealed bile leakage from the VI-VII segmental biliary duct, communicating with the main biliary tree. The leakage probably originated from the posterior ducts, and it was caused from percutaneous puncture. Conservative treatment was attempted, with maintenance of internal drainage for 15 days, but the leakage associated with a biloma persisted internally [Figure 1]. The patient had pain, fever, and elevated inflammatory indices. Using a different percutaneous access, through the right lobe itself,

Access this article online

Quick Response Code:



Website:
www.ijri.org

DOI:
10.4103/0971-3026.95398

a superselective approach to the site of the leakage was obtained, using another biliary radicle, which was dilated enough. A 2.8F microcatheter (Progreat™; Terumo, Tokyo, Japan) was used using a 5F catheter (Cobra, Cordis, Miami Lakes, FL) and an hydrophilic guidewire (Terumo, Tokyo, Japan). Embolization was performed with three fibered 0.018-inch platinum micro-coils (VortX™; Boston Scientific) with nominal configured diameters of 2 mm × 3 mm, pushed with saline solution injection. The leakage was only slightly reduced. The microcatheter was preliminary flushed by a nonionic dextrose solution and then the tissue adhesive agent NBCA (Glubran 2™, GEM), mixed with iodized oil (Lipiodol™; Guebert, Aulnay-sous-Bois, France) in a ratio of 1:2 for opacification, was injected [Figure 2]. A total of 2 ml of NBCA was administered. This solution completely filled the leakage tract within a few seconds. A postprocedural cholangiogram confirmed the absence of any complication and the disappearance of the leakage [Figure 3]. The patient was discharged after 1 week with an 8F internal–external biliary drain open, allowing bile drainage and permitting

easy access for repeat radiologic follow-up. At the last follow-up visit (3 months after the procedure), the drainage was removed, and no evidence of recurrence was noticed [Figure 4], and also biloma was reabsorbed.

Informed consent was obtained before each procedure. Before any percutaneous procedure, the patient receives intravenous antibiotic, 1.5 g cefuroxime (Cefurex™, Salus Researches S.p.A, Italy), as a one-time dose.

Discussion

Biliary leakage occurs most frequently after hepatobiliary

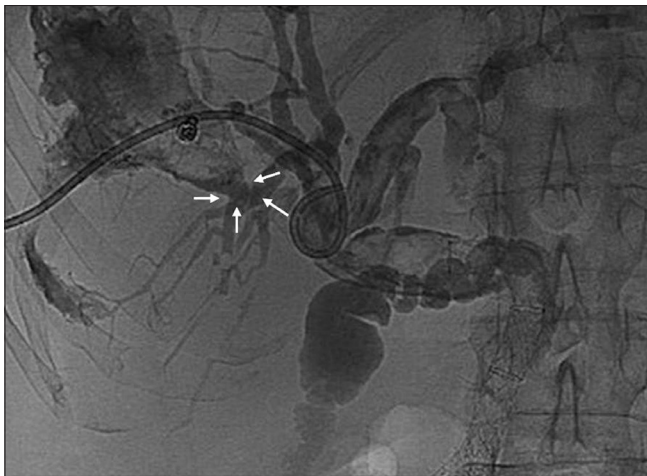


Figure 1: Cholangiogram shows biliary leakage (arrows) after conservative treatment

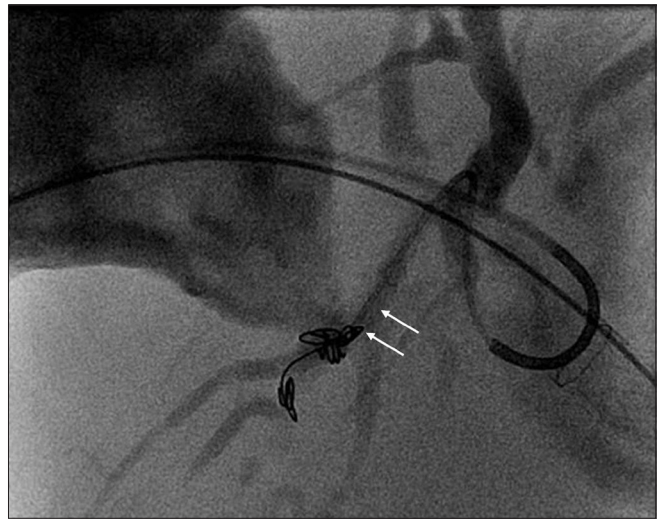


Figure 2: Superselective embolization of biliary leakage with NBCA (arrows)

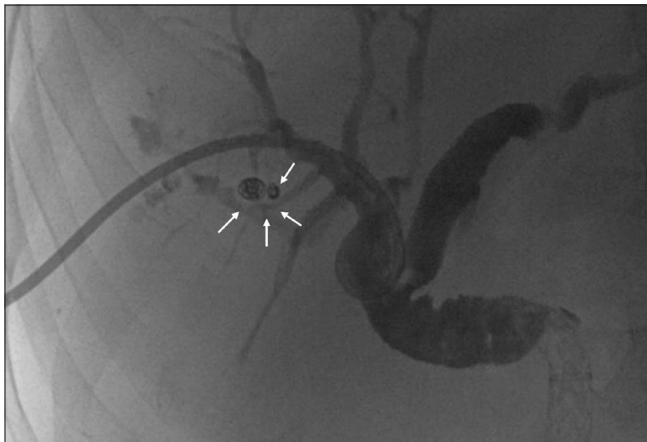


Figure 3: Postprocedural cholangiogram shows the disappearance of the leakage (arrows)

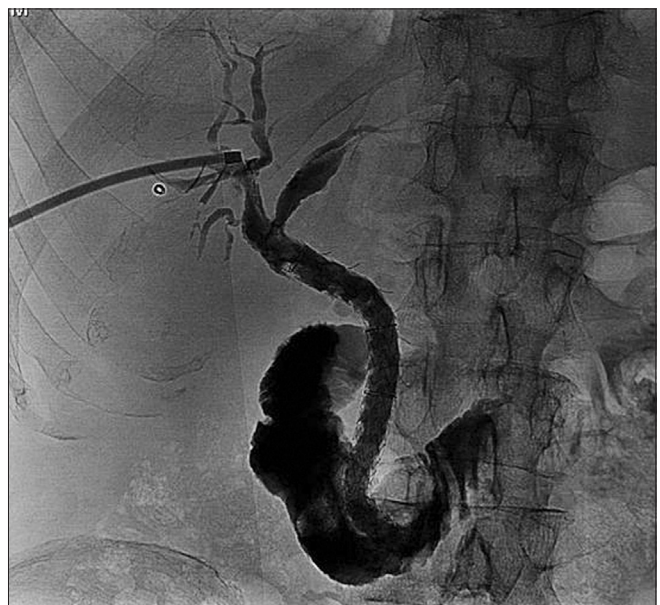

Figure 4: Cholangiogram performed after 3 months shows the absence of recurrence. The drainage was removed

surgery, especially open or LC, but is also seen after liver resection or liver transplantation, after endoscopic or interventional radiological maneuvers, or after severe hepatic trauma.^[14,16,17] Many of these biliary tract injuries may go unrecognized at the time of surgery and have a delayed presentation.^[18] Nonoperative management of these patients can be successful, and interventional radiology has a major role to play in delineating the anatomy of the injury and controlling ongoing bile duct injury.^[18]

In the literature, there is a description of the use of fibrin glue for the treatment of communication between an abscess cavity and an aberrant posterior segment hepatic duct that was injured in a LC; however, the bile discharge in that case was not reduced and the cavity and fistula could not be closed.^[19]

There are three main materials that have been studied as potential sealants of the biliary tract: fibrin,^[10] ethanol, and NBCA. Matsumoto *et al.*^[20] reported a case in which multiple ethanol injections were performed to close a biliary–cutaneous fistula from an isolated small bile duct of the left caudate lobe after resection of the right caudate lobe for hepatocellular carcinoma. Sadakari *et al.*^[21] described a case of intractable bile leakage after hepatectomy, which was successfully treated by percutaneous transhepatic portal embolization with ethanol. Ethanol is not advised when there is communication with the remainder of the biliary tree^[11] as there may be seepage of the ethanol into the biliary tree, which could lead to irreversible damage.^[22] Flushing, fever, leukocytosis, mild increases of aminotransferase levels, and systemic hypotension may occur with ethanol injection.^[11,21,22] Ethanol injection may also cause necrosis of the bile duct epithelium.^[21]

NCBA, a low-viscosity monomer used as tissue adhesive glue, is a promising solution to biliary chemical embolization. When in contact with organic fluids (i.e., bile), this substance undergoes rapid polymerization and solidification. It provides a permanent embolization and hence, due to an inflammatory tissue response, a long-term occlusion in vessels of various size resulting in vessel thrombosis or tissue atrophy.^[14,15,17]

Vu *et al.*,^[14] based on their experience with six patients, suggested the placement of a coil at the neck of the fistula and subsequent administration of NBCA from an external approach as the most effective way to prevent recurrence of biliary fistulas.

Gorich *et al.*^[16] described their experience of percutaneous embolization of bile duct fistulas with Ethibloc™ (Ethicon, Somerville, NJ) and isobutyl-2-cyanoacrylate in four patients. They observed unintentional spillage of isobutyl-2-cyanoacrylate in the bile duct in one of the four patients. They also reported that a coaxial catheter became glued

to the bile duct wall in one patient after an isobutyl-2-cyanoacrylate embolization.^[16]

If the patient is unable to undergo percutaneous embolization for the biliary leak, continued percutaneous drainage is also an option. However, this too is not without complications. Bleeding episodes can occur after catheter removal and metabolic acidosis may develop secondary to continued bile loss from the drainage catheter.^[23]

We could find only two reports in literature describing biliary leakage treated with percutaneous insertion of NBCA: the series of patients (six patients) treated by Vu *et al.*^[14] and a case report by Lauterio *et al.*^[15] The success of the procedure in our patient is further evidence of the efficacy and safety of using percutaneous insertion of NBCA glue in biliary injuries. Further studies are needed to confirm the efficacy and safety of this approach and to determine whether it can reduce hospital stay and treatment costs.

References

1. Albasini JL, Aledo VS, Dexter SP, Marton J, Martin IG, McMahon MJ. Bile leakage following laparoscopic cholecystectomy. *Surg Endosc* 1995;9:1274-8.
2. O’Rahilly S, Duignan JP, Lennon JR, O’Malley E. Successful treatment of a post-operative external biliary fistula by endoscopic papillotomy. *Endoscopy* 1983;15:68-9.
3. Burmeister W, Koppen MO, Wurbs D. Treatment of a biliocutaneous fistula by endoscopic insertion of a nasobiliary tube. *Gastrointest Endosc* 1985;31:279-81.
4. Sauerbruch T, Weinzierl M, Holl J, Pratschke E. Treatment of postoperative bile fistulas by internal endoscopic biliary drainage. *Gastroenterology* 1986;90:1998-2003.
5. Kozarek RA, Traverso LW. Endoscopic stent placement for cystic duct leak after laparoscopic cholecystectomy. *Gastrointest Endosc* 1991;37:71-3.
6. Chow S, Bosco JJ, Heiss FW, Shea JA, Qaseem T, Howell D. Successful treatment of post-cholecystectomy bile leaks using nasobiliary tube drainage and sphincterotomy. *Am J Gastroenterol* 1997;92:1839-43.
7. Sugiyama M, Atomi Y, Matsuoka T, Yamaguchi Y. Endoscopic biliary stenting for treatment of persistent biliary fistula after blunt hepatic injury. *Gastrointest Endosc* 2000;51:42-4.
8. Ryan ME, Geenen JE, Lehman GA, Aliperti G, Freeman ML, Silverman WB, *et al.* Endoscopic intervention for biliary leaks after laparoscopic cholecystectomy: A multicenter review. *Gastrointest Endosc* 1998;47:261-6.
9. Bergman JJ, van den Brink GR, Rauws EA, de Wit L, Obertop H, Huibregtse K, *et al.* Treatment of bile duct lesions after laparoscopic cholecystectomy. *Gut* 1996;38:141-7.
10. Brady AP, Malone DE, Deignan RW, O’Donovan N, McGrath FP. Fibrin sealant in interventional radiology: A preliminary evaluation. *Radiology* 1995;196:573-8.
11. Kusano T, Kida H, Nishiwaki Y, Ikematsu Y, Goto K, Kuroda H, *et al.* Percutaneous sclerotherapy for intractable external biliary fistula after hepatectomy. *Int Surg* 2003;88:72-5.
12. Soehendra N, Nam VC, Grimm H, Kempeneers I. Endoscopic obliteration of large esophagogastric varices with bucrylate. *Endoscopy* 1986;18:25-6.
13. Seewald S, Groth S, Sriram PV, Xikun H, Akaraviputh T, Mendoza

- G, *et al.* Endoscopic treatment with biliary leakage with n-butyl-2 cyanoacrylate. *Gastrointest Endosc* 2002;56:916-9.
14. Vu DN, Strub WM, Nguyen PM. Biliary duct ablation with n-butyl cyanoacrylate. *J Vasc Interv Radiol* 2006;17:63-9.
 15. Lauterio A, Slim A, Aseni P, Giacomoni A, Di Sandro S, Corso R, *et al.* Percutaneous transhepatic bile duct ablation with n-butyl cyanoacrylate in the treatment of a biliary complication after split liver transplantation. *J Transplant* 2009;2009:824803.
 16. Görich J, Rilinger N, Sokiranski R, Siech M, Vogel J, Wikström M, *et al.* Percutaneous transhepatic embolization of bile duct fistulas. *J Vasc Interv Radiol* 1996;7:435-8.
 17. Seewald S, Groth S, Sriram PV, Xikun H, Akaraviputh T, Mendoza G, *et al.* Endoscopic treatment of biliary leakage with n-butyl-2 cyanoacrylate. *Gastrointest Endosc* 2002;56:916-9.
 18. Lichtenstein S, Moorman DW, Malatesta JQ, Martin MF. The role of hepatic resection in the management of bile duct injuries following laparoscopic cholecystectomy. *Am Surg* 2000;66:372-6; discussion 377.
 19. Ohtsuka T, Chijiwa K, Yamaguchi K, Akashi Y, Matsunaga H, Miyoshi A. Posterior hepatic duct injury during laparoscopic cholecystectomy finally necessitating hepatic resection: Case Report. *JLS* 1999;3:323-6.
 20. Matsumoto T, Iwaki K, Hagino Y, Kawano K, Kitano S, Tomonari K, *et al.* Ethanol injection therapy of an isolated bile duct associated with a biliary cutaneous fistula. *J Gastroenterol Hepatol* 2002;17:807-10.
 21. Sadakari Y, Miyoshi A, Ohtsuka T, Kohya N, Takahashi T, Matsumoto K, *et al.* Percutaneous transhepatic portal embolization for persistent bile leakage after hepatic resection: Report of a case. *Surg Today* 2008;38:668-71.
 22. Kyokane T, Nagino M, Sano T, Nimura Y. Ethanol ablation for segmental bile duct leakage after hepatobiliary resection. *Surgery* 2002;131:111-3.
 23. Kaufman SL, Kadir S, Mitchell SE, Chang R, Kinnison ML, Cameron JL, *et al.* Percutaneous transhepatic biliary drainage for bile leaks and fistulas. *AJR Am J Roentgenol* 1985;144:1055-8.

Cite this article as: Carrafiello G, Ierardi AM, Piacentino F, Cardim LN. Percutaneous transhepatic embolization of biliary leakage with N-butyl cyanoacrylate. *Indian J Radiol Imaging* 2012;22:19-22.

Source of Support: Nil, **Conflict of Interest:** None declared.

Author Help: Online submission of the manuscripts

Articles can be submitted online from <http://www.journalonweb.com>. For online submission, the articles should be prepared in two files (first page file and article file). Images should be submitted separately.

1) **First Page File:**

Prepare the title page, covering letter, acknowledgement etc. using a word processor program. All information related to your identity should be included here. Use text/rtf/doc/pdf files. Do not zip the files.

2) **Article File:**

The main text of the article, beginning with the Abstract to References (including tables) should be in this file. Do not include any information (such as acknowledgement, your names in page headers etc.) in this file. Use text/rtf/doc/pdf files. Do not zip the files. Limit the file size to 1024 kb. Do not incorporate images in the file. If file size is large, graphs can be submitted separately as images, without their being incorporated in the article file. This will reduce the size of the file.

3) **Images:**

Submit good quality color images. Each image should be less than **4096 kb (4 MB)** in size. The size of the image can be reduced by decreasing the actual height and width of the images (keep up to about 6 inches and up to about 1800 x 1200 pixels). JPEG is the most suitable file format. The image quality should be good enough to judge the scientific value of the image. For the purpose of printing, always retain a good quality, high resolution image. This high resolution image should be sent to the editorial office at the time of sending a revised article.

4) **Legends:**

Legends for the figures/images should be included at the end of the article file.