

Safety of cervical spine manipulation: are adverse events preventable and are manipulations being performed appropriately? A review of 134 case reports

Emilio J. Puentedura¹, Jessica March¹, Joe Anders¹, Amber Perez¹, Merrill R. Landers¹, Harvey W. Wallmann², Joshua A. Cleland³

¹Department of Physical Therapy, School of Allied Health Sciences, University of Nevada Las Vegas, Las Vegas, NV, USA, ²Department of Physical Therapy, Western Kentucky University, Bowling Green, KY, USA; ³Department of Physical Therapy, Franklin Pierce University, Concord, NH, USA

Background: Cervical spine manipulation (CSM) is a commonly utilized intervention, but its use remains controversial.

Purpose: To retrospectively analyze all available documented case reports in the literature describing patients who had experienced severe adverse events (AEs) after receiving CSM to determine if the CSM was used appropriately, and if these types of AEs could have been prevented using sound clinical reasoning on the part of the clinician.

Data sources: PubMed and the Cumulative Index to Nursing and Allied Health were systematically searched for case reports between 1950 and 2010 of AEs following CSM.

Study selection: Case reports were included if they were peer-reviewed; published between 1950 and 2010; case reports or case series; and had CSM as an intervention. Articles were excluded if the AE occurred without CSM (e.g. spontaneous); they were systematic or literature reviews. Data extracted from each case report included: gender; age; who performed the CSM and why; presence of contraindications; the number of manipulation interventions performed; initial symptoms experienced after the CSM; and type of resultant AE.

Data synthesis: Based on the information gathered, CSMs were categorized as appropriate or inappropriate, and AEs were categorized as preventable, unpreventable, or unknown. Chi-square analysis with an alpha level of 0.05 was used to determine if there was a difference in proportion between six categories: appropriate/preventable, appropriate/unpreventable, appropriate/unknown, inappropriate/preventable, inappropriate/unpreventable, and inappropriate/unknown.

Results: One hundred thirty four cases, reported in 93 case reports, were reviewed. There was no significant difference in proportions between appropriateness and preventability, $P=.46$. Of the 134 cases, 60 (44.8%) were categorized as preventable, 14 (10.4%) were unpreventable and 60 (44.8%) were categorized as 'unknown'. CSM was performed appropriately in 80.6% of cases. Death resulted in 5.2% ($n=7$) of the cases, mostly caused by arterial dissection.

Limitations: There may have been discrepancies between what was reported in the cases and what actually occurred, since physicians dealing with the effects of the AE, rather than the clinician performing the CSM, published many of the cases.

Conclusions: This review showed that, if all contraindications and red flags were ruled out, there was potential for a clinician to prevent 44.8% of AEs associated with CSM. Additionally, 10.4% of the events were unpreventable, suggesting some inherent risk associated with CSM even after a thorough exam and proper clinical reasoning.

Keywords: Adverse events, Case reports, Cervical spine, Manipulation, Risk of harm, Safety

Introduction

Cervical spine manipulation (CSM) is utilized by physical therapists, chiropractors, and other health-care practitioners to treat a multitude of disorders, most commonly headaches, neck pain, and stiffness.¹

Correspondence to: E J Puentedura, Department of Physical Therapy, School of Allied Health Sciences, University of Nevada Las Vegas, 4505 Maryland Parkway, Box 453029, Las Vegas, NV 89154-3029, USA. Email: louie.puentedura@unlv.edu

The safety of CSM has been an issue of significant debate since 1907, when the first adverse event (AE) was reported.² An AE is here defined as the sequelae following a CSM that are medium to long term in duration, with moderate to severe symptoms, and of a nature that was serious, distressing, and unacceptable to the patient and required further treatment.^{3,4} Much of the debate regarding the safety of CSM may be attributed to the lack of agreement between incidence reports of AE following CSM, which have been reported to vary from 1/50 000 to 1/5.85 million manipulations.^{5,6}

While there is little agreement between the frequency of incidence, it is evident that there are some risks associated with CSM. Several literature reviews have suggested that the risks associated with CSM may outweigh the benefits.^{1,7-9} This conclusion may have been made based on the fact that there exists limited evidence for the effectiveness of CSM and that the potential benefits may not offset the risks associated with the technique.⁷ Additionally, after a retrospective review of cases involving cerebrovascular accident (CVA) following CSM, Haldeman *et al.*¹⁰ concluded that risks associated with CSM are inherent and the occurrence of serious complications appears to be unpredictable.

Despite the conclusions from Haldeman *et al.*,¹⁰ some have speculated that AEs following CSM are predictable and may be attributed to insufficient judgment and examination by the clinician as well as inadequate skill or inappropriate use of techniques.¹ It has been suggested that, when deciding whether or not to use CSM, a clinician should determine if the technique is both appropriate and safe.^{11,12} CSM may be considered an appropriate treatment technique if it is indicated by the patient's presenting condition. Such conditions indicating the use of CSM include neck pain, stiffness, cervicogenic headache, and cervical radiculopathy.¹² A 1995 study examined the appropriateness of CSM by surveying the opinions of a nine-member multidisciplinary expert panel.¹² The panel was presented with clinical scenarios including patient history, symptoms, results from radiographic imaging, and response to previous treatment. Patient conditions ranged from acute neck pain to cardiovascular pathology. The panel found CSM to be an

Table 1 Absolute contraindications to performing cervical spine manipulation (CSM)

Acute fracture	Acute soft tissue injury
Dislocation	Osteoporosis
Ligamentous rupture	Ankylosing spondylitis
Instability	Rheumatoid arthritis
Tumor	Vascular disease
Infection	Vertebral artery abnormalities
Acute myelopathy	Connective tissue disease
Recent surgery	Anticoagulant therapy

appropriate technique to use in only 11.1% of the 736 clinical scenarios.¹² The study emphasized the importance of proper clinical reasoning, so as to not place a patient at risk for an AE following CSM if they are not likely to benefit from the technique.

Once CSM is deemed to be appropriate for a patient's presenting condition, the clinician should determine the safety of the technique by identifying preexisting conditions that might indicate a patient's risk for an AE. Absolute contraindications (Table 1) and red flag symptoms (Table 2) have been identified to assist clinicians with decision-making.¹ Red flag symptoms may indicate the presence of a contraindicated condition. CSM should never be performed when absolute contraindications or red flag symptoms are present.¹ Childs *et al.*¹¹ recommend that contraindications and red flags be used in conjunction with sound clinical reasoning as part of an examination scheme to assist in determining if CSM is an appropriate technique and to prevent AE due to CSM.

While suggestions have been made to guide clinical reasoning and reduce the risk of AE following spinal manipulation, there have been few studies examining the use of these suggestions clinically.^{10,13} Haldeman *et al.*¹⁰ were unable to recognize characteristics from a patient's history or examination that would indicate increased risk of CVA following CSM.

The purpose of this review was to retrospectively analyze all available documented case reports in the literature describing patients who had experienced severe AEs after receiving CSM to determine if the CSM was used appropriately, and if these types of AEs could have been prevented using sound clinical reasoning on the part of the clinician. Secondary analysis was performed to examine the characteristics of cases leading to death.

Methods

Case reports published in peer-reviewed journals involving AE following CSM were found by searching PubMed (1950–2010) and the Cumulative Index

Table 2 Red flags

Previous diagnosis of vertebrobasilar insufficiency
Facial/intra-oral anesthesia or paresthesia
Visual disturbances
Dizziness/vertigo
Blurred vision
Diplopia
Nausea
Tinnitus
Drop attacks
Dysarthria
Dysphagia
Any symptom listed above aggravated by position or movement of the neck
No change or worsening of symptoms after multiple manipulations

to Nursing and Allied Health (CINHAL, 1982–2010). Initial search terms included any combination of the following: *cervical manipulation, adjustment, chiropractic, manual therapy, physical therapy, physiotherapy, osteopathy, arterial injury, stroke, safety, adverse event, side effect, injury*; and *risk*. Additional case reports were obtained through hand searching the reference list from previous review articles on cervical manipulation injuries by Di Fabio,⁷ Ernst,^{8,9} and Terrett.¹⁴

Titles and abstracts of articles identified with search terms were screened by three independent reviewers. Articles were included if they: (1) were peer-reviewed; (2) were published between 1950 and 2010; (3) provided case reports or case series; and (4) had CSM as an intervention. Articles were excluded if: (1) the AE occurred without CSM (e.g. spontaneous); (2) the article was a systematic or literature review; or (3) it was written in a language other than English, German, Spanish, Polish, French, or Norwegian. See Fig. 1 for a summary of the article retrieval and review process.

Cases included in a language other than English were translated by native speakers or those fluent in the language prior to being evaluated. All case information was entered into a case analysis form which included: gender; age; who performed the CSM and why; presence of contraindications; the number of manipulation interventions performed; initial symptoms experienced after the CSM; as well as type of AE that resulted.

All three reviewers completed a case analysis form and categorized each case report individually. Based on the information gathered, CSMs were categorized as appropriate or inappropriate, and AEs were categorized as preventable, unpreventable, or unknown. The appropriateness of cases was dichotomized based upon the patient’s presenting condition. A case was determined to be appropriate if CSM was used for an indicated condition such as neck pain, neck stiffness, headache, or cervical radiculopathy; and inappropriate when CSM was performed for reasons that are not indicative to cervical disorders, such as low back pain, otitis media, asthma, non-radicular shoulder pain, or maintenance therapy.

Preventability was based on the presence of factors that increase a patient’s risk for injury. Cases were classified as preventable when contraindications or red flags should have otherwise stopped the care provider from performing CSM and unpreventable when the patient appeared to be clear of any contraindications or red flags to CSM either in current and/or past history (see Tables 1 and 2). Therefore, a CSM could have been performed for appropriate reasons, but if the clinician performed the CSM in the presence of contraindications or red

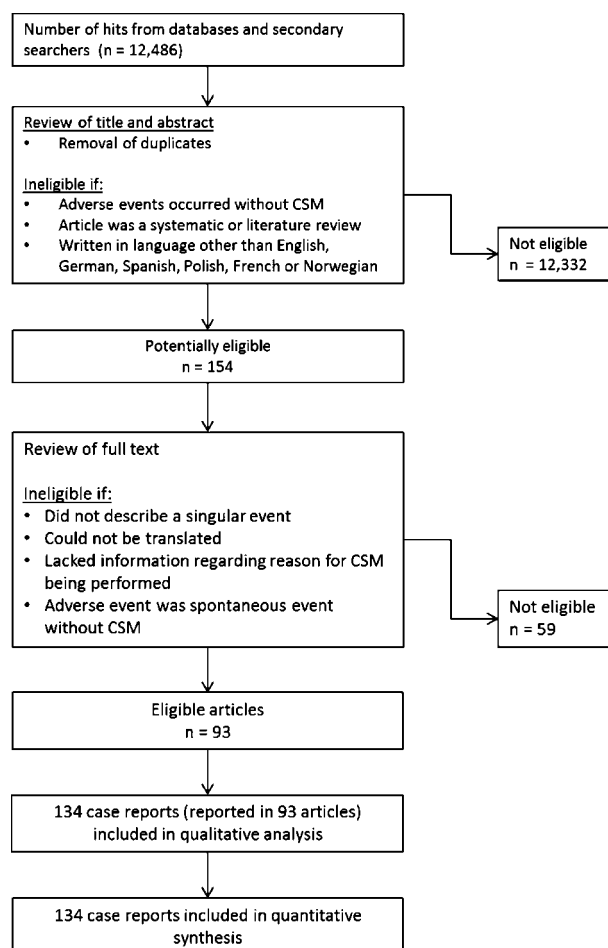


Figure 1 Retrieval and review process.

flags, the AE was classified as preventable. Cases were also classified as preventable when CSM was continued for more than five consecutive treatment sessions with either no change in presenting symptoms or worsening of symptoms. An unknown category was created and used whenever a case report did not provide enough information to allow it to be categorized as either preventable or unpreventable. To improve the accuracy of data analysis, each case was then compared between all three reviewers and disagreements were resolved by consensus. A fourth reviewer independently analyzed the cases afterwards to ensure there was final consensus.

All statistics were performed using PASW 17.0 (SPSS 2009, PASW Statistics 2009 PASW statistics version 17.0. Chicago, IL: SPSS, Inc.). Chi-square analysis with an alpha level of 0.05 was used to determine if there was a difference in proportion between the six categories: appropriate/preventable, appropriate/unpreventable, appropriate/unknown, inappropriate/preventable, inappropriate/unpreventable, and inappropriate/unknown. Our hypothesis was that there would be an association between CSMs that were performed inappropriately and AEs that were preventable. Further examination of these categories was done with frequency statistics. Demographic data

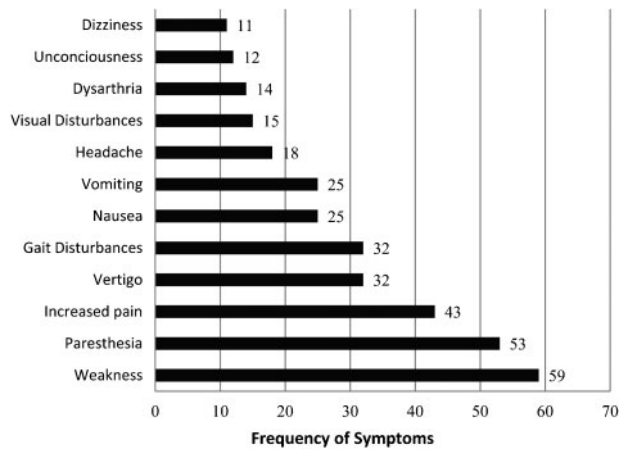


Figure 2 Frequency of symptoms associated with adverse events (AEs) following cervical spine manipulation (CSM).

and remaining data from the case analysis sheets were analyzed using descriptive and frequency statistics.

Results

Demographics

One hundred and thirty-four (134) cases, reported in 93 articles, were analyzed for this review.¹⁵⁻¹⁰⁷ Language translation by researchers fluent in the language was required in 9% of the cases. The 134 cases involved 73 males and 61 females. The average age of the patient was 43.8 years (SD=11.8; range=23-86 years).

Arterial dissection was the most common AE reported, being present in 37.3% of the cases (n=50). Other common AEs included disc herniation (18.7%, n=25), CVA (13.4%, n=18), and vertebral dislocation or fracture (6.7%, n=9). The most common post-manipulation symptoms described were weakness (n=59), paresthesias (n=53), and increased pain (n=43) (Fig. 2).

Chiropractors were involved in the majority of injuries following CSM with 69.4% (n=93) of the cases analyzed (Fig. 3). Osteopathic physicians were involved in 8.2% (n=11) of the cases. Physical therapists accounted for 3.7% (n=5) of the cases; whereas, 11.9% (n=16) did not report the practitioner performing the CSM. Non-clinicians, including bone setters, barbers, and masseurs accounted for 6.7% (n=9) of the CSMs.

Appropriateness and preventability

Chi-square analysis showed no significant difference in the proportions between appropriateness of the CSM and preventability of AE, chi-square(2)=1.556, P=0.46. Of the cases analyzed, 19.4% (n=26) of the CSMs were categorized as inappropriate, 44.8% (n=60) of the AEs were preventable, and 9% (n=12) of the cases were both inappropriate and preventable (Table 3).

Half of the cases categorized as preventable (n=30) were determined to be so because of the presence of a

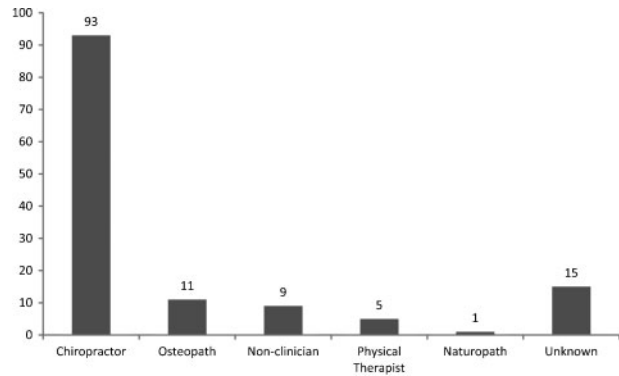


Figure 3 Frequency of practitioners performing cervical spine manipulation (CSM) in cases of adverse events (AEs).

preexisting condition in the cervical spine. Preexisting conditions present in the preventable cases consisted mostly (70%, n=21) of active bony pathologies including severe spondylosis, osteoporosis, rheumatoid arthritis, ankylosing spondylitis, and cervical stenosis. Vascular pathologies, such as cardiac infarct and atherosclerosis of the cervical arteries, accounted for 13.3% (n=4) of preexisting conditions. Miscellaneous conditions consisting of pregnancy, chronic symptoms from a motor vehicle accident 40 years prior, and symptomatic disc pathology, accounted for 16.7% (n=5) of AEs. Continued manipulations (more than five consecutive treatments) with either no change in presenting symptoms or worsening of symptoms, occurred with a frequency of 24.6% (n=15) in both conditions.

Cases resulting in death

Seven (5.2%) of the total cases ultimately resulted in death. Of the patients involved, four were male and three were female between the ages of 25 and 51 years. Practitioners involved in resulting death included: chiropractors (71.4%, n=5), a naturopath (14.3%, n=1), and an unknown practitioner (14.3%, n=1). Arterial dissection was the cause of five deaths and CVA accounted for the remaining two deaths. Four of the deaths were determined to be preventable, one unpreventable and two unknown. Two of the cases resulting in death were categorized as preventable because the practitioner continued to perform CSM when symptoms were worsening, and

Table 3 Distribution of cases categorized by appropriateness and preventability

	Appropriate	Inappropriate	Total
Preventable	48 80.0%	12 20.0%	60 44.8%
Unpreventable	13 92.9%	1 7.2%	14 10.4%
Unknown	47 78.3%	13 21.7%	60 44.8%
Total	108 80.6%	26 19.4%	134 100.0%

in the other two cases, clinicians performed excessive (>5) CSMs with no change in symptoms.

Discussion

There was no significant association between appropriateness of CSM and preventability of AE. CSMs that were performed inappropriately were not more likely to be classified as preventable. In fact, while 80.6% of all reviewed CSMs were performed for appropriate conditions, 44.8% of the cases were preventable and apparently not screened for contraindicating signs. These results suggested that simply determining that a CSM may be indicated is not sufficient to prevent AE. From a clinical perspective, a thorough examination to rule out all contraindications and red flags may have the potential to prevent nearly half of all AEs related to CSM. Additionally, 19.4% of CSMs reviewed were performed for inappropriate conditions, meaning that patients were placed at risk for AE although they were not likely to benefit from the technique.

The inability of clinicians to recognize signs indicating that a patient is at increased risk may be attributed to the lack of reliable and valid screening tools, as well as poor history taking and insufficient clinical reasoning. The most common AE reported in these cases was arterial dissection. This finding has been well documented, and as a result, pre-manipulative screening tools have mostly focused on identifying patients who experience vertebral insufficiency (VBI) or may have cervical arterial dysfunction (CAD)¹⁰⁸ to rule out risk of arterial dissection associated with CSM, although the use of these tests remains controversial.^{2,109–111} The controversy stems from the high rate of false-positive results associated with these tools.¹¹¹ Westaway *et al.*¹¹¹ and Haldeman *et al.*¹⁰ described cases in which patients experienced VBI, but screening tools, consisting of end range extension and rotation of the cervical spine to evaluate vertebral artery patency, failed to provoke symptoms that would contraindicate CSM. In cases reviewed that were found to be preventable, clinicians may not have considered the possibility of CAD in their patient and may have excluded VBI testing due to conflicting evidence regarding its efficacy. However, it is also possible that clinicians had no intent to screen for contraindications due to lack of knowledge, poor clinical judgment or carelessness. Regardless of the evidence, or lack thereof, it is the responsibility of the clinician to perform screening examinations and clearly document their use to reduce legal risk if an AE were to occur with CSM.^{11,108,112,113}

With uncertainty regarding screening tools, clinicians must use additional strategies (e.g. red flags) for decision-making when choosing to use CSM.¹¹ Most of

the cases reviewed were classified as preventable due to inability of the clinician to recognize red flag symptoms of preexisting conditions that would contraindicate the use of CSM. The most common preexisting conditions were found to be bony pathologies such as severe osteoporosis, spondylosis, and rheumatoid arthritis. These conditions are clear contraindications to CSM and should have been easily identifiable through a detailed patient history. With the lack of accurate screening tools, it is prudent for the clinician to perform a thorough history to ensure patient safety.¹¹ Clinicians should use not only clinical reasoning to determine whether or not CSM is appropriate and safe, but they should also consider their own skill level, the preferences of the referring provider, and the demeanor and goals of the patient.^{11,112}

While most of the cases of AEs were classified as preventable, 10.4% of cases were found to be unpreventable. Considering reported incidence figures, AEs following CSM are uncommon at 1/50 000,⁵ indicating that the 14 unpreventable AEs are perhaps even more uncommon. Though millions of CSMs are performed without AE, the results suggest that there is a very small but inherent risk associated with CSM even after a thorough examination for contraindications and proper clinical reasoning. These findings are consistent with conclusions made by Haldeman *et al.*,¹¹⁴ but may also reflect the inability of examination procedures to detect all patients at risk for AE.

Demographics of the patient population were comparable to those reported in previous literature, with one disparity consisting of gender ratios being skewed more toward male than female.^{7–9} In our review, the majority of AEs were severe and irreversible. However, according to current literature, transient events (side effects) are more common than severe AE.¹¹⁵ In fact, transient side effects are reported to occur in 55% of all CSMs.^{116,117} The discrepancy in representation of severity is likely because transient side effects tend to be under-reported. Severe complications are more likely to require medical attention and, therefore, be documented.¹¹⁸ Additionally, the purpose of this review was to analyze cases with severe AE rather than transient side effects following CSM.

The distribution of clinicians in our review mirrors those described by both Di Fabio⁷ and Ernst.⁸ Chiropractors were found to be involved in the majority of severe AEs resulting from CSM. This result may be because CSM is the most common treatment intervention used in the practice of chiropractic and is performed with greater frequency by chiropractors than any other clinician. Osteopaths and physical therapists were also involved in 11 and 4%, respectively, of the AEs associated with CSM in this review.

The incidences of severe injuries resulting from CSM have been estimated to be uncommon, with injuries resulting in death even less common.^{5,6} Of the cases analyzed, death occurred in only 5.2% compared to 18% as reported by Di Fabio.⁷ This discrepancy may be attributed to differences in the results of our literature search. The most recent case of death included in the present review was reported in 1995, which may indicate either a lower incidence of death resulting from CSM or a lack of reporting of such incidences in recent years. Other factors that may have contributed include the following: a paucity of reports written by clinicians regarding death after CSM; search methods may not have been sufficient to identify more recent cases of death; and stipulations of settlements on litigated cases may not have allowed information regarding the case to be made public. Most of the deaths were related to CSM provided by chiropractors, which is reflected in the percentage of chiropractors involved in total CSMs. In this review, chiropractors were involved in 71% of the deaths, which mirrors the 70% of the total AEs that were associated with chiropractors performing the CSM.

All deaths were related to either arterial dissection or CVA. It is well known that CVA and arterial dissection are closely related, and it is possible that the cases of CVA may have also been caused by arterial dissection that was missed upon examination.¹¹⁹ Although many factors may lead to serious complications, arterial dissection is potentially the most serious and life threatening complication resulting from CSM.

Four cases of death were found to be preventable. Of these cases, two patients received multiple manipulations with no improvement in symptoms.^{66,90} The first patient received at least 19 CSMs in 4 months without change in their presenting headache symptoms, while the second patient was receiving CSM 'maintenance therapy' over multiple years with no improvement in symptoms.^{66,90} Among other potential factors, these cases may suggest that repeated CSMs could lead to damage to the vessels over time. While no human studies have been conducted, Austin *et al.* were unable to refute or support the idea that micro-damage occurs to arterial vessels with repeated CSM in his animal model study.¹²⁰ The third patient experienced symptoms of vertebrobasilar ischemia following CSM including dizziness, severe headache, and nausea, but was treated with another CSM 1 hour later resulting in loss of consciousness and cessation of breathing.⁵⁰ The final patient was noted to have a red flag symptom of vertigo prior to receiving CSM.⁷⁵ In these cases, it appears that the clinician may have missed or ignored symptoms indicating that the patient was at risk for

serious injury. Although evidence for VBI testing and related symptoms to rule out the presence of CAD are lacking, it is unwise for clinicians to disregard these symptoms and continue to perform CSM in their presence.¹¹

Limitations

One limitation of our review was that the search for relevant cases may not have been exhaustive due to exclusion prior to 1950 and use of limited search engines. Another limitation may have been discrepancies between what was reported in the cases and what actually occurred, since physicians dealing with the effects of the AE, rather than the clinician performing the CSM, published many of the cases. Missing information needed for the analysis of cases resulted in the exclusion, or placement of a large proportion (44.8%) of cases into an unknown category, which may have had an influence on the results of the statistical analyses. When the term 'chiropractic manipulation' was used in the case reports, it was assumed that the clinician performing the CSM was indeed a chiropractor. However, Di Fabio stated that the term 'chiropractic manipulation' was occasionally used when other clinicians were performing the CSM.⁷ Additionally, relying on secondary sources for translation of non-English articles may have led to misinterpretation by the translators as well as the reviewers.

Based on the results of this review, we propose that cases regarding AE to CSM should provide more standardized information. This should include detailed information regarding the manipulation technique, as proposed by Mintken *et al.*¹²¹ The six categories suggested include: (1) rate of force application; (2) location in range of available movement; (3) direction of force; (4) target of force; (5) relative structural movement; and (6) patient position.¹²¹ Additionally, cases should include: total number of CSMs performed for the present condition; for what condition the CSM was performed; which clinician performed the CSM; and a description of examination procedures to rule out contraindications and red flags.

Conclusion

This review showed that, if all contraindications and red flags were ruled out, there was potential for a clinician to prevent 44.8% of AEs associated with CSM. Additionally, 10.4% of the events were unpreventable, suggesting some inherent risks associated with CSM even after a thorough exam and proper clinical reasoning. By performing a thorough examination and using sound clinical reasoning, clinicians may be able to prevent a majority of AEs, further reducing risks associated with CSM and improving patient safety.

References

- 1 Refshauge KM, Parry S, Shirley D, Larsen D, Rivett DA, Boland R. Professional responsibility in relation to cervical spine manipulation. *Aust J Physiother*. 2002;48:171–9.
- 2 Rivett DA. Adverse events and the vertebral artery: can they be averted? *Man Ther*. 2006;11:241–2.
- 3 Puentedura EJ, Landers MR, Cleland JA, Mintken PE, Huijbregts P, Fernandez-de-Las-Penas C. Thoracic spine thrust manipulation versus cervical spine thrust manipulation in patients with acute neck pain: a randomized clinical trial. *J Orthop Sports Phys Ther*. 2011;41:208–20.
- 4 Carnes D, Mullinger B, Underwood M. Defining adverse events in manual therapies: a modified Delphi consensus study. *Man Ther*. 2010;15:2–6.
- 5 Magarey ME, Rebbeck T, Coughlan B, Grimmer K, Rivett DA, Refshauge K. Pre-manipulative testing of the cervical spine review, revision and new clinical guidelines. *Man Ther*. 2004;9:95–108.
- 6 Haldeman S, Carey P, Townsend M, Papadopoulos C. Arterial dissections following cervical manipulation: the chiropractic experience. *CMAJ*. 2001;165:905–6.
- 7 Di Fabio RP. Manipulation of the cervical spine: risks and benefits. *Phys Ther*. 1999;79:50–65.
- 8 Ernst E. Manipulation of the cervical spine: a systematic review of case reports of serious adverse events, 1995–2001. *Med J Aust*. 2002;176:376–80.
- 9 Ernst E. Adverse effects of spinal manipulation: a systematic review. *J R Soc Med*. 2007;100:330–8.
- 10 Haldeman S, Kohlbeck FJ, McGregor M. Unpredictability of cerebrovascular ischemia associated with cervical spine manipulation therapy: a review of sixty-four cases after cervical spine manipulation. *Spine (Phila Pa 1976)*. 2002;27:49–55.
- 11 Childs JD, Flynn TW, Fritz JM, Piva SR, Whitman JM, Wainner RS, et al. Screening for vertebral artery insufficiency in patients with neck pain: manual therapy decision-making in the presence of uncertainty. *J Orthop Sports Phys Ther*. 2005;35:300–6.
- 12 Coulter ID, Hurwitz EL, Adams AH, Meeker WC, Hansen DT, Mootz RD, et al. The appropriateness of spinal manipulation and mobilization of the cervical spine. Santa Monica, CA: Rand Publishing; 1996.
- 13 Shekelle PG, Hurwitz EL, Coulter I, Adams AH, Genovese B, Brook RH. The appropriateness of chiropractic spinal manipulation for low back pain: a pilot study. *J Manipulative Physiol Ther*. 1995;18:265–70.
- 14 Terrett AG. Vascular accidents from cervical spine manipulation: report on 107 cases. *J Aust Chiropr Assoc*. 1987;17:15–24.
- 15 Beatty RA. Dissecting hematoma of the internal carotid artery following chiropractic cervical manipulation. *J Trauma*. 1977;17:248–9.
- 16 Braun IF, Pinto RS, De Filipp GJ, Lieberman A, Pasternack P, Zimmerman RD. Brain stem infarction due to chiropractic manipulation of the cervical spine. *South Med J*. 1983;76:1507–10.
- 17 Braune HJ, Munk MH, Huffmann G. Cerebral infarct in the circulatory area of the arteria cerebri media following chiropractic therapy of the cervical spine. *Dtsch Med Wochenschr*. 1991;116:1047–50.
- 18 Brownson RJ, Zollinger WK, Madeira T, Fell D. Sudden sensorineural hearing loss following manipulation of the cervical spine. *Laryngoscope*. 1986;96:166–70.
- 19 Cellier P, Georget AM. Dissection of the vertebral arteries after manipulation of the cervical spine. Apropos of a case. *J Radiol*. 1984;65:191–6.
- 20 Chen WL, Chern CH, Wu YL, Lee CH. Vertebral artery dissection and cerebellar infarction following chiropractic manipulation. *Emerg Med J*. 2006;23:e1.
- 21 Chung OM. MRI confirmed cervical cord injury caused by spinal manipulation in a Chinese patient. *Spinal Cord*. 2002;40:196–9.
- 22 Cook JW, 4th, Sanstead JK. Wallenberg's syndrome following self-induced manipulation. *Neurology*. 1991;41:1695–6.
- 23 Devereaux MW. The neuro-ophthalmologic complications of cervical manipulation. *J Neuroophthalmol*. 2000;20:236–9.
- 24 Domenicucci M, Ramieri A, Salvati M, Brogna C, Raco A. Cervicothoracic epidural hematoma after chiropractic spinal manipulation therapy. Case report and review of the literature. *J Neurosurg Spine*. 2007;7:571–4.
- 25 Donovan JS, Kerber CW, Donovan WH, Marshall LF. Development of spontaneous intracranial hypotension concurrent with grade IV mobilization of the cervical and thoracic spine: a case report. *Arch Phys Med Rehabil*. 2007;88:1472–3.
- 26 Dunne JW, Conacher GN, Khangure M, Harper CG. Dissecting aneurysms of the vertebral arteries following cervical manipulation: a case report. *J Neurol Neurosurg Psychiatry*. 1987;50:349–53.
- 27 Ea HK, Weber AJ, Yon F, Liote F. Osteoporotic fracture of the dens revealed by cervical manipulation. *Joint Bone Spine*. 2004;71:246–50.
- 28 Easton JD, Sherman DG. Cervical manipulation and stroke. *Stroke*. 1977;8:594–7.
- 29 Frisoni GB, Anzola GP. Vertebrobasilar ischemia after neck motion. *Stroke*. 1991;22:1452–60.
- 30 Fritz VU, Maloon A, Tuch P. Neck manipulation causing stroke. Case reports. *S Afr Med J*. 1984;66:844–6.
- 31 Frumkin LR, Baloh RW, Wallenberg's syndrome following neck manipulation. *Neurology*. 1990;40:611–5.
- 32 Gittinger JW, Jr. Occipital infarction following chiropractic cervical manipulation. *J Clin Neuroophthalmol*. 1986;6:11–3.
- 33 Gouveia LO, Castanho P, Ferreira JJ, Guedes MM, Falcao F, e Melo TP. Chiropractic manipulation: reasons for concern? *Clin Neurol Neurosurg*. 2007;109:922–5.
- 34 Grayson M. Horner's syndrome after manipulation of the neck. *BMJ*. 1987;295:1381–2.
- 35 Heffner JE. Diaphragmatic paralysis following chiropractic manipulation of the cervical spine. *Arch Intern Med*. 1985;145:562–4.
- 36 Heiner JD. Cervical epidural hematoma after chiropractic spinal manipulation. *Am J Emerg Med*. 2009;27:1023.e1–2.
- 37 Hillier CE, Gross ML. Sudden onset vomiting and vertigo following chiropractic neck manipulation. *Postgrad Med J*. 1998;74:567–8.
- 38 Hinse P, Thie A, Lachenmayer L. Dissection of the extracranial vertebral artery: report of four cases and review of the literature. *J Neurol Neurosurg Psychiatry*. 1991;54:863–9.
- 39 Hoffelner T, Maurer-Ertl W, Kienbacher G, Radl R, Leithner A, Windhager R. Internal jugular vein thrombosis following cervical manipulation. *Man Ther*. 2009;14:706–8.
- 40 Horn SW, 2nd. The 'locked-in' syndrome following chiropractic manipulation of the cervical spine. *Ann Emerg Med*. 1983;12:648–50.
- 41 Hsieh JH, Wu CT, Lee ST. Cervical intradural disc herniation after spinal manipulation therapy in a patient with ossification of posterior longitudinal ligament: a case report and review of the literature. *Spine (Phila Pa 1976)*. 2010;35:E149–51.
- 42 Jay WM, Shah MI, Schneck MJ. Bilateral occipital-parietal hemorrhagic infarctions following chiropractic cervical manipulation. *Semin Ophthalmol*. 2003;18:205–9.
- 43 Jentzen JM, Amatuzio J, Peterson GF. Complications of cervical manipulation: a case report of fatal brainstem infarct with review of the mechanisms and predisposing factors. *J Forensic Sci*. 1987;32:1089–94.
- 44 Jeret JS, Bluth M. Stroke following chiropractic manipulation. Report of 3 cases and review of the literature. *Cerebrovasc Dis*. 2002;13:210–3.
- 45 Kanshepolksky J, Danielson H, Flynn RE. Vertebral artery insufficiency and cerebellar infarct due to manipulation of the neck. Report of a case. *Bull Los Angeles Neurol Soc*. 1972;37:62–5.
- 46 Katirji MB, Reinmuth OM, Latchaw RE. Stroke due to vertebral artery injury. *Arch Neurol*. 1985;42:242–8.
- 47 Khan AM, Ahmad N, Li X, Korsten MA, Rosman A. Chiropractic sympathectomy: carotid artery dissection with oculosympathetic palsy after chiropractic manipulation of the neck. *Mt Sinai J Med*. 2005;72:207–10.
- 48 Kraft CN, Conrad R, Vahlensieck M, Perlick L, Schmitt O, Diedrich O. Non-cerebrovascular complication in chirotherapy manipulation of cervical vertebra. *Z Orthop Ihre Grenzgeb*. 2001;139:8–11.
- 49 Krieger D, Leibold M, Bruckmann H. Dissections of the vertebral artery following cervical chiropractic manipulations. *Dtsch Med Wochenschr*. 1990;115:580–3.
- 50 Krueger BR, Okazaki H. Vertebral-basilar distribution infarction following chiropractic cervical manipulation. *Mayo Clin Proc*. 1980;55:322–32.
- 51 Kunkle EC, Muller JC, Odom GL. Traumatic brain-stem thrombosis: report of a case and analysis of the mechanism of injury. *Ann Intern Med*. 1952;36:1329–35.

- 52 Kurbanyan K, Lessell S. Intracranial hypotension and abducens palsy following upper spinal manipulation. *Br J Ophthalmol*. 2008;92:153–5.
- 53 Lennington BR, Laster DW, Moody DM, Ball MR. Traumatic pseudoaneurysm of ascending cervical artery in neurofibromatosis: complication of chiropractic manipulation. *AJNR Am J Neuroradiol*. 1980;1:269–70.
- 54 Liao CC, Chen LR. Anterior and posterior fixation of a cervical fracture induced by chiropractic spinal manipulation in ankylosing spondylitis: a case report. *J Trauma*. 2007;63:E90–4.
- 55 Lipper MH, Goldstein JH, Do HM. Brown-Sequard syndrome of the cervical spinal cord after chiropractic manipulation. *AJNR Am J Neuroradiol*. 1998;19:1349–52.
- 56 Ludwig SC, Vaccaro AR, Balderston RA, Cotler JM. Immediate quadriplegia after manipulation for bilateral cervical facet subluxation. A case report. *J Bone Joint Surg Am*. 1997;79:587–90.
- 57 Malone DG, Baldwin NG, Tomecek FJ, Boxell CM, Gaede SE, Covington CG, et al. Complications of cervical spine manipulation therapy: 5-year retrospective study in a single-group practice. *Neurosurg Focus*. 2002;13:eep1.
- 58 Mas JL, Henin D, Bousser MG, Chain F, Hauw JJ. Dissecting aneurysm of the vertebral artery and cervical manipulation: a case report with autopsy. *Neurology*. 1989;39:512–5.
- 59 Mendel T, Baranska-Gieruszczak M. Brain stem syndrome after cervical chiropractic manipulations. *Neurol Neurochir Pol*. 2001;35:695–9.
- 60 Menendez-Gonzalez M, Garcia C, Suarez E, Fernandez-Diaz D, Blazquez-Menes B. Wallenberg's syndrome secondary to dissection of the vertebral artery caused by chiropractic manipulation. *Rev Neurol*. 2003;37:837–9.
- 61 Morelli N, Gallerini S, Gori S, Chiti A, Cosottini M, Orlandi G, et al. Intracranial hypotension syndrome following chiropractic manipulation of the cervical spine. *J Headache Pain*. 2006;7:211–3.
- 62 Mueller S, Sahs AL. Brain stem dysfunction related to cervical manipulation. Report of three cases. *Neurology* 1976;26(6 Pt 1):547–50.
- 63 Murphy DR. Herniated disc with radiculopathy following cervical manipulation: nonsurgical management. *Spine J*. 2006;6:459–63.
- 64 Murthy JM, Naidu KV. Aneurysm of the cervical internal carotid artery following chiropractic manipulation. *J Neurol Neurosurg Psychiatry*. 1988;51:1237–8.
- 65 Nadgir RN, Loevner LA, Ahmed T, Moonis G, Chalela J, Slawek K, et al. Simultaneous bilateral internal carotid and vertebral artery dissection following chiropractic manipulation: case report and review of the literature. *Neuroradiology*. 2003;45:311–4.
- 66 Nyberg-Hansen R, Loken AC, Tenstad O. Brainstem lesion with coma for five years following manipulation of the cervical spine. *J Neurol*. 1978;218:97–105.
- 67 Oehler J, Gandjour J, Fiebach J, Schwab S. Bilateral vertebral artery dissection after chiropractic treatment. *Orthopade*. 2003;32:911–3.
- 68 Oppenheim JS, Spitzer DE, Segal DH. Nonvascular complications following spinal manipulation. *Spine J*. 2005;5:660–6.
- 69 Padua L, Padua R, Lo Monaco M, Tonali PA. Radiculomedullary complications of cervical spinal manipulation. *Spinal Cord*. 1996;34:488–92.
- 70 Panagariya A, Kumawat BL, Singh R, Sukhani P. Total unilateral medullary syndrome — a rare complication of chiropractic manipulation. *J Assoc Physicians India*. 2004;52:556.
- 71 Parenti G, Orlandi G, Bianchi M, Renna M, Martini A, Murri L. Vertebral and carotid artery dissection following chiropractic cervical manipulation. *Neurosurg Rev*. 1999;22:127–9.
- 72 Parkin PJ, Wallis WE, Wilson JL. Vertebral artery occlusion following manipulation of the neck. *N Z Med J*. 1978;88:441–3.
- 73 Parwar BL, Fawzi AA, Arnold AC, Schwartz SD. Horner's syndrome and dissection of the internal carotid artery after chiropractic manipulation of the neck. *Am J Ophthalmol*. 2001;131:523–4.
- 74 Patel A, Lee R, Fritz W, Matos E, Freeman JW. Vertebral artery dissection from cervical spine manipulation: case reports and analysis. *dS D Med*. 2008;61:95, 7–9.
- 75 Peters M, Bohl J, Thomke F, Kallen KJ, Mahlzahn K, Wandel E, et al. Dissection of the internal carotid artery after chiropractic manipulation of the neck. *Neurology*. 1995;45:2284–6.
- 76 Phillips SJ, Maloney WJ, Gray J. Pure motor stroke due to vertebral artery dissection. *Can J Neurol Sci*. 1989;16:348–51.
- 77 Povlsen UJ, Kjaer L, Arlien-Soborg P. Locked-in syndrome following cervical manipulation. *Acta Neurol Scand*. 1987;76:486–8.
- 78 Powell FC, Hanigan WC, Olivero WC. A risk/benefit analysis of spinal manipulation therapy for relief of lumbar or cervical pain. *Neurosurgery*. 1993;33:73–8.
- 79 Prasad S, El-Haddad G, Zhuang H, Khella S. Intracranial hypotension following chiropractic spinal manipulation. *Headache*. 2006;46:1456–8.
- 80 Pribek RA. Brain stem vascular accident following neck manipulation. *Wis Med J*. 1963;62:141–3.
- 81 Putnam TD, Wu Y. Tracheal rupture following cervical manipulation: late complication posttracheostomy. *Arch Phys Med Rehabil*. 1986;67:48–50.
- 82 Quintana JG, Drew EC, Richtsmeier TE, Davis LE. Vertebral artery dissection and stroke following neck manipulation by Native American healer. *Neurology*. 2002;58:1434–5.
- 83 Raskind R, North CM. Vertebral artery injuries following chiropractic cervical spine manipulation — case reports. *Angiology*. 1990;41:445–52.
- 84 Rinsky LA, Reynolds GG, Jameson RM, Hamilton RD. A cervical spinal cord injury following chiropractic manipulation. *Paraplegia*. 1976;13:223–7.
- 85 Schellhas KP, Latchaw RE, Wendling LR, Gold LH. Vertebrobasilar injuries following cervical manipulation. *JAMA*. 1980;244:1450–3.
- 86 Schmitz A, Lutterbey G, von Engelhardt L, von Falkenhausen M, Stoffel M. Pathological cervical fracture after spinal manipulation in a pregnant patient. *J Manipulative Physiol Ther*. 2005;28:633–6.
- 87 Schram DJ, Vosik W, Cantral D. Diaphragmatic paralysis following cervical chiropractic manipulation: case report and review. *Chest*. 2001;119:638–40.
- 88 Sedat J, Dib M, Mahagne MH, Lonjon M, Paquis P. Stroke after chiropractic manipulation as a result of extracranial postero-inferior cerebellar artery dissection. *J Manipulative Physiol Ther*. 2002;25:588–90.
- 89 Segal DH, Lidov MW, Camins MB. Cervical epidural hematoma after chiropractic manipulation in a healthy young woman: case report. *Neurosurgery*. 1996;39:1043–5.
- 90 Sherman MR, Smialek JE, Zane WE. Pathogenesis of vertebral artery occlusion following cervical spine manipulation. *Arch Pathol Lab Med*. 1987;111:851–3.
- 91 Sinel M, Smith D. Thalamic infarction secondary to cervical manipulation. *Arch Phys Med Rehabil*. 1993;74:543–6.
- 92 Sivakumaran P, Wilsher M. Diaphragmatic palsy and chiropractic manipulation. *N Z Med J*. 1995;108:279–80.
- 93 Smith RA, Estridge MN. Neurologic complications of head and neck manipulations. *JAMA*. 1962;182:528–31.
- 94 Soper JR, Parker GD, Hallinan JM. Vertebral artery dissection diagnosed with CT. *AJNR Am J Neuroradiol*. 1995;16(4 Suppl):952–4.
- 95 Sturzenegger M. Vertebral artery dissection following manipulation of the cervical vertebrae. *Schweiz Med Wochenschr*. 1993;123:1389–99.
- 96 Suh SI, Koh SB, Choi EJ, Kim BJ, Park MK, Park KW, et al. Intracranial hypotension induced by cervical spine chiropractic manipulation. *Spine (Phila Pa 1976)*. 2005;30:E340–2.
- 97 Tinel D, Bliznakova E, Juhel C, Gallien P, Brissot R. Vertebrobasilar ischemia after cervical spine manipulation: a case report. *Ann Readapt Med Phys*. 2008;51:403–14.
- 98 Tolge C, Iyer V, McConnell J. Phrenic nerve palsy accompanying chiropractic manipulation of the neck. *South Med J*. 1993;86:688–90.
- 99 Tseng SH, Chen Y, Lin SM, Wang CH. Cervical epidural hematoma after spinal manipulation therapy: case report. *J Trauma*. 2002;52:585–6.
- 100 Tseng SH, Lin SM, Chen Y, Wang CH. Ruptured cervical disc after spinal manipulation therapy: report of two cases. *Spine (Phila Pa 1976)*. 2002;27:E80–2.
- 101 Vibert D, Rohr-Le Floch J, Gauthier G. Vertigo as manifestation of vertebral artery dissection after chiropractic neck manipulations. *ORL J Otorhinolaryngol Relat Spec*. 1993;55:140–2.
- 102 Wang JL, Lin JJ, Lin JC, Lie CC, Shih TP, Tsao WL. Vertebral artery dissection complicated by cervical manipulation: a case

- report. *Zhonghua Yi Xue Za Zhi (Taipei)*. 1995; 55:496–500.
- 103 Weintraub MI. Dormant foramen magnum meningioma 'activated' by chiropractic manipulation. *N Y State J Med*. 1983;83:1039–40.
 - 104 Whedon JM, Quebada PB, Roberts DW, Radwan TA. Spinal epidural hematoma after spinal manipulative therapy in a patient undergoing anticoagulant therapy: a case report. *J Manipulative Physiol Ther*. 2006;29:582–5.
 - 105 Wood MJ, Lang EK, Woolhandler GJ, Faludi HK. Traumatic vertebral artery thrombosis. *J La State Med Soc*. 1971;123: 413–4.
 - 106 Young YH, Chen CH. Acute vertigo following cervical manipulation. *Laryngoscope*. 2003;113:659–62.
 - 107 Zupruk GM, Mehta Z. Brown-Sequard syndrome associated with posttraumatic cervical epidural hematoma: case report and review of the literature. *Neurosurgery*. 1989;25:278–80.
 - 108 Thomas LC, Rivett DA, Attia JR, Parsons M, Levi C. Risk factors and clinical features of craniocervical arterial dissection. *Man Ther*. 2011;16:351–6.
 - 109 Bolton PS, Stick PE, Lord RS. Failure of clinical tests to predict cerebral ischemia before neck manipulation. *J Manipulative Physiol Ther*. 1989;12:304–7.
 - 110 Thiel H, Rix G. Is it time to stop functional pre-manipulation testing of the cervical spine? *Man Ther*. 2005;10:154–8.
 - 111 Westaway MD, Stratford P, Symons B. False-negative extension/rotation pre-manipulative screening test on a patient with an atretic and hypoplastic vertebral artery. *Man Ther*. 2003;8:120–7.
 - 112 Kerry R, Taylor AJ, Mitchell J, McCarthy C, Brew J. Manual therapy and cervical arterial dysfunction, directions for the future: a clinical perspective. *J Man Manipulative Ther*. 2008;16:39–48.
 - 113 Kerry R, Taylor AJ, Mitchell J, McCarthy C. Cervical arterial dysfunction and manual therapy: a critical literature review to inform professional practice. *Man Ther*. 2008;13:278–88.
 - 114 Haldeman S, Kohlbeck FJ, McGregor M. Stroke, cerebral artery dissection, and cervical spine manipulation therapy. *J Neurol*. 2002;249:1098–104.
 - 115 Thiel HW, Bolton JE, Docherty S, Portlock JC. Safety of chiropractic manipulation of the cervical spine: a prospective national survey. *Spine (Phila Pa 1976)*. 2007;32:2375–8.
 - 116 Cagnie B, Vinck E, Beernaert A, Cambier D. How common are side effects of spinal manipulation and can these side effects be predicted? *Man Ther*. 2004;9:151–6.
 - 117 Senstad O, Leboeuf-Yde C, Borchgrevink C. Frequency and characteristics of side effects of spinal manipulative therapy. *Spine (Phila Pa 1976)*. 1997;22:435–40.
 - 118 Ernst E. Prospective investigations into the safety of spinal manipulation. *J Pain Symptom Manage*. 2001;21:238–42.
 - 119 Schwartz NE, Vertinsky AT, Hirsch KG, Albers GW. Clinical and radiographic natural history of cervical artery dissections. *J Stroke Cerebrovasc Dis*. 2009;18:416–23.
 - 120 Austin N, DiFrancesco LM, Herzog W. Microstructural damage in arterial tissue exposed to repeated tensile strains. *J Manipulative Physiol Ther*. 2010;33:14–9.
 - 121 Mintken PE, Derosa C, Little T, Smith B. A model for standardizing manipulation terminology in physical therapy practice. *J Man Manip Ther*. 2008;16:50–6.