

Prevalence of hip pathology in patients over age 50 with spinal conditions requiring surgery

Byung Ho Lee, Seong Hwan Moon, Hwan Mo Lee, Tae Hwan Kim, Seung Ju Lee

ABSTRACT

Background: The objective of this study was to evaluate of prevalence of co-existing spine and hip disease using initial screening kidney–ureter–bladder (KUB) radiograph in patients over 50 who underwent spinal surgery.

Materials and Methods: The study subjects were 388 patients (male: female=117:271; mean age 62.0 years) who underwent spinal surgery between 2008 and 2010. We retrospectively reviewed the initial KUB radiographs used to diagnose the spine and hip disease. Depending on the extent of acetabular and hip joint visualization in KUB, we divided the subjects into three groups: Acetabulum, hip joint, and femoral neck visualization. The hip visualization rate was also assessed with respect to patient height. χ^2 and logistic regression test were used for statistical analysis.

Results: 126 (32.5%) cases had significant hip pathology including hip osteoarthritis (Kellgren/Lawrence grade 3 in 123 cases, grade 4 in 3 cases) and avascular necrosis (1 case each of Ficat stage IIA and IIB), and 8 cases had other morphologic abnormalities. Regarding acetabulum–hip visualization in KUB, 7 (1.8%) cases had acetabulum visualization only, 16 (4.1%) had hip joint visualization, and 365 (94.1%) had femoral neck including lesser trochanter visualization. Patients were categorized into four groups according to height (less than 150 cm, 150–159 cm, 160–169 cm, greater than 170 cm). The hip visualization rates differed significantly among these four groups ($P<0.05$).

Conclusions: The prevalence of discernible hip pathology in patients who underwent spinal surgery was 32.5%. Hip joint visualization was excellent (98.2%) in KUB radiographs. Hence, spinal surgeons should pay attention to hip pathology in surgically indicated spinal patients.

Key words: Hip pathology, spinal surgery, elderly

INTRODUCTION

The lower back pain, pelvic pain, and leg pain are common occurrence in aging patients and, careful scrutiny to achieve definitive diagnosis of the origin of the pain, such as spondylogenic, coxogenic, or both is mandatory. Comorbidity of spine and hip conditions sometimes results in misdiagnosis or delayed diagnosis.¹

The purposes of this study were to assess the prevalence of hip pathology in patients who underwent spinal surgery and to test the diagnostic efficiency of conventional plain radiography of the kidney–ureter–bladder (KUB) to detect hip pathology.

MATERIALS AND METHODS

Between 2008 and 2010, 388 patients who had low back pain with or without pain in the lower extremities were enrolled in this study. This study was approved by the Institutional Review Board (IRB No. 4-2010-0615). All patients underwent spinal surgery for corresponding spinal conditions. After collecting medical history and performing a physical examination, diagnostic image tests such as KUB and lumbosacral lateral radiographs were performed in each supine and lateral decubitus position using a 14 × 17 inch cassette according to Rowe and Yohum’s technique.² Then, in all surgically indicated patients, magnetic resonance imaging (MRI) of the spine was performed. We retrospectively reviewed the corresponding 388 medical records to retrieve basic information of the patients. The rate and extent of visualization of both hip

Department of Orthopedic Surgery, Yonsei University College of Medicine, Seoul, Korea

Address for correspondence: Dr. Seong Hwan Moon, Department of Orthopedic Surgery, Severance Hospital, Yonsei University College of Medicine, 250 Seongsanno (134 Sinchon-dong), Seodaemun-gu, Seoul 120-752, South Korea.
E-mail: shmoon@yuhs.ac

Access this article online	
Quick Response Code:	Website: www.ijonline.com
	DOI: 10.4103/0019-5413.96386

joints was assessed using KUB radiographs. To assess the extent of hip joint visualization, we divided the subjects into three groups depending on the extent of acetabular and hip joint visualization: acetabulum, hip joint, and femoral neck including lesser trochanter visualization [Figure 1a–c]. The hip visualization rate was also assessed with respect to patient's height.

In cases with any hip pathology according to the radiograph, possible diagnoses were made by two separate co-working hip surgeons. In cases of hip osteoarthritis and avascular necrosis of the femoral head, the Kellgren/Lawrence (K/L) scale and Ficat stage were used, respectively.^{3,4} The inter-observer correlation coefficient (*r*) was 0.91. Furthermore, based on the hypothesis that patient trunk height might affect the visualization rate or extent of the hip joints because KUB uses a standard sized radiographic cassette (14 × 17 inch), patients were categorized into four groups according to height. The statistical differences among groups were evaluated using the χ^2 and logistic regression test, and all *P* < 0.05 were considered significant.

RESULTS

The 388 patients consisted of 117 males and 271 females with an average age of 62.0 ± 7.9 years, ranging from 50 to 87 years (males 63.0 ± 8.0 years, range 50–87; females 61.5 ± 7.9 years, range 50–86) [Figure 2]. The average patient height was 157.8 ± 8.8 cm, with a range of 120–183 cm (males 166.7 ± 6.9 cm, range 130–183; females 154.0 ± 6.5 cm, range 120–180). Of these, most patients (377 cases, 97.2%) presented with lower back pain and leg pain and the remainder (11 cases, 2.8%) complained of lower back pain only. Distribution of patients according to symptom duration was quite heterogeneous, ranging from 0.1 to 360 months (mean duration 43.4 ± 58.2 months).

The major diagnoses were spinal stenosis (*n*=282, 72.7%), spondylolisthesis (*n*=51, 13.1%), and herniated nucleus pulposus (*n*=35, 9.0%), although 22 cases (5.6%) had other diagnoses. Twenty-eight patients had undergone previous spinal surgery. Patient treatments included posterolateral fusion (*n*=250, 64.4%), decompression (*n*=66, 17.0%), discectomy (*n*=21, 5.4%), posterolumbar interbody fusion (*n*=44, 11.3%) and other treatments (*n*=7, 1.8%) [Table 1].

The results of radiologic investigation for hip arthropathy showed that 126 (32.5%) cases had significant hip disease including hip osteoarthritis (123 cases of KL grade 3 and 3 cases of grade 4) and avascular necrosis of the femoral heads (1 case each of Ficat stage IIA and stage IIB). Other morphologic abnormalities were seen in eight cases, including five cases of coxa valga and three cases of other hip dysplasia [Figure 3].

Table 1: Diagnoses and type of surgery treatments of enrolled patients

Diagnoses	n (%)	Type of surgery	n (%)
Spinal stenosis	282 (72.7) cases	Posterolateral fusion	250 (64.4) cases
Spondylolisthesis	51 (13.1) cases	Decompression	66 (17.0) cases
Herniated nucleus pulposus	35 (9.0) cases	Posterior lumbar interbody fusion	44 (11.3) cases
Infection	8 (2.1) cases	Discectomy	21 (5.4) cases
Fracture	8 (2.1) cases	Incision and drainage	2 (0.5) cases
Cancer	2 (0.5) cases	Circumferential fusion	2 (0.5) cases
Deformity	2 (0.5) cases	Anterior interbody fusion	2 (0.5) cases
		Hardware removal	1 (0.3) cases
Total	388 (100) cases		388 (100) cases

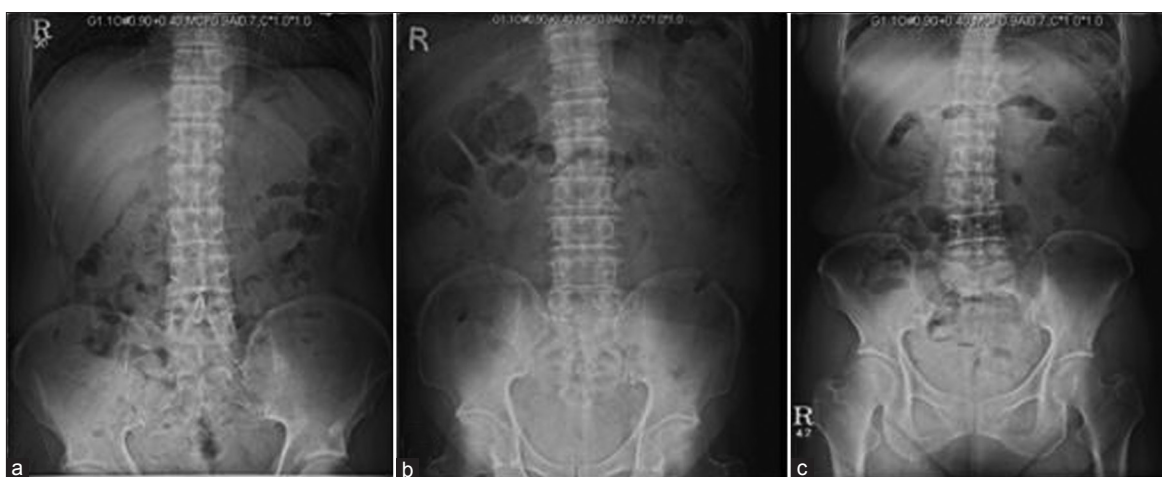

Figure 1: KUB lumbar spine AP and radiographic grades. (a) Acetabulum visualization: Entire (partial) acetabula are visible. (b) Hip joint visualization: Entire acetabula and femoral head areas are visible. (c) Femoral neck including lesser trochanter visualization: Entire hip joints including femoral necks and lesser trochanter areas are visible

The severity of osteoarthritic hip joints differed significantly depending on age ($P=0.05$, logistic regression), with older patients exhibiting more advanced osteoarthritis [Figure 4].

Regarding radiographic grade, 7 (1.8%) cases were classified as acetabular visualization, 16 (4.1%) as hip joint visualization, and 365 (94.1%) as femoral neck including lesser trochanter visualization. The extent of hip visualization showed statistically significant differences among the four groups categorized by height according to the χ^2 test ($P<0.05$) and logistic regression tests ($P=0.05$, logistic regression). In the two tallest groups (160–169 cm and greater than 170 cm), higher percentages of acetabular visualization and hip joint visualization were observed [Table 2, Figure 5].

The rate of complete visualization of the lumbar spine and hip joint in single plain KUB was 98.2%, as determined by the sum of hip joint visualization and femoral neck visualizations (381 of 388 cases). Most patients with hip pathology were followed up by a hip reconstructive surgeon. Additionally, the Patrick test was not effective to

detect hip pathologic condition [Table 3]. The sensitivity was heterogeneous (0–33.3%) depending on the disease status. Four patients underwent total hip replacement based on the priority to treat hip and spine disease; the others were treated conservatively [Table 4].

DISCUSSION

A recent increase in life expectancy in the general population makes musculoskeletal diseases in elderly people to

Table 2: Comparison of visualization rates among the four height groups

	<150 cm	150–159 cm	160–169 cm	>170 cm	Total
Acetabula	0	2	1	4	7
Hip joints	1	5	7	3	16
Femoral neck including lesser trochanter	60	162	108	35	365
Total	61	169	116	42	388

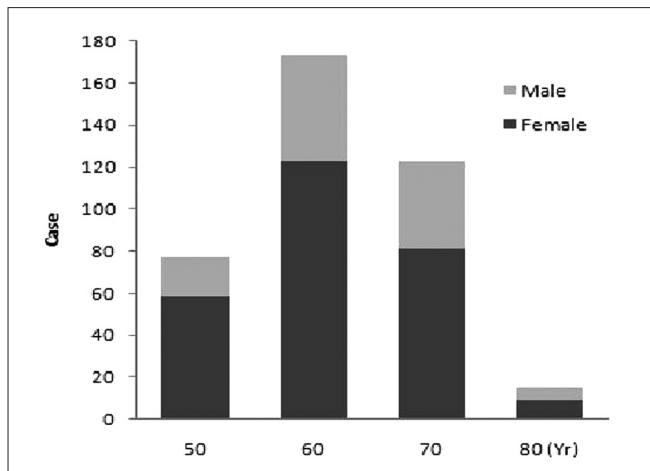


Figure 2: Composition of patient groups according to age and gender

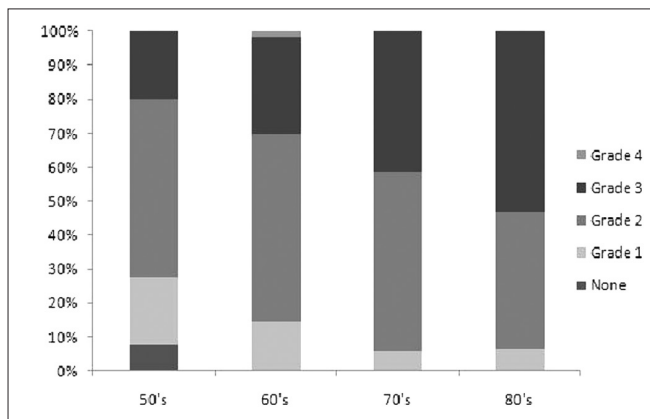


Figure 4: Distribution of hip osteoarthritis according to age. Older patients had greater progression of osteoarthritis ($P<0.05$, χ^2 ; $P=0.05$, logistic regression)

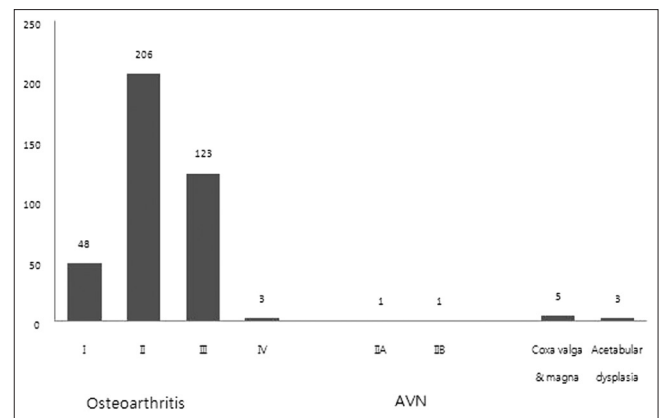


Figure 3: Hip pathologies detected on KUB lumbar anteriorposterior X-rays. In cases of hip osteoarthritis and avascular necrosis of the femoral head, the Kellgren/Lawrence (K/L) scale⁶ and Ficat stage⁷ were used. AVN, avascular necrosis

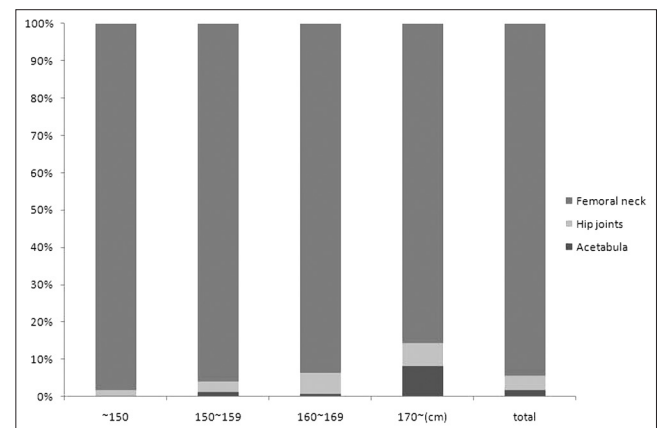


Figure 5: The distribution of the extents of radiographic visualization in the four height groups. The percentages of acetabula visualization and hip joint visualization increased with height ($P<0.05$, χ^2 ; $P=0.05$, logistic regression)

become major challenges for orthopedic surgeons.⁵ Hip and spine arthritis in the aged population is part of the same degenerative process and coexist.⁶ Co-existence of spine and hip pathologies, especially in patients who are indicated for lumbar spinal surgery, prompts spinal surgeons to evaluate the exact source of pain to avoid jeopardizing the surgical outcomes. Therefore, statistics regarding the prevalence of hip pathology in surgically indicated spinal patients are needed.

Furthermore, to rule out spine and hip conditions in the initial screening radiograph, separate lumbar spine and pelvis plain radiographs can be commonly conducted; however, this extra step increases medical costs and radiation exposures of the patients. Evaluation of the diagnostic efficiency of screening spine radiographs for visualization is therefore also needed. Therefore, we tried to assess the prevalence of hip pathology in patients who underwent spinal surgery and to test the diagnostic efficiency of conventional plain radiography of the KUB to visualize hip joints and detect hip pathology.

The differentiation of signs and symptoms suggestive of hip disorder versus spine disorder is important in order to provide proper treatment, especially when the patient has pain associated with both hip and spine disorders. Patients with osteoarthritis of the hip may present with radiating

pain below the knee, back pain, and limited internal rotation of the hip, creating difficulty in the determination of spine versus hip etiology.⁷ Various physical examination maneuvers have been described to localize the pain source, but most of these have been shown to have either poor inter-observer reproducibility or validity.⁸ Also, patients in severe or chronic pain may report pain aggravation with almost any maneuver, thus decreasing the specificity of the test.⁹

Several studies have shown that decompression in patients with spine disorders does not alleviate pain if hip arthrosis is also present.¹⁰ In some patients, treatment of one disorder has led to the development of another disorder, for example, development of foot drop secondary to spinal pathology after hip arthroplasty.¹¹ Thus necessitating lumbar decompression. A study by McNamara *et al.* reported patients with concurrent hip disease and spinal stenosis who initially underwent hip arthroplasty, followed by decompression of spinal stenosis.¹² The results showed that eight of nine patients who had decompression reported good or excellent subjective relief of symptoms at their final followup visit.¹² The order of treatment for pain depends on the presence of neurologic symptoms and sequelae or the presence of a fixed flexion contracture and absence of neurologic deficits.¹³ In our series, two patients were diagnosed with simultaneous spinal stenosis and avascular necrosis of the femoral heads. Both underwent spinal surgery first because of spine-originated neurologic symptoms and then underwent total hip arthroplasties as the avascular necrosis progressed. They had favorable outcomes at their final followups in July 2010 and December 2008.

Thus, it should be emphasized that a definitive differential diagnosis and identification of the anatomic source of pain is most important for selecting the proper therapeutic modality. Nevertheless, correct diagnosis based on patient history, physical examination, and simple radiography is sometimes difficult, particularly in the presence of a significant spinal disorder. Several signs and symptoms such as limp, groin pain, limited internal rotation, and reduced spinal range of motion (ROM) have been associated with low back and leg pain.^{13,14} Other possible, but presumably less common,

Table 3: The Patrick test results under the hip pathologic condition at spinal operation

	Osteoarthritis grade					AVN	Total
	None	1.00	2.00	3.00	4.00		
Patrick test							
Positive	1	1	9	5	1	0	17
Count	16.7	2.1	4.4	4.1	33.3%	0	4.4%
% within case							
Negative	5	47	197	118	2	2	371
Count	83.3	97.9	95.6	95.9	67.7	100%	95.6%
% within case							
Total	6	48	206	123	3	2	388
Count	100.0	100.0	100.0	100.0	100.0%	100.0%	100.0%
% within case							

Table 4: Patients who underwent hip surgery after a spinal operation

Case	Age/gender	CC	Dx (spine)	Operation (date)	Dx (hip)	Treatment
1*	63/F	LBP with bilateral radiating pain→postoperative both hip pain	SS	PLF (27/11/2006)	AVN, both (known, Ficat IIA)	THR, both (14/12/2007)
2	65/F	LBP with bilateral radiating pain	SS	PLF (04/09/2007)	Both THR state (1990 and 2004)	Revisional THR (18/06/2010) due to loosened acetabular component
3†	63/F	LBP with bilateral radiating pain→postoperative Lt hip pain	SS	PLF (10/05/2007)	AVN, Lt (new)	THR performed at other hospital
4*	54/M	Pain in both buttocks→postoperative Rt thigh pain	SS	PLF (07/12/2006)	AVN, Rt (known, Ficat IIB)	THR, Rt (24/10/2008)

*For patients with known hip disease, the order of treatment was determined based on patient symptoms. †Case No. 3 had newly developed hip lesions 3 months postoperative. CC - Chief complaint, LBP - Low back pain, SS - Spinal stenosis, PLF - Posterolateral fusion, AVN - Avascular necrosis. THR - Total hip replacement, Dx - Diagnosis

origins of pain are the retroperitoneal structures within the abdominal and pelvic cavities. Antolak *et al.* reported that ureter stones could chronically compress and irritate the L2–4 sensory fibers, either part of the obturator or femoral nerve, around the psoas muscle and cause medical thigh pains.¹⁵ Pain may also arise from the sacroiliac joint.^{16–18}

Consequently, all small clues should receive attention in order to avoid missing or overlooking important signs that differentiate the most common co-existing diseases. It is useful to take plain radiographs for initial screening of hip and spine disease and to detect the additional rare possibility of urolithiasis. However, plain radiographs may be unable to detect early stages of disease or other intra-articular pathologies such as a labral tear or chondral lesions. In the absence of arthritic changes in the setting of positive physical examination findings, patients could undergo assessment of intra-articular pathologies such as a labral tear.¹⁹ One of our cases had collection of hip joint fluid that could not be detected via plain radiographs and lumbar spine MRI. She had aggravating pain for 10 years in both buttocks and radiculopathy in the left lower extremity. The diagnosis was degenerative spondylolisthesis L3 on L4. After decompression and fusion at the L3–4 area, she experienced some improvement in her symptoms (preoperative Oswestry Disability Index score 22 decreased to 13 postoperatively) but complained of continued left hip pain. The MRI of left hip showed hip effusion and she responded to the additional medical treatment.

Since 1983, when Offierski and MacNab discussed the significance of the relationship between the spine and hip joints, described as hip spine syndrome,²⁰ many authors have studied their inter-related pathologies.^{21–24} Therefore, the inextricable connection between the hip and spine should be considered in relevant cases. One of the purposes of this study was to increase surgeons' levels of awareness of the co-existence of spine hip diseases and the importance of order of treatment for these two conditions. Therefore, we chose a group of patients who had undergone surgery for spinal disease to determine whether there were any cases that inevitably required another operation on their hip and/or other pain source due to the incorrect initial diagnosis or order of treatment. Fortunately, our study population contained no such cases because of easiness in patients' referral between the hip and spine department in our clinic.

Another purpose of the study was to increase diagnostic convenience for both physicians and patients. So far, we have taken both KUB and pelvis anteroposterior radiographs at once for initial imaging study. But in the

aspect of saving medical expenses and avoiding additional radiation exposure, although KUB X-rays may not be valuable as confirmatory diagnostic tools for hip diseases, we hypothesized that they are sufficiently useful to visualize and diagnose hip joint problems. In our study, visualization of the hip joint was sufficient to evaluate hip pathology in 381 (98.2%) cases. During the followup period, the patients who were classified as acetabula visualization on their first screening KUB could be classified as hip joint or femoral neck including lesser trochanter visualization on their followup films. Among 11 cases of acetabula visualization, 5 cases could be classified as hip joint and femoral neck including lesser trochanter visualization. This indicated that a standardized methodology of KUB X-rays might increase the effectiveness of KUB as a screening test, especially as there are variations in the procedure depending on the radiographer.

Hip arthritis is a much lesser common condition in comparison to low back pain, afflicting only 3.2% of the population older than 55 years, which is disabling enough to warrant joint arthroplasty in some patients.²⁵ The results of the current study demonstrated that the prevalence of comorbid hip pathology in patients with spine conditions who underwent spinal surgery was 32.5%. All of them were not severe enough to undergo total hip arthroplasty. Also, not all patients were symptomatic on their hip, as the Patrick tests were positive only for 4.4% of pathologic hip conditions. But we archived some useful information of hip pathology rate in patients who underwent lumbar spine surgery.

Furthermore, we showed that a simple KUB radiograph can provide visualization of the hip joint at a rate of 98.2%, sufficiently high to rule out hip pathology, although in rare cases (1.8%), the hip joint was not included in the simple KUB radiograph. Nonvisualization of the hip joint in the KUB radiograph mandates an additional radiographic examination of the hip joint due to the high prevalence of hip pathology in patients with spinal conditions. The limitation of the present study is that we have focused on the radiographic evaluation of hip pathology using single radiograph without correlating the pathologic condition with the surgical outcome of the patients. In future, we will try to investigate the clinical correlation of hip pathologic condition with the surgical outcome.

In conclusion, we found discernible hip pathology on KUB in 32.5% of the patients who underwent spinal surgery. The diagnostic efficiency of conventional plain radiograph of KUB in the detection of hip pathology was sufficient (98.2%) for it to be used as an initial screening test for diseases of the spine and hip, as well as other possible diseases.

REFERENCES

1. Swezey RL. Overdiagnosed sciatica and stenosis, underdiagnosed hip arthritis. *Orthopedics* 2003;26:173-4.
2. Rowe LJ, Yochum TR. Radiographic positioning and normal anatomy. In Yochum TR, Rowe LJ eds. *Essentials of skeletal radiology*. 2nd ed. Baltimore: Williams and Wilkins; 1996. p. 1-138.
3. Kellgren JH, Lawrence JS. Radiological assessment of osteo-arthrosis. *Ann Rheum Dis* 1957;16:494-502.
4. Ficat RP. Idiopathic bone necrosis of the femoral head. Early diagnosis and treatment. *J Bone Joint Surg Br* 1985;67:3-9.
5. Baek GH. Are we prepared for geriatric orthopedics?. *Clin Orthop Surg* 2010;2:129.
6. Parvizi J, Pour AE, Hillibrand A, Goldeberg G, Sharkey PF, Rothman RH. Back pain and total hip arthroplasty: A prospective natural history study. *Clin Orthop Relat Res* 2010;468:1325-30.
7. Wolfe F. Determinants of WOMAC function, pain and stiffness scores: Evidence for the role of low back pain, symptom counts, fatigue and depression in osteoarthritis, rheumatoid arthritis and fibromyalgia. *Rheumatology* 1999;38:355-61.
8. Stuber KJ. Specificity, sensitivity, and predictive values of clinical tests of the sacroiliac joint: A systematic review of the literature. *J Can Chiropr Assoc* 2007;51:30-41.
9. Waddell G, McCulloch JA, Kummel E, Venner RM. Nonorganic physical signs in low-back pain. *Spine* 1980;5:117-25.
10. Airaksinen O, Herno A, Turunen V, Saari T, Suomlainen O. Surgical outcome of 438 patients treated surgically for lumbar spinal stenosis. *Spine* 1997;22:2278-82.
11. Pritchett JW. Lumbar decompression to treat foot drop after hip arthroplasty. *Clin Orthop Relat Res* 1994:173-7.
12. McNamara MJ, Barrett KG, Christie MJ, Spengler DM. Lumbar spinal stenosis and lower extremity arthroplasty. *J Arthroplasty* 1993;8:273-7.
13. Brown MD, Gomez-Marin O, Brookfield KF, Li PS. Differential diagnosis of hip disease versus spine disease. *Clin Orthop Relat Res* 2004:280-4.
14. Steultjens MP, Dekker J, van Baar ME, Oostendorp RA, Bijlsma JW. Range of joint motion and disability in patients with osteoarthritis of the knee or hip. *Rheumatology* 2000;39:955-61.
15. Antolak C, Canales B, Monga M. Medial thigh pain: Neurology or urology? *Urology* 2005;65:799.
16. Sembrano JN, Polly DW Jr. How often is low back pain not coming from the back? *Spine* 2009;34: E27-32.
17. Fortin JD, Aprill CN, Ponthieux B, Pier J. Sacroiliac joint: Pain referral maps upon applying a new injection/arthrography technique. Part II: Clinical evaluation. *Spine* 1994;19:1483-9.
18. Dreyfuss P, Michaelsen M, Pauza K, McLarty J, Boqdok N. The value of medical history and physical examination in diagnosing sacroiliac joint pain. *Spine (Phila Pa 1976)* 1996;21:2594-602.
19. Toomayan GA, Holman WR, Major NM, Kozlowicz SM, Vali TP. Sensitivity of MR arthrography in the evaluation of acetabular labral tears. *AJR Am J Roentgenol* 2006;86:449-53.
20. Offierski CM, MacNab I. Hip-spine syndrome. *Spine (Phila Pa 1976)* 1983;8:316-21.
21. Yoshimoto H, Sato S, Masuda T, Kanno T, Shundo M, Hyakumachi T, *et al.* Spinopelvic alignment in patients with osteoarthritis of the hip: A radiographic comparison to patients with low back pain. *Spine(Phila Pa 1976)* 2005;30:1650-7.
22. Itoi E. Roentgenographic analysis of posture in spinal osteoporotics. *Spine (Phila Pa 1976)* 1991;16:750-6.
23. Matsuyama Y, Hasegawa Y, Yoshihara H, Tsuji T, Sakai Y, Nakamura H, *et al.* Hip-spine syndrome: Total sagittal alignment of the spine and clinical symptoms in patients with bilateral congenital hip dislocation. *Spine (Phila Pa 1976)* 2004;29:2432-7.
24. Ben-Galim P, Ben-Galim T, Rand N, Haim A, Hipp J, Dekel S, *et al.* Hip-spine syndrome: The effect of total hip replacement surgery on low back pain in severe osteoarthritis of the hip. *Spine (Phila Pa 1976)* 2007;32:2099-102.
25. Fear J, Hillman M, Chamberlain MA, Tennant A. Prevalence of hip problems in the population aged 55 years and over: Access to specialist care and future demand for hip arthroplasty. *Br J Rheumatol* 1997;36:74-6.

How to cite this article: Lee BH, Moon SH, Lee HM, Kim TH, Lee SJ. Prevalence of hip pathology in patients over age 50 with spinal conditions requiring surgery. *Indian J Orthop* 2012;46:291-6.

Source of Support: Nil, **Conflict of Interest:** None.