

DOI: 10.3201/eid1704.101010

Suggested citation for this article: Hughes CM, Blythe D, Yu L, Ramani R, Jordan C, Edwards C, et al. Vaccinia virus infections in martial arts gym, Maryland, USA, 2008. *Emerg Infect Dis.* 2011 Apr; [Epub ahead of print]

Vaccinia Virus Infections in Martial Arts Gym, Maryland, USA, 2008

Christine M. Hughes,¹ David Blythe,¹ Yu Li, Ramani Reddy, Carol Jordan, Cindy Edwards, Celia Adams, Holly Conners, Catherine Rasa, Sue Wilby, Jamaal Russell, Kelly S. Russo, Patricia Somsel, Danny L. Wiedbrauk, Cindy Dougherty, Christopher Allen, Mike Frace, Ginny Emerson, Victoria A. Olson, Scott K. Smith, Zachary Braden, Jason Abel, Whitney Davidson, Mary Reynolds, and Inger K. Damon

Author affiliations: Centers for Disease Control and Prevention, Atlanta, Georgia, USA (C.M. Hughes, Y. Li, C. Dougherty, C. Allen, M. Frace, G. Emerson, V.A. Olson, S.K. Smith, Z. Braden, J. Abel, W. Davidson, M. Reynolds, I.K. Damon) ; Maryland Department of Health and Mental Hygiene, Baltimore, Maryland, USA (D. Blythe); Maximed Associates, Silver Spring, Maryland, USA (R. Reddy); Montgomery County Department of Health and Human Services, Silver Spring (C. Jordan, C. Edwards, C. Adams, H. Conners, C. Rasa, S. Wilby, J. Russell, K.S. Russo); Michigan Department of Community Health, Lansing, Michigan, USA (P. Somsel); and Warde Medical Laboratory, Ann Arbor, Michigan, USA (D. Wiedbrauk)

¹These authors contributed equally to this article.

Vaccinia virus is an orthopoxvirus used in the live vaccine against smallpox. Vaccinia virus infections can be transmissible and can cause severe complications in those with weakened immune systems. We report on a cluster of 4 cases of vaccinia virus infection in Maryland, USA, likely acquired at a martial arts gym.

Vaccinia virus (VACV) is the virus used in the live vaccine against smallpox. Smallpox was declared eradicated by the World Health Organization in 1980 (*1*), and routine childhood smallpox vaccination ceased after 1972 in the United States. Since 2002, smallpox vaccinations have again been administered to some military personnel and health care workers, and they continue to be recommended for laboratory workers who work with nonattenuated

orthopoxviruses (2). VACV infections are transmissible and can cause severe complications in those with weakened immune systems (3). We report a cluster of community-acquired VACV infections at a martial arts gym in Maryland, USA.

Case-Patients

In July 2008, the Michigan Department of Community Health (MDCH) Bureau of Laboratories reported a suspected orthopoxvirus infection to the Centers for Disease Control and Prevention (CDC). In the affected person, a 26-year-old male resident of Maryland, multiple pustules had developed on the arm, chin, and back of the knee on June 16 (Table; case-patient 1). He sought treatment after a fever and headache developed on June 19 and was advised to go to an emergency room if his fever worsened (Figure 1). His condition did not improve, and he was hospitalized in Maryland on June 23. His lesions were umbilicated pustules ≈ 0.5 cm in diameter with similar morphologic features (Figure 1). The cause of his illness remained undetermined, and he was discharged on June 26 after defervescence. Contact precautions were employed during the hospitalization; however, the patient was not isolated in a negative-pressure isolation room.

Lesion samples were collected on June 24 and forwarded by the Maryland hospital to a virology reference laboratory in Michigan for testing. The samples were negative by PCR for varicella, adenovirus, and herpes simplex virus. Cytopathic effect suggestive of an orthopoxvirus was noted in MRC-5, A549, and primary rhesus monkey kidney cells, and the samples were forwarded to the MDCH laboratory for further testing. On July 4, the MDCH laboratory confirmed the presence of orthopoxvirus DNA in the lesion sample using an orthopoxvirus (nonvariola) and an orthopoxvirus generic real-time PCR (4). The specimens were sent to CDC for confirmation and virus species identification. Real-time PCRs designed to differentiate orthopoxvirus species were performed, and samples were positive for VACV DNA but not for monkeypox virus DNA (5) (Table).

The Maryland Department of Health and Mental Hygiene was contacted on July 3 and, in collaboration with the Montgomery County Department of Health and Human Services, began an investigation. The patient was asked whether he recently received smallpox vaccination or had history suggestive of exposure to orthopoxviruses such as monkeypox virus (i.e., contact

with animals, recent international travel). He reported having neither; however, his wife and child had returned from a trip to Brazil 2 weeks before his illness. Human VACV infections caused by contact with infected dairy cattle occur in regions of Brazil (6). His wife only visited an urban area in Brazil, reported no contact with farm animals, and reported no fever or rash.

Sequence analysis of a 160-bp fragment of the hemagglutinin gene from the virus isolate was performed at CDC to determine whether the VACV strain originated from smallpox vaccine or from a strain that occurs naturally in Brazil. The isolate matched the strain used in the ACAM2000 smallpox vaccine and was distinctive from known Brazilian VACV (Figure 2). ACAM2000 is the second-generation smallpox vaccine, which replaced Dryvax in January/February 2008 (7).

The patient reported belonging to a martial arts gym; he reported having several military personnel as recent sparring partners before the onset of his illness. He also reported that a recent sparring partner had exhibited a rash around the same time. This person, a 28-year-old man (case-patient 2), was contacted and described having a 4-day rash on his right forearm in mid to late June with no systemic symptoms (Figure 1). Samples of his serum, collected 2–3 weeks after lesion onset, were sent to CDC for testing and showed modestly elevated levels of anti-orthopoxvirus immunoglobulin (Ig) M antibodies (Table). Scab material tested at CDC was weakly positive for orthopoxvirus DNA by using the orthopoxvirus nonvariola and orthopoxvirus (generic) PCRs.

In the absence of an explanation for these 2 VACV (ACAM2000) infections, Maryland public health officials launched an investigation at the gym to identify additional cases and pinpoint the source of infection. Approximately 400 surveys were distributed to gym members through email and by hand at the gym. Members were asked whether they had any recent skin lesions similar to those shown in an attached photo. They were asked whether they had recently received a smallpox vaccination or had contact with someone recently vaccinated.

Ninety-five gym members responded to the survey. Several reported having received a smallpox vaccination previously, but none reported vaccination within the prior 2 months. Thirteen gym members reported skin lesions or rash but no recent smallpox vaccination. Two of these persons (case-patients 3 and 4) were clinically diagnosed with methicillin-resistant *Staphylococcus aureus* (MRSA) by health care providers in late June and early July. Both

attended the gym on the same day as case-patient 1 (Figure 1). Serum samples were collected from these men 3–4 weeks after lesion onset and sent to CDC for testing. Both had elevated levels of anti-orthopoxvirus IgG and IgM antibodies, indicative of a recent exposure (Table).

Maryland public health officials reviewed cleaning protocols at the gym. They determined that equipment and pads were cleaned at least twice daily (stemming from a concern about MRSA transmission) and that appropriate cleaning products were being used.

CDC identified 5 civilian clinics that had received ACAM2000 vaccine since late February in the Maryland area. These clinics reported having vaccinated 65 persons; none were members of the martial arts gym. The Military Vaccine Agency (Milvax) cross-checked its list of recent military vaccinees against the gym member list since late February. Although several of those identified as being vaccinated had an association with the gym, they were either not currently gym members or were not at the gym during this period. The source of virus introduction into the martial arts gym remains unknown. No further infections have been identified among gym members or health care workers exposed to case-patients.

Conclusions

This cluster of community-acquired VACV infection was possibly the result of sequential person-to-person spread of virus through direct physical contact, although transmission through fomites cannot be ruled out. The ultimate source-person responsible for introducing the virus into the gym was not identified, but given the limited time that ACAM2000 had been available to providers in the region (late February 2008), the most likely source was a recent vaccinee. None of the current gym members were known to have been vaccinated within the 4 weeks before illness onset of the first case-patient. Unrecognized transmission of VACV among gym members may have been ongoing over several months.

Multiple cases of VACV infection caused by secondary transmission have been noted recently (8–13). Materials such as towels and bedding used by the vaccinee should be treated as potential fomites and should not be shared with others (14). To our knowledge, this is the first reported cluster of community acquired VACV in which an obvious source-person was not identified. This cluster highlights the need to reinforce transmission precautions to recent vaccinees and indicates that physicians should include VACV infections on the differential of

vesiculopustular rash lesions and take appropriate infection control precautions, even in the absence of a known exposure to smallpox vaccine.

Acknowledgments

We thank Patricia Clark, Laura Mosher, Patrick Garman, Robert Myers, and Naomi Barker for their dedicated work on this case.

Ms Hughes is a health scientist with the Poxvirus and Rabies Branch, Centers for Disease Control and Prevention. Her primary research interest is the epidemiology of various poxvirus infections.

References

1. Fenner F, Henderson DA, Arita I, Jezek Z, Ladnyi ID. Smallpox and its eradication. Geneva; World Health Organization; 1988.
2. Rotz LD, Dotson DA, Damon IK, Becher JA. Vaccinia (smallpox) vaccine: recommendations of the Advisory Committee on Immunization Practices (ACIP), 2001. *MMWR Recomm Rep*. 2001;50(RR-10):1–25. [PubMed](#)
3. Casey C, Vellozzi C, Mootrey GT, Chapman LE, McCauley M, Roper MH, et al. Surveillance guidelines for smallpox vaccine (vaccinia) adverse reactions. *MMWR Recomm Rep*. 2006;55(RR-1):1–16. [PubMed](#)
4. Li Y, Ropp SL, Zhao H, Damon IK, Esposito JJ. Orthopoxvirus pan-genomic DNA assay. *J Virol Methods*. 2007;141:154–65. [PubMed DOI: 10.1016/j.jviromet.2006.12.005](#)
5. Li Y, Olson VA, Laue T, Laker MT, Damon IK. Detection of monkeypox virus with real-time PCR assays. *J Clin Virol*. 2006;36:194–203. [PubMed DOI: 10.1016/j.jcv.2006.03.012](#)
6. de Souza Trindade G, Drumond BP, Guedes MI, Leite JA, Mota BE, Campos MA, et al. Zoonotic vaccinia virus infection in Brazil: clinical description and implications for health professionals. *J Clin Microbiol*. 2007;45:1370–2. [PubMed DOI: 10.1128/JCM.00920-06](#)
7. Centers for Disease Control and Prevention. Notice to readers: newly licensed smallpox vaccine to replace old smallpox vaccine. *MMWR Morb Mortal Wkly Rep*. 2008;57:207–8.
8. Centers for Disease Control and Prevention. Household transmission of vaccinia virus from contact with a military smallpox vaccinee—Illinois and Indiana, 2007. *MMWR Morb Mortal Wkly Rep*. 2007;56:478–81. [PubMed](#)

9. Centers for Disease Control and Prevention. Secondary and tertiary transfer of vaccinia virus among US military personnel—United States and worldwide, 2002–2004. *MMWR Morb Mortal Wkly Rep.* 2004;53:103–5. [PubMed](#)
10. Centers for Disease Control and Prevention. Vulvar vaccinia infection after sexual contact with a military smallpox vaccinee—Alaska, 2006. *MMWR Morb Mortal Wkly Rep.* 2007;56:417–9. [PubMed](#)
11. Vora S, Damon I, Fulginiti V, Weber SG, Kahana M, Stein SL, et al. Severe eczema vaccinatum in a household contact of a smallpox vaccinee. *Clin Infect Dis.* 2008;46:1555–61. [PubMed DOI: 10.1086/587668](#)
12. Egan C, Kelly CD, Rush-Wilson K, Davis SW, Samsonoff WA, Pfeiffer H, et al. Laboratory-confirmed transmission of vaccinia virus infection through sexual contact with a military vaccinee. *J Clin Microbiol.* 2004;42:5409–11. [PubMed DOI: 10.1128/JCM.42.11.5409-5411.2004](#)
13. Lorch MF, Smith SB, Bessinger GT, Olivere JW. Conjugal transfer of vaccinia. *J Am Acad Dermatol.* 2004;51:460–2. [PubMed DOI: 10.1016/j.jaad.2003.10.675](#)
14. Centers for Disease Control and Prevention. Smallpox vaccination and adverse events training module—preventing contact transmission, 2010 [cited 2010 Jun 1]. <http://www.bt.cdc.gov/training/smallpoxvaccine/reactions/prevent.html>

Address for correspondence: Christine M. Hughes, Centers for Disease Control and Prevention; 1600 Clifton Rd NE, Mailstop G06, Atlanta, GA 30333, USA; email: christine.hughes@cdc.hhs.gov

Table. Characteristics of 4 cases of vaccinia infection at a martial arts gym, Maryland, USA, 2008*

Case-patient no.†	Age, y/sex	Date of onset	Rash features	Initial diagnosis	PCR	Serologic results
1	26/M	Jun 16	Pustules on face, arm, back of knee	Unknown viral exanthem	+	NA
2	28/M	Mid-late Jun	Vesicles on right forearm	None	Weak +	IgM+ (0.243), IgG+ (0.116)
3	31/M	Jun 25	Unknown presentation	MRSA‡	NA	IgM+ (0.389), IgG+ (0.227)
4	31/M	Late Jun/early Jul	Unknown presentation	MRSA‡	NA	IgM+ (0.137), IgG+ (0.2195)

*Ig, immunoglobulin; NA, not applicable; MRSA, methicillin-resistant *Staphylococcus aureus*.

†For purposes of this investigation, a case-patient is defined as a person whose clinical samples are positive for vaccinia virus DNA by PCR, or a person with lesions or a rash (macular, papular, vesicular, or pustular) and whose serum sample was positive for anti-orthopoxvirus IgM antibodies (indicative of a recent orthopoxvirus exposure). No case-patients had received a previous smallpox vaccination.

‡Clinically diagnosed, no laboratory confirmation.

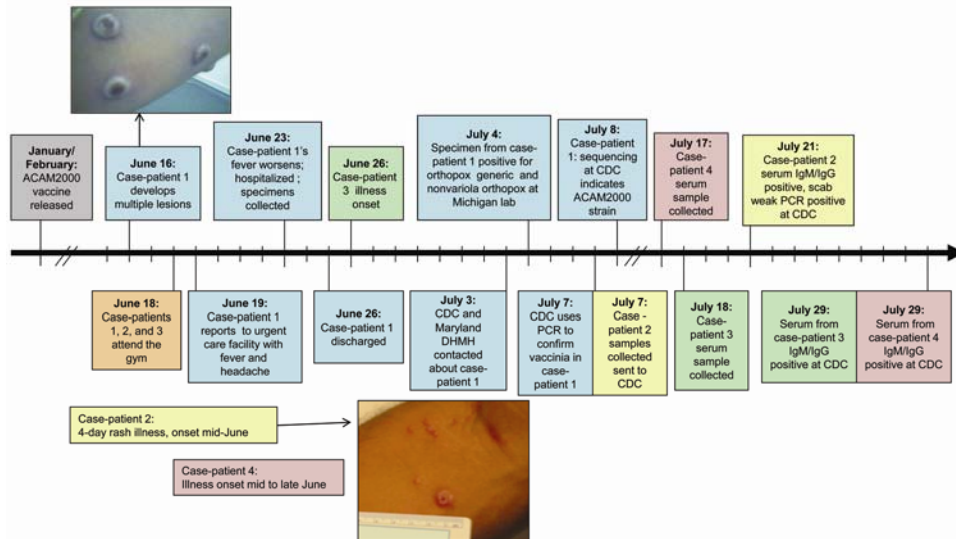


Figure 1. Timeline of the vaccinia cluster, Maryland, USA, 2008. The photo of case-patient 1's skin lesions was taken on ≈day 8 of illness (courtesy of R. Reddy). The photo of case-patient 2's skin lesions was taken ≈3 weeks after lesion onset (courtesy of K. Russo). Blue shading, case-patient 1; yellow shading, case-patient 2; green shading, case-patient 3. CDC, Centers for Disease Control and Prevention; Ig, immunoglobulin; DHMH, Department of Health and Mental Hygiene.

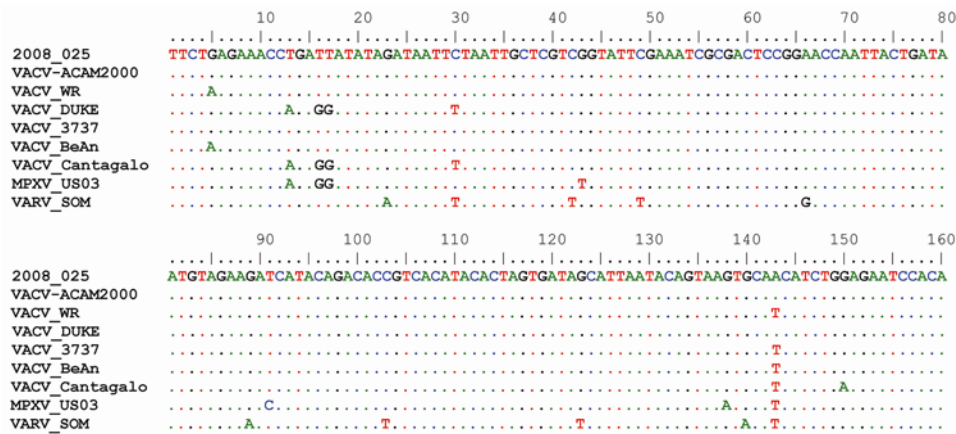


Figure 2. Partial DNA sequence alignment of the hemagglutinin gene. Case-patient 1's isolate sequence is displayed at the top (2008–025). Dots in the alignment indicate identical nucleotides at that position. The reference sequences shown: current smallpox vaccine strain (VACV-ACAM2000), a commonly used laboratory vaccinia strain (VACV-WR), Dryvax vaccinia strains (VACV-Duke and VACV-3737), natural Brazilian vaccinia isolates (VACV-BeAn and VACV-Cantagalo), a 2003 US monkeypox outbreak isolate (MPXV-US03), and a variola virus isolate (VARV-SOM). Reference GenBank accession nos., AY313847, NC_006998, DQ439815, DQ377945, DQ206442, AF229247, DQ011157, and DQ437590, respectively.