

Relationship among Visual Field, Blood Flow, and Neural Structure Measurements in Glaucoma

John C. Hwang,¹ Ranjith Konduru,¹ Xinbo Zhang,² Ou Tan,² Brian A. Francis,¹ Robit Varma,¹ Mitra Sehi,³ David S. Greenfield,³ Srinivas R. Sadda,¹ and David Huang²

PURPOSE. To determine the relationship among visual field, neural structural, and blood flow measurements in glaucoma.

METHODS. Case-control study. Forty-seven eyes of 42 patients with perimetric glaucoma were age-matched with 27 normal eyes of 27 patients. All patients underwent Doppler Fourier-domain optical coherence tomography to measure retinal blood flow and standard glaucoma evaluation with visual field testing and quantitative structural imaging. Linear regression analysis was performed to analyze the relationship among visual field, blood flow, and structure, after all variables were converted to logarithmic decibel scale.

RESULTS. Retinal blood flow was reduced in glaucoma eyes compared to normal eyes ($P < 0.001$). Visual field loss was correlated with both reduced retinal blood flow and structural loss of rim area and retinal nerve fiber layer (RNFL). There was no correlation or paradoxical correlation between blood flow and structure. Multivariate regression analysis revealed that reduced blood flow and structural loss are independent predictors of visual field loss. Each dB decrease in blood flow was associated with at least 1.62 dB loss in mean deviation ($P \leq 0.001$), whereas each dB decrease in rim area and RNFL was associated with 1.15 dB and 2.56 dB loss in mean deviation, respectively ($P \leq 0.03$).

CONCLUSIONS. There is a close link between reduced retinal blood flow and visual field loss in glaucoma that is largely independent of structural loss. Further studies are needed to elucidate the causes of the vascular dysfunction and potential avenues for therapeutic intervention. Blood flow measurement may be useful as an independent assessment of glaucoma severity. (*Invest Ophthalmol Vis Sci.* 2012;53:3020-3026) DOI:10.1167/iovs.11-8552

Glaucoma is the second leading cause of blindness worldwide¹ and affects approximately 60 million people.² In traditional models of glaucoma pathophysiology, elevation of

intraocular pressure (IOP) leads to structural loss of neural tissue at the optic nerve head (ONH) with subsequent visual field loss.³ More recently, a multifactorial etiology of glaucomatous optic neuropathy has gained greater recognition as studies reveal that IOP control alone cannot prevent progression in all patients.⁴⁻⁷

A number of studies suggest that vascular factors play a critical role in the pathophysiology of glaucoma, with the premise that low ocular blood flow may lead to retinal ganglion cell damage. Prospective trials have demonstrated blood flow deficiencies in primary open angle glaucoma in the ophthalmic,⁸⁻¹⁰ retinal,^{8,11} choroidal,¹² and retrobulbar circulations.¹³ These trials have instigated a renaissance of interest in metabolic ophthalmic assessment in glaucoma. In 2009, the World Glaucoma Association issued a consensus supporting the investigation of neuroretinal structure and blood flow in glaucoma.¹⁴

A central challenge in the study of ocular perfusion has been accurate and reliable measurement of blood flow. Optical coherence tomography (OCT) is commonly used in the diagnosis and management of retinal diseases¹⁵⁻¹⁷ and glaucoma.¹⁸⁻¹⁹ A novel application using Doppler OCT can rapidly and accurately quantify retinal blood flow. This modality detects a Doppler shift of reflected light, which provides information about flow and movement.²⁰⁻²² A recently developed double circular scanning protocol allows for precise quantification of retinal blood flow using Doppler OCT.²³ In 2007, Doppler OCT was first used to measure retinal blood flow in vivo.^{24,25} Phantom flow measurements identified the difference between measured flow and actual flow as less than 10%.²⁶ A pilot study using Doppler OCT identified a significant correlation between reduced retinal blood flow and visual field loss in glaucoma.²⁷

While there is general consensus that ocular blood flow is reduced in glaucoma, the precise relationship among visual field loss, blood flow, and structural damage remains controversial. The purpose of this study was to assess whether or not reduced retinal blood flow in glaucoma, as measured by Doppler OCT, is associated with neural structure loss or is representative of an independent vascular dysfunction that leads to visual field loss.

METHODS

Study Population

This study was performed at the Doheny Eye Institute at the University of Southern California (Los Angeles, CA) and the Bascom Palmer Eye Institute at the University of Miami (Miami, FL). The research protocols were approved by the institutional review boards at both institutions and carried out in accordance with the tenets of the Declaration of Helsinki. Written informed consent was obtained from each subject after explanation of the nature and possible consequences of the study.

From the ¹Doheny Eye Institute, Keck School of Medicine, University of Southern California, Los Angeles, California; the ²Casey Eye Institute, Oregon Health & Science University, Portland, Oregon; and the ³Bascom Palmer Eye Institute, Miami, Florida.

Supported by National Institutes of Health Grants R01 EY013516 and P30 EY03040 and by a grant from Research to Prevent Blindness.

Submitted for publication September 7, 2011; revised November 30, 2011; accepted March 4, 2012.

Disclosure: **J.C. Hwang**, None; **R. Konduru**, None; **X. Zhang**, None; **O. Tan**, Optovue, Inc. (F, P); **B.A. Francis**, None; **R. Varma**, None; **M. Sehi**, None; **D.S. Greenfield**, None; **S.R. Sadda**, Optovue, Inc. (F), Carl Zeiss Meditec (F), Optos PLC (F), Topcon Medical Systems (I, P); **D. Huang**, Optovue, Inc. (F, I, P, R)

Corresponding author: David Huang, Casey Eye Institute, Oregon Health & Science University, 3375 SW Terwilliger Boulevard, Portland, OR 97239-4197; davidhuang@alum.mit.edu.

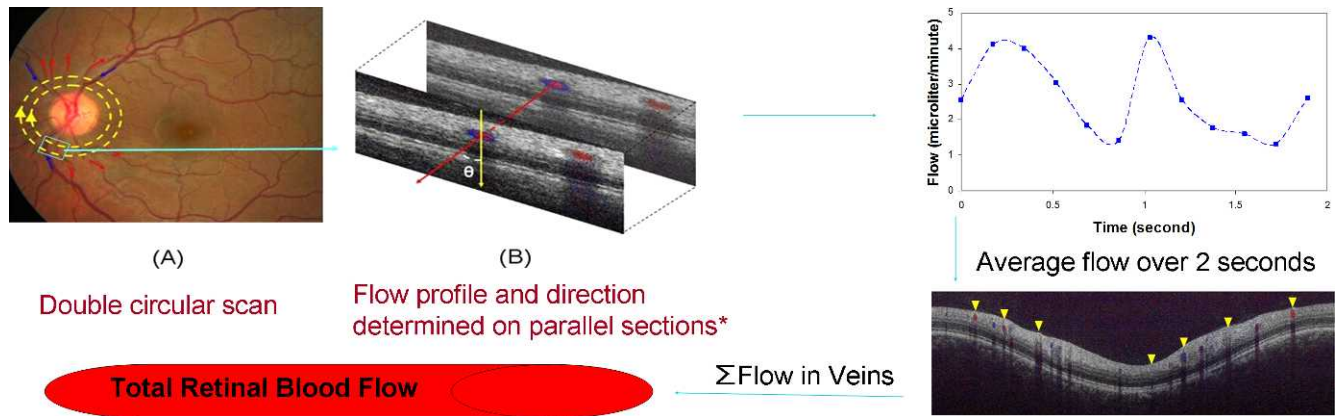


FIGURE 1. Measurement of retinal blood flow. (A) Optical coherence tomography (OCT) using a double circular scanning protocol imaged retinal blood vessels emanating from the optic nerve. (B) The incident angle θ between the beam and the blood vessel was determined by the relative position of the blood vessel in 2 cross-sectional OCT images. The Doppler shift of reflected light was detected by OCT. Arteries and veins were distinguished by the direction of flow as determined by the signs (*blue* or *red*) of the Doppler shift and the angle θ . Velocity was calculated using the Doppler shift and angle θ . (C) Volumetric blood flow rate was calculated by multiplying the velocity with the vessel cross-sectional pixel area. Flow measurements were averaged over a 2-second recording. (D) Total retinal blood flow was calculated by summing flow from all detectable veins. Image magnification ratio is 3.39:1.00 (vertical:horizontal).

The normal and perimetric glaucoma subjects were part of the Advanced Imaging for Glaucoma (AIG) study, and their inclusion criteria for that study were reported in a previous publication²⁸ and on www.AIGStudy.net. Briefly, the normal participants had IOPs of less than 21 mm Hg for both eyes, a normal Humphrey Swedish Interactive Threshold Algorithm (SITA) 24-2 standard visual field with mean deviation (MD), and pattern standard deviation (PSD) within 95% limits of the normal reference. They also had a glaucoma hemifield test within 97% limits, a central corneal thickness ≥ 500 μm , a normal-appearing ONH, a normal nerve fiber layer, an open anterior chamber angle as observed by gonioscopy, and no history of chronic ocular or systemic corticosteroid use. The age distribution of the controls matched that of the glaucoma cases. The perimetric glaucoma participants had at least one eye that fulfilled the following criteria: glaucomatous (abnormal) visual field loss with PSD or glaucoma hemifield test outside normal limits ($P < 0.05$ and $P < 1\%$, respectively) in a consistent pattern on both qualifying visual fields. They also had ONH changes such as diffuse or localized rim thinning, disc (splinter) hemorrhage, vertical cup/disc ratio greater than the fellow eye by >0.2 , or a notch in the rim detected on baseline dilated fundus examination and confirmed by masked reading of stereo disc photographs.

Optical Coherence Tomography

A spectrometer-based^{23,29} Fourier-domain OCT (FDOCT) system was used for Doppler imaging (RTVue; Optovue Inc., Fremont, CA). This system operated at a wavelength of 840 nm with an axial resolution of 5 μm and a transverse resolution of 20 μm in tissue. The power incident on the eye was 750 μW , and the time interval between two sequential axial scans was 36.7 μs . The maximum measurable Doppler shift was 13.6 kHz at the phase wrapping limit of $\pm\pi$ radian phase shift between sequential axial scans. This corresponds to a maximum measurable axial velocity component in the eye of 4.2 mm/s.

Doppler Image Acquisition and Processing

After pupil dilation with 1% tropicamide and 2.5% phenylephrine eye drops, each subject was seated in front of the OCT scanner and instructed to look at the internal fixation target. The subject's head was stabilized by a chin rest. The fundus of the subject eye was visualized on a real-time video display. Doppler imaging was performed with FDOCT, using a double circular scan pattern around the optic disc (Fig. 1). The double

circular scan pattern contained circles of 2 diameters, 3.4 mm and 3.75 mm, and was centered on the optic disc. The frame rate was 6 frames per second. Each scan contained 12 frames and was recorded over consecutive 2-second intervals. Five or 6 repeated scans were performed on one randomly selected eye for each subject. Retinal blood flow was measured by graders at the Doheny Doppler OCT reading center, using the semi-automated software DOCTORC (created by coauthor O. Tan at the University of Southern California and the Oregon Health & Science University), which was adapted from a previously described method.²³

Blood vessels were identified based on Doppler and reflectance OCT images. Vessel type, vein versus artery, was decided based on OCT images and fundus photographs. The pixel ranges were 2.7 or 2.9 μm in the horizontal dimension and 3.1 μm in the vertical dimension. Vessel diameter (D) was measured by computing caliper on the cross-sectional Doppler OCT images and was used to compute lumen area ($\pi D^2/4$). The venous cross-sectional areas for all branch vessels around the optic disc were summed to obtain the total venous area for the eye. The Doppler angle, between the vessel and OCT beam, was measured by the relative position of each vessel in the two concentric OCT images.

The effect of eye motion on the calculation of Doppler angle was small because of the short time interval between the inner and outer circular scans (0.16 second). The error was further minimized by averaging the Doppler angle estimates from 6 pairs of concentric circular scans. Flow velocity was computed from the Doppler shift and Doppler angle, with steps to account for the effect of background retinal motion and transverse scan step size.²³ The Doppler angle in our study was small enough that the axial velocity component for the great majority of veins was within the range of the OCT systems used. When the peak axial Doppler shift was between π and 2π (or $-\pi$ and -2π) at the center of the vessel, a phase unwrapping algorithm was applied automatically to allow valid flow measurements.³⁰ The phase unwrapping algorithm ensured that all appropriate multiples of 2π were included in the calculated angle for flow measurements. Doppler shifts of greater than $\pm 2\pi$ did not occur in any vein in this data set. However, faster arterial velocities could cause multiple phase wrapping ($>2\pi$ or $<-2\pi$), and we did not measure arterial flow because of this difficulty.

Veins were identified by the flow direction toward the optic disc. The volumetric blood flow rate for each pixel was calculated by multiplying the velocity by vessel area. Flow within a vein was calculated by summing the flow in the pixels over lumen cross-section. Flow measurements were averaged over each 2-second recording. Measurements from all valid scans were averaged. Total retinal blood flow was calculated by summing flow from all detectable veins. Retinal

TABLE 1. Baseline Characteristics of Normal and Glaucoma Subjects

| Characteristic | Normal | Glaucoma | P Value |
|----------------------------------------------------|--------------|--------------|---------|
| Patients, <i>n</i> | 27 | 42 | |
| Eyes, <i>n</i> | 27 | 47 | |
| Age (years) | 62.1 ± 9.0 | 61.4 ± 8.7 | 0.73 |
| Diabetes mellitus, <i>n</i> (%) | 1 (4) | 3 (7) | 0.99 |
| Systemic hypertension, <i>n</i> (%) | 10 (37) | 15 (36) | 0.84 |
| Systemic antihypertensive medication, <i>n</i> (%) | 4 (15) | 11 (23) | 0.56 |
| Intraocular pressure (mm Hg) | 14.3 ± 2.1 | 13.5 ± 2.4 | 0.13 |
| Diastolic blood pressure (mm Hg) | 82.5 ± 8.6 | 80.3 ± 8.0 | 0.32 |
| Systolic blood pressure (mm Hg) | 130.3 ± 17.1 | 124.6 ± 12.0 | 0.12 |
| Diastolic ocular perfusion pressure (mm Hg) | 68.6 ± 8.9 | 66.8 ± 7.5 | 0.41 |
| Systolic ocular perfusion pressure (mm Hg) | 116.4 ± 17.6 | 111.1 ± 11.1 | 0.27 |

blood flow in arteries and veins should have an equal sum because inflow must equal outflow in any steady state system that obeys the law of conservation of mass. This has been confirmed by actual measurements of retinal arterial and venous flows with a number of techniques.³¹ Thus, measuring total venous flow alone is sufficient to quantify the total retinal blood flow. Average venous velocities were obtained by dividing the total retinal flow by the total venous areas.

Visual Field Testing

Visual fields were tested in normal and glaucoma subjects using the Humphrey Field Analyzer II (Carl Zeiss Meditec, Inc., Dublin, CA) with the 24-2 threshold test, size III white stimulus, and the SITA standard 24-2.

Structural Analysis

Standard quantitative imaging modalities were used to assess structural parameters of the retinal nerve fiber layer (RNFL). Thickness was determined by scanning laser polarimetry (SLP) with enhanced corneal compensation (GDx-ECC; Carl Zeiss Meditec) and FDOCT using the RTVue. Disc rim area was measured by confocal scanning laser ophthalmoscopy (HRT3; Heidelberg Engineering, GmbH, Dossenheim, Germany), and ganglion cell complex thickness (GCC) was measured by FDOCT using the RTVue.

Statistical Analysis

Two-sided *t*-tests were used to compare the average values of measurements. The authors used the generalized estimating equation method to account for the correlation between both eyes from the

same participant. Because visual field values for mean deviation and pattern standard deviation were reported in logarithmic dB scale, values for blood flow, rim area, RNFL, and GCC thickness were converted to logarithmic dB scale by $10 \times \log_{10}$ [value/(average value of the normal group)] to improve the correlation linearity and strengthen the correlation coefficient values. Linear regression was then used to analyze the effect of blood flow and structural parameters on the visual fields. All of the statistical analyses were performed with SAS software (SAS 9.1.3; SAS Institute, Cary, NC).

RESULTS

A total of 47 consecutive eyes of 42 patients with glaucoma were age-matched with 27 normal eyes of 27 patients. There were no significant differences in age, systemic hypertension, and diabetes mellitus between the two groups (Table 1). There was also no significant difference between the control and glaucoma groups for use of systemic antihypertensive medications, diastolic blood pressure, systolic blood pressure, diastolic ocular perfusion pressure, and systolic ocular perfusion pressure. However, the mean IOP was lower in glaucoma eyes ($P = 0.03$), which were all undergoing treatment.

Traditional measures of function and structure were consistent with expected findings for glaucoma eyes (Table 2). Glaucoma eyes demonstrated visual field loss with lower MD values and higher PSD values compared to normal eyes ($P < 0.0001$). Structural evaluation identified loss of disc rim area, GCC thickness, and RNFL thickness in glaucoma eyes relative to normal eyes ($P < 0.0001$).

TABLE 2. Results of Diagnostic Testing

| Parameter | Normal | Glaucoma | P Value |
|-----------------------------------|----------------|----------------|---------|
| Visual field | | | |
| Mean deviation (dB) | 0.16 ± 1.00 | -4.39 ± 4.14 | <0.0001 |
| Pattern standard deviation (dB) | 1.61 ± 0.39 | 6.54 ± 4.45 | <0.0001 |
| Structural assessments | | | |
| cSLO rim area (mm ²) | 1.52 ± 0.34 | 1.01 ± 0.29 | <0.0001 |
| SLP RNFL thickness (μm) | 54.6 ± 4.9 | 44.2 ± 6.3 | <0.0001 |
| FDOCT RNFL thickness (μm) | 104.6 ± 7.4 | 82.9 ± 8.6 | <0.0001 |
| GCC thickness (μm) | 92.5 ± 6.6 | 80.7 ± 7.7 | <0.0001 |
| Total retinal blood flow (μL/min) | 45.5 ± 9.5 | 34.9 ± 8.5 | <0.001 |
| Arterial area (mm ²) | 0.033 ± 0.0077 | 0.028 ± 0.0074 | 0.006 |
| Venous area (mm ²) | 0.047 ± 0.012 | 0.041 ± 0.0086 | 0.01 |
| Arterial velocity (mm/sec) | 23.9 ± 7.2 | 21.8 ± 7.3 | 0.22 |
| Venous velocity (mm/sec) | 16.3 ± 2.8 | 14.5 ± 3.7 | 0.03 |

dB, decibel; cSLO, scanning laser ophthalmoscopy; SLP, scanning laser polarimetry; RNFL, retinal nerve fiber layer; FDOCT, Fourier-domain optical coherence tomography; GCC, ganglion cell complex.

TABLE 3. Age-adjusted Correlation Coefficient Matrix on Visual Field, Blood Flow, Structural Parameters, and Intraocular Pressure in Glaucoma Patients

| Parameter | Visual Field MD (dB) | Visual Field PSD (dB) | Blood Flow* (dB) | cSLO Rim Area* (dB) | SLP RNFL* (dB) | FDOCT RNFL* (dB) | FDOCT GCC* (dB) |
|-----------------------------------|----------------------|-----------------------|------------------|---------------------|----------------|------------------|-----------------|
| Visual field PSD (dB) | -0.88 (<0.01)† | | | | | | |
| Blood flow* (dB) | 0.48 (<0.01) | -0.26 (0.09) | | | | | |
| cSLO rim area* (dB) | 0.34 (0.02) | -0.31 (0.04) | -0.02 (0.91) | | | | |
| SLP RNFL thickness* (dB) | 0.24 (0.12) | -0.28 (0.07) | -0.37 (0.01) | 0.67 (<0.01) | | | |
| FDOCT RNFL thickness* (dB) | 0.37 (0.01) | -0.25 (0.10) | 0.19 (0.23) | 0.36 (0.02) | 0.36 (0.02) | | |
| FDOCT GCC thickness* (dB) | 0.20 (0.20) | -0.19 (0.23) | 0.03 (0.84) | 0.31 (0.04) | 0.35 (0.02) | 0.68 (<0.01) | |
| Mean intraocular pressure (mm Hg) | -0.01 (0.93) | -0.12 (0.44) | -0.12 (0.45) | 0.07 (0.66) | 0.07 (0.67) | 0.15 (0.35) | 0.14 (0.37) |

FDOCT, Fourier-domain optical coherence tomography; PSD, pattern standard deviation; MD, mean deviation; cSLO, confocal scanning laser ophthalmoscopy; SLP, scanning laser polarimetry; RNFL, retinal nerve fiber layer; GCC, ganglion cell complex.

* Parameters converted to dB scale by $10 \times \log_{10} [\text{value}/(\text{average value of the normal group})]$. Pre-conversion physical units were $\mu\text{L}/\text{min}$ for blood flow, mm^2 for cSLO rim area, and μm for SLP RNFL thickness, FDOCT RNFL thickness, and FDOCT GCC thickness.

† Pearson's R (P value to test $|R| = 0$).

Visual field loss was correlated with some measures of structural change. MD was correlated with rim area and RNFL thickness ($P \leq 0.02$) measured by FDOCT (Table 3), but was not correlated with GCC or RNFL thickness determined by scanning laser polarimetry ($P \geq 0.12$). Univariate analysis (Table 4) confirmed a direct relationship between the MD and both disc rim area and RNFL thickness as measured by FDOCT. Each dB decrease in rim area and RNFL was associated with a 1.11 dB and 3.29 dB decrease in mean deviation, respectively ($P \leq 0.03$). Univariate analysis did not demonstrate any significant correlation between visual field loss (MD and PSD) and both diastolic and systolic perfusion pressures (data not shown). Multivariate analysis confirmed a largely independent relationship between structural loss and visual field loss, even after accounting for reduced blood flow (Table 4).

Total retinal blood flow was significantly reduced in glaucoma eyes with decreased vessel area and venous velocity compared to normal eyes ($P \leq 0.03$, Table 2). Blood flow reduction was correlated with visual field loss, but had no correlation or paradoxical correlation with structural loss of neural tissue (Table 3). Blood flow was negatively correlated to RNFL thickness as determined by SLP ($P = 0.01$) but had no significant correlation with rim area, RNFL thickness as determined by FDOCT, or GCC thickness ($P \geq 0.23$). The reasons underlying the paradoxical correlation between blood flow and RNFL thickness determined by SLP are unclear.

Univariate analysis showed that blood flow was highly correlated with visual field loss as measured by MD (Table 4). Univariate analysis did not demonstrate any significant correlation between total retinal blood flow and either diastolic or systolic perfusion pressures. Multivariate analyses confirmed a largely independent relationship between reduced blood flow and visual field loss, even after accounting for structural loss of rim area or RNFL thickness (Table 4). In these

multivariate analyses, blood flow was the dominant explanatory variable, accounting for more than twice the variance (R^2) in visual field MD as rim area or RNFL thickness (Table 4). Further multivariate analysis, which incorporated variables of diastolic perfusion pressure, systolic perfusion pressure, and use of systemic antihypertensive medication, did not alter the significant relationship between reduced blood flow and visual field loss.

Mean IOP was significantly lower in glaucoma eyes, all of which were undergoing treatment, compared with normal eyes ($P = 0.03$). IOP in glaucoma eyes was not significantly correlated to measurements of visual field, structure, or blood flow (Table 3).

DISCUSSION

The purpose of this study was to determine the relationship among visual field loss, structural loss of neural tissue, and blood flow reduction in glaucoma. The authors' multivariate regression analysis revealed that blood flow reduction and structural loss were both significant and independent predictors of visual field loss in glaucoma patients. In addition, there was no correlation or paradoxical correlation between blood flow and structural changes. These findings suggest that structural evaluation alone can, at best, only provide a partial understanding of disease severity. Retinal blood flow, as measured by OCT, was more than twice as important as structural variables in explaining the variation in visual field MD. Therefore blood flow measurements may potentially be at least as important as structural measurements in the diagnostic and prognostic evaluation of glaucoma.

There are a number of possible causal relationships among blood flow, IOP, ONH structure, and visual field loss (Fig. 2). In

TABLE 4. Linear Regression Models to Predict Mean Deviation Associated with Blood Flow, Rim Area, and Retinal Nerve Fiber Layer Thickness in Glaucoma Patients

| Model | Variable 1 | | | Variable 2 | | | Total R^2 |
|-------|----------------------|--------------------|-------|----------------------|--------------------|-------|-------------|
| | Parameter (dB)* | Slope (P value) | R^2 | Parameter (dB)* | Slope (P value) | R^2 | |
| 1 | Blood flow | 1.91 (<0.001) | 0.29 | | | | |
| 2 | cSLO rim area | 1.11 (0.03) | 0.10 | | | | |
| 3 | FDOCT RNFL thickness | 3.29 (0.01) | 0.13 | | | | |
| 4 | Blood flow | 1.93 (<0.001) | 0.26 | cSLO rim area | 1.15 (0.006) | 0.10 | 0.36 |
| 5 | Blood flow | 1.62 (0.001) | 0.24 | FDOCT RNFL thickness | 2.56 (0.03) | 0.09 | 0.33 |

FDOCT, Fourier-domain optical coherence tomography; RNFL, retinal nerve fiber layer; cSLO, confocal scanning laser ophthalmoscopy.

* Parameters converted to dB scale (see Table 3).

clinically detectable glaucoma, the ONH has already undergone significant structural change with the loss of nearly 50% of retinal nerve fibers.³² It is possible that neural tissue loss drives the reduction in blood flow through decreased metabolic demand³³ (Fig. 2A) or that neural structure loss is a consequence of ischemic damage due to perfusion deficits (Fig. 2B). Alternatively, visual field loss may arise from reduced blood flow that is independent of structural loss (Fig. 2C). The distinction is critical because the identification of a vascular dysfunction independent of structural loss raises the possibility of a new metric for glaucoma evaluation and the potential for a novel therapeutic target. The authors' analysis suggests that structural thinning of the RNFL or disc rim is not a critical intermediate link or confounding variable when evaluating the relationship between reduced blood flow and visual field loss. Therefore, reduced blood flow in glaucoma appears to be neither a major consequence nor a strong driver of neural tissue loss, and is largely independently associated with visual field loss in glaucoma.

While this study identifies blood flow as a predictor of visual loss, the precise pathophysiological link between blood flow and glaucoma remains unclear. Ocular perfusion pressure is the driving force for the blood circulation in the eye, and is defined as the difference between mean arterial blood pressure and venous pressure, which is approximately equal to IOP. Several studies have demonstrated significant associations between ocular perfusion pressure, blood flow, and visual function.³⁴⁻³⁸ Some studies have demonstrated a positive correlation between systemic blood pressure and glaucoma,³⁹ while others identified a negative correlation⁴⁰ or no correlation.⁴¹ These conflicting results suggest that the link between blood pressure and glaucoma is complex, and may depend on many other factors such as medications and vascular autoregulation.

Intraocular pressure has been evaluated extensively and is an important risk factor for glaucoma. However, IOP is an imperfect correlate of visual field loss. In some patients, disease progression can occur despite adequate IOP control,⁴⁻⁷ while in ocular hypertensive patients there may be no structural or functional consequence despite sustained elevation of IOP.⁶ Therefore, it seems that the level of glaucomatous damage depends on the susceptibility of an individual eye to a certain level of IOP. Similarly, it is possible that the amount of RNFL loss depends on the susceptibility of an individual eye to a certain level of retinal blood flow. A number of population-based studies identified a strong association between low perfusion pressure and glaucoma.⁴⁰⁻⁴³ This study did not demonstrate any significant correlation between visual field loss or total retinal blood flow, and either diastolic or systolic perfusion pressures. Further studies are warranted to elucidate the precise relationship between the various vascular factors and glaucoma. Direct measurement of retinal blood flow may provide insight on how other vascular factors affect ocular perfusion, which in turn could lead to glaucoma progression.

Vascular deficiencies in glaucoma may also be related to unstable perfusion and dysfunctional autoregulation. Nocturnal circadian dips in blood pressure with presumed ischemic damage have been implicated in disease progression.⁴⁴⁻⁴⁶ However, blood pressure is an imperfect surrogate of ocular perfusion, since brachial and ocular blood pressures likely vary in diseased vascular beds and significant differences can arise with positional change. Further studies assessing hour-to-hour variability in blood flow using Doppler OCT would allow a stronger understanding of the influence of circadian variation on ocular perfusion and glaucoma.

Autoregulation of ocular capillary beds causes shifts in regional blood flow in accordance with tissue demand and adds further complexity to assessing ocular perfusion. Auto-

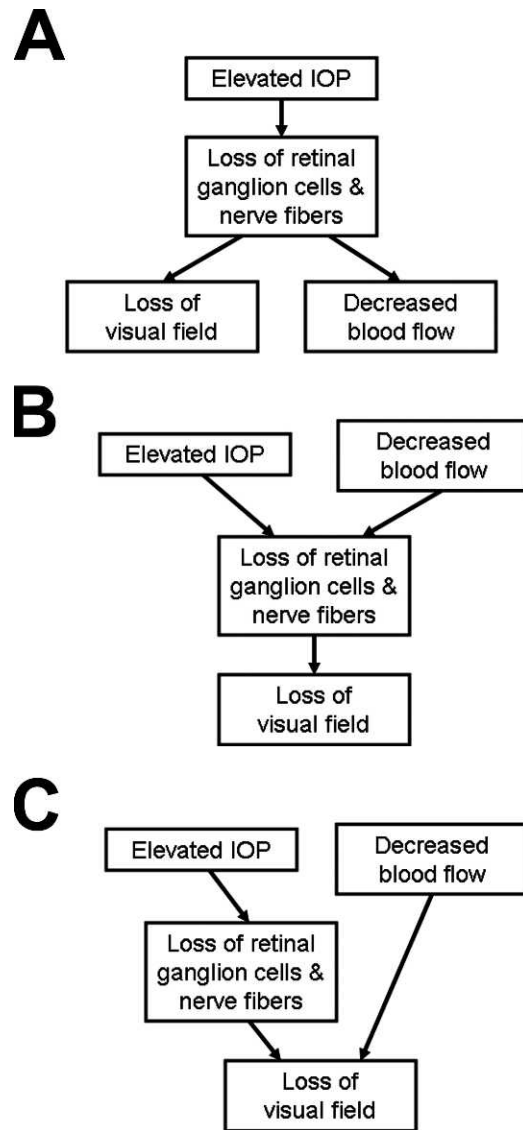


FIGURE 2. Possible relationships among blood flow, intraocular pressure, structure, and visual field loss in glaucoma. (A) Reduced blood flow could be a consequence of neural tissue loss arising from elevated intraocular pressure. (B) Reduced blood flow and elevated intraocular pressure could both lead to neural structure loss. (C) Reduced blood flow could be an independent cause of visual field loss. IOP, intraocular pressure.

regulation may mitigate shifts in blood pressure and IOP, and recent studies suggest that autoregulation may be dysfunctional or absent in glaucoma patients.⁴⁷ In healthy eyes, retinal and ONH blood flow are autoregulated and maintained at a relatively constant level, despite diurnal variations of IOP and ocular perfusion pressure. Ocular blood flow in the eye is autoregulated via local mechanisms, and includes metabolic and mechanical autoregulation. Metabolic autoregulation is influenced by local conditions, such as nutritional needs, carbon dioxide or oxygen levels, and adenosine levels when ATP is not being produced because of hypoxia.⁴⁸ Mechanical autoregulation is triggered by changes in systemic blood pressure, IOP, ocular perfusion pressure, or shear stress. It seems that some factors such as endothelin-1 and nitric oxide, released by the vascular endothelium, are responsible for the regulation of local perfusion in the retina and ONH.⁴⁹ In glaucoma, ocular flow dysregulation is common and is closely

associated with the systemic vascular dysregulation mediated by endothelial dysfunction,⁵⁰ and systemic factors such as vasospasm or atherosclerosis may influence it.⁵¹ The severity of glaucoma may affect retinal function, and thereby the metabolic need and the level of retinal blood flow. The fact that each dB reduction in blood flow was associated with nearly 2 dB reduction in visual field MD suggests that glaucoma may affect the functioning of not only the ganglion cell layer and nerve fiber layer, but other inner retinal layers as well. Additional studies employing Doppler OCT may advance our understanding of vascular dysregulation in glaucoma.

The principal finding of this study, that retinal blood flow is a largely independent metric of visual function, raises new questions. Retinal blood flow may not only act as a useful complementary variable for the diagnosis and monitoring of disease progression, but may also serve as a potential therapeutic target. However, critical questions need to be addressed before these possibilities are realized. First, we need to gain a stronger understanding of ocular blood flow physiology and its diagnostic potential. When do changes first manifest in the glaucoma disease process? What is the sensitivity and specificity of reduced ocular blood flow? Are there racial differences in normative values? Is there a circadian influence on ocular perfusion? What are the implications of reduced retinal blood flow on retinal function in glaucomatous eyes? Second, we need to understand the mechanisms by which ocular blood flow is lowered or raised. Does lowering IOP increase blood flow? Are systemic factors at play? Can increasing blood pressure improve ocular perfusion? What are the systemic risks? Third, we need to assess the functional benefits of improving ocular perfusion. Could enhanced blood flow improve visual field function? Or slow visual field loss? Or reduce structural change?

There are a number of limitations to this study. First, the study employed a non-interventional case-control design, which can identify associations but cannot determine causation. Although the pattern of correlation is highly suggestive of causation, further assessments using alternative study designs will be needed to confirm a causal link between reduced blood flow and glaucoma. Second, the case-control design is also susceptible to confounding elements not accounted for in control selection. The study's glaucoma and normal groups were age-matched and there were no significant differences between the groups for history of hypertension and diabetes mellitus. There was also no significant difference in use of antihypertensive medications, diastolic ocular perfusion pressure, and systolic ocular perfusion pressure. However, there may be relevant confounding elements that remain unidentified and the potential confounding impact of both ocular and systemic medications warrants further investigation. Third, this study assessed total retinal blood flow, but not localized retinal flow. RNFL loss is more localized in early to moderate glaucoma, and there may be significant correlations between localized RNFL loss and localized retinal flow. This study was not able to evaluate the microcirculation of the neuroretinal rim, because the double-circular Doppler OCT used in the study was not designed for this purpose. Similarly, technological limitations precluded precise, non-invasive measurements of blood flow in the short posterior ciliary arteries. These may be relevant to the glaucoma disease process because they partly supply the ONH. Fourth, there is variability in repeat measurements of retinal blood flow using Doppler OCT, and previous studies reported the coefficient of variation to be approximately 10–14%.^{27,52} Future studies confirming the reliability of the authors' findings would be instructive.

In summary, this study demonstrated that retinal blood flow measurement may be useful as a novel variable in glaucoma assessment. The authors' analysis demonstrated that reduced

blood flow is associated with visual field loss and largely independent of thinning of the disc rim or the RNFL. Therefore, blood flow assessment provides information on glaucoma disease severity that is not captured by structural evaluation alone. Further investigations in ocular perfusion are warranted, and may open the possibility of a paradigm shift in the diagnosis and treatment of glaucoma.

References

1. Leske MC. Open-angle glaucoma—an epidemiologic overview. *Ophthalmic Epidemiol.* 2007;14:166–172.
2. Quigley HA, Broman AT. The number of people with glaucoma worldwide in 2010 and 2020. *Br J Ophthalmol.* 2006;90:262–267.
3. Pan Y, Varma R. Natural history of glaucoma. *Indian J Ophthalmol.* 2011;59:S19–23.
4. Heijl A, Leske MC, Bengtsson B, Hyman L, Bengtsson B, Hussein M. Reduction of intraocular pressure and glaucoma progression: results from the Early Manifest Glaucoma Trial. *Arch Ophthalmol.* 2002;120:1268–1279.
5. Musch DC, Gillespie BW, Lichter PR, Niziol LM, Janz NK. Visual field progression in the Collaborative Initial Glaucoma Treatment Study: the impact of treatment and other baseline factors. *Ophthalmology.* 2009;116:200–207.
6. Kass MA, Heuer DK, Higginbotham EJ, et al. The Ocular Hypertension Treatment Study: a randomized trial determines that topical ocular hypotensive medication delays or prevents the onset of primary open-angle glaucoma. *Arch Ophthalmol.* 2002;120:701–713.
7. Collaborative Normal Tension Glaucoma Study Group. The effectiveness of intraocular pressure reduction in the treatment of normal-tension glaucoma. *Am J Ophthalmol.* 1998;126:498–505.
8. Butt Z, McKillop G, O'Brien C, Allan P, Aspinall P. Measurement of ocular blood flow velocity using colour Doppler imaging in low tension glaucoma. *Eye.* 1995;9:29–33.
9. Galassi F, Sodi A, Ucci F, Renieri G, Pieri B, Baccini M. Ocular hemodynamics and glaucoma prognosis: a color Doppler imaging study. *Arch Ophthalmol.* 2003;121:1711–1715.
10. Rojanapongpun P, Drance SM, Morrison BJ. Ophthalmic artery flow velocity in glaucomatous and normal subjects. *Br J Ophthalmol.* 1993;77:25–29.
11. Chung HS, Harris A, Kagemann L, Martin B. Peripapillary retinal blood flow in normal tension glaucoma. *Br J Ophthalmol.* 1999;83:466–469.
12. Yin ZQ, Vaegan, Millar TJ, Beaumont P, Sarks S. Widespread choroidal insufficiency in primary open-angle glaucoma. *J Glaucoma.* 1997;6:23–32.
13. Januleviciene I, Sliesoraityte I, Siesky B, Harris A. Diagnostic compatibility of structural and haemodynamic parameters in open-angle glaucoma patients. *Acta Ophthalmol.* 2008;86:552–557.
14. Weinreb RN, Harris A. *Ocular Blood Flow in Glaucoma: Consensus Series 6.* The Netherlands: Kugler Publications; 2009.
15. Puliafito CA, Hee MR, Lin CP, et al. Imaging of macular diseases with optical coherence tomography. *Ophthalmology.* 1995;102:217–229.
16. Hee MR, Puliafito CA, Wong C, et al. Optical coherence tomography of macular holes. *Ophthalmology.* 1995;102:748–756.
17. Hee MR, Bauman CR, Puliafito CA, et al. Optical coherence tomography of age-related macular degeneration and choroidal neovascularization. *Ophthalmology.* 1996;103:1260–1270.
18. Schuman JS, Hee MR, Puliafito CA, et al. Quantification of nerve fiber layer thickness in normal and glaucomatous eyes

- using optical coherence tomography. *Arch Ophthalmol*. 1995; 113:586-596.
19. Schuman JS, Hee MR, Arya AV, et al. Optical coherence tomography: a new tool for glaucoma diagnosis. *Curr Opin Ophthalmol*. 1995;6:89-95.
 20. Wang XJ, Milner TE, Nelson JS. Characterization of fluid flow velocity by optical Doppler tomography. *Opt Lett*. 1995;20:1337-1339.
 21. Izatt JA, Kulkarni MD, Yazdanfar S, Barton JK, Welch AJ. In vivo bidirectional color Doppler flow imaging of picoliter blood volumes using optical coherence tomography. *Opt Lett*. 1997; 22:1439-1441.
 22. Zhao Y, Chen Z, Saxer C, Xiang S, de Boer JF, Nelson JS. Phase-resolved optical coherence tomography and optical Doppler tomography for imaging blood flow in human skin with fast scanning speed and high velocity sensitivity. *Opt Lett*. 2000;25: 114-116.
 23. Wang Y, Bower BA, Izatt JA, Tan O, Huang D. Retinal blood flow measurement by circumpapillary Fourier domain Doppler optical coherence tomography. *J Biomed Opt*. 2008;13: 064003.
 24. Wang Y, Bower BA, Izatt JA, Tan O, Huang D. In vivo total retinal blood flow measurement by Fourier domain Doppler optical coherence tomography. *J Biomed Opt*. 2007;12: 041215.
 25. Makita S, Fabritius T, Yasuno Y. Quantitative retinal-blood flow measurement with three-dimensional vessel geometry determination using ultrahigh-resolution Doppler optical coherence angiography. *Opt Lett*. 2008;33:836-838.
 26. Wehbe HM, Ruggeri M, Jiao S, Gregori G, Puliafito CA, Zhao W. Calibration of blood flow measurement with spectral domain optical coherence tomography. *Biomedical Optics, OSA Technical Digest [CD-ROM]* Optical Society of America; 2008. Paper BMD75.
 27. Wang Y, Fawzi AA, Varma R, et al. Pilot study of optical coherence tomography measurement of retinal blood flow in retinal and optic nerve diseases. *Invest Ophthalmol Vis Sci*. 2011;52:840-845.
 28. Tan O, Chopra V, Lu ATH, et al. Detection of macular ganglion cell loss in glaucoma by Fourier-domain optical coherence tomography. *Ophthalmology*. 2009;116:2305-2314.
 29. White BR, Pierce MC, Nassif N, et al. In vivo dynamic human retinal blood flow imaging using ultra-high-speed spectral domain optical Doppler tomography. *Opt Express*. 2003;11: 3490-3497.
 30. Ghiglia DC, Mastin GA, Romero LA. Cellular-automata method for phase unwrapping. *J Opt Soc Am A*. 1987;4:267-280.
 31. Fekete GT, Tagawa H, Deupree DM, Goger DG, Sebag J, Weiter JJ. Blood flow in the normal human retina. *Invest Ophthalmol Vis Sci*. 1989;30:58-65.
 32. Harwerth RS, Quigley HA. Visual field defects and retinal ganglion cell losses in patients with glaucoma. *Arch Ophthalmol*. 2006;124:853-859.
 33. Caprioli J, Coleman AL; Blood Flow in Glaucoma Discussion. Blood pressure, perfusion pressure, and glaucoma. *Am J Ophthalmol*. 2010;149:704-712.
 34. Sato EA, Ohtake Y, Shinoda K, Mashima Y, Kimura I. Decreased blood flow at neuroretinal rim of optic nerve head corresponds with visual field deficit in eyes with normal tension glaucoma. *Graefes Arch Clin Exp Ophthalmol*. 2006;244:795-801.
 35. Ben Simon GJ, Moroz I, Goldenfeld M, Melamed S. Scanning laser Doppler flowmetry of nonperfused regions of the optic nerve head in patients with glaucoma. *Ophthalmic Surg Lasers Imaging*. 2003;34:245-250.
 36. Ciancaglini M, Carpineto P, Costagliola C, Matropasqua L. Perfusion of the optic nerve head and visual field damage in glaucomatous patients. *Graefes Arch Clin Exp Ophthalmol*. 2001;239:549-555.
 37. Martínez A, Sánchez M. Predictive value of colour Doppler imaging in a prospective study of visual field progression in primary open-angle glaucoma. *Acta Ophthalmol Scand*. 2005; 83:716-722.
 38. Nicoletta MT, Drance SM, Rankin SJ, Buckley AR, Walman BE. Color Doppler imaging in patients with asymmetric glaucoma and unilateral visual field loss. *Am J Ophthalmol*. 1996;121: 502-510.
 39. Mitchell P, Lee AJ, Rochtchina E, Wang JJ. Open-angle glaucoma and systemic hypertension: the blue mountains eye study. *J Glaucoma*. 2004;13:319-326.
 40. Leske MC, Wu SY, Hennis A, Honkanen R, Nemesure B. Risk factors for incident open-angle glaucoma: the Barbados Eye Studies. *Ophthalmology*. 2008;115:85-93.
 41. Hulsman CA, Vingerling JR, Hofman A, Witteman JC, de Jong PT. Blood pressure, arterial stiffness, and open-angle glaucoma: the Rotterdam study. *Arch Ophthalmol*. 2007;125:805-812.
 42. Tielsch JM, Katz J, Sommer A, Quigley HA, Javitt JC. Hypertension, perfusion pressure, and primary open-angle glaucoma. A population-based assessment. *Arch Ophthalmol*. 1995;113:216-221.
 43. Quigley HA, West SK, Rodriguez J, Munoz B, Klein R, Snyder R. The prevalence of glaucoma in a population-based study of Hispanic subjects: Proyecto VER. *Arch Ophthalmol*. 2001;119: 1819-1826.
 44. Graham SL, Drance SM. *Surv Ophthalmol*. Nocturnal hypotension: role in glaucoma progression. 1999;43:S10-16.
 45. Graham SL, Drance SM, Wijsman K, Douglas GR, Mikelberg FS. Ambulatory blood pressure monitoring in glaucoma: the nocturnal dip. *Ophthalmology*. 1995;102:61-69.
 46. Tokunaga T, Kashiwagi K, Tsumura T, Taguchi K, Tsukahara S. Association between nocturnal blood pressure reduction and progression of visual field defect in patients with primary open-angle glaucoma or normal-tension glaucoma. *Jpn J Ophthalmol*. 2004;48:380-385.
 47. Fekete GT, Pasquale LR. Retinal blood flow response to posture change in glaucoma patients compared with healthy subjects. *Ophthalmology*. 2008;115:246-252.
 48. Orgül S, Gugleta K, Flammer J. Physiology of perfusion as it relates to the optic nerve head. *Surv Ophthalmol*. 1999;43: S17-26.
 49. Venkataraman ST, Flanagan JG, Hudson C. Vascular reactivity of optic nerve head and retinal blood vessels in glaucoma—a review. *Microcirculation*. 2010;17:568-581.
 50. Resch H, Garhofer G, Fuchsjäger-Mayrl G, Hommer A, Schmetterer L. Endothelial dysfunction in glaucoma. *Acta Ophthalmol*. 2009;87:4-12.
 51. Flammer J, Pache M, Resink T. Vasospasm, its role in the pathogenesis of diseases with particular reference to the eye. *Prog Retin Eye Res*. 2001;20:319-349.
 52. Wang Y, Lu A, Gil-Flamer J, Tan O, Izatt JA, Huang D. Measurement of total blood flow in the normal human retina using Doppler Fourier-domain optical coherence tomography. *Br J Ophthalmol*. 2009;93:634-637.