

## Five-year update on the mouse model of orthotopic lung transplantation: Scientific uses, tricks of the trade, and tips for success

Xue Lin<sup>1</sup>, Wenjun Li<sup>1</sup>, Jiaming Lai<sup>2</sup>, Mikio Okazaki<sup>1,3</sup>, Seiichiro Sugimoto<sup>1,4</sup>, Sumiharu Yamamoto<sup>1</sup>, Xingan Wang<sup>1</sup>, Andrew E. Gelman<sup>1,5</sup>, Daniel Kreisel<sup>1,5</sup>, Alexander Sasha Krupnick<sup>1</sup>

<sup>1</sup>Department of Surgery, <sup>2</sup>The First Affiliated Hospital of Sun Yat-sen University, Guangzhou 510080, China; <sup>3</sup>Center of Chest Medicine and Surgery, Ehime University, Ehime, Japan; <sup>4</sup>Department of Thoracic Surgery, Okayama University Hospital, Okayama, Japan; <sup>5</sup>Department of Pathology and Immunology, Washington University School of Medicine, USA

### ABSTRACT

It has been 5 years since our team reported the first successful model of orthotopic single lung transplantation in the mouse. There has been great demand for this technique due to the obvious experimental advantages the mouse offers over other large and small animal models of lung transplantation. These include the availability of mouse-specific reagents as well as knockout and transgenic technology. Our laboratory has utilized this mouse model to study both immunological and non-immunological mechanisms of lung transplant physiology while others have focused on models of chronic rejection. It is surprising that despite our initial publication in 2007 only few other laboratories have published data using this model. This is likely due to the technical complexity of the surgical technique and perioperative complications, which can limit recipient survival. As two of the authors (XL and WL) have a combined experience of over 2500 left and right single lung transplants, this review will summarize their experience and delineate tips and tricks necessary for successful transplantation. We will also describe technical advances made since the original description of the model.

### KEY WORDS

Mouse model; orthotopic lung transplantation; surgical complications; evaluation

*J Thorac Dis* 2012;4(3):247-258. DOI: 10.3978/j.issn.2072-1439.2012.06.02

### Introduction

As of 2011 our laboratory has successfully completed over 4,500 mouse orthotopic lung transplants as a part of investigator-initiated studies (1-20) and collaborations with biotechnological companies (21-30). While in the beginning of our experience technical obstacles were encountered, after an initial learning curve complications are now rare (less than 1%, not including post-transplantation atelectasis). Other laboratories have reported technical success rates of around 80-90% (9,26). As we have already described the rudimentary steps of this procedure (1,5), here we will focus only on major surgical complications that hinder experimental success. We will also discuss the causes

of technical failures and steps that can be taken to prevent them.

### Complications

#### *Pneumothorax*

The first type of pneumothorax (Type I pulmonary injury) stems from technical errors that occur due to excessive handling of the lung. This results in a severe air leak, mostly because of a bronchial tear, or damage to the lung surface. This becomes evident immediately after graft reperfusion and reoxygenation. This type of injury is worth repairing if the area of injury is small or the recipient is a very rare transgenic mouse. Although the mouse bronchus and lung tissue are very friable, one can still repair this form of damage by placing a shorter cuff on the torn bronchus to incorporate the area of damage into the cuff or utilize 10-0 nylon suture (SharpPoint AK-D106, Surgical Specialties Corporation, Figure 1) to repair a small hole in the donor or recipient bronchus. As for tiny defects on the graft surface one can use tissue glue to seal it (Webglue, Webster Veterinary Supply Inc, Figure 2). In our experience a successful repair of this type of injury is easy to achieve and the graft can often be salvaged.

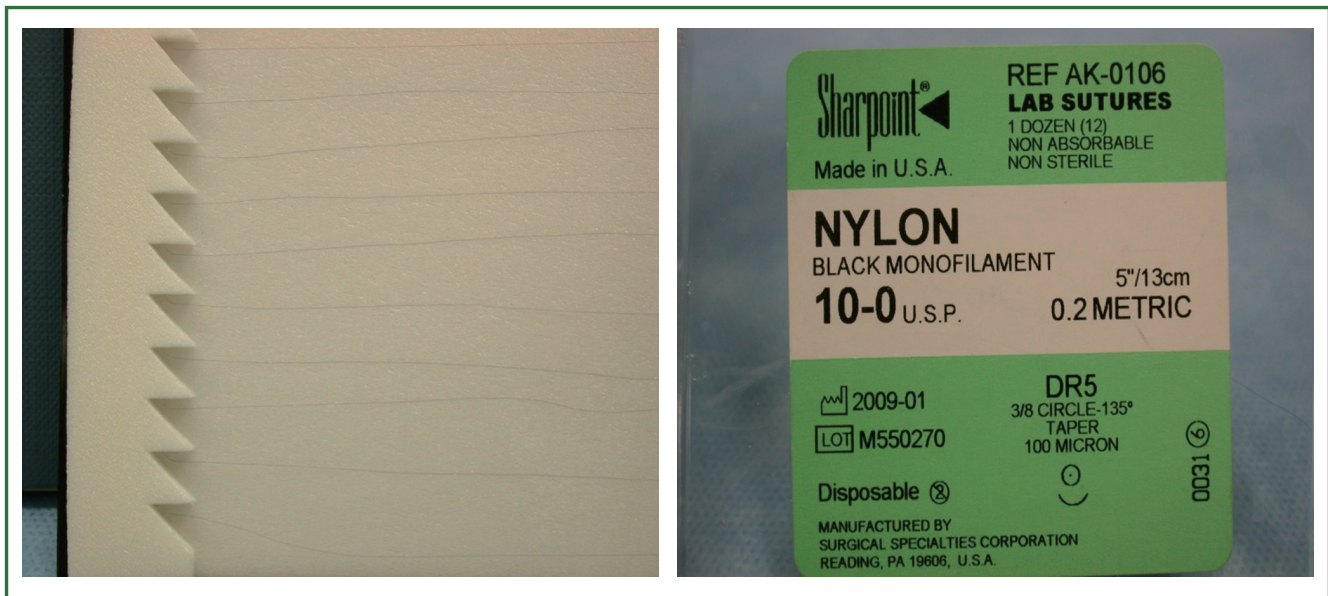
Corresponding to: Dr. Alexander Sasha Krupnick, Assistant Professor of Surgery, Campus Box 8234, 660 South Euclid Avenue, Washington University in St Louis, St Louis, MO 63110-1013, USA. Email: [krupnicka@wudosis.wustl.edu](mailto:krupnicka@wudosis.wustl.edu).

Submitted May 07, 2012. Accepted for publication Jun 05, 2012.

Available at [www.jthoracdis.com](http://www.jthoracdis.com)

ISSN: 2072-1439

© Pioneer Bioscience Publishing Company. All rights reserved.



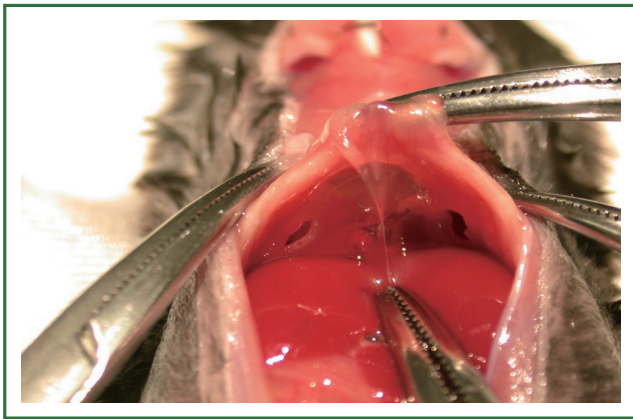
**Figure 1.** 10-0 Nylon for suturing tiny hole of bronchus.



**Figure 2.** Animal Surgical Glue for sealing small air leak of graft lung.

The second type of pneumothorax (Type II pulmonary injury) is more dangerous because the lung injury is small and may not be evident immediately upon release of the hilar structures. This is usually discovered only after extubation of the animal and is often manifested by respiratory distress and difficulty in initiating spontaneous respirations. Without immediate reintubation the recipient will die within 1 or 2 minutes and is unlikely to be resuscitated. In order to salvage this situation the animal must be quickly reintubated and the upper part of the abdomen opened. This will allow immediate diagnosis of the problem as either the left or the right side of the diaphragm will bulge down with an obvious tension pneumothorax. In our experience a Type II pulmonary injury can occur either on the side of the transplant or native lung. While the reason for this injury can be difficult to determine it may be related to the process of mechanical ventilation. In the

mouse the respiratory rate varies between 60-230 breaths per minute (bpm). The tidal volume can vary between 0.09-0.38 mL/breath resulting in a minute ventilation of 11-36 mL/min (31). Despite this physiology our preferred mouse ventilator settings include a tidal volume of 0.5 mL and a respiratory rate of 110-120 bpm, which yield minute ventilations exceeding the normal range. Other laboratories performing similar procedures recommend even higher tidal volumes (26). In our experience decreasing the minute ventilation for extended portions of the procedure leads to poor long-term outcome (unpublished data). During single lung ventilation, however, this high volume positive-pressure may cause barotrauma and volutrauma, which may lead to a Type II pulmonary injury (32). While serious, this complication is very rare (from our database we have encountered fewer than 20 cases in 5 years), and the severity of pulmonary damage is unpredictable. In order to prevent this complication we: (I) reduce the tidal volume from 0.5 mL to 0.35-0.40 mL when single lung ventilation is initiated and maintain this low tidal volume until the lung graft is implanted and (II) inflate the lung graft for no more than 1-2 seconds after implantation. However, if a pneumothorax does occur the only possible treatment is to reintubate the animal immediately, incise the upper abdomen and cut a small window in the diaphragm to release the air that has collected under tension in the chest. After recipient hemodynamics have stabilized the diaphragmatic window is left open and the abdominal incision is closed (Figure 3). If needed, one can close the diaphragm window at a later time point. However, it is unlikely that these salvage maneuvers will result in a ventilated lung at the time of sacrifice as atelectasis will occur after this type of injury. Therefore, mice can generally not be used for data generation if this complication arises.



**Figure 3. Diaphragm window for treatment of type II pulmonary injury.**

### **Graft atelectasis**

The anatomy of the mouse lung differs from that of other species (33). Total lung capacity (TLC) of the mouse is about 1ml compared to 10 ml in the rat. The alveoli of the mouse lung are significantly smaller than those of the rat (34) and the airways constitute a large percentage of the lung volume in the mouse (11%) compared to the rat (5.7%). Cartilage is present in the mouse trachea, but is less well organized than in other species. Mouse lungs also have fewer respiratory bronchioles and airway generations than humans. Two other significant features of the mouse lung anatomy are the thinness of the respiratory epithelium and the relatively large airway lumen (35). This large airway caliber may reduce the flow-resistive load in this small animal with a rapid respiratory rate (33). All of these characteristics work in favor of preventing atelectasis of the mouse lung in comparison to other animal models. Nevertheless, it has been brought to our attention that non-alloimmune-mediated collapse of the grafted lung, which is not associated with graft rejection, but rather due to technical problems, is the most common complication encountered by other laboratories. Thus, in our opinion, pulmonary atelectasis after transplantation is generally due to methodologic problems rather than inherent anatomic considerations.

Based on our experience and serial sacrifice, pulmonary collapse that is unrelated to graft rejection usually occurs on the third to fifth post-operative day after transplantation and is often not diagnosed until the time of sacrifice. The diagnosis of atelectasis is further complicated by the fact that mice do not manifest any outward signs of shortness of breath when this occurs (6). Furthermore, while non-invasive diagnostic tools such as small animal MRI are available to monitor pulmonary graft function after transplantation, the routine use of such modalities is impractical (Figure 4) (29). Thus, we contend that the best method for preventing graft atelectasis is to pay meticulous attention to surgical details and rely on several “tricks”

that we have accumulated over the years in order to prevent this complication.

In our mouse model, we believe pulmonary collapse occurs due to two main reasons. The first one involves pathophysiologic changes in pulmonary parenchyma after transplantation and the second one is technical failure. Graft ischemia-reperfusion injury alters graft compliance, increases air flow resistance and contributes to atelectatic collapse of the lung (36). Anastomotic problems of the small mouse bronchus also can lead to atelectasis and anastomotic ischemia followed by remodeling and granulation tissue formation, which leads to bronchial wall thickening and significant airway obstruction (37-39). Technical problems due to poor orientation of the cuff, donor to recipient cuff mismatch and other mishaps can lead to atelectatic collapse of the lung graft as well. While some have demonstrated that cuffing the bronchial anastomosis can be problematic and may lead to airway stenosis in the rat (36) the small size of the bronchial structures in the mouse makes suturing this structure nearly impossible (unpublished observations). Thus, while retaining the cuff technique for the bronchial anastomosis we have gradually modified the surgical approach and have made significant revisions in the method for cuffing this structure. First, we now shorten the donor bronchus as close as possible to the secondary carina in order to reduce anastomotic ischemia and improve the bronchial blood supply (40-43). This type of maneuver also results in the need to shorten the venous cuff in order to prevent rotation and torsion of the hilar structures. Second, we use as big a cuff as possible in order to reduce air flow resistance (with gain of experience some microsurgeons now cuff most strains of mice with a cuff made from a #18 angiocatheter instead of a #20 as we had previously described (5) (Figure 5). As the hilar anatomy of each strain differs (C3H and CBA/Ca mice for example have comparably foreshortened hilar structures) the size of the cuff must match each bronchus in order to achieve not only optimal ventilation, but also prevent venous complications (see below). After these modifications our incidence of graft atelectasis has decreased to <5%.

### **Pulmonary venous thrombosis**

This complication does not usually lead to immediate post-operative demise and is usually discovered at autopsy either due to recipient death before the scheduled sacrifice or at the time of sacrifice. Gross appearance of the graft can be diagnostic of pulmonary venous thrombosis as the lung is dark red or black, is grossly enlarged and firm. Often a clot can be seen in the pulmonary vein. At times the right upper lobe of the native lung can be involved as well due to propagation of clot. Venous thrombosis is usually caused by pulmonary vein torsion or compression of the venous outflow from a large bronchus cuff. Thus, one must balance the “trade off” of a large bronchial cuff,

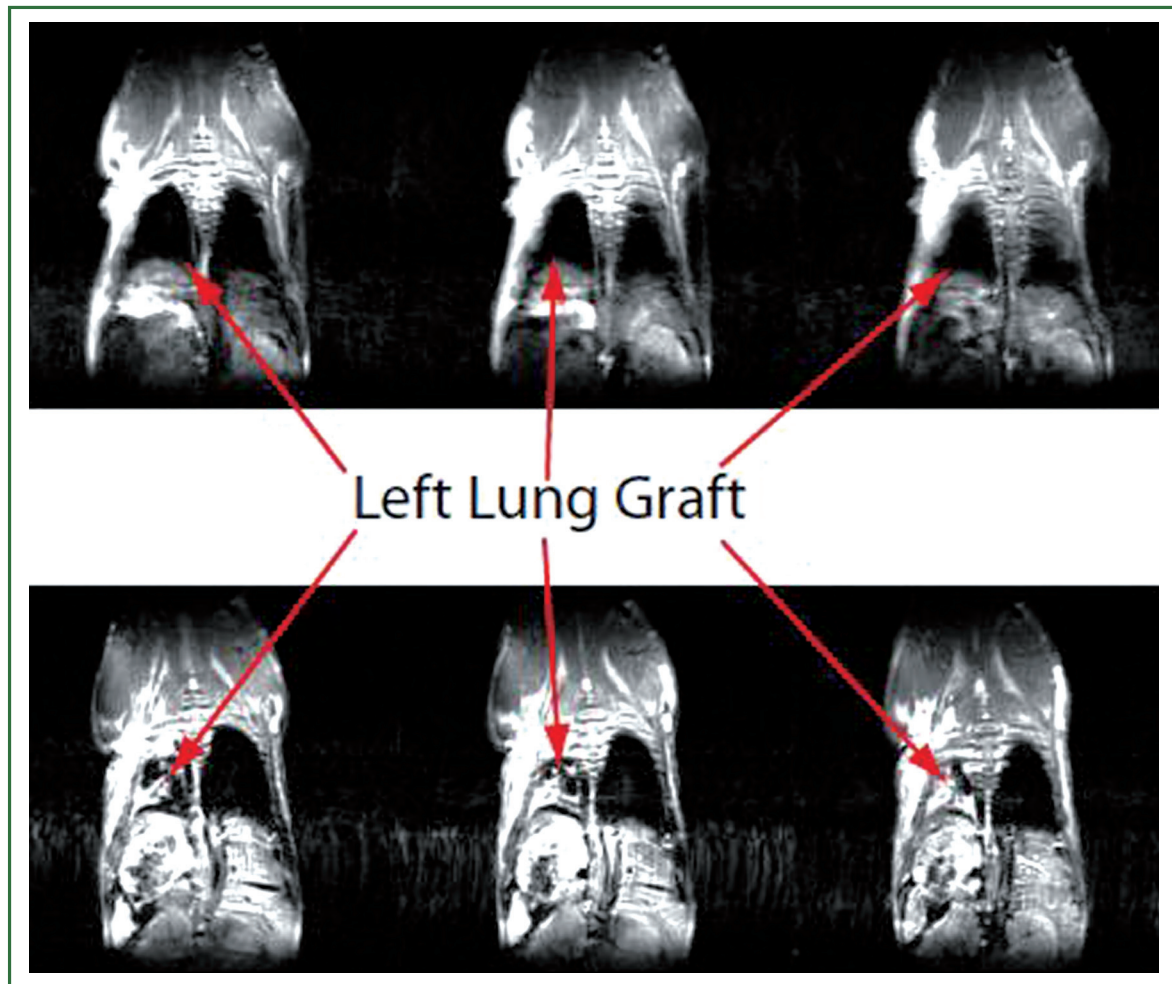


Figure 4. MRI images obtained 3 days after lung transplantation reveal ventilation of lung graft on three serial coronal images (top) and graft atelectasis in a different animal (bottom). As previously described (29) aerated lung looks black on MRI due to lack of signal intensity while a consolidated lung looks white due to the high intensity of this water-rich structure when atelectatic.




Figure 5. Adjustment of bronchus cuff size. From L to R, the size is 18#, 20# and 24#, which are used for bronchus, pulmonary vein, and pulmonary artery, respectively.

which results in a lower incidence of graft atelectasis, but a higher incidence of pulmonary venous thrombosis. Nevertheless, the incidence of this complication can be reduced to very low levels

by meticulous attention to detail in preventing venous torsion and proper cuffing of the hilar structures to reduce rotation of the lung by an imbalance between the bronchial and venous cuffs.

## Evaluation

### *Evaluation of technical success and rejection*

After technically successful lung transplantation the graft should be well aerated and perfused, even in the face of mild acute rejection. As mentioned above, unlike cardiac allografts, where early technical failure can be manifested by cessation of heart beat, the evaluation of the technical success of lung transplantation requires either gross inspection after sacrifice or radiographic imaging. Conventional imaging modalities, such as X-rays, lung perfusion scintigraphy or angiography may be

**Table 1. Classification and grading of pulmonary allograft rejection.**

A: Acute rejection	with/without	B.: Airway inflammation-lymphocytic bronchitis/bronchiolitis
Grade 0: None		Grade X: Ungradeable
Grade 1: Minimal		Grade 0: None
Grade 2: Mild		Grade 1R: Low grade
Grade 3: Moderate		Grade 2R: High grade
Grade 4: Severe		
C: Chronic airway rejection: bronchiolitis obliterans		
0: Absent		
1: Present		
D: Chronic vascular rejection: accelerated graft vascular sclerosis		
"R" denotes revised grade to avoid confusion with 1996 scheme. Stewart, S, Fishbein, MC, Snell, GI, et al. Revision of the 1996 working formulation for the standardization of nomenclature in the diagnosis of lung rejection. J Heart Lung Transplant 2007; 26:1229		

useful in humans and large animals, but are not practical for large throughput experiments in mice (44-48). Either the resolution of these techniques is not suitable to evaluate subtle pathological changes, or the techniques cannot be performed on a serial basis in the same animal (36). Greschus suggested Flat-Panel Volumetric Computer Tomography (fpVCT) as a precise tool to assess the success of rat orthotopic lung transplantation that can be used to follow the process of graft rejection with very high spatial resolution (36). Such a technique, however, might not be applicable to the mouse due to its small size. We have recently focused on small animal MRI to evaluate pulmonary pathology and have found this technique to be a highly reproducible non-invasive approach to visualize anatomic pathology of the lung such as pulmonary collapse due to either advanced acute rejection or atelectasis (29) (Figure 4). However, we realize that this modality might not be easily accessible to all laboratories and thus to date there still is no easily accessible, effective and precise imaging modality to evaluate the grafted lung for technical success or rejection. Our current practice thus relies on grading rejection based on strict histologic criteria, which mirror human graft evaluation. In 1990, the International Society for Heart and Lung Transplantation (ISHLT) adopted a "Working Formulation of the Standardization of the Nomenclature in the Diagnosis of Lung Rejection," which was revised in 1996 and again in 2007 (49). We have thus adapted this grading scale for the mouse model (Table 1). The development of better imaging modalities in the future may facilitate serial monitoring of graft outcome and early detection of technical failures.

### Evaluation of graft function

Mouse orthotopic lung transplantation is a very useful model not only because it mimics human lung transplantation, but because the investigator can collect samples that mimic clinical investigations of human lung transplant recipients, such as

arterial blood gases (ABGs), bronchioalveolar lavages (BALs), and lung parenchymal tissue. The most important tests, such as spirometry and plethysmography have been reported by some groups (21,50), but are not currently routinely used by us. To date our laboratory has relied mostly on arterial blood gas (ABG) measurement of a mouse supported solely by the lung graft after hilar clamping of the native lung to evaluate function as well as bronchoalveolar lavage, wet dry ratio, histology, FACS, and immunohistochemistry. We have focused on these tests as they mirror the techniques of perioperative graft assessment used in the clinics. Some of these techniques are described below.

### Arterial Blood Gas measurement(ABG)

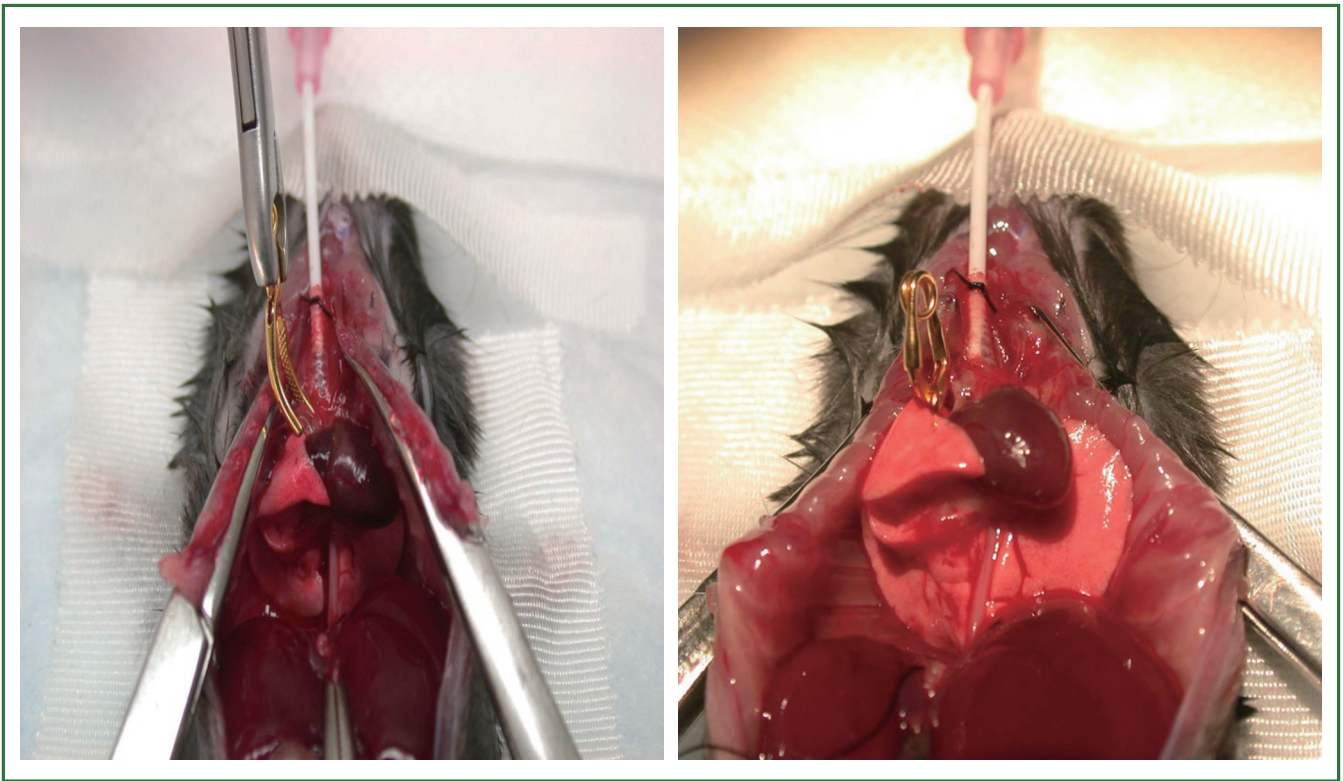
Our laboratory has relied on ABG measurement to assess graft function (1,6,16,18,19).

(I) Anesthetize the recipient mouse with an intraperitoneal (i.p) injection of Ketamine (5-6 µg/g) and Xylazine (7-8 µg/g). This is about 2/3 of the regular dose used during the actual transplantation procedure as often after transplantation the recipient cannot tolerate a regular dose of anesthetics (5).

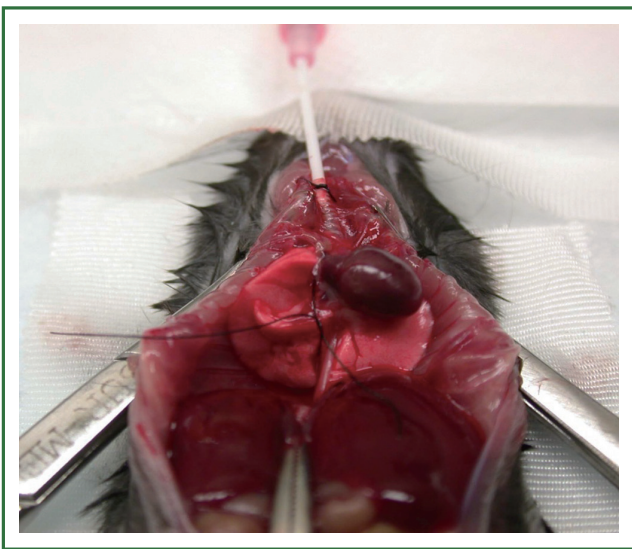
(II) Initiate mechanical ventilation of both lungs with 100% FiO<sub>2</sub> for 4 minutes prior to hilar clamping.

(III) Occlude the hilum of the native non-transplanted lung (use either a clip or a 6-0 silk tie. Figures 6, 7) and ventilate 4 to 10 more minutes prior to drawing blood.

Here, the microsurgeon needs to detach the right lower lobe from the esophagus very carefully and free the entire right lung (in case of left lung transplantation) from connective tissue without bleeding. The total circulating blood volume in the mouse is only around 2 mL (6-8% of whole body weight), and literally any blood loss will affect hemodynamics, result in circulatory instability and impact the ABG measurement. Ventilate both lungs for 4 minutes before occluding the native right lung in order to assess the function of the graft. The duration of single lung ventilation prior to drawing ABG is



**Figure 6.** Occlude the hilum of native non-transplanted lung with clip.



**Figure 7.** Occlude the hilum of native non-transplanted lung with 6-0 silk.

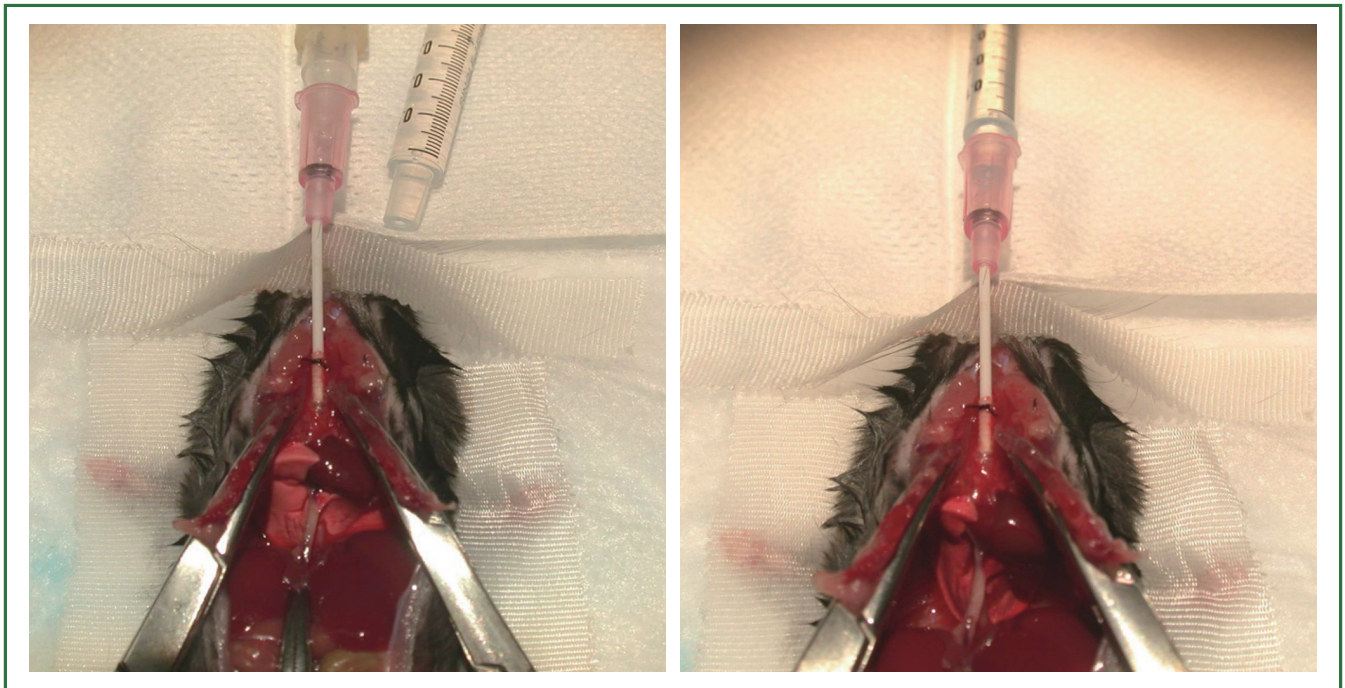
controversial and must be tailored based on experimental conditions (1,26). After transplantation either ischemia-reperfusion injury or graft rejection can cause severe lung graft dysfunction. Poor oxygenation as a result of this type of injury can lead to myocardial ischemia, heart failure, and death in approximately 10 minutes. As mice consume large quantities

of  $O_2$  even at rest (31,33), the fall in  $PaO_2$  and the associated oxyghemoglobin desaturation occurs fairly rapidly (51). Thus, in our experience drawing the ABG after 4 to 10 minutes of single lung ventilation will allow for a sensitive assessment of graft function with reliable and reproducible data obtained by matching the period of single lung ventilation between experimental and control groups.

(IV) Use a 1mL heparin coated syringe with 25 G needle to draw blood from the left ventricle or ascending aorta to measure ABG.

#### **Broncho-alveolar lavage (BAL)**

BAL is used to analyze the influx of inflammatory cells into the airways after human lung transplantation (52) and has been used by our laboratory to assess lung grafts (3,53). Using current techniques BAL fluid collection originates from both right and left lung as the lavage is performed with an open chest while intubating the main trachea (Figure 8). The advantage of this technique is that it is easy to perform but the disadvantage is that it mixes the airway cell infiltrates of the native and transplanted lung. Nevertheless, our data describe that airway inflammatory cells, such as neutrophils, correlate with tissue infiltration in the transplanted lung (4) and thus we have routinely utilized tracheal BAL to sample the airways and are currently developing methods to use a longer catheter that can be inserted into either



**Figure 8. The current method for BAL.**

the left or right lung selectively. Alternatively one can occlude the native lung in order to collect the BAL sample exclusively from the graft.

### **Two-photon microscopy**

As the lung is constantly exposed to both innocuous and potentially noxious antigens, a thorough understanding of both innate and adaptive immune responses in this organ is essential (30). Two-photon microscopy has evolved into a powerful tool that can allow for observation of cellular interactions in real time. Such a technique has allowed us to substantially extend our understanding of immune responses (54-59). Recently, our group has expanded 2-photon microscopy to the study of the inflammatory responses in the lung, which has allowed us to study ischemia reperfusion injury *in vivo* (28,55,56). By relying on this approach we were able to demonstrate that, contrary to popular belief, monocytes coordinate the transendothelial migration of neutrophils into inflamed tissue. We determined that depletion of blood monocytes impairs neutrophil recruitment to the lung, which could have important implications for the design of therapeutic strategies to treat inflammatory lung diseases (28). Based on this experience, we have expanded the use of intravital two-photon microscopy to investigate cellular trafficking behavior after lung transplantation.

### **Scientific uses of mouse orthotopic lung transplantation**

Lung transplantation is an established therapy for a variety of

end-stage pulmonary disease. Importantly, long-term outcome after lung transplantation are far worse than those of other solid organs (60). Immunologic and non-immunologic mechanisms that contribute to acute and chronic graft lung dysfunction remain poorly understood and the mouse lung transplantation model presents a unique tool that can allow us to study innate and adaptive immune responses after lung transplantation.

### **Ischemia-reperfusion (I-R) injury-mediated primary graft dysfunction (PGD)**

PGD is a form of acute lung injury that results from inflammatory changes induced by I-R injury (61). PGD is graded based on  $\text{PaO}_2/\text{FiO}_2$  (P/F) ratio and radiographic infiltrates assessed at several time points up to 72 hours after transplantation (Table 2). By definition this form of injury arises within the first 72 hours following lung transplantation and is a leading cause of early morbidity and mortality after transplantation. PGD is characterized by impaired oxygenation and pulmonary edema and affects up to 80% of all lung transplant recipients (62-68). In addition, PGD has been linked to the development of chronic allograft rejection manifested by bronchiolitis obliterans (69). Thus, a better knowledge of the pathophysiology of I-R injury should facilitate a better understanding of PGD. Biomarker phenotyping should become possible in order to develop novel therapeutics and reduce the impact of PGD on lung transplant outcomes (62). Neutrophils and factors that control their production and activation play a critical role in I-R injury. Over the last 5 years using the mouse model of orthotopic lung

**Table 2. ISHLT PGD grading schema.**

Grade	PaO <sub>2</sub> /FiO <sub>2</sub>	Radiographic Infiltrates Consistent with Pulmonary Edema
0	>300	Absent
1	>300	Present
2	200-300	Present
3	<200	Present

Time points for assessment: T (0 to within 6 hours of reperfusion, 24, 48, and 72 hours). Data from Christie JD, Carby M, Bag R, et al. Report of the ISHLT Working Group on Primary Lung Graft Dysfunction part II: definition. A consensus statement of the International Society for Heart and Lung Transplantation. *J Heart Lung Transplant* 2005;24:1458.

transplantation our group has focused heavily on this cell type. We have delineated that neutrophils isolated from the airways of lung transplantation recipients stimulate donor dendritic cells (DCs) in a contact-dependent fashion to augment their production of IL-12 and expand alloantigen-specific IFN- $\gamma$ (+) T cells. DC IL-12 expression is largely regulated by degranulation and induced by TNF- $\alpha$  associated with the neutrophil plasma membrane. Extended cold ischemic graft storage enhances G-CSF-mediated granulopoiesis and neutrophilic graft infiltration, resulting in exacerbation of I-R injury after lung transplantation. I-R injury prevents immunosuppression-mediated acceptance of mouse lung allografts unless G-CSF-mediated granulopoiesis is inhibited (19). In addition, we also identified that transcriptional coregulator B cell leukemia/lymphoma 3 (Bcl3) limits granulopoiesis under inflammatory conditions. Bcl3-deficient myeloid progenitors demonstrated an enhanced capacity to proliferate and differentiate into granulocytes following G-CSF stimulation, whereas the accumulation of Bcl3 protein attenuated granulopoiesis in an NF- $\kappa$ B p50-dependent manner (70). Future experiments will focus on therapeutic strategies to modulate the activation of and degranulation of neutrophils in order to ameliorate pulmonary graft injury.

#### **Acute cellular rejection (ACR)**

According to the ISHLT Registry, 36% of lung transplant recipients experience at least one episode of ACR within the first year after transplantation (71). Risk factors for ACR remain poorly defined. The degree of major histocompatibility antigen (MHC) discordance between donor and recipient has been identified as a risk factor in some studies (67-69,72). The mouse model of lung transplantation offers an ideal platform to study ACR as inbred mouse strains have well defined MHC antigens allowing for evaluation of ACR in fully mismatched, minor antigen mismatched, and partially matched (by using F1 crosses as graft donors for example) situations. Since the mouse lung transplantation model was established, we have verified

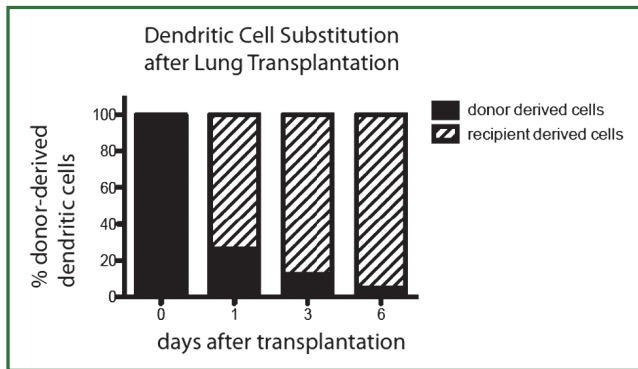
histopathologically and flow cytometrically that this new animal model can recapitulate acute lung allograft rejection successfully (1). We have also demonstrated that, similar to other organs (73), treatment of lung allografts with anti-CD28-B7 and CD40-CD40 Ligand co-stimulatory blockade can prolong allograft survival indefinitely in several strain combinations (7). Dodd-o and colleagues found that anti-CD154 antibody therapy alone is sufficient to attenuate ACR in an MHC mismatched mouse orthotopic lung transplant model. Improved lung allograft acceptance in anti-CD154 Ab treated recipients was associated with abrogated CD8+ and CD4+ allospecific effector responses and increased frequencies of CD4+CD25+Foxp3+ regulatory T-cells in the lung allografts (74). Our group has also provided evidence that pulmonary nonhematopoietic cells, through their expression of MHC-II, play a critical role in downregulating CD4+ T cell-mediated immune responses *in vivo* (2,4). Obviously, this new mouse model will allow for the design of novel studies that elucidate mechanisms of ACR and provide rationale for the development of therapeutic approaches.

#### **Chronic rejection – Obliterative bronchiolitis (OB)**

OB is a form of chronic rejection specific to the lung and is characterized by progressive fibrosis and obliteration of the small and medium-sized airways of the donor lung (75). The mechanisms leading to the development of this condition still remain unclear (76). Although lymphocytes are observed in the bronchial wall, the prominent cell type found in the BAL is neutrophils (77). Recently, evidence suggests the involvement of multiple factors such as excessive activation of innate immune responses, abnormal angiogenesis and failure of appropriate epithelial regeneration and fibroproliferative tissue remodeling (78). Laboratory experimentation using animal models forms an important component of a “bench-to bedside-to-bench” approach that can both increase our understanding and lead to the development of novel therapeutic strategies for this (76).

Of the several different animal OB models available, each has advantages and limitations. There is not an “ideal” model





**Figure 9. Rapid substitution of professional antigen presenting cells, such as dendritic cells, occurs after orthotopic lung transplantation.**

that precisely reproduces what happens to humans after lung transplantation. The lesions of OB are thought to represent the shared histological outcome of injury to the airway epithelium and subcellular matrix by an array of immune and inflammatory insults. From a clinical standpoint, OB remains heterogeneous, varying both in timing of onset after transplantation and aggressiveness in clinical course (79). So, it is not practical or scientifically desirable to test multiple contributing factors at the same time. Pulmonary chronic rejection shares features of chronic rejection observed in other solid organ. Chronic rejection in all organs mainly manifests as fibrosis in the graft resulting in loss of function and eventually grafts loss (80). There are several immunologic antigens involved in this fibrosis, including major and minor histocompatibility antigens (81) as well as self-antigens (82) as both can emerge as targets of immune responses after transplantation (83-85).

In theory the orthotopic mouse lung transplantation model has great advantages for studying the pathogenesis of OB as it offers a physiological model of the human lung transplant environment. Lung function and BAL can be assessed at various times, various drugs can be tested for efficacy, and transgenic and knock-out strains are available to model human diseases. However, several physiologic factors in the mouse lung anatomy and physiology create potential obstacles in the study of OB. The initial OB process starts with a lymphocytic infiltrate of the sub-mucosa of the airways followed by the migration of the lymphocytes through the basement membrane into the epithelium (86). At this site, epithelial cell necrosis occurs with denudation of mucosa. In the mouse lung, there is lack of submucosal glands in the bronchioles, but a high numbers of locally resident Clara cells. One of the main functions of Clara cells is to protect the bronchiolar epithelium from injury. They accomplish this by secreting a variety of proteins, including Clara cell secretory protein (CCSP) and a solution similar to lung surfactant. They are also responsible for detoxifying inhaled harmful substances. Clara cells also act as a stem cell and multiply to differentiate into ciliated cells

that can regenerate bronchiolar epithelium. This is a possible reason why mouse airway epithelium remains intact and fully differentiated in lung allografts, despite profound vascular rejection (7). Since 2007, a few separate groups have tried to establish an OB model in the mouse. Although two groups have found OB lesions by histology, the experimental design and the histological features still need further clarification (9,27). Currently we are focusing on three factors that may influence the development of OB including: (I) donor and recipient strain combinations; (II) time period necessary to see chronic rejection in the mouse and; (III) the form of immunosuppression that may allow for OB to develop. Once established and reproducible, such a model could hold great promise for further mechanistic studies and may be used to accelerate the development of new strategies for the prevention or treatment of pulmonary chronic rejection.

#### **Studies of Non-hematopoietic stromal cells**

While bone marrow-derived hematopoietic cells, such as dendritic cells, play a critical role in pulmonary physiology (87-92), we as well as others have focused on the contribution of non-hematopoietic cells in pulmonary immune responses (4,93). Traditional methods for separating the physiology of hematopoietic from non-hematopoietic cells involves the creation of bone marrow chimeras by lethal irradiation of a recipient mouse followed by reconstitution with bone marrow from a mutant strain (94). Donor irradiation, however, may change the physiology of non-hematopoietic cells and bone marrow chimeras can also suffer from autoimmune disease (4). We have recently demonstrated that the transplantation of a left lung into a congenic host leads to the rapid substitution of donor-derived hematopoietic cells with those of the host, leading to the creation of a "chimeric lung graft" in an otherwise immunocompetent host. Furthermore, such substitution occurs for multiple types of hematopoietic cells such as T cells (4,5) and dendritic cells (Figure 9). Such a model can thus be used to study both immunology and physiology of pulmonary non-hematopoietic cells in the absence of irradiation.

#### **Conclusions**

Although technically difficult, orthotopic lung transplantation in the mouse is feasible and reproducible. It has been used for multiple scientific avenues of investigation for the last 5 years by our laboratory as well as others. Obviously, it is important for researchers to understand the physiology behind this model as well as its advantages and limitations. Well-designed mouse orthotopic lung transplantation experiments provide a great opportunity to study mechanisms that affect lung allograft survival and explore new therapies for a wide variety of human lung diseases.

## Acknowledgements

Supported by American Thoracic Society/Lungevity Foundation, NIH 1R01HL094601, the Barnes Jewish Research Foundation, The American Association for Thoracic Surgery and the Thoracic Surgery Foundation for Research and Education.

*Disclosure:* The authors declare no conflict of interest.

## References

- Okazaki M, Krupnick AS, Kornfeld CG, et al. A mouse model of orthotopic vascularized aerated lung transplantation. *Am J Transplant* 2007;7:1672-9.
- Gelman AE, Okazaki M, Sugimoto S, et al. CCR2 regulates monocyte recruitment as well as CD4 T1 allorecognition after lung transplantation. *Am J Transplant* 2010;10:1189-99.
- Kreisel D, Lai J, Richardson SB, et al. Polarized alloantigen presentation by airway epithelial cells contributes to direct CD8+ T cell activation in the airway. *Am J Respir Cell Mol Biol* 2011;44:749-54.
- Kreisel D, Richardson SB, Li W, et al. Cutting edge: MHC class II expression by pulmonary nonhematopoietic cells plays a critical role in controlling local inflammatory responses. *J Immunol* 2010;185:3809-13.
- Krupnick AS, Lin X, Li W, et al. Orthotopic mouse lung transplantation as experimental methodology to study transplant and tumor biology. *Nat Protoc* 2009;4:86-93.
- Li W, Sugimoto S, Lai J, et al. Orthotopic vascularized right lung transplantation in the mouse. *J Thorac Cardiovasc Surg* 2010;139:1637-43.
- Okazaki M, Gelman AE, Tietjens JR, et al. Maintenance of airway epithelium in acutely rejected orthotopic vascularized mouse lung transplants. *Am J Respir Cell Mol Biol* 2007;37:625-30.
- Burlingham WJ, Love RB, Jankowska-Gan E, et al. IL-17-dependent cellular immunity to collagen type V predisposes to obliterative bronchiolitis in human lung transplants. *J Clin Invest* 2007;117:3498-506.
- Fan L, Benson HL, Vittal R, et al. Neutralizing IL-17 prevents obliterative bronchiolitis in murine orthotopic lung transplantation. *Am J Transplant* 2011;11:911-22.
- Shilling RA, Wilkes DS. Role of Th17 cells and IL-17 in lung transplant rejection. *Semin Immunopathol* 2011;33:129-34.
- Sumpter TL, Wilkes DS. Role of autoimmunity in organ allograft rejection: a focus on immunity to type V collagen in the pathogenesis of lung transplant rejection. *Am J Physiol Lung Cell Mol Physiol* 2004;286:L1129-39.
- Wilkes DS. Chronic lung allograft rejection and airway microvasculature: is HIF-1 the missing link? *J Clin Invest* 2011;121:2155-7.
- Yasufuku K, Heidler KM, Woods KA, et al. Prevention of bronchiolitis obliterans in rat lung allografts by type V collagen-induced oral tolerance. *Transplantation* 2002;73:500-5.
- Gelman AE, Okazaki M, Lai J, et al. CD4+ T lymphocytes are not necessary for the acute rejection of vascularized mouse lung transplants. *J Immunol* 2008;180:4754-62.
- Gelman AE, Li W, Richardson SB, et al. Cutting edge: Acute lung allograft rejection is independent of secondary lymphoid organs. *J Immunol* 2009;182:3969-73.
- Huang HJ, Sugimoto S, Lai J, et al. Maintenance of IKKbeta activity is necessary to protect lung grafts from acute injury. *Transplantation* 2011;91:624-31.
- Okazaki M, Sugimoto S, Lai J, et al. Costimulatory blockade-mediated lung allograft acceptance is abrogated by overexpression of Bcl-2 in the recipient. *Transplant Proc* 2009;41:385-7.
- Sugimoto S, Lin X, Okazaki M, et al. Monocyte differentiation is controlled by MyD88 after mouse orthotopic lung transplantation. *Transplant Proc* 2009;41:388-90.
- Kreisel D, Sugimoto S, Zhu J, et al. Emergency granulopoiesis promotes neutrophil-dendritic cell encounters that prevent mouse lung allograft acceptance. *Blood* 2011;118:6172-82.
- Jungraithmayr W, Weder W. The Technique of Orthotopic Mouse Lung Transplantation as a Movie-Improved Learning by Visualization. *Am J Transplant* 2012;12:1624-6.
- De Vleeschauwer S, Jungraithmayr W, Wauters S, et al. Chronic rejection pathology after orthotopic lung transplantation in mice: the development of a murine BOS model and its drawbacks. *PLoS ONE* 2012;7:e29802.
- Jungraithmayr W, De Meester I, Matheussen V, et al. CD26/DPP-4 inhibition recruits regenerative stem cells via stromal cell-derived factor-1 and beneficially influences ischaemia-reperfusion injury in mouse lung transplantation. *Eur J Cardiothorac Surg* 2012;41:1166-73.
- Jungraithmayr W, Draenert A, Marquardt K, et al. Ultrastructural changes in acute lung allograft rejection: novel insights from an animal study. *J Heart Lung Transplant* 2012;31:94-100.
- Iken K, Liu K, Liu H, et al. IDO and Metabolites Protect Mouse Lung Allografts and Impair Calcium Mobilization of T Cells. *Am J Respir Cell Mol Biol* 2012. [Epub ahead of print].
- Waki N, Yamane M, Yamamoto S, et al. Egr1: a novel target for ameliorating acute allograft rejection in an experimental lung transplant model. *Eur J Cardiothorac Surg* 2012;41:669-75.
- Jungraithmayr WM, Korom S, Hillinger S, et al. A mouse model of orthotopic, single-lung transplantation. *J Thorac Cardiovasc Surg* 2009;137:486-91.
- Kreisel D, Gelman AE, Palmer SM. In pursuit of new experimental models of obliterative bronchiolitis. *Am J Transplant* 2011;11:882-3.
- Kreisel D, Nava RG, Li W, et al. In vivo two-photon imaging reveals monocyte-dependent neutrophil extravasation during pulmonary inflammation. *Proc Natl Acad Sci USA* 2010;107:18073-8.
- Krupnick AS, Tidwell VK, Engelbach JA, et al. Quantitative monitoring of mouse lung tumors by magnetic resonance imaging. *Nat Protoc* 2012;7:128-42.
- Nava RG, Li W, Gelman AE, et al. Two-photon microscopy in pulmonary research. *Semin Immunopathol* 2010;32:297-304.
- Kling MA. A review of respiratory system anatomy, physiology, and disease in the mouse, rat, hamster, and gerbil. *Vet Clin North Am Exot Anim Pract* 2011;14:287-337.
- Morgan GE, Mikhail MS, Murray MJ. *Clinical anesthesiology*. 4th ed. New York: Lange Medical Books/McGraw Hill, Medical Pub. Division; 2006. xiv, 1105 p.p.
- Irvin CG, Bates JH. Measuring the lung function in the mouse: the

- challenge of size. *Respir Res* 2003;4:4.
34. Knudsen L, Weibel ER, Gundersen HJ, et al. Assessment of air space size characteristics by intercept (chord) measurement: an accurate and efficient stereological approach. *J Appl Physiol* 2010;108:412-21.
35. Gomes RF, Bates JH. Geometric determinants of airway resistance in two isomorphic rodent species. *Respir Physiol Neurobiol* 2002;130:317-25.
36. Greschus S, Kuchenbuch T, Plotz C, et al. Monitoring of experimental rat lung transplants by high-resolution flat-panel volumetric computer tomography (fpVCT). *J Invest Surg* 2009;22:69-75.
37. Santacruz JF, Mehta AC. Airway complications and management after lung transplantation: ischemia, dehiscence, and stenosis. *Proc Am Thorac Soc* 2009;6:79-93.
38. Tendulkar RD, Fleming PA, Reddy CA, et al. High-dose-rate endobronchial brachytherapy for recurrent airway obstruction from hyperplastic granulation tissue. *Int J Radiat Oncol Biol Phys* 2008;70:701-6.
39. Kennedy AS, Sonett JR, Orens JB, et al. High dose rate brachytherapy to prevent recurrent benign hyperplasia in lung transplant bronchi: theoretical and clinical considerations. *J Heart Lung Transplant* 2000;19:155-9.
40. Shennib H, Massard G. Airway complications in lung transplantation. *Ann Thorac Surg* 1994;57:506-11.
41. Van De Wauwer C, Van Raemdonck D, Verleden GM, et al. Risk factors for airway complications within the first year after lung transplantation. *Eur J Cardiothorac Surg* 2007;31:703-10.
42. Mulligan MS. Endoscopic management of airway complications after lung transplantation. *Chest Surg Clin N Am* 2001;11:907-15.
43. Choong CK, Sweet SC, Zoole JB, et al. Bronchial airway anastomotic complications after pediatric lung transplantation: incidence, cause, management, and outcome. *J Thorac Cardiovasc Surg* 2006;131:198-203.
44. Marck KW, Piers DA, Wildevuur CR. Lung transplantation in the rat: II. lung perfusion scintigraphy in normal and left lung-transplanted rats. *Ann Thorac Surg* 1982;34:81-8.
45. Marck KW, Prop J, Wildevuur CR. Lung transplantation in the rat. III. Functional studies in iso- and allografts. *J Surg Res* 1983;35:149-58.
46. Zweers N, Petersen AH, van der Hoeven JA, et al. Donor brain death aggravates chronic rejection after lung transplantation in rats. *Transplantation* 2004;78:1251-8.
47. Reis A, Giaid A, Serrick C, et al. Improved outcome of rat lung transplantation with modification of the nonsuture external cuff technique. *J Heart Lung Transplant* 1995;14:274-9.
48. Yuh DD, Gandy KL, Morris RE, et al. Leflunomide prolongs pulmonary allograft and xenograft survival. *J Heart Lung Transplant* 1995;14:1136-44.
49. Stewart S, Fishbein MC, Snell GI, et al. Revision of the 1996 working formulation for the standardization of nomenclature in the diagnosis of lung rejection. *J Heart Lung Transplant* 2007;26:1229-42.
50. Vanoirbeek JA, Rinaldi M, De Vooght V, et al. Noninvasive and invasive pulmonary function in mouse models of obstructive and restrictive respiratory diseases. *Am J Respir Cell Mol Biol* 2010;42:96-104.
51. Lee EJ, Woodske ME, Zou B, et al. Dynamic arterial blood gas analysis in conscious, unrestrained C57BL/6J mice during exposure to intermittent hypoxia. *J Appl Physiol* 2009;107:290-4.
52. Heron M, Grutters JC, Ten Dam-Molenkamp KM, et al. Bronchoalveolar lavage cell pattern from healthy human lung. *Clin Exp Immunol* 2012;167:523-31.
53. Vikis HG, Gelman AE, Franklin A, et al. Neutrophils are required for 3-methylcholanthrene-initiated, butylated hydroxytoluene-promoted lung carcinogenesis. *Mol Carcinog* 2011. [Epub ahead of print].
54. Miller MJ, Wei SH, Parker I, et al. Two-photon imaging of lymphocyte motility and antigen response in intact lymph node. *Science* 2002;296:1869-73.
55. Cahalan MD, Parker I, Wei SH, et al. Two-photon tissue imaging: seeing the immune system in a fresh light. *Nat Rev Immunol* 2002;2:872-80.
56. Cahalan MD, Parker I, Wei SH, et al. Real-time imaging of lymphocytes in vivo. *Curr Opin Immunol* 2003;15:372-7.
57. Miller MJ, Wei SH, Cahalan MD, et al. Autonomous T cell trafficking examined in vivo with intravital two-photon microscopy. *Proc Natl Acad Sci USA* 2003;100:2604-9.
58. Miller MJ, Hejazi AS, Wei SH, et al. T cell repertoire scanning is promoted by dynamic dendritic cell behavior and random T cell motility in the lymph node. *Proc Natl Acad Sci USA* 2004;101:998-1003.
59. Miller MJ, Safrina O, Parker I, et al. Imaging the single cell dynamics of CD4+ T cell activation by dendritic cells in lymph nodes. *J Exp Med* 2004;200:847-56.
60. Trulock EP, Edwards LB, Taylor DO, et al. Registry of the International Society for Heart and Lung Transplantation: twenty-third official adult lung and heart-lung transplantation report--2006. *J Heart Lung Transplant* 2006;25:880-92.
61. Lee JC, Christie JD. Primary graft dysfunction. *Clin Chest Med* 2011;32:279-93.
62. Christie JD, Bavaria JE, Palevsky HI, et al. Primary graft failure following lung transplantation. *Chest* 1998;114:51-60.
63. Christie JD, Kotloff RM, Pochettino A, et al. Clinical risk factors for primary graft failure following lung transplantation. *Chest* 2003;124:1232-41.
64. Arcasoy SM, Kotloff RM. Lung transplantation. *N Engl J Med* 1999;340:1081-91.
65. Christie JD, Van Raemdonck D, de Perrot M, et al. Report of the ISHLT Working Group on Primary Lung Graft Dysfunction part I: introduction and methods. *J Heart Lung Transplant* 2005;24:1451-3.
66. Arcasoy SM, Fisher A, Hachem RR, et al. Report of the ISHLT Working Group on Primary Lung Graft Dysfunction part V: predictors and outcomes. *J Heart Lung Transplant* 2005;24:1483-8.
67. Christie JD, Carby M, Bag R, et al. Report of the ISHLT Working Group on Primary Lung Graft Dysfunction part II: definition. A consensus statement of the International Society for Heart and Lung Transplantation. *J Heart Lung Transplant* 2005;24:1454-9.
68. King RC, Binns OA, Rodriguez F, et al. Reperfusion injury significantly impacts clinical outcome after pulmonary transplantation. *Ann Thorac Surg* 2000;69:1681-5.
69. Daud SA, Yusef RD, Meyers BF, et al. Impact of immediate primary lung allograft dysfunction on bronchiolitis obliterans syndrome. *Am J Respir Crit Care Med* 2007;175:507-13.
70. Kreisel D, Sugimoto S, Tietjens J, et al. Bcl3 prevents acute inflammatory lung injury in mice by restraining emergency granulopoiesis. *J Clin Invest*

- 2011;121:265-76.
71. Kotloff RM, Thabut G. Lung transplantation. *Am J Respir Crit Care Med* 2011;184:159-71.
72. Palmer SM, Burch LH, Davis RD, et al. The role of innate immunity in acute allograft rejection after lung transplantation. *Am J Respir Crit Care Med* 2003;168:628-32.
73. Larsen CP, Elwood ET, Alexander DZ, et al. Long-term acceptance of skin and cardiac allografts after blocking CD40 and CD28 pathways. *Nature* 1996;381:434-8.
74. Dodd-o JM, Lendermon EA, Miller HL, et al. CD154 blockade abrogates allospecific responses and enhances CD4(+) regulatory T-cells in mouse orthotopic lung transplant. *Am J Transplant* 2011;11:1815-24.
75. Sato M, Keshavjee S, Liu M. Translational research: animal models of obliterative bronchiolitis after lung transplantation. *Am J Transplant* 2009;9:1981-7.
76. De Vleeschauwer S, Vanaudenaerde B, Vos R, et al. The need for a new animal model for chronic rejection after lung transplantation. *Transplant Proc* 2011;43:3476-85.
77. Estenne M, Maurer JR, Boehler A, et al. Bronchiolitis obliterans syndrome 2001: an update of the diagnostic criteria. *J Heart Lung Transplant* 2002;21:297-310.
78. Sato M, Keshavjee S. Bronchiolitis obliterans syndrome: alloimmune-dependent and -independent injury with aberrant tissue remodeling. *Semin Thorac Cardiovasc Surg* 2008;20:173-82.
79. Todd JL, Palmer SM. Bronchiolitis obliterans syndrome: the final frontier for lung transplantation. *Chest* 2011;140:502-8.
80. Rocha PN, Plumb TJ, Crowley SD, et al. Effector mechanisms in transplant rejection. *Immunol Rev* 2003;196:51-64.
81. Dierselhuis M, Goulmy E. The relevance of minor histocompatibility antigens in solid organ transplantation. *Curr Opin Organ Transplant* 2009;14:419-25.
82. Fukami N, Ramachandran S, Saini D, et al. Antibodies to MHC class I induce autoimmunity: role in the pathogenesis of chronic rejection. *J Immunol* 2009;182:309-18.
83. Rolls HK, Kishimoto K, Dong VM, et al. T-cell response to cardiac myosin persists in the absence of an alloimmune response in recipients with chronic cardiac allograft rejection. *Transplantation* 2002;74:1053-7.
84. Barber LD, Whitelegg A, Madrigal JA, et al. Detection of vimentin-specific autoreactive CD8+ T cells in cardiac transplant patients. *Transplantation* 2004;77:1604-9.
85. Carter V, Shenton BK, Jaques B, et al. Vimentin antibodies: a non-HLA antibody as a potential risk factor in renal transplantation. *Transplant Proc* 2005;37:654-7.
86. Yousem SA. Lymphocytic bronchitis/bronchiolitis in lung allograft recipients. *Am J Surg Pathol* 1993;17:491-6.
87. Grayson MH, Holtzman MJ. Emerging role of dendritic cells in respiratory viral infection. *J Mol Med (Berl)* 2007;85:1057-68.
88. Hammad H, Lambrecht BN. Lung dendritic cell migration. *Adv Immunol* 2007;93:265-78.
89. Ray P, Krishnamoorthy N, Ray A. Emerging functions of c-kit and its ligand stem cell factor in dendritic cells: regulators of T cell differentiation. *Cell Cycle* 2008;7:2826-32.
90. Suzuki T, Chow CW, Downey GP. Role of innate immune cells and their products in lung immunopathology. *Int J Biochem Cell Biol* 2008;40:1348-61.
91. Lambrecht BN, Hammad H. The role of dendritic and epithelial cells as master regulators of allergic airway inflammation. *Lancet* 2010;376:835-43.
92. Chiappori AA, Soliman H, Janssen WE, et al. INGN-225: a dendritic cell-based p53 vaccine (Ad.p53-DC) in small cell lung cancer: observed association between immune response and enhanced chemotherapy effect. *Expert Opin Biol Ther* 2010;10:983-91.
93. Hollingsworth JW, Theriot BS, Li Z, et al. Both hematopoietic-derived and non-hematopoietic-derived {beta}-arrestin-2 regulates murine allergic airway disease. *Am J Respir Cell Mol Biol* 2010;43:269-75.
94. Kreisel D, Krupnick AS, Gelman AE, et al. Non-hematopoietic allograft cells directly activate CD8+ T cells and trigger acute rejection: an alternative mechanism of allorecognition. *Nat Med* 2002;8:233-9.



**Cite this article as:** Lin X, Li W, Lai J, Okazaki M, Sugimoto S, Yamamoto S, Wang X, Gelman AE, Kreisel D, Krupnick AS. Five-year update on the mouse model of orthotopic lung transplantation: Scientific uses, tricks of the trade, and tips for success. *J Thorac Dis* 2012;4(3):247-258. DOI: 10.3978/j.issn.2072-1439.2012.06.02