


A millimeter miss is as good as a thousand miles: The role of accurate target localization in lung stereotactic body radiation therapy

Allan Y. Chen¹, Michelle B. Chen², Yi-Jen Chen²

¹Department of Radiation Oncology, The Permanente Medical Group, Sacramento, CA, USA; ²Radiation Oncology, City of Hope Medical Center, Duarte, CA, USA

J Thorac Dis 2012;4(2):109-111. DOI: 10.3978/j.issn.2072-1439.2012.03.12



Allan Y. Chen, M.D., Ph.D

Surgical intervention with lobectomy and mediastinal lymph node dissection is considered the treatment of choice in early stage non-small cell lung cancer (NSCLC) (1). However, approximately 20-25% of patients with early stage NSCLC are poor surgical candidates for lobectomy because of concomitant severe cardiac or pulmonary co-morbidities. For these patients, conventional radiotherapy with 60 to 70 Gy delivered in 30-35 fractions over a 6-7-week period generally resulted in poor 20-40% 3-year and 10-30% 5-year survival rates (2,3). This inadequate tumor control is mainly due to the insufficient tumor dose that is limited by normal tissue toxicity and possible target-miss caused by tumor mobility.

Stereotactic body radiation therapy (SBRT), or stereotactic ablative radiotherapy (SABR), has been emerging as an excellent alternative for medically inoperable early stage NSCLC patients. Conceptually derived from cranial stereotactic radiosurgery, the planning and delivery of SBRT is characterized by highly target-conformal dose distributions with steep dose gradients towards normal tissues, allowing the administration of potent tumor-ablative radiation doses. In lung SBRT, a total of 45-50 Gy of radiation is delivered in 3-5 fractions over a 10-20 days' duration. Calculated by LQ with $\alpha/\beta=10$ Gy, a less than 5 cm tumor is generally treated with higher than 100 biologically equivalent dose (BED). Available data demonstrated an impressive 80-95% local tumor control at 2-5 years and good lung function preservation (3-6). The recently published RTOG 0236 phase II study demonstrated 3-years 98% local tumor control and 56% survival (7). This result is quite comparable to the reported 53% 5-year survival with surgical resection, based on thousands of patients in the International Association for the Study of Lung Cancer Staging Project (8). Lung SBRT is comparably superior than radiofrequency ablation (RFA), an alternative invasive procedure with a moderate 60% tumor control rate for less than 3 cm tumors, but is also associated with much higher procedure-related morbidities, mainly caused by pneumothorax and hemorrhage (9).

How to accurately locate small pulmonary targets for lung SBRT is the subject of one article published in this issue of Journal of Thoracic Disease. In their study, Shen *et al.* investigated the application of double CT imaging to measure the respiratory movement of small pulmonary tumors during SBRT (10). A total of 122 small pulmonary tumors in 45 patients were measured.

No potential conflict of interest.

Corresponding to: Allan Y. Chen, MD, PhD. Department of Radiation Oncology, The Permanente Medical Group, Sacramento, CA, USA. Tel: 916-631-2786; Fax: 916-631-2710. Email: allan.y.chen@kp.org.

Submitted Mar 08, 2012. Accepted for publication Mar 15, 2012.

Available at www.jthoracdis.com

ISSN: 2072-1439

© Pioneer Bioscience Publishing Company. All rights reserved.

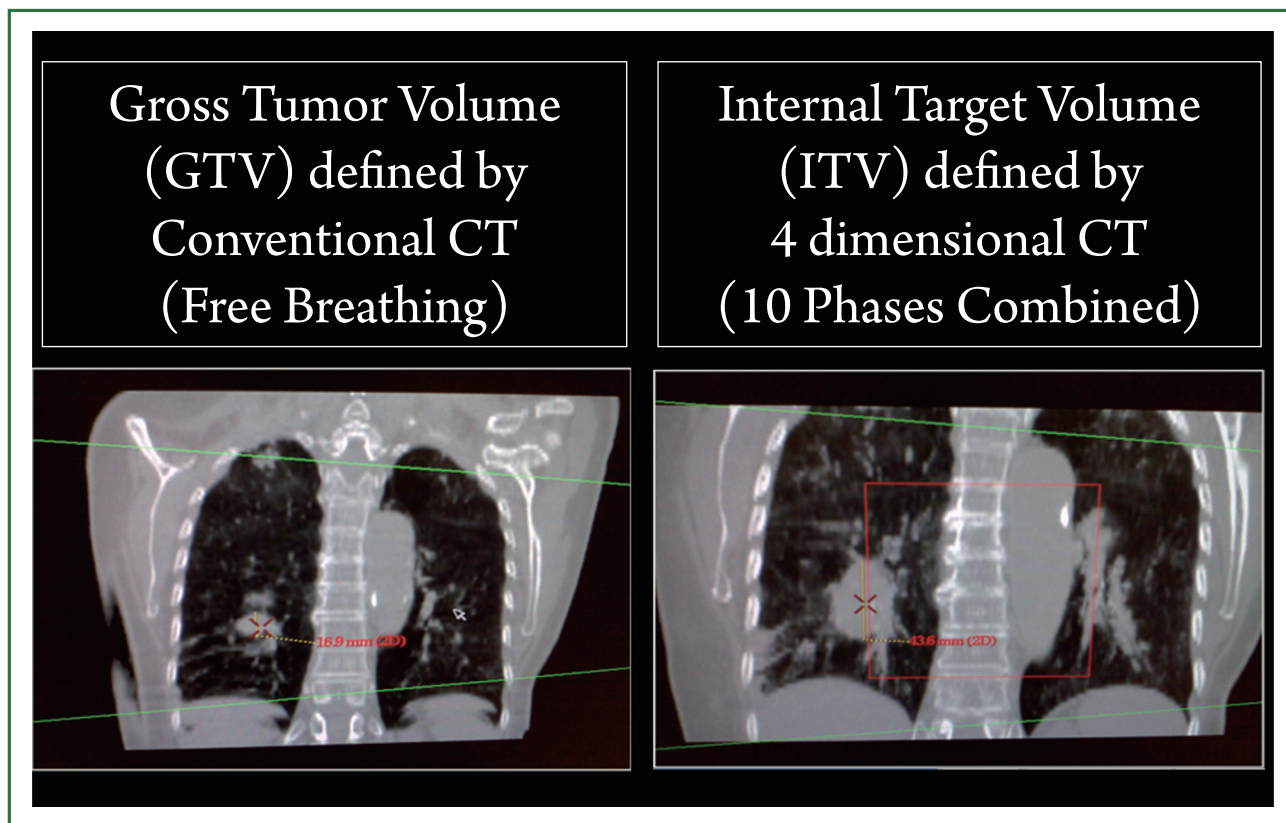


Figure 1. Four-dimensional CT (4D-CT) reduces motion artifact and allows accurate determination of internal target volume (ITV) for small-sized pulmonary tumors.

Four-slice spiral CT scans were conducted twice in all patients—once each at the end of quiet inhalation and of exhalation, and three times in 17 patients - with one additional free breathing image. The displacement of the tumor center in three directions was measured. The study showed an overall 3D motion of 10.10 ± 7.16 mm in 122 tumors, with 1.96 ± 2.03 , 5.19 ± 4.69 and 7.38 ± 6.48 mm in the X, Y and Z directions, respectively. The extent of tumor motion was influenced by the pulmonary location of individual tumor: greater motion was noted in tumors in the lower, left and anterior locations than in the upper, right and posterior locations. In contrast to 4-dimensional CT, this is a relatively less expansive, yet practical method for target localization. Their conclusions are in general agreement with published results (11).

The success of lung SBRT relies largely on accurate target localization, which enables precise ablative radiotherapy to target while maximizing the spared surrounding normal tissues from treatment-related side effects. It is an eminent observation that small-sized lung tumors are moving targets, which changes not only their locations, but also their shapes and volumes as the lung inflates and deflates. In addition, respiratory-induced motion can cause severe geometrical distortion of tumors and normal tissues in free breathing CT scanning. A variety of methods and techniques have been used to determine the exact

location of a moving target inside of lung. Voluntary breath-holding during imaging and treatment represents one simple, but often problematic approach in many lung cancer patients due to poor lung function and anxiety issues. Four-dimensional CT (4D-CT) is currently considered a standard methodology to reduce motion artifact and allow accurate determination of internal target volume (ITV; Figure 1). In 4D-CT, an over-sampled spiral CT scan with continuous slices is acquired simultaneously, while the respiratory motion (arbitrarily divided into 10 phases) is recorded by an infrared camera-based motion-tracking system (12). 4D-CT is capable of accurately defining the location and volume of the tumor and its surrounding organs over time during breathing cycles.

A famous Chinese idiom - "A Millimeter Miss is as Good as a Thousand Miles" applies to how in medicine, even slightly subtle errors may lead to huge consequences. Target localization for lung SBRT represents one such situation, in which inaccuracy in millimeters may result in the dire consequence of treatment failure.

References

1. Wright G, Manser RL, Byrnes G, Hart D, Campbell DA. Surgery for non-small cell lung cancer: systematic review and meta-analysis of randomised controlled trials. *Thorax* 2006;61:597-603.

2. Sibley GS, Jamieson TA, Marks LB, Anscher MS, Prosnitz LR. Radiotherapy alone for medically inoperable stage I non-small-cell lung cancer: the Duke experience. *Int J Radiat Oncol Biol Phys* 1998;40:149-54.
3. Cheung PC, Mackillop WJ, Dixon P, Brundage MD, Youssef YM, Zhou S. Involved-field radiotherapy alone for early-stage non-small-cell lung cancer. *Int J Radiat Oncol Biol Phys* 2000;48:703-10.
4. Henderson M, McGarry R, Yiannoutsos C, Fakiris A, Hoopes D, Williams M, et al. Baseline pulmonary function as a predictor for survival and decline in pulmonary function over time in patients undergoing stereotactic body radiotherapy for the treatment of stage I non-small-cell lung cancer. *Int J Radiat Oncol Biol Phys* 2008;72:404-9.
5. Kavanagh, B. D. & Timmerman, R. D., (eds.). "Stereotactic Body Radiation Therapy". Lippincott Williams Wilkins: Philadelphia, 2005.
6. Onishi H, Shirato H, Nagata Y, Hiraoka M, Fujino M, Gomi K, et al. Hypofractionated stereotactic radiotherapy (HypoFXSRT) for stage I non-small cell lung cancer: updated results of 257 patients in a Japanese multi-institutional study. *J Thorac Oncol* 2007;2:S94-100.
7. Timmerman R, Paulus R, Galvin J, Michalski J, Straube W, Bradley J, et al. Stereotactic body radiation therapy for inoperable early stage lung cancer. *JAMA* 2010;303:1070-6.
8. Rusch VW, Crowley J, Giroux DJ, Goldstraw P, Im JG, Tsuboi M, et al. The IASLC Lung Cancer Staging Project: proposals for the revision of the N descriptors in the forthcoming seventh edition of the TNM classification for lung cancer. *J Thorac Oncol* 2007;2:603-12.
9. Haasbeek CJ, Senan S, Smit EF, Paul MA, Slotman BJ, Lagerwaard FJ. Critical review of nonsurgical treatment options for stage I non-small cell lung cancer. *Oncologist* 2008;13:309-19.
10. Shen G, Wang YJ, Sheng HG, Duan XP, Wang JL, Zhang WJ, et al. Double CT imaging can measure the respiratory movement of small pulmonary tumors during stereotactic ablative radiotherapy. *J Thorac Dis* 2012;4:131-40.
11. "Image-Guided Radiotherapy of Lung Cancer", Cox, J. D., Chang J. Y. & Komaki R., (ed.), informa, Health care Communications, 2007. Available online: <http://informahealthcare.com/doi/pdf/10.3109/9780849387821>
12. Vedam SS, Keall PJ, Kini VR, Mostafavi H, Shukla HP, Mohan R. Acquiring a four-dimensional computed tomography dataset using an external respiratory signal. *Phys Med Biol* 2003;48:45-62.

Cite this article as: Chen AY, Chen MB, Chen YJ. A millimeter miss is as good as a thousand miles: The role of accurate target localization in lung stereotactic body radiation therapy. *J Thorac Dis* 2012;4(2):109-111. DOI: 10.3978/j.issn.2072-1439.2012.03.12