

5. Mätz-Rensing K, Jentsch KD, Rensing S, Langenhuysen S, Verschoor E, Niphuis H, et al. Fatal herpes simplex infection in a group of common marmosets (*Callithrix jacchus*). *Vet Pathol.* 2003;40:405–11. doi:10.1354/vp.40-4-405
6. Bruno SF, Liebhold M, Mätz-Rensing K, Romão MA, Didier A, Brandes A, et al. Herpesvirus infection in free-living black-tufted-ear marmoset (*Callithrix penicillata* E. Geoffroy 1812) at the state park of Serra da Tiririca, Niterói, Rio de Janeiro, Brazil. *Berl Munch Tierarztl Wochenschr.* 1997;110:427–30.
7. Kalter SS, Heberling RL. Comparative virology of primates. *Bacteriol Rev.* 1971;35:310–64.
8. Mansfield K. Emerging and re-emerging infectious diseases of nonhuman primates. Proceedings of the American College of Veterinary Pathologists/American Society for Veterinary Clinical Pathology Concurrent Annual Meeting, San Antonio, Texas, USA. November 15–19, 2008.
9. Bruno SF, Hilsberg S, Guimarães LF, de Barreto Netto MR, de Mello Affonso PRA, et al. Observations of two species of *Callithrix* in the State of Serra da Tiririca, Niterói, Rio de Janeiro, Brazil. Proceedings of American Association of Zoo Veterinarians, Houston, USA. 1997.
10. Coimbra-Filho AF. Situação atual dos calitriquideos que ocorrem no Brasil. Anais do 1º Congresso Sociedade Brasileira de Primatologia, Belo Horizonte, Brazil, 1983.

Address for correspondence: Camila S. Longa, Empresa de Pesquisa Agropecuária, Alameda São Boaventura, 770, Niterói, Rio de Janeiro CEP 24.120-191, Brazil; email: mila.longa@gmail.com



## Melioidosis in Birds and *Burkholderia pseudomallei* Dispersal, Australia

**To the Editor:** Melioidosis is an emerging infectious disease of humans and animals caused by the gram-negative bacterium *Burkholderia pseudomallei*, which inhabits soil and surface water in the disease-endemic regions of Southeast Asia and northern Australia (1). The aim of this study was to assess the potential for birds to spread *B. pseudomallei*. Birds are known carriers of various human pathogens, including influenza viruses, West Nile virus, *Campylobacter jejuni*, and antimicrobial drug-resistant *Escherichia coli* (2).

During February–August 2007, we conducted a survey to determine *B. pseudomallei* carriage in 110 wild native finches and doves from the melioidosis-endemic Darwin region, Northern Territory, Australia. Swab specimens from the beaks, feet, cloacae, and feces were cultured for *B. pseudomallei* as described (3). One healthy (normal physical appearance, weight, and hematocrit) native peaceful dove (*Geopelia placida*) at a coastal nature reserve was found to carry *B. pseudomallei* in its beak. The peaceful dove is a common, sedentary, ground-foraging species in the Darwin region. *B. pseudomallei* was not detected in environmental samples from the capture site, but *B. pseudomallei* is known to occur within 3 km of the capture site (4), the typical movement range for this bird species. On multilocus sequence typing (MLST) (5), the *B. pseudomallei* isolate was identified as sequence type (ST) 144, which we have previously found in humans and soil within 30 km of the site.

Numerous cases of melioidosis in birds have been documented (online Technical Appendix, [www.cdc.gov/EID/content/17/7/1310-Techapp.pdf](http://www.cdc.gov/EID/content/17/7/1310-Techapp.pdf)).

However, these are mostly birds in captivity and often exotic to the location, suggesting potential reduced immunity. Little is known about melioidosis in wild birds. In Sabah, Malaysia, only 1 of 440 wild birds admitted to a research center over 9 years was found to have melioidosis (6).

Although birds are endotherms, with high metabolic rates and body temperature (40°C–43°C) protecting them from many diseases, some birds appear more susceptible to melioidosis. Indeed, high body temperature would not deter *B. pseudomallei*, which is routinely cultured at 42°C and at this temperature shows increased expression of a signal transduction system, which is involved in pathogenesis (7).

Examples of birds with fatal melioidosis in our studies in the Darwin region include a domesticated emu in 2009 with *B. pseudomallei* cultured from brain tissue and a chicken in 2007 with *B. pseudomallei* cultured from facial abscesses. In 2007, an outbreak of melioidosis occurred in an aviary; 4 imported exotic yellow-bibbed lorikeets (*Lorius chlorocercus*) died within months of arriving from a breeder in South Australia. On necropsy, the birds showed nodules throughout the liver and spleen (Figure). *B. pseudomallei* was cultured from the liver, spleen, crop, beak, and rectum. At the aviary, *B. pseudomallei* was also found in water from sprinklers, the water bore head, soil next to the bore, and the drain of the aviary. The unchlorinated sprinkler system used to cool the aviary was identified as the likely source of infection. MLST and 4-locus multilocus variable-number tandem repeat analysis (8) suggested a point-source outbreak with an identical 4-locus multilocus variable-number tandem repeat analysis pattern and ST for all *B. pseudomallei* isolated from the diseased birds and the sprinkler system. The ST was novel (ST673),

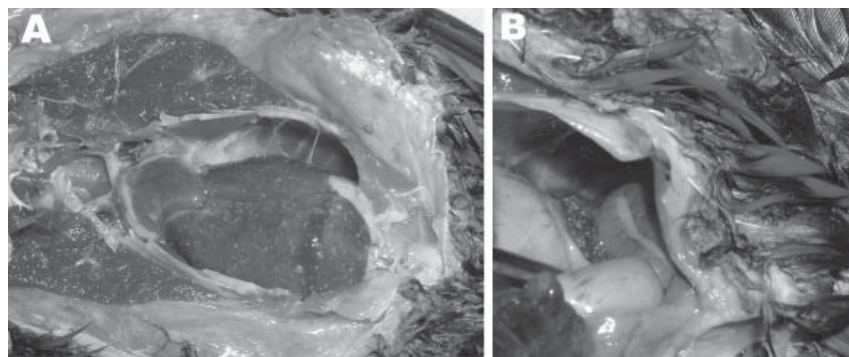


Figure. Images from necropsy of yellow-bibbed lorikeet that died of melioidosis, showing multiple diffuse nodular lesions in the liver (A) and spleen (B). Photographs by Jodie Low Choy. A color version of this figure is available online ([www.cdc.gov/EID/content/17/7/1310-F.htm](http://www.cdc.gov/EID/content/17/7/1310-F.htm)).

with no single-locus variants in the global MLST dataset.

Although an infected exotic or captive bird is likely to quickly die from melioidosis, our survey suggests that native birds are not very susceptible to infection with *B. pseudomallei* and resulting disease. Further studies are required to quantify the carriage of *B. pseudomallei* in wild native birds in melioidosis-endemic locations. Nevertheless, although no direct proof exists for spread of *B. pseudomallei* by birds, our finding of an asymptomatic native bird with *B. pseudomallei* in its beak supports the hypothesis of potential dispersal of these bacteria by birds from melioidosis-endemic regions to previously uncontaminated areas. For instance, carriage by birds could explain the introduction of *B. pseudomallei* to New Caledonia in the Pacific, 2,000 km east of Australia. *B. pseudomallei* strains from New Caledonia are related by MLST to Australian strains; 1 strain is a single-locus variant of a strain from Australia's east coast (9). Vagrant water birds are known to irregularly disperse from eastern tropical Australia to the southwestern Pacific, presumably driven by drought and offshore winds (G. Dutson, pers. comm.). Thus, *B. pseudomallei* could have been introduced to New Caledonia by an infected bird that flew there from northeastern Australia.

In summary, melioidosis is uncommon in wild birds but occurs in captive or exotic birds brought to melioidosis-endemic locations. Asymptomatic carriage of *B. pseudomallei* can occur in wild birds but appears to be unusual. We believe the risk for spread of *B. pseudomallei* by birds is low, but such occurrence does provide a possible explanation for the spread of melioidosis from Australia to offshore islands.

#### Acknowledgments

We are grateful to Cathy Shilton for advice and to the owners of the lorikeet aviary for their enthusiastic cooperation and help. We also thank the Charles Darwin University Animal Ethics Committee and Northern Territory Parks and Wildlife Commission for permission to trap wild birds, collect swab specimens, and release the wild birds.

**Vanya Hampton,<sup>1</sup>  
Mirjam Kaestli,<sup>1</sup> Mark Mayo,  
Jodie Low Choy,  
Glenda Harrington,  
Leisha Richardson,  
Suresh Benedict,  
Richard Noske,  
Stephen T. Garnett,  
Daniel Godoy, Brian G. Spratt,  
and Bart J. Currie**

<sup>1</sup>These authors contributed equally to this article.

Author affiliations: Menzies School of Health Research—Charles Darwin University, Darwin, Northern Territory, Australia (V. Hampton, M. Kaestli, M. Mayo, J. Low Choy, G. Harrington, L. Richardson, B.J. Currie); School for Environmental Research—Charles Darwin University, Darwin (R. Noske, S.T. Garnett); Berrimah Veterinary Laboratories, Darwin (S. Benedict); and Imperial College, London, UK (D. Godoy, B.G. Spratt)

DOI: 10.3201/eid1707.100707

#### References

- Cheng AC, Currie BJ. Melioidosis: epidemiology, pathophysiology, and management. *Clin Microbiol Rev.* 2005;18:383–416 [erratum in *Clin Microbiol Rev.* 2007;20:533].
- Reed KD, Meece JK, Henkel JS, Shukla SK. Birds, migration and emerging zoonoses: West Nile virus, Lyme disease, influenza A and enteropathogens. *Clin Med Res.* 2003;1:5–12.
- Mayo M, Kaestli M, Harrington G, Cheng A, Ward L, Karp D, et al. *Burkholderia pseudomallei* in unchlorinated domestic bore water, tropical northern Australia. *Emerg Infect Dis.* 2011;17:1283–5.
- Kaestli M, Mayo M, Harrington G, Ward L, Watt F, Hill JV, et al. Landscape changes influence the occurrence of the melioidosis bacterium *Burkholderia pseudomallei* in soil in northern Australia. *PLoS Negl Trop Dis.* 2009;3:e364.
- Godoy D, Randle G, Simpson A, Aanensen D, Pitt T, Kinoshita R, et al. Multilocus sequence typing and evolutionary relationships among the causative agents of melioidosis and glanders, *Burkholderia pseudomallei* and *Burkholderia mallei*. *J Clin Microbiol.* 2003;41:2068–79.
- Ouah A, Zahedi M, Perumal R. Animal melioidosis surveillance in Sabah. *The Internet Journal of Veterinary Medicine.* 2007;2 [cited 2011 May 16]. [http://www.ispub.com/journal/the\\_internet\\_journal\\_of\\_veterinary\\_medicine/volume\\_2\\_number\\_2/article/animal\\_melioidosis\\_surveillance\\_in\\_sabah.html](http://www.ispub.com/journal/the_internet_journal_of_veterinary_medicine/volume_2_number_2/article/animal_melioidosis_surveillance_in_sabah.html)
- Mahfouz ME, Grayson TH, Dance DA, Gilpin ML. Characterization of the mrgRS locus of the opportunistic pathogen *Burkholderia pseudomallei*: temperature regulates the expression of a two-component signal transduction system. *BMC Microbiol.* 2006;6:70.
- Currie BJ, Haslem A, Pearson T, Hornstra H, Leadem B, Mayo M, et al. Identification of melioidosis outbreak by multilocus variable number tandem repeat analysis. *Emerg Infect Dis.* 2009;15:169–74.

9. Le Hello S, Currie BJ, Godoy D, Spratt BG, Mikulski M, Lacassin F, et al. Melioidosis in New Caledonia. *Emerg Infect Dis*. 2005;11:1607–9.

Address for correspondence: Bart J. Currie, Menzies School of Health Research, PO Box 41096, Casuarina, NT 0811, Australia; email: bart@menzies.edu.au

## Rare Case of Trichomonal Peritonitis

**To the Editor:** Trichomonads are flagellated protozoa with several species capable of infecting or colonizing humans. The most common, *Trichomonas vaginalis*, causes genitourinary infection in adults and, rarely, respiratory infections in premature neonates of infected mothers. *Pentatrichomonas hominis* has been isolated from the human gastrointestinal tract, and *Trichomonas tenax*, a human oropharynx commensal, has caused empyema in immunocompromised persons. Rare cases of human peritonitis caused by trichomonads have been reported.

Some trichomonads, including *Tritrichomonas foetus* and *Tritrichomonas suis*, primarily infect and colonize animals. Although they were previously thought to be different species, current molecular and biologic evidence suggests they are indistinguishable (1). *T. foetus* (synonym *T. suis*) causes genitourinary infection in cattle and diarrhea in cats and colonizes the gastrointestinal tract of swine.

We report *T. foetus* peritonitis in a 52-year-old man with common variable immunodeficiency, rheumatoid arthritis, splenectomy, and cryptogenic cirrhosis. In June 2007,

he was admitted with peritonitis to a community hospital in Pennsylvania, United States. He lived on a farm that had swine, horses, and cats. Exposure to cattle was unknown. He denied having a history of sexually transmitted infections or high-risk sexual behavior.

Initial examination showed paracentesis fluid with numerous motile, flagellated organisms consistent with trichomonads. Bacterial fluid cultures had no growth. Despite receiving antimicrobial drugs (including metronidazole 500 mg intravenously every 6 hours), he became increasingly ill over the following 72 hours with hypotension, acute renal failure, and metabolic acidosis, which required transfer to Penn State Milton S. Hershey Medical Center (Hershey, PA, USA) for further care.

Upon arrival, the man was afebrile but hypotensive and tachycardic. Abdominal examination showed ascites, decreased bowel sounds, and diffuse tenderness. Genitourinary examination results were normal. Repeat paracentesis demonstrated numerous motile trichomonads. Urinalysis and routine cultures of peritoneal fluid and blood were negative. Computed tomography of the abdomen and pelvis showed edematous bowel, ascites, and peritonitis. His condition deteriorated during the following 48 hours. Despite ongoing treatment with broad-spectrum antimicrobial drugs (including metronidazole 500 mg intravenously every 6 hours), he died of multiorgan failure.

Autopsy showed peritonitis with copious intraabdominal exudate and peripancreatic and perigastric abscesses. No intestinal perforation or genitourinary abnormalities were noted. No portal of entry for peritoneal infection was identified. Premortem abdominal fluid samples were sent to the Centers for Disease Control and Prevention (Atlanta, GA, USA) for analysis.

DNA was extracted from the trichomonad culture and peritoneal

fluid by using the QIAamp DNA mini-kit (QIAGEN, Valencia, CA, USA). PCR testing for *T. vaginalis* was performed (2). PCR for *T. foetus* was performed by using primers TFR3 and TFR4 with thermocycling conditions outlined previously (3). PCR was performed in a 50- $\mu$ L reaction volume with 1  $\mu$ L of deoxynucleoside triphosphate mix (12.5 mmol/L each of dATP, dCTP, dGTP, and 5 mmol/L of dUTP; Applied Biosystems, Foster City, CA, USA), 5  $\mu$ L of MgCl<sub>2</sub> (25 mmol/L; Applied Biosystems), 0.2  $\mu$ M each primer, 2.5U of AmpliTaq Gold polymerase (Applied Biosystems), 5  $\mu$ L of 10 $\times$  PCR buffer (Applied Biosystems), and 5  $\mu$ L of DNA. PCR products were analyzed on an Agilent 2100 Bioanalyzer (Agilent Technologies, Palo Alto, CA, USA). Amplicons were purified with the QIAquick PCR purification kit (QIAGEN) and directly sequenced with PCR primers on an ABI 3130-XL Genetic Analyzer (Applied Biosystems). Sequences were assembled and aligned with Lasergene software (DNASTAR, Inc., Madison, WI, USA) and deposited in GenBank (accession no. HQ849063).

Metronidazole sensitivity was tested with methods previously described (4). The patient's trichomonads had minimal lethal concentration (MLC) of 3.1  $\mu$ g/mL for metronidazole, similar to MLCs of the known metronidazole-sensitive *T. vaginalis* isolate. *T. vaginalis* metronidazole MLCs >50  $\mu$ g are associated with resistance (5).

PCR performed by using primers TFR3/4 produced a 348-bp amplicon with DNA extracted from peritoneal fluid and culture (Figure). Comparison of DNA sequence from the parasite to GenBank sequences showed 100% identity with cattle isolates of *T. foetus*.

Two human cases of *T. foetus* infection have been reported. *T. foetus* was identified by PCR in the respiratory tract of a patient with AIDS and pneumonia (6) and