

Published in final edited form as:

*J Neurol Neurosurg Psychiatry*. 2012 April ; 83(4): 358–364. doi:10.1136/jnnp-2011-301883.

## Atypical, slowly progressive behavioral variant frontotemporal dementia associated with *C9ORF72* hexanucleotide expansion

Baber K. Khan, B.A.<sup>1</sup>, Jennifer S. Yokoyama, PhD<sup>1</sup>, Leonel T. Takada, M.D.<sup>1</sup>, Sharon J. Sha, M.D.<sup>1</sup>, Nicola J. Rutherford, B.Sc.<sup>2</sup>, Jamie C. Fong, M.S., CGC<sup>1</sup>, Anna Karydas, B.A.<sup>1</sup>, Teresa Wu, B.A.<sup>1</sup>, Robin Ketelle, RN<sup>1</sup>, Matt C. Baker, B.Sc.<sup>2</sup>, Mariely-Dejesus Hernandez, B.S.<sup>2</sup>, Giovanni Coppola, M.D.<sup>3</sup>, Daniel H. Geschwind, M.D., PhD<sup>3</sup>, Rosa Rademakers, PhD<sup>2</sup>, Suzee E. Lee, M.D.<sup>1</sup>, Howard J. Rosen, M.D.<sup>1</sup>, Gil D. Rabinovici, M.D.<sup>1</sup>, William Seeley, M.D.<sup>1</sup>, Katherine P. Rankin, PhD<sup>1</sup>, Adam L. Boxer, M.D., PhD<sup>1,\*</sup>, and Bruce L. Miller, M.D.<sup>1</sup>

<sup>1</sup>Department of Neurology, University of California, San Francisco, San Francisco, CA

<sup>2</sup>Department of Neuroscience, Mayo Clinic Florida, Jacksonville, FL

<sup>3</sup>Departments of Psychiatry & Neurology, and Semel Institute for Neuroscience and Human Behavior, University of California Los Angeles, Los Angeles, CA

### Abstract

**Background**—Some patients meeting behavioral variant frontotemporal dementia (bvFTD) diagnostic criteria progress slowly and plateau at mild symptom severity. Such patients have mild neuropsychological and functional impairments, lack characteristic bvFTD brain atrophy, and have thus been referred to as bvFTD “phenocopies” or slowly progressive (bvFTD-SP). The few patients with bvFTD-SP that have been studied at autopsy have found no evidence of FTD

\*Corresponding author: Adam L. Boxer, MD, PhD, UCSF Memory and Aging Center, Box 1207, San Francisco, CA 94143-1207, (415)-476-0668 (w), (415)-476-0679 (f).

Authorship Contributions – all authors meet criteria for authorship

Baber Khan contributed to study design, data interpretation, manuscript preparation and manuscript revision

Jennifer Yokoyama contributed to study design, data interpretation, imaging analyses, statistical analysis, manuscript preparation and manuscript revision

Leonel Takada contributed to study design, data interpretation, manuscript preparation and manuscript revision

Sharon Sha contributed to study design, data interpretation, manuscript preparation and manuscript revision

Nicola Rutherford contributed to genetic data acquisition and manuscript revision

Jamie Fong contributed to genetic data interpretation and manuscript revision

Anna Karydas contributed to genetic data acquisition, data interpretation and manuscript revision

Teresa Wu contributed to data acquisition and manuscript revision

Robin Ketelle contributed to CDR data acquisition and manuscript revision

Matt C. Baker contributed to data acquisition and manuscript revision

Mariely-Dejesus Hernandez contributed to genetic data acquisition, data interpretation and manuscript revision

Giovanni Coppola contributed to study design, data interpretation, genetic data acquisition and manuscript revision

Daniel Geschwind contributed to study design, data interpretation, genetic data acquisition and manuscript revision

Rosa Rademakers contributed to study design, data interpretation and manuscript revision

Suzee Lee contributed to data collection, data interpretation and manuscript revision

Howard Rosen contributed to data collection, data interpretation and manuscript revision

Gil Rabinovici contributed to PET scan data acquisition, data interpretation and manuscript revision

William Seeley contributed to study design, imaging data interpretation and manuscript revision

Katherine Rankin contributed to study design, data interpretation, social-emotional data acquisition, statistical analyses and manuscript revision

Adam Boxer contributed to study design, data interpretation and manuscript revision

Bruce Miller contributed to study design, data interpretation and manuscript revision

**Competing Interests:** Rosa Rademakers has a patent pending for the *C9ORF72* non-coding expansion. All other authors report no competing interests.

pathology, suggesting that bvFTD-SP is neuropathologically distinct from other forms of FTD. Here, we describe two patients with bvFTD-SP with *chromosome 9 open reading frame 72* (*C9ORF72*) hexanucleotide expansions.

**Methods**—Three hundred and eighty-four patients with FTD clinical spectrum and Alzheimer’s disease diagnoses were screened for *C9ORF72* expansion. Two bvFTD-SP mutation carriers were identified. Neuropsychological and functional data, as well as brain atrophy patterns assessed using voxel-based morphometry (VBM), were compared with 44 patients with sporadic bvFTD and 85 healthy controls.

**Results**—Both patients were age 48 at baseline and met possible bvFTD criteria. In the first patient, VBM revealed thalamic and posterior insula atrophy. Over seven years, his neuropsychological performance and brain atrophy remained stable. In the second patient, VBM revealed cortical atrophy with subtle frontal and insular volume loss. Over two years, her neuropsychological and functional scores as well as brain atrophy remained stable.

**Conclusions**—*C9ORF72* mutations can present with a bvFTD-SP phenotype. Some bvFTD-SP patients may have neurodegenerative pathology, and *C9ORF72* mutations should be considered in patients with bvFTD-SP and a family history of dementia or motor neuron disease.

### Keywords

C9ORF72; C9FTD/ALS; frontotemporal dementia; genetics; dementia

## INTRODUCTION

Behavioral variant frontotemporal dementia (bvFTD) is a neurodegenerative clinical syndrome characterized by insidious behavioral and personality changes. One lingering challenge to bvFTD diagnostic criteria [1] is that some patients meeting criteria present with a slowly progressive course (bvFTD-SP) and plateau at mild symptom severity.[2] These patients have been referred to as bvFTD “phenocopies” because, although their behavioral features resemble bvFTD, they do not display typical patterns of brain atrophy or hypometabolism at baseline,[3, 4] nor do they show progressive volume loss typical of bvFTD, leading some authors to suggest that the syndrome is not caused by a neurodegenerative disease.[1, 5, 6] The few individuals who have been examined with brain autopsy did not show FTLT pathology,[1] and because these patients often have normal life spans,[1] large pathological series are not available, leaving the neuropathological correlates of bvFTD-SP unclear.

Despite estimates from one group that “phenocopies” may account for one-third of patients with bvFTD,[2] there has yet to be a study linking bvFTD-SP to a known FTD-associated mutation. Recently, a hexanucleotide expansion in *chromosome 9 open reading frame 72* (*C9ORF72*) was shown to be the most common genetic abnormality in both familial and sporadic bvFTD and amyotrophic lateral sclerosis (ALS), with bvFTD being the major phenotype in carriers with a dementia syndrome.[7, 8] All patients examined have displayed FTLT-TDP pathology.[9, 10] Here we report two patients who were diagnosed with bvFTD-SP at the University of California, San Francisco (UCSF) and have *C9ORF72* expansions. The presence of the *C9ORF72* (*C9FTD/ALS*) mutation in these patients suggests that some patients with bvFTD-SP may have slowly progressive FTD with pathological inclusions containing TDP-43, the protein associated with bvFTD and ALS in *C9ORF72* mutation carriers.[7, 8]

## METHODS

### Participant selection

Three hundred and eighty-four patients with FTD clinical spectrum diagnoses and possible or probable Alzheimer's disease (AD) diagnoses (NINDS-ADRDA research criteria) were tested for *C9ORF72* expansion (Figure 1). Eighty-seven patients had a diagnosis of bvFTD (n=61) or FTD-ALS (n=26). Twenty-three (bvFTD=13; FTD-ALS=10) of the 87 patients carried the mutation (C9+). No patient with a non-bvFTD clinical syndrome was C9+. Four patients (2 C9+, 2 C9-) were identified as bvFTD-SP. Patients were identified as bvFTD-SP if they met the following criteria: 1) symptomatic for a  $\geq 5$  years, 2) met FTD Consortium (FTDC) international criteria for bvFTD (possible or probable), [11] 3) no decline on the clinical dementia rating sum of boxes (CDR-SB) score over at least 2 years after initial evaluation, and 4) little or no atrophy on visual assessment of structural magnetic resonance imaging (MRI) at the most recent evaluation. The follow-up period in criterion 3 was used in a previous study by another group to identify bvFTD-SP.[2] Demographic and non-neurological clinical data have been modified to maintain anonymity. All study participants (or their surrogates) provided written informed consent, and all study procedures were approved by local institutional review board.

### Genotyping

The GGGGCC hexanucleotide repeat expansion in *C9ORF72* was detected using a two-step polymerase chain reaction (PCR) based protocol as previously described.[7] Briefly, the hexanucleotide repeat was amplified in all samples using one fluorescently-labeled PCR primer. Next, fragment length analysis was performed on an automated ABI3730 DNA-analyzer. All patients that appeared homozygous in this assay were next analyzed using a repeat-primed PCR method, where characteristic stutter amplification pattern on electropherogram was considered evidence of pathogenic *C9ORF72* expansion.

### Imaging

Each patient underwent structural MR scanning on a 1.5T (2005–2006), 3T (2009–11), or 4T (2007–2008) and images were preprocessed for voxel-based morphometry (VBM) using DARTEL running in SPM5 with Matlab version 7.7 (scanner protocols and preprocessing previously described).[12] Single-subject VBM of combined gray-white matter images for each patient's initial scan were compared to 50 healthy controls selected to match each patient in age (within a decade) and scanner type. Because single-subject VBM typically lacks statistical power to detect regions of clinically significant atrophy, unthresholded maps were generated to depict the full extent of each patient's atrophy relative to controls. For comparative purposes, maps were also generated using 20 patients with C9- bvFTD and 164 healthy controls. Positron emission tomography (PET) with the beta-amyloid ligand [11C]PIB and [18F]-labeled fluorodeoxyglucose (FDG) was performed, using previously described methods,[13] on one of the C9+ patients with bvFTD-SP.

### Neuropsychological and Social-Emotional Testing

Each patient was tested with a previously described neuropsychological exam (Table 1).[14] For comparative purposes, neuropsychological data from 44 C9- patients with typical bvFTD (age:  $61.8 \pm 6.6$  years [range 46–83]; education:  $16.1 \pm 2.4$  years; gender 36.3% female; CDR:  $1.1 \pm 0.5$  [range 0.5–2]; CDR-SB:  $6.8 \pm 2.8$  [range 1.5–14] and FAQ:  $17.8 \pm 7.6$ ) and 85 cognitively normal middle-aged controls are shown (age range 50–64; education:  $17.8 \pm 2.6$  years; 50 female/35 male). Clinically significant impairment (performance less than the 5<sup>th</sup> percentile relative to control subjects) was identified by converting patient raw

scores to Z-scores. Social-emotional functioning was quantified using previously described methods.[15]

## CASE REPORTS

### Patient 1

Patient 1 was a 48-year-old right-handed man referred for evaluation after a five-year history of personality change, memory and visuospatial dysfunction, and an inability to work. His first symptoms were misplacing objects, getting lost in familiar neighborhoods, and forgetting song lyrics. Soon thereafter, he experienced spells during which he would become unresponsive and uncooperative for hours, several times per week. At night, he would walk through his home aimlessly, resisting re-direction from his wife. The patient became progressively more rigid regarding dietary preferences, eating fixed meals and requiring his family to adopt similar dietary restrictions. After being fired from his job for violating protocols, he developed severe anxiety and depression, and attempted suicide.

The patient then sought medical attention. He was first diagnosed with post-traumatic stress disorder (PTSD) and depression, and later with bipolar disorder type II. Although psychiatric medications were effective for many of his psychiatric symptoms, he developed increasing memory difficulties; he began to lose his train of thought mid-sentence, and developed word finding difficulty. Previously an involved father, the patient was indifferent when his child was hospitalized and became increasingly unsympathetic towards friends and family. He became compulsively fixated on computer games and began to have delusions about his family, accusing them of lying to him. These changes prompted an evaluation at our center.

Patient 1 reported a lifetime of dysthymia and superimposed major depression. He had no history of head injury or loss of consciousness and had never taken acetylcholinesterase inhibitors or memantine. He obtained a Master's degree and worked successfully as a mortician for twenty years. There was no history of alcohol, tobacco or recreational drug abuse. His maternal family history was remarkable for a grandmother diagnosed with AD at an unknown age and an aunt with obsessive-compulsive disorder. His paternal side was significant for late life AD in his grandmother, an aunt diagnosed with late life schizophrenia in her mid-40's and later AD in her 60's, an uncle and cousin diagnosed with bipolar affective disorder, and another cousin with unspecified psychiatric illness (Supplemental Figure 1). The patient's father had a progressive cognitive, behavioral, and motor disorder that progressed to death at age 73. Autopsy was performed, and follow-up immunohistochemistry was performed on archival tissue blocks from frontal cortex and medial temporal lobe. These studies revealed an unclassifiable subtype of FTLT-DTP with TDP-43-immunoreactive dots, threads, and neuronal cytoplasmic inclusions (NCIs) that were sparse in frontal and entorhinal cortex and moderate in hippocampal CA1/subiculum, accompanied by hippocampal sclerosis (further described in Supplemental Data).

On examination, the patient was alert, oriented and well-groomed but had a flat affect. He was overly familiar, perseverative, angry, and critical of others throughout the interview. He frequently interrupted the examiner and raised his voice inappropriately. He showed poor insight into his symptoms, making excuses for his deficits. Cranial nerve examination revealed mild flattening of the right nasolabial fold with normal facial strength. Motor examination was normal for bulk and power, but there was mild axial rigidity. Stride length was normal, but arm swing was diminished on the right greater than left. He had mild retropulsive instability.

On neuropsychological evaluation [14] (Table 1), the patient scored 30/30 on the Mini-Mental State examination (MMSE) [16] and performed normally on verbal episodic memory testing, speech and language, visuoconstruction, visuo-perceptual function, and calculations. He performed below expectations on visual memory free recall, but his recognition was normal. On measures of executive function, he scored in the impaired range relative to matched controls on phonemic fluency, category fluency, and cognitive control (Stroop) tasks, and his working memory (digits backward) was below expectations, though he was able to complete a set-shifting and sequencing task rapidly and accurately. He endorsed 20 items on the Geriatric Depression Scale (GDS)[17], consistent with clinically significant depression. His neuropsychiatric inventory (NPI)[18] total score was 61, and was notable for elevated agitation, anxiety, depression, disinhibition, irritability and aberrant eating behavior. The patient scored 11 on the Functional Activities Questionnaire (FAQ),[19] suggesting mild impairment in ADLs, and his global CDR[20] score was 1, with sum of boxes equal to 5 (Table 2), suggestive of very mild functional impairment.

Social-emotional testing revealed pathologically low levels of empathy, characterized by an inability to think about others' emotions [Interpersonal Reactivity Index-Perspective Taking (IRI-PT): 12/35] and irritation from others' emotional expressions [IRI-Personal Distress (PD): 23/35], though his level of empathic concern was not in the impaired range [IRI-Empathic Concern (EC): 24/35].[21] He was pathologically insensitive to subtle social cues [Revised Self-Monitoring Scale (RSMS): 37/84],[22] but was sensitive to perceived criticism and afraid of making errors [Behavioral Inhibition Scale (BIS): 27/28].[23] He was impaired at naming emotions [The Awareness of Social Inference Test-Emotion Evaluation Test (TASIT-EET): 9/14],[24] though he could detect sarcasm [TASIT-Social Inference Minimal (SIM): Simple Sarcasm (SSR) 19/20, Paradoxical Sarcasm (PSR) 17/20]. His emotional theory of mind was impaired (Castelli Triangles Intentionality (CIT): 11/20).[25] Personality ratings through the Interpersonal Adjectives Scale indicated impaired warmth (T=32) and pathologically high levels of arrogance (T=81) and dominance (T=78) were a part of the patient's normal personality *before* becoming ill that had further intensified since symptom onset.[26]

A structural brain MRI revealed no abnormalities or gross atrophy as rated visually by UCSF clinicians (Figure 2a). At age 51, the patient also underwent FDG PET that was within normal limits based on qualitative and quantitative assessments. A PET scan with PIB did not reveal evidence of cortical amyloid. CSF analysis revealed normal tau and A-beta levels, not suggestive of AD. An EEG was unremarkable.

The patient was evaluated annually for the next five years. During this period, he developed new compulsions (e.g., repetitively watching grotesque horror films) and had increasing loss of empathy towards family and friends. On social-emotional testing, he became less able to recognize socially inappropriate behaviors, could no longer detect sarcasm or deception in others, and his moral reasoning became highly utilitarian and emotionally detached. In other domains, the patient remained stable. His neurological exam, neuropsychological scores (Table 1), and MRI (Figure 2a) remained unchanged. Some memory scores improved (Table 1), but this was likely the result of a practice effect. Notably, the patient's CDR and FAQ scores improved slightly with longitudinal follow-up (Table 2). Moreover, his clinicians noted in subsequent visits, the patient displayed greater insight into his disease, learning to compensate for his cognitive and behavioral changes. For example, he adapted to his memory deficits by becoming more organized and regimented, and developed a list of social rules to guide his conduct when interacting with others.

Based on the patient's initially progressive symptoms, he met FTDC criteria [11] at initial evaluation. Due to his stable neurological, neuropsychological and imaging tests at later



evaluations, he met the present criteria for bvFTD-SP. Single case VBM compared to normal controls revealed bilateral thalamic and mild posterior insular atrophy (Figure 2a).

## Patient 2

Patient 2 was a 48-year-old right-handed woman who reported a five-year history of behavioral and personality changes. Her symptoms began when she became irritable, self-centered and emotionally detached. For example, she refused to visit her son in the hospital after he had major surgery, and she was resentful and angry during her son's recovery period. She displayed inappropriate behaviors such as sneaking up on a co-worker from behind, pretending to have a gun. Previously flexible in her daily routine, the patient began to ritualistically follow a rigid daily schedule with set waking, sleeping and eating times, and she would get angry if this routine was broken. At age 46, she sought medical evaluation due to her increasing confusion and distractibility. She was diagnosed with bvFTD by an outside neurologist despite a reportedly normal MRI. Over the next two years she became depressed, her speech became more tangential, and she gradually lost her ability to use simple household appliances.

Patient 2's medical history was significant only for hypertension. She had a history of dyslexia. She completed tenth grade and worked as an exterminator until her late twenties before managing a construction company until becoming ill. The patient endorsed alcohol and drug abuse in her twenties, including cocaine and marijuana. At the time of her evaluation, the patient had stopped drinking alcohol but continued to smoke marijuana. Both of her parents had a history of alcohol abuse, and late life behavioral disorders were reported in her father and an older brother.

On examination, the patient was pleasant and cooperative but occasionally became agitated when discussing her symptoms. Her speech was fluent with rare phonemic paraphasic errors. Naming and comprehension were normal. Neurological examination was otherwise unremarkable. On neuropsychological testing (Table 1), the patient scored 23/30 on the MMSE (losing points for orientation, recall, repetition, visuospatial function, and following a command). Verbal episodic learning and delayed free recall were poor, but recognition was normal, and visuospatial episodic learning and recall were normal. Language and visuospatial functions were normal. She was impaired in calculations due to careless errors rather than frank acalculia. She was impaired on lexical fluency, was slow on a set-shifting task, and her abstraction and working memory were below expectations. Her design fluency and category fluency were normal. She endorsed 9/30 items on the GDS. NPI total score was 35 and was notable for delusions, agitation, anxiety, euphoria, apathy, disinhibition and eating changes. The patient scored 20 on the FAQ and her global CDR score was 1, with sum of boxes equaling 7.5 (Table 2).

Social-emotional testing showed impaired ability to think about others' emotions (IRI-PT: 14/35), extreme irritation by others' emotions (IRI-PD: 33/35), but low-normal empathic concern (IRI-EC: 23/35). She was pathologically insensitive to subtle social cues (RSMS: 30/84), but showed high-average sensitivity to criticism (BIS: 20/28). She was impaired at naming emotions (TASIT-EET: 9/14) and recognizing sarcasm (TASIT-SIM: SSR 13/20; PSR: 14/20). Compared to informant ratings of her premorbid personality (NEO-PI-3), [27] she had significantly increased Neuroticism, including anxiety (+8), depression (+10), angry hostility (+7), and self-consciousness (+10), along with decreased Extraversion and more mild decreases in Agreeableness.

The patient's brain MRI at initial evaluation revealed no gross atrophy or abnormalities by visual inspection, and two years later her scan remained unchanged (Figure 2b). Single case

VBM compared to normal controls revealed a non-specific pattern of parieto-occipital atrophy with more subtle frontal and insular changes (Figure 2b).

During the two intervening years her husband noted slightly increased apathy, but otherwise her symptoms remained stable and her neurological and neuropsychological assessments remained unchanged (Table 1). In fact, her CDR-SB score decreased (Table 2). Compared to her initial visit, the patient demonstrated greater insight into her illness, showing concern over her symptoms and prognosis, and personality testing showed decreased neuroticism. She continued to be impaired on tests of emotion naming and empathy, but her performance did not worsen. The patient's progressive behavioral and personality changes fulfilled FTDC criteria at initial evaluation. Due to stable symptoms without characteristic bvFTD brain atrophy, she was diagnosed with a slowly progressive variant.

## DISCUSSION

We report two patients diagnosed with a slowly progressive bvFTD (bvFTD-SP), or “FTD phenocopy,” who were subsequently found to carry the *C9ORF72* expansion. These individuals initially fulfilled international criteria for possible bvFTD, and were later diagnosed with bvFTD-SP due to their stable clinical course over seven (Patient 1) and two (Patient 2) years of follow-up, and imaging uncharacteristic of bvFTD. These findings demonstrate that a subset of patients with bvFTD-SP may have neurodegeneration due to underlying FTLT-DTP pathology. The presence of slowly progressive forms of C9+ bvFTD may reflect a difference in the type of underlying *C9ORF72* mutation (e.g., number of hexanucleotide repeats), modifying effects of genetic/epigenetic factors, or incomplete penetrance of the allele. Since the overall number of bvFTD-SP patients was small in our *C9ORF72* expansion-screened FTD population, it is not possible to reliably estimate the prevalence of C9+ bvFTD-SP; however, both patients reported here had a family history of dementia. Our findings therefore suggest that *C9ORF72* mutations should be entertained in patients with bvFTD-SP, particularly if there is a known family history of dementia.

To date, only a handful of bvFTD-SP patients have come to autopsy, and none were found to harbor FTLT pathology.[1] Structural imaging changes are not mandatory for a definite bvFTD diagnosis if a known genetic cause of FTD is present,[11] and the lack of such atrophy over longitudinal assessment makes the diagnosis of neurodegenerative disease uncertain.[6] As assessed visually by our clinicians, neither patient had a typical bvFTD atrophy pattern on initial visit or on longitudinal structural MRIs (Figure 2). Accordingly, these patients would have received a possible bvFTD diagnosis using FTDC international research criteria. Patient 1's normal FDG-PET is consistent with reports of normal FDG-PET in other bvFTD-SP patients.[3] Retrospectively, VBM revealed thalamic and posterior insular atrophy in Patient 1 and a nonspecific pattern of parieto-occipital and frontal and insular atrophy in Patient 2; neither of these patterns were deemed clinically significant by the treating physicians at the time of evaluation. While the full spectrum of imaging abnormalities associated with *C9FTD/ALS* has not yet been described, the pattern of atrophy observed in Patient 2 is similar to what we have described in the VSM-20 *C9FTD/ALS* family in whom the *C9ORF72* mutation was first identified.[7, 9] These findings raise the possibility that *C9FTD/ALS*-associated brain atrophy patterns could be used to identify slowly progressive *C9ORF72* mutation carriers with a bvFTD-SP phenotype.

Prominent frontal and insular atrophy is a consistent neuroanatomical feature of bvFTD. VBM analysis of Patient 1 showed no frontal atrophy, while insular atrophy was more posterior than typically found in patients with bvFTD (Figure 2a–c). While VBM in Patient 2 revealed frontal and insular atrophy, compared to other patients with bvFTD, these changes were unrecognized on visual inspection of structural imaging and were only

detected using single-subject VBM (Figure 2b). The lack of significant atrophy in characteristic bvFTD regions may explain why both patients maintained a level of insight into their illness. Anosognosia, or the lack of awareness into one's deficits, has been linked to atrophy in the frontal lobes,[28] and the lack of significant frontal atrophy in both patients may be why both patients better adapted to their deficits. Patient 1 eventually developed strategies to cope with his symptoms, and during follow-up evaluation, Patient 2 was actively engaged with questions about her disease and interest in clinical trials. Interestingly, Patient 1 generated a list of rules to guide his conduct during social situations. While this demonstrates a depth of insight into his illness, it is also reflective of the obsessive features frequently observed in bvFTD.

Similarly, although both patients showed many deficits on socioemotional testing, such as impaired emotion naming and difficulty imagining others' thoughts and emotions, they both retained a rudimentary concern for others and themselves that is atypical of bvFTD. Greater insight and some preservation of basic emotional responding could also be the reason that both individuals developed significant depression and anxiety, consistent with reports that individuals with bvFTD-SP may have higher rates of depression compared to typical bvFTD.[2] In fact, both patients reported more items on the GDS across longitudinal evaluations, and at the time of final evaluation had higher GDS scores than other bvFTD patients (Table 1).

Despite the lack of frontal atrophy, both patients displayed executive dysfunction on neuropsychological testing. While impaired on some neuropsychological tests, both patients outperformed individuals with typical bvFTD on many of the executive tasks (Table 1), consistent with reports that patients with bvFTD-SP can be differentiated from progressive bvFTD through such tests.[1] Moreover, given that both patients were at least seven years into their disease course at final evaluation and that time from first symptom to death averages six years,[29] these patients' impairments were remarkably mild for typical bvFTD. Importantly, mild executive dysfunction is not unusual in bvFTD, and 25% of patients with typical bvFTD initially perform within normal limits on standard neuropsychological testing.[30] Thus, normal performance on cognitive testing may be supportive of a diagnosis of bvFTD-SP, but it does not rule out typical bvFTD.

Taken together, our findings suggest that clinicians should strongly consider FTLN pathology in patients who meet criteria for bvFTD-SP, particularly when there is significant psychiatric comorbidity, as was the case in Patient 1. Up to 51% of patients with bvFTD receive erroneous diagnoses at initial evaluation due to symptoms that resemble psychiatric diseases.[31] Patient 1 was initially diagnosed with PTSD and bipolar affective disorder due to his early symptoms. The presence of prominent psychiatric illness in the families of both patients may further indicate underlying neurodegenerative disease,[31] yet the absence of such history in bvFTD-SP would not rule out C9+ bvFTD, since sporadic patients of *C9ORF72* bvFTD are not uncommon.[7] Notably, the limited materials available from the father's autopsy suggest an unclassifiable form of FTLN-TDP as well as ubiquitin-positive, TDP-43-negative NCIs in the medial temporal lobe; these features strongly suggest a *C9ORF72*-linked illness.[32]

One of the most enigmatic and diagnostically challenging features of patients with bvFTD-SP is their altered personality and behavior in light of unremarkable imaging assessments.[6] A possible explanation for the behavioral symptoms we observed in our subjects is that these features derive from neuronal and synaptic dysfunction that is not well captured on standard neuroimaging assessments. It is possible that newer imaging techniques such as intrinsic connectivity fMRI may be more sensitive to such *C9ORF72*-related brain



dysfunction.[33, 34] It will also be of interest to continue to monitor these patients for the emergence of more typical bvFTD imaging abnormalities.

There are limitations to this report. In our cohort of 61 patients with bvFTD without comorbid motor neuron disease who were screened for the *C9ORF72* variant, only four patients had been diagnosed as bvFTD-SP, which is lower than the frequency of bvFTD-SP reported by others (26 of 71 bvFTD in one series).[2] This difference may be due to the limited longitudinal data available within our bvFTD cohort (31 out of 61 patients were followed for 2 years). However, we can accurately report the frequency of bvFTD-SP due to *C9ORF72* expansion to be 15% in our cohort of 13 C9+ carriers. None of the other 11 carriers with bvFTD had bvFTD-SP; 7 had progressive changes on longitudinal evaluation and all had significant atrophy at first evaluation. Nevertheless, larger studies are needed to verify this estimate as our cohort of *C9ORF72* carriers is small.

Here we identify a novel link between bvFTD-SP and a known FTD-causing mutation. Our findings suggest that an underlying neurodegenerative etiology should not be ruled out in patients who meet criteria for possible bvFTD but have atypical features consistent with a bvFTD “phenocopy.” We also speculate that screening larger series of bvFTD-SP will likely identify other patients with *C9ORF72* mutations.

## Supplementary Material

Refer to Web version on PubMed Central for supplementary material.

## Acknowledgments

We would like to thank Dr. William Jagust for PET imaging data. We thank our patients and their families for participating in neurodegenerative disease research.

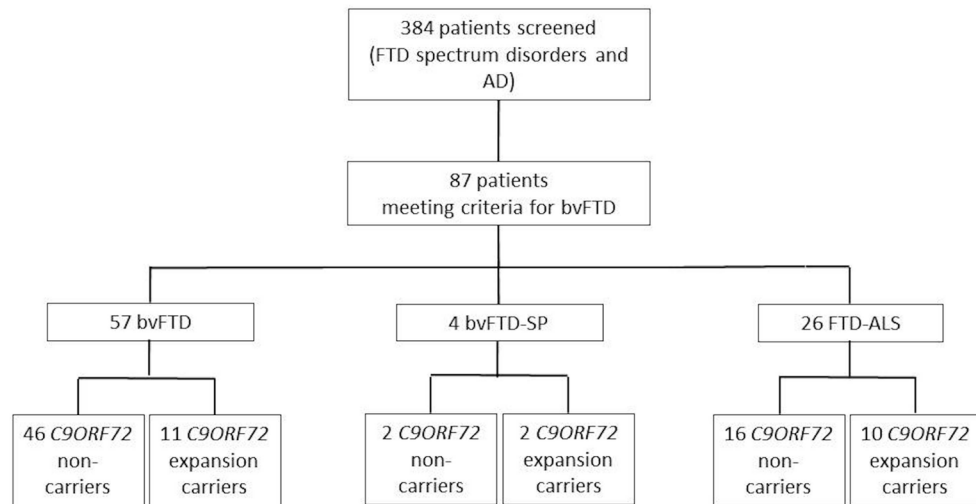
**Funding:** This work was supported by National Institute of Health [grants R01AG031278, R01 AG038791, R01NS065782, R01 AG026251, R01 AG026938, R01 AG029577, K23 AG031861, K23 AG021606, P01 AG19724, M01-RR0079, P50 AG023501 and P50 AG1657303]; the Hellman Foundation, the Tau Research Consortium, the ALS Association (ALSA), the State of California, Alzheimer’s Disease Research Center of California (ARCC) [grant 03-7527] and the Larry Hillblom Foundation grants 2002/2J and 2007/2I.

## References

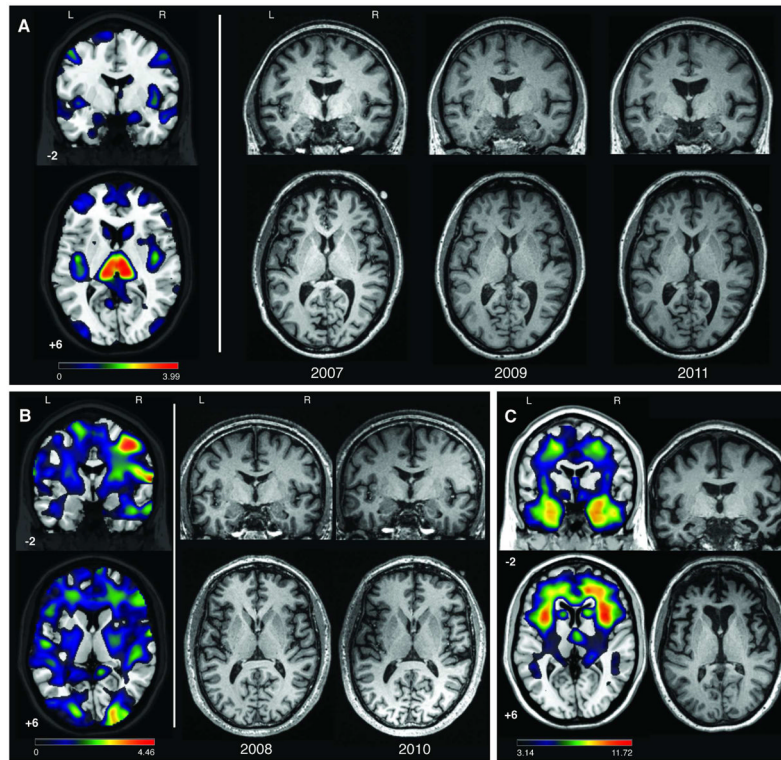
1. Kipps C, Hodges J, Hornberger M. Nonprogressive behavioral frontotemporal dementia: recent developments and clinical implications of the ‘bvFTD phenocopy syndrome’. *Curr Opin Neurol*. 2010; 23:628–632. [PubMed: 20962637]
2. Hornberger M, Shelley BP, Kipps C, et al. Can Progressive and non-progressive behavioral variant frontotemporal dementia be distinguished at presentation. *J Neurol Neurosurg Psychiatry*. 2009; 80:591–593. [PubMed: 19228667]
3. Kipps C, Hodges J, Fryer TD, et al. Combined Magnetic resonance imaging and positron emission tomography brain imaging in behavioural variant frontotemporal degeneration: refining the clinical phenotype. *Brain*. 2009; 13:2566–2578. [PubMed: 19416953]
4. Kipps C, Nestor PJ, Fryer TD, et al. Behavioral variant frontotemporal dementia: not all it seems? *Neurocase*. 2007; 13:237–247. [PubMed: 17852756]
5. Davies RR, Kipps C, Mitchell J, et al. Progression in frontotemporal dementia: identifying a benign behavioral variant by magnetic resonance imaging. *Arch Neurol*. 2006; 63:1627–1631. [PubMed: 17101833]
6. Kipps C, Davies RR, Mitchell J, et al. Clinical Significance of lobar atrophy in frontotemporal dementia: application of an MRI visual rating scale. *Dement Geriatr Cogn Disord*. 2007; 23:334–342. [PubMed: 17374952]

7. DeJesus-Hernandez M, Mackenzie I, Boeve BF, et al. Expanded GGGGCC Hexanucleotide Repeat in Noncoding Region of C9ORF72 Causes Chromosome 9p-Linked FTD and ALS. *Neuron*. 2011; 72:245–256. [PubMed: 21944778]
8. Renton A, Majounie E, Waite A, et al. A Hexanucleotide Repeat Expansion in C9ORF72 Is the Cause of Chromosome 9p21-Linked ALS-FTD. *Neuron*. 2011; 72:257–268. [PubMed: 21944779]
9. Boxer A, Mackenzie I, Boeve BF, et al. Clinical, neuroimaging and neuropathological features of a new chromosome 9p-linked FTD-ALS family. *J Neurol Neurosurg Psychiatry*. 2011; 82:193–203.
10. Murray M, DeJesus-Hernandez M, Rutherford NJ, et al. Clinical and neuropathologic heterogeneity of c9FTD/ALS associated with hexanucleotide repeat expansion in C9ORF72. *Acta Neuropathol*. 2011; 122:673–690. [PubMed: 22083254]
11. Rascovsky K, Hodges J, Knopman D, et al. Sensitivity of revised diagnostic criteria for behavioral variant frontotemporal dementia. *Brain*. 2011; 134:2456–2477. [PubMed: 21810890]
12. Wilson S, Brambati S, Henry R, et al. The neural basis of surface dyslexia in semantic dementia. *Brain*. 2009; 132:71–86. [PubMed: 19022856]
13. Rabinovici G, Rosen H, Alkalay A, et al. Amyloid and FDG PET in the Differential Diagnosis of Alzheimer's Disease and Frontotemporal Lobar Degeneration. *Neurology*. 2011; 77:2034–2042. [PubMed: 22131541]
14. Kramer J, Jurik J, Sha S, et al. Distinctive neuropsychological patterns in frontotemporal dementia, semantic dementia, and Alzheimer disease. *Cogn Behav Neurol*. 2003; 16:211–218. [PubMed: 14665820]
15. Lee, S.; Seeley, W.; Poorzand, P., et al. [accessed 16 Jan 2012] Clinical Characterization of bvFTD due to FUS neuropathology. *Neurocase*. 2011. <http://dx.doi.org/10.1080/13554794.2011.604637>
16. Folstein MF, Folstein SE, McHugh PR. "Mini-mental state". A practical method for grading the cognitive state of patients for the clinician. *J Psychiatr Res*. 1975; 12:189–198. [PubMed: 1202204]
17. Yesavage JA, Brink TL, Rolse TL, et al. Development and validity of a Geriatric Depression Scale: a preliminary report. *J Psychiatr Res*. 1983; 17:37–49. [PubMed: 7183759]
18. Cummings JL. The Neuropsychiatric Inventory: assessing psychopathology in dementia patients. *Neurology*. 1997; 48:S10–16. [PubMed: 9153155]
19. Pfeffer R, Kurosaki T, Harrah CJ, et al. Measurement of functional activities in older adults in the community. *J Gerontol*. 1982; 37:323–329. [PubMed: 7069156]
20. Morris JC. The Clinical Dementia Rating (CDR): current version and scoring rules. *Neurology*. 1993; 43:2412–2414. [PubMed: 8232972]
21. Davis M. Measuring individual differences in empathy: Evidence for a multidimensional approach. *J Pers Soc Psychol*. 1983:44.
22. Lennox R, Wolfe R. Revision of the self-monitoring scale. *J Pers Soc Psychol*. 1984; 46:1349–1364. [PubMed: 6737217]
23. Carver CS, White T. Behavioral inhibition, behavioral activation and affective responses to impending reward and punishment: the BIS/BAS scales. *J Pers Soc Psychol*. 1994; 67:319–333.
24. McDonald S, Bornhofen C, Shum D, et al. Reliability and validity of The Awareness of Social Inference Test (TASIT): a clinical test of social perception. *Disabil Rehabil*. 2006; 28:1529–1542. [PubMed: 17178616]
25. Castelli F, Happe F, Frith U, et al. Movement and mind: a functional imaging study of perception and interpretation of complex intentional movement patterns. *Neuroimage*. 2000; 12:314–325. [PubMed: 10944414]
26. Wiggins, J. *Interpersonal Adjectives Scale: Professional Manual*. Odessa, FL: Psychological Assessment Resources, Inc; 1995.
27. Costa, PTJ.; McCrae, RR. *The NEO-PI-R Professional Manual*. Odessa, FL: Psychological Assessment Resources, Inc; 1992.
28. Rosen H. Anosognosia in neurodegenerative disease. *Neurocase*. 2011; 17:231–241. [PubMed: 21667396]
29. Hodges J, Davies RR, Xuereb J, et al. Survival on frontotemporal dementia. *Neurology*. 2003; 61(3):349–354. [PubMed: 12913196]

30. Hornberger M, Piguet O, Kipps C, et al. Executive Function in progressive and nonprogressive behavioral variant frontotemporal dementia. *Neurology*. 2008; 71:1481–1488. [PubMed: 18981369]
31. Woolley J, Khan B, Murthy N, et al. The Diagnostic Challenge of Psychiatric Symptoms in Neurodegenerative Disease: Rates of and Risk Factors for Prior Psychiatric Diagnosis in Patients with Early Neurodegenerative Disease. *J Clin Psych*. 72:126–133.
32. Al-Sarraj S, King A, Troakes C, et al. p62 positive, TDP-43 negative, neuronal cytoplasmic and intranuclear inclusions in the cerebellum and hippocampus define the pathology of C9orf72-linked FTLN and MND/ALS. *Acta Neuropathol*. 2011; 122:691–702. [PubMed: 22101323]
33. Whitwell J, Josephs K, Avula R, et al. Altered functional connectivity in asymptomatic MAPT subjects: a comparison to bvFTD. *Neurology*. 2011; 77:866–874. [PubMed: 21849646]
34. Zhou J, Greicius MD, Gennatas ED, et al. Divergent network connectivity changes in behavioral variant frontotemporal dementia and Alzheimer's disease. *Brain*. 2010; 133:1352–1367. [PubMed: 20410145]



**Figure 1.**  
Diagnoses of patients screened for the *C9ORF72* mutation



**Figure 2.**

Patients 1 and 2 single-subject VBM and serial MRIs and typical bvFTD atrophy pattern.

(A) *Patient 1*: Single-subject VBM for Patient 1 using the second (2009) scan is shown in left panel with unthresholded T-map ( $0 < T < 3.99$ ) results overlaid on the template brain. On the right, slices from three serial structural T1 MRIs are provided for Patient 1 from 2007, 2009 and 2011. (B) *Patient 2*: Single-subject VBM results with an unthresholded T-map ( $0 < T < 4.46$ ) are shown overlaid on the template brain in the left panel, with corresponding slices from Patient 2's structural MRIs from 2008 and 2010 shown in the right panel. VBM was performed on the 2010 image. (C) *Typical bvFTD Atrophy Pattern*: VBM results comparing 20 bvFTD to 164 cognitively normal controls overlaid on the template brain are shown on the left ( $p < 0.001$ ). On the right is a single demographically matched bvFTD patient's structural MRI. MNI coordinates are provided for template images (template brain in MRIcron: ch2.nii), and for all coronal and axial slices the left side of the image represents the left side of the patient.



Table 1

Performance on Neuropsychological Measures

Test	Controls N=85	C9- bvFTDs N=44	Patient 1			Patient 2		
			Year 1 2005	Year 4 2008	Year 7 2011	Year 1 2008	Year 3 2010	
MMSE (max=30)	29.7±0.6	23.1±0.7*	30	28*	28*	23*	26*	
Geriatric Depression Scale (max=30)	3.3±3.1	7.9±1.0	20*	17*	24*	9*	12*	
LANGUAGE								
Boston Naming Test (max=15)	14.7±1.9	11.6±0.3	15	13	15	14	13	
VISOSPATIAL								
Benson Complex Figure Copy (max=17)	15.6±1.1	13.8±0.3*	16	14	15	13*	14	
VOSP Number Location	9.4±0.2	7.5±0.3	8	7*	9	9	8	
LEARNING/MEMORY								
CVLT-SF Verbal Learning Trials 1-4 (max=36)	31.3±2.4	20.4±0.9*	25*	33	35	20*	21*	
CVLT-SF 30' Recall (max=9)	8.2±0.8	5.0±0.2*	8	9	9	5*	5*	
CVLT-SF 10' Recall	7.9±1.5	4.1±0.3*	8	9	9	4*	5*	
CVLT-SF Recognition	8.8±0.4	7.6±0.2*	9	8*	9	8*	8*	
Benson Figure 10' Recall	12.5±2.5	6.6±0.6*	8*	13	15	11	16	
EXECUTIVE FUNCTIONING								
Span of Digits Backward	5.4±1.3	3.7±0.2	4	3*	3*	3*	3*	
Trailmaking Speed (# lines/minute)	31.2±11.8	18.6±2.6	28	56	25	16	16	
Lexical Fluency (# D-words/minute)	16.0±4.1	7.6±0.9*	9*	13	10	9*	9*	
Category Fluency (# animals/minute)	23.8±4.6	9.7±0.9*	15*	14*	14*	24	24	
Design Fluency (#/minute)	11.5±2.9	4.6±0.5*	NA	8	7	7	9	
Stroop Interference (# words/minute)	54.8±11.3	22.0±2.7*	30*	35*	23*	34*	32*	
Calculations (max=5)	4.8±0.6	3.2±0.1*	5	4	5	3*	4	

\* = clinically impaired relative to middle-aged healthy controls (z-score < -1.65, <5th percentile). All test data represented as raw scores. MMSE= Mini Mental Status Examination; CVLT-SF= California Verbal Learning Test - Short Form; VOSP= Visual Object and Space Perception Battery. NA= data not available. Values displayed as means ± standard deviation.

**Table 2**

Disease Severity and Functional Impairment

	Patient 1			Patient 2	
	Year 1 2005	Year 4 2008	Year 7 2011	Year 1 2008	Year 3 2010
Functional Activities Questionnaire	11	13	9	20	23
Clinical Dementia Rating Global	1	0.5	0.5	1	1
CDR sub scores	Memory	1	0.5	0	0.5
	Orientation	0	0.5	0.5	1
	Judgment	2	1	1	2
	Community Affairs	1	0.5	0.5	2
	Hobbies	1	0.5	0.5	2
	Personal Care	0	0	0	0
	Sum of Boxes	5	3	2.5	7.5