

Intestinal alkaline phosphatase in the colonic mucosa of children with inflammatory bowel disease

Kriszta Molnár, Ádám Vannay, Beáta Szebeni, Nóra Fanni Bánki, Erna Sziksz, Áron Cseh, Hajnalka Györffy, Péter László Lakatos, Mária Papp, András Arató, Gábor Veres

Kriszta Molnár, Áron Cseh, András Arató, Gábor Veres, First Department of Pediatrics, Semmelweis University, H-1083 Budapest, Hungary

Ádám Vannay, Beáta Szebeni, Erna Sziksz, Research Group for Pediatrics and Nephrology, Semmelweis University and Hungarian Academy of Sciences, H-1083 Budapest, Hungary

Nóra Fanni Bánki, SE-MTA "Lendület" Diabetes Research Group, H-1083 Budapest, Hungary

Hajnalka Györffy, Second Department of Pathology, Semmelweis University, H-1091 Budapest, Hungary

Péter László Lakatos, First Department of Medicine, Semmelweis University, H-1083 Budapest, Hungary

Mária Papp, Second Department of Medicine, University of Debrecen, H-4032 Debrecen, Hungary

Author contributions: Veres G, Vannay Á and Molnár K designed the research; Arató A and Veres G included the patients; Molnár K, Szebeni B, Bánki NF and Cseh Á performed the analyses; Sziksz E and Györffy H analyzed the histological data; Molnár K, Vannay Á and Veres G wrote the paper; Lakatos PL, Papp M and Arató A critically reviewed the paper.

Supported by Grants OTKA-76316, OTKA-K81117, and ETT-028-02 (Veres G and Vannay Á are holders of the János Bolyai Research grant); János Bolyai Research Scholarship of the Hungarian Academy of Sciences

Correspondence to: Gábor Veres, MD, PhD, First Department of Pediatrics, Semmelweis University, H-1083 Budapest, Hungary. veres.gabor@med.semmelweis-univ.hu

Telephone: +36-208-258163 Fax: +36-1-3036077

Received: November 2, 2011 Revised: April 17, 2012

Accepted: April 21, 2012

Published online: July 7, 2012

Abstract

AIM: To investigate intestinal alkaline phosphatase (iAP) in the intestinal mucosa of children with inflammatory bowel disease (IBD).

METHODS: Colonic biopsy samples were taken from 15 newly diagnosed IBD patients and from 10 healthy controls. In IBD patients, specimens were obtained

both from inflamed and non-inflamed areas. The iAP mRNA and protein expression was determined by reverse transcription-polymerase chain reaction and Western blotting analysis, respectively. Tissue localization of iAP and Toll-like receptor (TLR) 4 was investigated by immunofluorescent staining.

RESULTS: The iAP protein level in the inflamed mucosa of children with Crohn's disease (CD) and ulcerative colitis (UC) was significantly decreased when compared with controls (both $P < 0.05$). Similarly, we found a significantly decreased level of iAP protein in the inflamed mucosa in CD compared with non-inflamed mucosa in CD ($P < 0.05$). In addition, the iAP protein level in inflamed colonic mucosa in patients with UC was decreased compared with non-inflamed mucosa in patients with CD ($P < 0.05$). iAP protein levels in the non-inflamed mucosa of patients with CD were similar to controls. iAP mRNA expression in inflamed colonic mucosa of children with CD and UC was not significantly different from that in non-inflamed colonic mucosa with CD. Expression of iAP mRNA in patients with non-inflamed mucosa and in controls were similar. Co-localization of iAP with TLR4 showed intense staining with a dotted-like pattern. iAP was present in the inflamed and non-inflamed mucosa of patients with CD, UC, and in control biopsy specimens, irrespective of whether it was present in the terminal ileum or in the colon. However, the fluorescent signal of TLR4 was more pronounced in the colon compared with the terminal ileum in all groups studied.

CONCLUSION: Lower than normal iAP protein levels in inflamed mucosa of IBD patients may indicate a role for iAP in inflammatory lesions in IBD. Based on our results, administration of exogenous iAP enzyme to patients with the active form of IBD may be a therapeutic option.

© 2012 Baishideng. All rights reserved.

Key words: Intestinal alkaline phosphatase; Toll-like receptor; Colonic biopsy; Children; Inflammatory bowel disease

Peer reviewer: Dr. Limas Kupcinskis, Professor, Department of Gastroenterology, Kaunas University of Medicine, Mickeviciaus 9, LT 44307 Kaunas, Lithuania

Molnár K, Vannay Á, Szebeni B, Bánki NF, Sziksz E, Cseh Á, Gyórfy H, Lakatos PL, Papp M, Arató A, Veres G. Intestinal alkaline phosphatase in the colonic mucosa of children with inflammatory bowel disease. *World J Gastroenterol* 2012; 18(25): 3254-3259 Available from: URL: <http://www.wjgnet.com/1007-9327/full/v18/i25/3254.htm> DOI: <http://dx.doi.org/10.3748/wjg.v18.i25.3254>

INTRODUCTION

The etiology of inflammatory bowel disease (IBD), including ulcerative colitis (UC) and Crohn's disease (CD), remains unclear. It is hypothesized that, in genetically susceptible individuals, inappropriate and ongoing activation of a mucosal immune response against luminal antigens is a major cause of the inflammation^[1,2]. In active IBD, the tolerance towards the resident intestinal flora is decreased. The balance between protective and commensal luminal bacterial species is lost and, due to increased mucosal permeability and insufficient mucosal clearance, the commensal flora and pathogenic bacteria enter into the lamina propria and destructive inflammatory responses are unavoidable^[3-6]. This prompts an exaggerated immune response with the activation of the two arms of mucosal immune system, the innate and adaptive elements^[7,8].

The activation of the innate immune system heavily depends on the recognition of microbes by pattern recognition receptors such as Toll-like receptors (TLRs). The TLR family consists of 13 members, and each has different type of ligands. One of them is TLR4, which is responsible for recognition of lipopolysaccharide (LPS), a principal component of the bacterial outer membrane. Uncontrolled activation of TLR4 may lead to the loss of mucosal barrier integrity, aggravation of the inflammatory response within the gut epithelial mucosa, increased expression of TLR-ligands and tumorigenesis^[9-13]. Previously, we found increased TLR4 protein and mRNA levels in the inflamed mucosa of children with IBD and celiac disease^[14,15].

An increasing body of evidence also supports the regulatory role of intestinal alkaline phosphatase (iAP) in TLR activation. iAP is expressed on the apical surface of enterocytes and exists in membrane-bound and soluble forms^[16]. iAP plays an essential role in the inactivation of LPS through dephosphorylation of its lipid A moiety, thus generating a non-toxic monophosphoryl section. This dephosphorylated monophosphoryl lipid A is not able to form a complex with TLR4^[17,18].

There is only one human study where expression of iAP (mRNA) in adult IBD patients was analyzed, and lower than normal iAP mRNA expression was found

in epithelial specimens^[19]. It should be noted, however, that no data on the level of iAP protein in IBD mucosa is available. The aim of our study was to investigate iAP protein and mRNA levels in affected and non-affected colon mucosa of children with newly diagnosed IBD. In addition, our secondary aim was to determine the localization of iAP enzyme with TLR4.

MATERIALS AND METHODS

Patients and colonic biopsies

Ten children (7 boys, 3 girls; median age: 10.5 years, range: 1.5-15 years) with newly diagnosed CD, 5 children (3 boys, 2 girls; median age: 11 years, range: 6-17 years) with newly diagnosed UC, and 10 control children (5 boys, 5 girls; median age: 9.5 years, range: 1.5-16 years) were enrolled in the study (Table 1). IBD was diagnosed according to the Porto criteria^[20,21]. The presenting symptoms in CD were perianal fistula, hematochezia, abdominal pain, diarrhea-bloody diarrhea, or anemia. All of the patients later diagnosed with UC had hematochezia, and some had abdominal pain and weight loss. Colonic biopsy samples were taken from macroscopically inflamed and non-inflamed sites of the colonic mucosa in children with CD. As each UC children had pancolitis, only inflamed mucosa was obtained from UC patients (Table 1). The activity score was calculated by means of the Pediatric Crohn's Disease Activity Index (PCDAI) and Pediatric Ulcerative Colitis Activity Index (PUCAI)^[22,23]. Measuring disease activity in pediatric CD is based on disease history (abdominal pain, stools per day and general well-being), laboratory findings, weight, abdominal and perianal examination, extra-intestinal manifestations, and growth rate^[24]. PUCAI requires no laboratory measurements^[25]. The mean PCDAI of our patients was 33.75, and the mean PUCAI was 35. This means that both groups had moderate-to-severe disease activity. Control children were referred to the outpatient clinic with rectal bleeding, constipation or weight loss. Colonoscopy was part of their diagnostic procedure and the biopsy specimens showed normal macroscopic appearance and histology. Written informed consent was obtained from parents prior to the procedure, and the study was approved by the Semmelweis University Regional and Institutional Committee and Research Ethics.

RNA isolation and real-time polymerase chain reaction

Total RNA was isolated from the colonic biopsy samples by RNeasy Total RNA Isolation Kit (Qiagen GmbH, Hilden, Germany), according to the instructions of the manufacturer. One μ g of total RNA was reverse-transcribed and iAP mRNA expressions were determined by real-time polymerase chain reaction (PCR) on Light Cycler480 (Roche Diagnostics, Mannheim, Germany). PCRs were performed containing RealTime ready Catalog Assay primer (Roche Diagnostics), Light Cycler 480 Probes Master (Roche Diagnostics, Mannheim, Germany), and cDNA. Conditions for iAP mRNA measurements: one

Table 1 Clinical characteristics of newly diagnosed patients with Crohn's disease and ulcerative colitis

| Patient | Form of IBD | Gender | Age (yr) | Main complaints at presentation | Activity score | Duration (symptoms) (mo) |
|---------|-------------|--------|----------|---------------------------------|----------------|--------------------------|
| 1 | CD | F | 15 | Perianal fistula | 25 | 1 |
| 2 | CD | M | 4 | Hematochezia | 20 | 3 |
| 3 | CD | M | 11 | Abdominal pain, diarrhea | 45 | 2 |
| 4 | CD | F | 9 | Bloody diarrhoea | 25 | 2 |
| 5 | CD | F | 4 | Diarrhoea, anaemia | 30 | 3 |
| 6 | CD | M | 14 | Hematochezia | 50 | 6 |
| 7 | CD | F | 1.5 | Bloody diarrhoea | 35 | 1.5 |
| 8 | CD | M | 11 | Bloody diarrhoea | 20 | 2 |
| 9 | CD | M | 12 | Diarrhoea, anaemia | 35 | 3 |
| 10 | CD | M | 10 | Weight loss, diarrhea | 52.5 | 1.5 |
| 11 | UC | F | 12 | Hematochezia, abdominal pain | 20 | 4 |
| 12 | UC | M | 9 | Hematochezia, anaemia | 35 | 1 |
| 13 | UC | M | 17 | Hematochezia, abdominal pain | 25 | 7 |
| 14 | UC | F | 12 | Hematochezia, weight loss | 55 | 4 |
| 15 | UC | M | 6 | Hematochezia | 40 | 2.5 |

The activity score was calculated by means of pediatric Crohn's disease activity index and pediatric ulcerative colitis activity index. IBD: Inflammatory bowel disease; CD: Crohn's disease; UC: Ulcerative colitis; M: Male; F: Female.

cycle, 95 °C, 10 min (denaturation), followed by several cycles at 95 °C, 10 s and 30 s, 72 °C 1 s (annealing and extension). The mRNA expression of glyceraldehyde-3-phosphate dehydrogenase (GAPDH) as internal control was determined using Brilliant II Fast SYBR Green quantitative polymerase chain reaction Master Mix (Stratagene, Cedar Creek, TX, United States), PCR primers (Forward: 5'-CAC CAC CAT GGA GAA GGC TG-3'; Reverse: 5'-GTG ATG GCA TGG ACT GTG-3', Invitrogen, CA, United States) and cDNA. Conditions for GAPDH: one cycle, 95 °C, 2 min, 50 cycles at 95 °C 20 s and 60 °C, 40 s. Results were analyzed by Light-Cycler software 480 (Roche Diagnostics).

Protein isolation and Western blotting

Colonic biopsy specimens were homogenized in lysing solution, and protein concentrations were determined by DC Protein Assay (Bio-Rad Laboratories, Hercules, CA, United States); 0.5 µg protein from each sample was separated by 10% sodium dodecyl sulfate-polyacrylamide gel electrophoresis (120 V, 40 mA, 120 min) (Penguin™ Dual-Gel Water Cooler Systems, Owl, NH, United States) and transferred to nitrocellulose membrane (GE Healthcare, Little Chalfont, United Kingdom) (70 V, 220 mA, 120 min) (MiniTank™ electroblotter, Owl). Membranes were blocked in 1% non-fat dry milk solution (1 h) and

incubated with iAP specific rabbit polyclonal antibody (1:1000, 1 h) (AbCam, Cambridge, United Kingdom). Equal protein loading was confirmed by β-actin specific (C-11) goat polyclonal IgG antibody (1:100) (Santa Cruz Biotechnology Inc., Santa Cruz, CA, United States). Peroxidase-conjugated secondary anti-rabbit IgG or donkey anti-goat IgG antibodies (1:2000, 30 min) (Santa Cruz Biotechnology Inc.) were used. Immunoreactive bands were visualized using the enhanced chemiluminescence Western blotting detection protocol (GE Healthcare). Bands were analyzed with software Image J. 1.42q (National Institutes of Health, United States). The values were expressed as relative optical density.

Immunofluorescent staining

Biopsy samples were snap-frozen, embedded in Shandon cryomatrix (ThermoElectron Co., Waltham, United States), cut to 3-4 µm slides and double incubated with TLR4 specific goat polyclonal antibody and iAP specific rabbit polyclonal antibody (1:100, 1 h) (Abcam Plc). Secondary antibodies were Alexa Fluor 488 donkey anti-goat and Alexa Fluor 568 goat anti-rabbit antibodies (Invitrogen). Zeiss LSM 510 Meta confocal laser scanning microscope (Carl Zeiss, Jena, Germany) was used with 20 × Plan Apochromat (NA = 0.8) and 63 × Plan Apochromat oil immersion differential interference contrast objectives (NA = 1.4).

Statistical analysis

Data were analyzed using Statistica 7.0 software (StatSoft Inc., Tulsa, OK, United States). After testing the normality with Shapiro-Wilk's test, non-parametric Mann-Whitney *U* test was used. Data were considered statistically significant if $P \leq 0.05$, and expressed as mean ± standard deviation.

RESULTS

iAP protein levels

Western blotting analysis revealed one distinct band at 60 kDa. The iAP protein level in the inflamed mucosa of children with CD and UC was lower by 22% and 20%, respectively, compared with controls ($P < 0.05$). We found a lower iAP protein level in the inflamed mucosa in CD compared with non-inflamed mucosa in CD ($P < 0.05$). The iAP protein level in the inflamed colonic mucosa in UC patients was decreased by 24% compared with non-inflamed mucosa in CD patients ($P < 0.05$) (Figure 1). iAP protein levels in the non-inflamed mucosa of patients with CD were normal.

iAP mRNA expression

iAP mRNA expression in inflamed and non-inflamed colonic mucosa in IBD was comparable with that in controls (Figure 2).

Mucosal localization of iAP and TLR4

The distribution of iAP was restricted to the epithelial

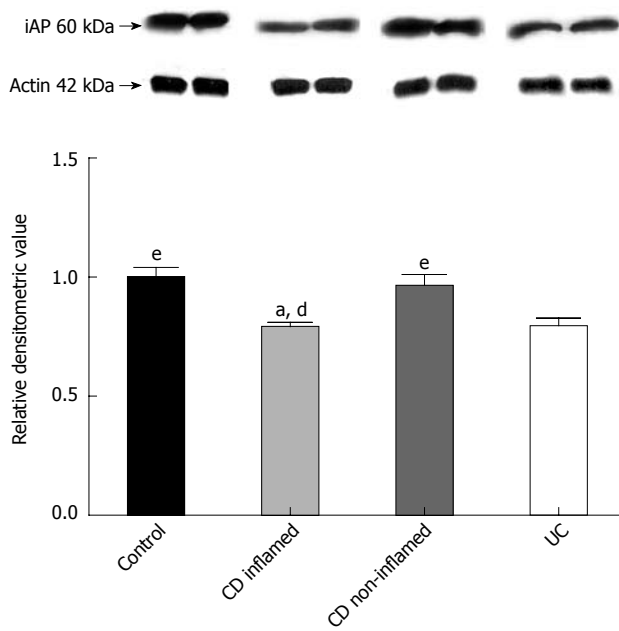


Figure 1 Protein levels of intestinal alkaline phosphatase in the colonic mucosa of children with newly diagnosed Crohn's disease, ulcerative colitis and controls. A: Western blotting analysis of the colonic biopsy specimens using intestinal alkaline phosphatase (iAP)-specific antibody reveals one distinct band at 60 kDa; B: Data for protein levels of iAP were obtained by computerized analysis of the Western blottings and expressed as median interquartile range. Analysis of significance was performed by the Mann-Whitney *U* test. ^a*P* < 0.05 vs control; ^d*P* < 0.01 vs non-inflamed CD; ^e*P* < 0.05 vs UC. CD: Crohn's disease; UC: Ulcerative colitis.

surface of the colonic and terminal ileal mucosa in each group. No fluorescent signal was detected in Lieberkühn crypt cells, in goblet cells, and in lamina propria immune cells. The co-localization of iAP with TLR4 showed intense staining with a dotted-like pattern. iAP was present in inflamed and non-inflamed mucosa of patients with CD, UC, and in control specimens irrespective of whether it was present in the terminal ileum or in the colon. However, the fluorescent TLR4 signal was more pronounced in the colon compared with the terminal ileum in all groups (Figure 3).

DISCUSSION

A dysregulated immune response, involving the innate immunity of the intestinal mucosa plays a role in the pathomechanism of IBD. The maintenance of microbiota and host is supported by the balance of microbiota and immune activation that may be disturbed in IBD^[26]. Previously we and others showed that activation of TLR4 by bacterial lipopolysaccharide contributes to disease progression^[14,27].

Recently, in connection with LPS-activated TLR4, a new enzyme, iAP has received increasing attention as a factor responsible for mucosal defense. iAP dephosphorylates and detoxifies LPS and, hence, generates an inactive, non-toxic form. This may be one of the key factors why dephosphorylated LPS is unable to bind to TLR4 and the innate immune system is not triggered. iAP may control the interaction between TLR4 in the intestinal

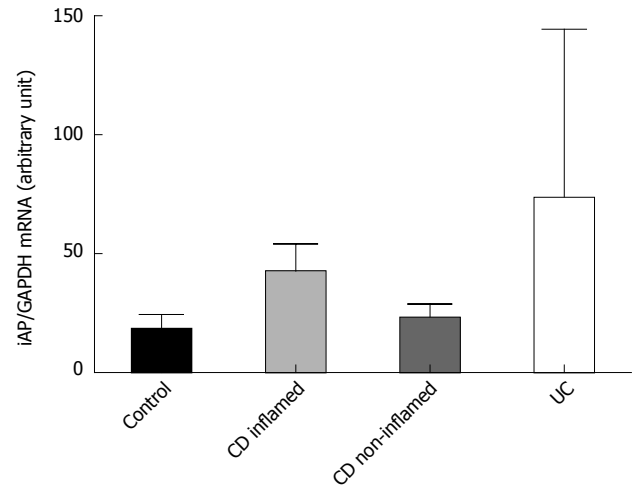


Figure 2 Intestinal alkaline phosphatase mRNA expression in the colonic mucosa of children with newly diagnosed Crohn's disease, ulcerative colitis and controls. iAP mRNA expression data were obtained by computerized analysis of PCR products. Optical density was corrected according to that of GAPDH. Data are expressed as median interquartile range. Analysis of significance was performed by Mann-Whitney *U* test. GAPDH: Glyceraldehyde-3-phosphate dehydrogenase; PCR: Polymerase chain reaction; iAP: Intestinal alkaline phosphatase; CD: Crohn's disease; UC: Ulcerative colitis.

mucosa and LPS derived from the bacterial flora^[28,29].

In the present study, we obtained data regarding the protein level, mRNA expression and localization of iAP in the intestinal mucosa of children with IBD. Lower than normal iAP levels were observed in the inflamed mucosa of CD and UC patients.

Previously it was hypothesized that the altered LPS-dephosphorylating activity may be a consequence of decreased iAP activity. We think that, in accordance with Tuin *et al*^[19], our observations also suggest that iAP has a role in the pathogenesis of IBD. Decreased iAP levels in the inflamed mucosa may be associated with decreased LPS detoxification and, consequentially, with increased TLR4 activation. On the other hand, we found no significant difference in iAP mRNA expression that may indicate a possible role of posttranscriptional regulation.

Tuin *et al*^[19] demonstrated decreased iAP mRNA expression in pretreated CD patients compared with controls. However, it should be noted that, in this study, more than half of the patients received immunosuppressive drugs such as infliximab, methotrexate, corticosteroids, and thiopurine at the time of sample collection, which may influence iAP mRNA synthesis^[30]. The unique feature of our study is the investigation of children without prior immunomodulatory therapy, hence, our results can be considered as characteristic for IBD.

Previously, we have demonstrated increased TLR4 mRNA expression and protein levels in the inflamed colonic mucosa of children with IBD^[14]. Therefore, the finding that iAP and TLR4 are co-localized, is particularly important from two aspects. First, it supports a linked role of iAP in the maintenance of mucosal integrity both in healthy and in diseased subjects. Second, the lower than normal iAP in the presence of a higher than

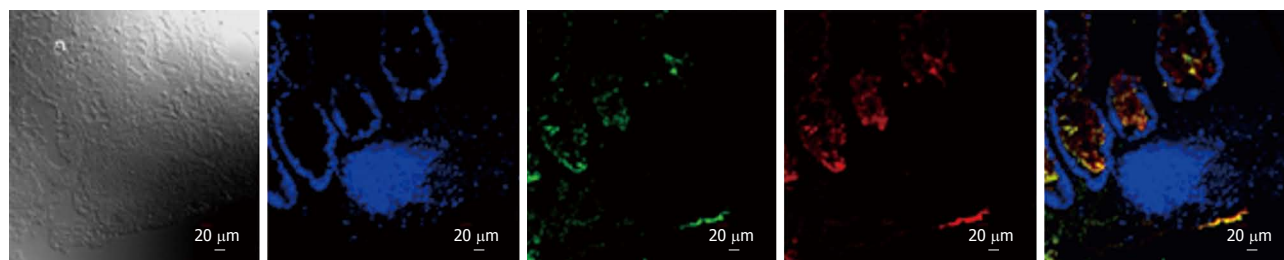


Figure 3 Localization of intestinal alkaline phosphatase and Toll-like receptor-4 in colon of Crohn's disease. Immunofluorescent staining for intestinal alkaline phosphatase (iAP) (red) and Toll-like receptor-4 (TLR4) (green) staining was performed in inflamed colon of patient with Crohn's disease. Yellow color (merge) indicates co-localization of iAP and TLR4. For the observation of non-labeled tissues, differential interference contrast was used. Nuclei are stained with blue.

normal TLR4 expression might indicate an imbalance in iAP/TLR4 that would result in an increased susceptibility of the mucosa to LPS. Indeed, this mechanism is already demonstrated in animal models of induced colitis. Our results are the first to indicate the presence of this phenomenon in man.

The current management of IBD consists of conventional therapy, but severe therapy-resistant cases require more powerful therapies, such as biological treatment^[31]. Therapeutic manipulation to restore the balance of microflora may have a strong impact on mucosal healing of IBD^[32]. In animal models of dextrane sodium sulfate (DSS)-induced colitis, exogenously administered iAP improved the signs of colitis both macroscopically and microscopically^[33]. Microscopic injury scores of DSS-induced colitis in iAP-knockout mice were much higher than in the wild-type group, which may reveal the mucosal defense role of iAP^[34]. In a human study performed in adult subjects a 7-d course of iAP products decreased the activity index of therapy-resistant UC patients^[35]. Oral administration of iAP may have a beneficial effect in the case of severe intestinal epithelial damage^[36]. Our results obtained in a pediatric population might indicate a similar approach may be of benefit in children with IBD.

In summary, to the best of our knowledge, this is the first demonstration of a decrement in the iAP enzyme in the mucosa of patients with IBD. A decreased level of iAP with reduced LPS-detoxifying capacity could be responsible for increased bacterial passage across the intestinal mucosa of patients with IBD, and this may play an important role in pathogenesis. In addition, co-localization of iAP and TLR4 was demonstrated in the epithelial compartment. Based on our results, administration of exogenous iAP enzyme to patients with active form of IBD may be a supplemental therapeutic option.

ACKNOWLEDGMENTS

We are grateful for the excellent technical assistance of Mária Bernáth.

COMMENTS

Background

The level of intestinal alkaline phosphatase (iAP) protein in inflammatory bowel disease (IBD) mucosa is very important for the study of IBD. The authors have

demonstrated firstly the presence of iAP enzyme in the colonic mucosa of patients with IBD. The decreased level of iAP enzyme with reduced lipopolysaccharide-detoxifying capacity could be responsible for the increased bacterial passage across the intestinal mucosa in the inflamed mucosa of patients with IBD and this may play a role in the pathogenesis.

Research frontiers

To the best of our knowledge, this is the first demonstration of a decrement in iAP enzyme in the mucosa of patients with IBD.

Innovations and breakthroughs

A decreased level of iAP with reduced lipopolysaccharide-detoxifying capacity could be responsible for increased bacterial passage across the intestinal mucosa of patients with IBD, and this may play an important role in the pathogenesis of IBD. In addition, co-localization of iAP and Toll-like receptor-4 was demonstrated in the epithelial compartment.

Applications

Based on their results, the authors propose administration of exogenous iAP enzyme to patients with the active form of IBD as a supplemental therapeutic option. However, this hypothesis should be tested in future clinical trials.

Terminology

The importance of the mucosal barrier damage is emphasized in IBD due to its potential role in IBD pathogenesis. iAP, a potent factor to maintain or restore mucosal barrier integrity in the gut, could participate in the mucosal healing of IBD.

Peer review

This is a well-written manuscript reporting about significance of intestinal alkaline phosphatase in the colonic mucosa for the pathogenesis of inflammatory bowel disease in children. The manuscript contains clear component of novelty to the best my knowledge, the authors have firstly demonstrated the decrement of iAP enzyme in the mucosa of patients with IBD.

REFERENCES

- 1 **Xavier RJ**, Podolsky DK. Unravelling the pathogenesis of inflammatory bowel disease. *Nature* 2007; **448**: 427-434
- 2 **Bousvaros A**, Sylvester F, Kugathasan S, Szigethy E, Fiocchi C, Colletti R, Otley A, Amre D, Ferry G, Czinn SJ, Splawski JB, Oliva-Hemker M, Hyams JS, Faubion WA, Kirschner BS, Dubinsky MC. Challenges in pediatric inflammatory bowel disease. *Inflamm Bowel Dis* 2006; **12**: 885-913
- 3 **Cseh A**, Vasarhelyi B, Molnar K, Szalay B, Svec P, Treszl A, Dezsofi A, Lakatos PL, Arato A, Tulassay T, Veres G. Immune phenotype in children with therapy-naïve remitted and relapsed Crohn's disease. *World J Gastroenterol* 2010; **16**: 6001-6009
- 4 **Roda G**, Sartini A, Zambon E, Calafiore A, Marocchi M, Caponi A, Belluzzi A, Roda E. Intestinal epithelial cells in inflammatory bowel diseases. *World J Gastroenterol* 2010; **16**: 4264-4271
- 5 **Rutella S**, Locatelli F. Intestinal dendritic cells in the pathogenesis of inflammatory bowel disease. *World J Gastroenterol* 2011; **17**: 3761-3775
- 6 **Harrison OJ**, Maloy KJ. Innate immune activation in intestinal homeostasis. *J Innate Immun* 2011; **3**: 585-593
- 7 **Siegmund B**, Zeitz M. Innate and adaptive immunity in

- inflammatory bowel disease. *World J Gastroenterol* 2011; **17**: 3178-3183
- 8 **Fava F**, Danese S. Intestinal microbiota in inflammatory bowel disease: friend of foe? *World J Gastroenterol* 2011; **17**: 557-566
 - 9 **Mayer L**, Shao L. The use of oral tolerance in the therapy of chronic inflammatory/autoimmune diseases. *J Pediatr Gastroenterol Nutr* 2004; **39** Suppl 3: S746-S747
 - 10 **Levy E**, Xanthou G, Petrakou E, Zacharioudaki V, Tsatsanis C, Fotopoulos S, Xanthou M. Distinct roles of TLR4 and CD14 in LPS-induced inflammatory responses of neonates. *Pediatr Res* 2009; **66**: 179-184
 - 11 **Himmel ME**, Hardenberg G, Piccirillo CA, Steiner TS, Levings MK. The role of T-regulatory cells and Toll-like receptors in the pathogenesis of human inflammatory bowel disease. *Immunology* 2008; **125**: 145-153
 - 12 **Rakoff-Nahoum S**, Paglino J, Eslami-Varzaneh F, Edberg S, Medzhitov R. Recognition of commensal microflora by toll-like receptors is required for intestinal homeostasis. *Cell* 2004; **118**: 229-241
 - 13 **Fukata M**, Shang L, Santaolalla R, Sotolongo J, Pastorini C, España C, Ungaro R, Harpaz N, Cooper HS, Elson G, Kosco-Vilbois M, Zaias J, Perez MT, Mayer L, Vamadevan AS, Lira SA, Abreu MT. Constitutive activation of epithelial TLR4 augments inflammatory responses to mucosal injury and drives colitis-associated tumorigenesis. *Inflamm Bowel Dis* 2011; **17**: 1464-1473
 - 14 **Szebeni B**, Veres G, Dezsöfi A, Rusai K, Vannay A, Mraz M, Majorova E, Arató A. Increased expression of Toll-like receptor (TLR) 2 and TLR4 in the colonic mucosa of children with inflammatory bowel disease. *Clin Exp Immunol* 2008; **151**: 34-41
 - 15 **Szebeni B**, Veres G, Dezsöfi A, Rusai K, Vannay A, Bokodi G, Vásárhelyi B, Korponay-Szabó IR, Tulassay T, Arató A. Increased mucosal expression of Toll-like receptor (TLR)2 and TLR4 in coeliac disease. *J Pediatr Gastroenterol Nutr* 2007; **45**: 187-193
 - 16 **Bates JM**, Akerlund J, Mittge E, Guillemin K. Intestinal alkaline phosphatase detoxifies lipopolysaccharide and prevents inflammation in zebrafish in response to the gut microbiota. *Cell Host Microbe* 2007; **2**: 371-382
 - 17 **Geddes K**, Philpott DJ. A new role for intestinal alkaline phosphatase in gut barrier maintenance. *Gastroenterology* 2008; **135**: 8-12
 - 18 **Laukoetter MG**, Nava P, Nusrat A. Role of the intestinal barrier in inflammatory bowel disease. *World J Gastroenterol* 2008; **14**: 401-407
 - 19 **Tuin A**, Poelstra K, de Jager-Krikken A, Bok L, Raaben W, Velders MP, Dijkstra G. Role of alkaline phosphatase in colitis in man and rats. *Gut* 2009; **58**: 379-387
 - 20 **IBD Working Group of the European Society for Paediatric Gastroenterology, Hepatology and Nutrition.** Inflammatory bowel disease in children and adolescents: recommendations for diagnosis—the Porto criteria. *J Pediatr Gastroenterol Nutr* 2005; **41**: 1-7
 - 21 **de Bie CI**, Buderus S, Sandhu BK, de Ridder L, Paerregaard A, Veres G, Dias JA, Escher JC. Diagnostic workup of paediatric patients with inflammatory bowel disease in Europe: results of a 5-year audit of the EUROKIDS registry. *J Pediatr Gastroenterol Nutr* 2012; **54**: 374-380
 - 22 **Turner D**, Mack D, Leleiko N, Walters TD, Ussouf K, Leach ST, Day AS, Crandall W, Silverberg MS, Markowitz J, Otley AR, Keljo D, Mamula P, Kugathasan S, Hyams J, Griffiths AM. Severe pediatric ulcerative colitis: a prospective multicenter study of outcomes and predictors of response. *Gastroenterology* 2010; **138**: 2282-2291
 - 23 **Oliva-Hemker M**, Fiocchi C. Etiopathogenesis of inflammatory bowel disease: the importance of the pediatric perspective. *Inflamm Bowel Dis* 2002; **8**: 112-128
 - 24 **Turner D**, Griffiths AM, Walters TD, Seah T, Markowitz J, Pfefferkorn M, Keljo D, Waxman J, Otley A, Leleiko NS, Mack D, Hyams J, Levine A. Mathematical weighting of the pediatric Crohn's disease activity index (PCDAI) and comparison with its other short versions. *Inflamm Bowel Dis* 2012; **18**: 55-62
 - 25 **Turner D**, Griffiths AM, Steinhart AH, Otley AR, Beaton DE. Mathematical weighting of a clinimetric index (Pediatric Ulcerative Colitis Activity Index) was superior to the judgmental approach. *J Clin Epidemiol* 2009; **62**: 738-744
 - 26 **Gersemann M**, Stange EF, Wehkamp J. From intestinal stem cells to inflammatory bowel diseases. *World J Gastroenterol* 2011; **17**: 3198-3203
 - 27 **Lakatos PL**, Lakatos L, Szalay F, Willheim-Polli C, Osterreicher C, Tulassay Z, Molnár T, Reinisch W, Papp J, Mozsik G, Ferenci P. Toll-like receptor 4 and NOD2/CARD15 mutations in Hungarian patients with Crohn's disease: phenotype-genotype correlations. *World J Gastroenterol* 2005; **11**: 1489-1495
 - 28 **Nagalingam NA**, Kao JY, Young VB. Microbial ecology of the murine gut associated with the development of dextran sodium sulfate-induced colitis. *Inflamm Bowel Dis* 2011; **17**: 917-926
 - 29 **Malo MS**, Alam SN, Mostafa G, Zeller SJ, Johnson PV, Mohammad N, Chen KT, Moss AK, Ramasamy S, Faruqui A, Hodin S, Malo PS, Ebrahimi F, Biswas B, Narisawa S, Millán JL, Warren HS, Kaplan JB, Kitts CL, Hohmann EL, Hodin RA. Intestinal alkaline phosphatase preserves the normal homeostasis of gut microbiota. *Gut* 2010; **59**: 1476-1484
 - 30 **López-Posadas R**, González R, Ballester I, Martínez-Moya P, Romero-Calvo I, Suárez MD, Zarzuelo A, Martínez-Augustín O, Sánchez de Medina F. Tissue-nonspecific alkaline phosphatase is activated in enterocytes by oxidative stress via changes in glycosylation. *Inflamm Bowel Dis* 2011; **17**: 543-556
 - 31 **Gionchetti P**, Calabrese C, Tambasco R, Brugnera R, Straforini G, Liguori G, Fornarini GS, Riso D, Campieri M, Rizzello F. Role of conventional therapies in the era of biological treatment in Crohn's disease. *World J Gastroenterol* 2011; **17**: 1797-1806
 - 32 **Andoh A**, Fujiyama Y. Therapeutic approaches targeting intestinal microflora in inflammatory bowel disease. *World J Gastroenterol* 2006; **12**: 4452-4460
 - 33 **Chen KT**, Malo MS, Beasley-Toppliffe LK, Poelstra K, Millan JL, Mostafa G, Alam SN, Ramasamy S, Warren HS, Hohmann EL, Hodin RA. A role for intestinal alkaline phosphatase in the maintenance of local gut immunity. *Dig Dis Sci* 2011; **56**: 1020-1027
 - 34 **Ramasamy S**, Nguyen DD, Eston MA, Alam SN, Moss AK, Ebrahimi F, Biswas B, Mostafa G, Chen KT, Kaliannan K, Yammine H, Narisawa S, Millán JL, Warren HS, Hohmann EL, Mizoguchi E, Reinecker HC, Bhan AK, Snapper SB, Malo MS, Hodin RA. Intestinal alkaline phosphatase has beneficial effects in mouse models of chronic colitis. *Inflamm Bowel Dis* 2011; **17**: 532-542
 - 35 **Lukas M**, Drastich P, Konecny M, Gionchetti P, Urban O, Cantoni F, Bortlik M, Duricova D, Bulitta M. Exogenous alkaline phosphatase for the treatment of patients with moderate to severe ulcerative colitis. *Inflamm Bowel Dis* 2010; **16**: 1180-1186
 - 36 **Bol-Schoenmakers M**, Fiechter D, Raaben W, Hassing I, Bleumink R, Kruijswijk D, Majoor K, Tersteeg-Zijderveld M, Brands R, Pieters R. Intestinal alkaline phosphatase contributes to the reduction of severe intestinal epithelial damage. *Eur J Pharmacol* 2010; **633**: 71-77

S- Editor Gou SX L- Editor Cant MR E- Editor Zhang DN