

Case Report

Endoscopic sealing of a rectovesical fistula with a combination of an over the scope clip and cyano-acrylate injection

Benedetto Mangiavillano¹, Andrea Pisani², Paolo Viaggi¹, Monica Arena¹, Enrico Opocher², Maria Mangano¹, Tara Santoro¹, Enzo Masci¹

¹Gastrointestinal Endoscopy, San Paolo University Hospital, University of Milan, Milan, Italy; ²Department of Surgery, San Paolo University Hospital, University of Milan, Milan, Italy

KEY WORDS OVESCO® clip; natural orifice transluminal endoscopic surgery (NOTES); cyano-acrylate injection

J Gastrointest Oncol 2010; 1: 122-124. DOI: 10.3978/j.issn.2078-6891.2010.020

Introduction

The risk of anastomotic fistula after colon resection is currently reported to range from 5% to 10%. If the fistula is symptomatic or pauci-symptomatic the best therapy is a diverting ileostomy for 2-3 months with subsequent recanalization only when a radiological contrast study shows that the fistula has disappeared (1). Recently, technological advances in gastrointestinal accessories have led to the development of a novel type of clip, the over the scope (OVESCO®) clip, currently used for organ closure during natural orifice transluminal endoscopic surgery (NOTES) (2), or in particular cases of bleeding of the gastrointestinal tract (3) or deep wall lesions (4).

Case report

A 57-year-old man with no relevant past medical history was referred to our digestive tract endoscopy unit because of a clinically silent rectovesical fistula (Fig 1), which was diagnosed by a radiological contrast examination 10 days after laparotomic resection of the sigmoid colon. The resection had been performed 10 days following the

detection of a distal sigmoid adenocarcinoma, diagnosed in our centre by colonoscopy plus biopsies. Endoscopy of the lower gastrointestinal tract confirmed the presence of a rectovesical fistula of 6 mm diameter, with an orifice at the colorectal anastomosis, located 9 cm from the anal margin. The patency of the fistula was verified by instillation of methylene blue through the bladder catheter.

The day after the diagnostic endoscopy we placed an OVESCO® clip (OVESCO® Endoscopy GmbH, Tuebingen, Germany) to close the fistula endoscopically (Fig 2). This intervention took about 15 minutes and was performed with the patient sedated, but conscious.

Three weeks after placement of the OVESCO® clip the patient started chemotherapy with FOLFOX (4 cycles) and 3 months later underwent resection of two hepatic segments (segments 1 and 8) because of residual metastases. Six days after surgery the patient complained of "liquid in the rectum" and a computed tomography scan showed a residual fistula between the bladder and the colorectal anastomosis (Fig 3). Two days later a lower gastrointestinal tract endoscopy was performed showing the absence of the OVESCO® clip and a 3-mm orifice of the residual fistula. After scrubbing the orifice with a brushing catheter, 1 cc of cyano-acrylate, which is not toxic to the gastrointestinal wall and surface, was injected endoscopically into the fistula. Four weeks later the patient started another four cycles of chemotherapy. Computed tomography scanning performed 45 days after starting chemotherapy showed total closure of the fistula (Fig 4), and the patient was totally asymptomatic.

Discussion

Surgical therapy with a diverting ileostomy for 2-3 months

No potential conflict of interest.

Corresponding to: Benedetto Mangiavillano, MD. Gastrointestinal Endoscopy, San Paolo University Hospital, University of Milan, Via A. di Rudini 8, Milan 20142, Italy. Tel: 0039-02-81844273-4759-4057; Fax: 0039-02-89125264. Email: b_mangiavillano@hotmail.com.

Submitted Oct 05, 2010. Accepted for publication Nov 29, 2010.

Available at www.thejgo.org

ISSN: 2078-6891

© 2010 Journal of Gastrointestinal Oncology. All rights reserved.

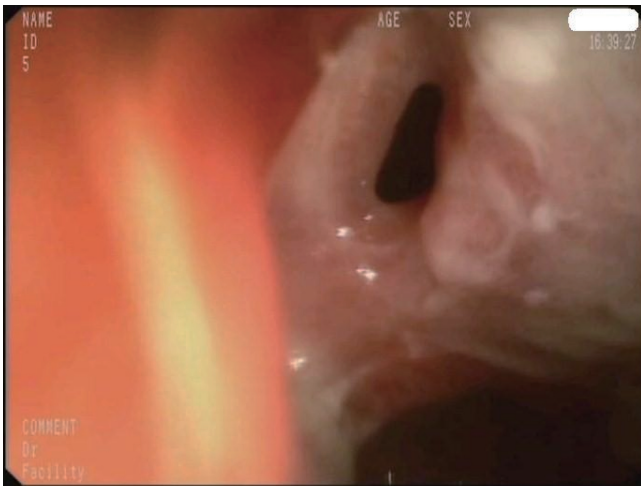


Figure 1 Endoscopic image of the rectovesical fistula

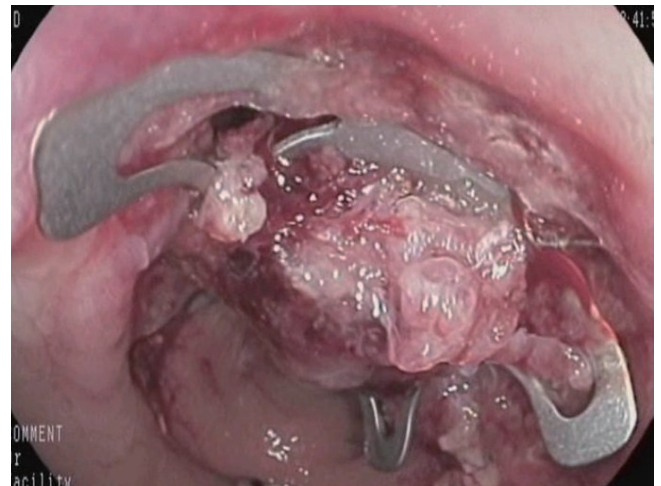


Figure 2 Rectovesical fistula closed with the OVESCO clip

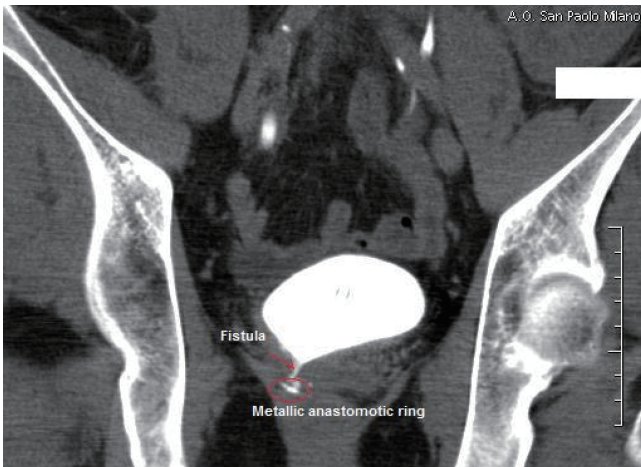

Figure 3 CT scan showing the residual rectovesical fistula

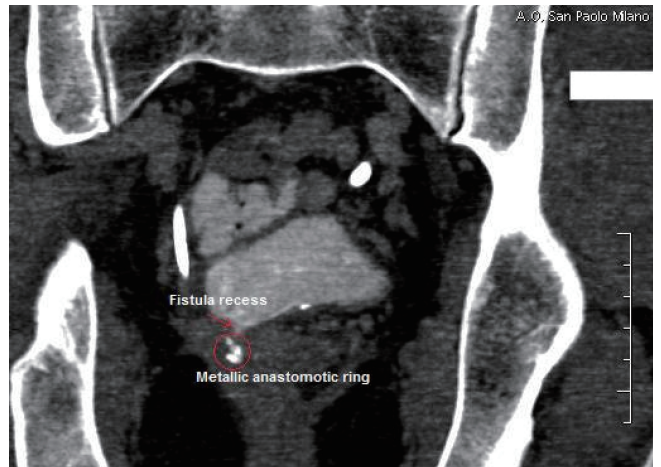


Figure 4 Computed tomography scan showing the closed fistula recess after cyano-acrylate injection

and subsequent recanalisation has been, up to now, the therapy of choice for cancer patients with an anastomotic rectovesical fistula. Although surgery allows for reliable repair, it requires general anaesthesia and can be associated with significant morbidity and mortality as well as prolonged stays in hospital; endoscopic closure could represent a less invasive alternative for fistula closure.

Technological advances in new accessories for gastrointestinal tract endoscopy have expanded treatment options in difficult situations. The OVESCO® clip, with its capability to grasp more tissue, was first used in NOTES (5,6) and found to be an excellent option for treating gastrointestinal tract haemorrhage (7), large perforations and post-operative fistulae (8). Various published studies on the endoscopic applications of the OVESCO® clip in

the gastrointestinal tract have reported promising results, particularly in porcine models (9-13). Our patient's fistula was narrowed, but not completely closed, by the placement of only an OVESCO® clip; subsequent intra-fistula injection of cyano-acrylate led to complete sealing of the fistula despite the fact that the continuous passage of urine (not eliminated by a bladder catheter) and the fibrotic tissue of the fistula did not contribute to this outcome.

A recent review of the application of standard metallic clips in the management of gastrointestinal tract perforations occurring during diagnostic and therapeutic endoscopy indicated that the use of these clips to treat small iatrogenic perforation is feasible. Moreover, they could reduce costs and time of hospitalisation and avoid patients having to undergo a surgical repair (14). However, although

skilled endoscopists can find standard clips easy to use, they are difficult to manage in cases with a fistula diameter > 1 cm, because of the problems of aligning the wound margins (15,16), and in cases in which the surrounding tissue is fibrotic, such as the case of rectovesical fistulae.

The major advantage of OVESCO® clips seems to be their ability to grasp more tissue compared to the standard clips and their strong grip on the wound margins, because of their sharpened teeth. The drawback of the clips in fistula sealing is their incomplete grasp when the tissue is fibrotic.

The new OVESCO® clip, in association with a cyanoacrylate injection in the case of incomplete clinical success, appears to be an excellent endoscopic therapeutic option in the subgroup of patients with anastomotic leak, without abdominal abscess, avoiding surgery in these patients. We, therefore, suggest trying an endoscopic approach to the treatment of rectovesical and anastomotic fistulae before referring a patient for the surgery.

References

1. Penna C. Management of anastomotic fistula following excision of rectal cancer. *J Chir (Paris)* 2003;140:149-55.
2. Schurr MO, Arezzo A, Ho CN, Anhoeck G, Buess G, Di Lorenzo N. The OTSC clip for endoscopic organ closure in NOTES: device and technique. *Minim Invasive Ther Allied Technol* 2008;17:262-6.
3. Repici A, Arezzo A, De Caro G, Morino M, Pagano N, Rando G, et al. Clinical experience with a new endoscopic over-the-scope clip system for use in the GI tract. *Dig Liv Dis* 2009;41:406-10.
4. Kirschniak A, Traub F, Kueper MA, Stüker D, Königsrainer A, Kratt T. Endoscopic treatment of gastric perforation caused by acute necrotizing pancreatitis using over-the-scope clips: a case report. *Endoscopy* 2007;39:1100-2.
5. von Renteln D, Vassiliou MC, Rothstein RI. Randomized controlled trial comparing endoscopic clips and over-the-scope clips for closure of natural orifice transluminal endoscopic surgery gastrotomies. *Endoscopy* 2009;41:1056-61.
6. Voermans RP, van Berge Henegouwen MI, Bemelman WA, Fockens P. Novel over-the-scope-clip system for gastrotomy closure in natural orifice transluminal endoscopic surgery (NOTES): an ex vivo comparison study. *Endoscopy* 2009;41:1052-5.
7. Kirschniak A, Kratt T, Stüker D, Braun A, Schurr MO, Königsrainer A. A new endoscopic over-the-scope clip system for treatment of lesions and bleeding in the GI tract: first clinical experiences. *Gastrointest Endosc* 2007;66:162-7.
8. Parodi A, Repici A, Pedroni A, Bianchi S, Conio M. Endoscopic management of GI perforations with a new over-the-scope clip device. *Gastrointest Endosc* 2010;72:881-6.
9. Schurr MO, Hartmann C, Ho CN, Fleisch C, Kirschniak A. An over-the-scope clip (OTSC) system for closure of iatrogenic colon perforations: results of an experimental survival study in pigs. *Endoscopy* 2008;40:584-8.
10. von Renteln D, Schmidt A, Vassiliou MC, Rudolph HU, Gieselmann M, Caca K. Endoscopic closure of large colonic perforations using an over-the-scope clip: a randomized controlled porcine study. *Endoscopy* 2009;41:481-6.
11. Kratt T, Küper M, Traub F, Ho CN, Schurr MO, Königsrainer A, et al. Feasibility study for secure closure of natural orifice transluminal endoscopic surgery gastrotomies by using over-the-scope clips. *Gastrointest Endosc* 2008;68:993-6.
12. Rolanda C, Lima E, Silva D, Moreira I, Pêgo JM, Macedo G, et al. In vivo assessment of gastrotomy closure with over-the-scope clips in an experimental model for varicocelelectomy (with video). *Gastrointest Endosc* 2009;70:1137-45.
13. von Renteln D, Rudolph HU, Schmidt A, Vassiliou MC, Caca K. Endoscopic closure of duodenal perforations by using an over-the-scope clip: a randomized, controlled porcine study. *Gastrointest Endosc* 2010;71:131-8.
14. Mangiavillano B, Viaggi P, Masci E. Endoscopic closure of acute iatrogenic perforations during diagnostic and therapeutic endoscopy in the gastrointestinal tract using metallic clips: a literature review. *J Dig Dis* 2010;11:8-12.
15. Katsinelos P, Beltsis A, Paroutoglou G, Galanis I, Tsolkas P, Mimidis K, et al. Endoclippping for gastric perforation after endoscopic polypectomy: an alternative treatment to avoid surgery. *Surg Laparosc Endosc Percutan Tech* 2004;14:279-81.
16. Tsunada S, Ogata S, Ohyama T, Ootani H, Oda K, Kikkawa A, et al. Endoscopic closure of perforations caused by EMR in the stomach by application of metallic clips. *Gastrointest Endosc* 2003;57:948-51.