

RAPID COMMUNICATION

Anaplastic lymphoma kinase gene rearrangement in non-small-cell lung cancer in a Brazilian population

Lisandro F. Lopes, Carlos E. Bacchi

Consultoria em Patologia, Botucatu/SP, Brazil.

Email: bacchi@conspat.com.br

Tel.: 55 14 3112-5900

INTRODUCTION

Lung cancer is the leading cause of cancer deaths worldwide (1). Non-small-cell lung carcinoma (NSCLC), which represents approximately 80% of all lung cancer cases, is frequently diagnosed at advanced stages of the disease and is associated with short survival time. Although the prognosis of this disease remains poor, significant advances in the genetics and treatment of NSCLC have been made in recent years.

In 2007, Soda et al. (2) identified the transforming *EML4-ALK* fusion gene in 6.7% of NSCLC patients. This fusion transcript, which presents potent oncogenic activity both *in vitro* and *in vivo* (2,3), is formed by the translocation of the echinoderm microtubule-associated protein-like 4 (*EML4*) gene (2p21) and anaplastic lymphoma kinase (*ALK*) gene (2p23). Subsequent studies have shown that between two and eight percent of all NSCLC cases may harbor *ALK* rearrangements, which are almost always mutually exclusive with *EGFR* and *KRAS* mutations. Moreover, these patients are frequently younger, non- or light smokers and have adenocarcinomas (2,4-23). Recently, crizotinib, an orally available small-molecule inhibitor of the *ALK* tyrosine kinase, was approved for the treatment of *ALK*-rearranged NSCLC patients, with successful results (24-29). The two most widely used methods for the diagnosis of *ALK*-rearranged NSCLC are fluorescence *in situ* hybridization (FISH) and immunohistochemistry.

Because there is no information about the prevalence and clinical characteristics of *ALK*-rearranged NSCLC in Latin America in the literature, the aim of this study was to evaluate NSCLC with *ALK* rearrangement in Brazilian patients.

MATERIALS AND METHODS

Case Selection

This study included 62 consecutive NSCLC cases received from August 2010 to September 2011 for *ALK* rearrangement testing using FISH (30) by Consultoria em Patologia, a large Anatomic Pathology and Molecular Pathology reference laboratory located in Botucatu, São Paulo State, Brazil.

Tissues from small biopsies and lung resection specimens were used. The ages and genders of the patients were registered.

Fluorescence *in situ* hybridization (FISH)

FISH was performed on formalin-fixed, paraffin-embedded tumor samples using a probe specific to the *ALK* locus (Vysis LSI *ALK* dual color, break apart rearrangement probe; Abbott Molecular, Des Plaines, IL, USA) according to the manufacturer's instructions. The FISH results were analyzed under a fluorescence microscope (Zeiss Axio Imager M1, Carl Zeiss AG, Oberkochen, Germany) with the appropriate filters (Chroma Technology GmbH, Fuerstenfeldbruck, Germany) and Metafer 4 software (MetaSystems, Altlußheim, Germany). FISH-positive cases were defined as those in which more than 15% of the cells (at least 40 neoplastic cells were counted) presented with split orange and green signals or an isolated orange signal, as previously described (31,32).

Immunohistochemistry

For comparison with FISH results, *ALK* protein expression was determined by immunohistochemistry using the mouse monoclonal antibody 5A4 (code ab17127, ABCAM, Cambridge, MA, USA), which was found to show high concordance with *ALK* gene status, as determined by molecular tests (13,14,23,33-36). Briefly, 3- μ m-thick unstained histologic sections of lung carcinoma tissue were used in all cases. The sections were deparaffinized in xylene and rehydrated in a graded series of alcohol in phosphate-buffered saline. The sections then were submitted to antigen retrieval in a microwave. Subsequently, slides were incubated overnight with the 5A4 antibody at a pre-standardized concentration (1:200), washed with phosphate-buffered saline, and incubated with Novocastra Novolink Polymer Detection System (Leica Biosystems Newcastle Ltd., Newcastle upon Tyne, UK). Diaminobenzidine was used as the chromogen, and sections were counterstained with hematoxylin and coverslipped. A case was considered positive for *ALK* if $\geq 10\%$ of the tumor cells showed intense cytoplasmic immunostaining.

RESULTS

Of the 62 NSCLC cases included in this study, two (3.2%) showed *ALK* rearrangement by FISH: one case presented an isolated orange signal along with one fusion signal in tumor cells, and the other showed split orange and green signals along with one fusion signal. These two FISH-positive cases were also positive for *ALK* by immunohistochemistry, with

Copyright © 2012 CLINICS – This is an Open Access article distributed under the terms of the Creative Commons Attribution Non-Commercial License (<http://creativecommons.org/licenses/by-nc/3.0/>) which permits unrestricted non-commercial use, distribution, and reproduction in any medium, provided the original work is properly cited.

No potential conflict of interest was reported.

strong cytoplasmic immunostaining in virtually all tumor cells. All of the other sixty FISH-negative cases were also negative for *ALK* using immunohistochemistry.

Both of the patients with FISH- and *ALK* immunohistochemistry-positive NSCLC were men (36 years old and 45 years old; mean: 40 years). One of them had no history of tobacco smoking, and the other was a light smoker who had stopped smoking some months prior to the diagnosis. The group of patients (n=60) presenting *ALK*-negative tumors by FISH varied in age from 32 to 87 years (mean: 58 years; median: 59 years), and most of these patients were male (33 patients).

According to the new international multidisciplinary classification of lung adenocarcinomas proposed by the International Association for the Study of Lung Cancer, the American Thoracic Society and the European Respiratory Society (37), tumors from the two patients with *ALK*-positive FISH were classified as invasive adenocarcinoma, acinar predominant. One tumor had papillary areas, and the other was rich in mucinous areas. The 36-year-old patient with invasive adenocarcinoma, acinar predominant with papillary areas, was also tested for *EGFR* and *KRAS* mutations; the tumor was negative for both mutations. Figure 1 presents the morphologic characteristics of the two *ALK*-positive cases, including FISH and immunohistochemical findings.

DISCUSSION

Clinical characteristics associated with *ALK* rearrangement in NSCLC include adenocarcinoma histology, younger age at diagnosis, and non- or light smoker status, similar to those described for *EGFR* mutations. The prevalence of NSCLCs with *ALK* fusion varies from 2% to 8% in the literature, and most studies have been conducted in Asian countries or in the United States of America. Table 1 presents the frequency of *ALK*-rearranged NSCLC in several countries. In Japan, the prevalence of lung cancer with *ALK* rearrangement varied widely, from 2.4% to 6.7% (2,16,19). In Korea, the frequency of *ALK*-positive NSCLC ranged from 3.7% to 4.2% (11,13,14). In China, it was approximately 5% (4,12,15). In the USA, the prevalence varied from 5.6 to 8.2%

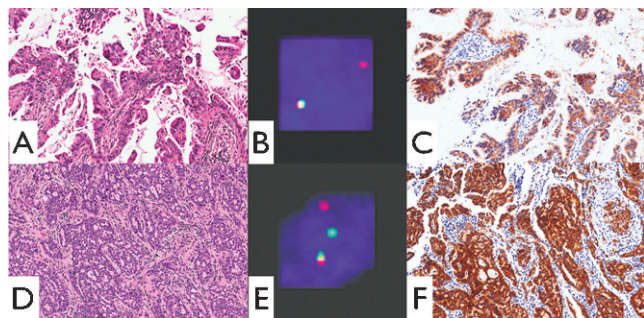


Figure 1 - *ALK*-rearranged NSCLCs. A. Invasive adenocarcinoma, acinar predominant with papillary areas, in a 36-year-old male patient (case 1). B. FISH of case 1 showing one isolated orange signal along with one fusion signal (positive for *ALK* rearrangement). C. *ALK* expression in case 1: diffuse and intense cytoplasmic immunostaining. D. Invasive adenocarcinoma, acinar predominant with mucinous areas, in a 45-year-old male patient (case 2). E. FISH of case 2 showing split orange and green signals along with one fusion signal (positive for *ALK* rearrangement). F. *ALK* expression in case 2: intense cytoplasmic immunostaining in virtually all tumor cells.

Table 1 - Prevalence of *ALK*-rearranged NSCLC in different countries.

Authors, year of publication	Country	<i>ALK</i> -rearranged tumors
Soda et al., 2007 (2)	Japan	6.7% (n=75)
Rodrig et al., 2009 (17)	USA	5.6% (n=358)
Wong et al., 2009 (4)	China	4.9% (n=266)
Sakairi et al., 2010 (19)	Japan	6.4% (n=109)
Takahashi et al., 2010 (16)	Japan	2.4% (n=211)
Sun et al., 2010 (15)	China	5.7% (n=52)
Paik et al., 2011 (11)	Korea	3.8% (n=735)
Li et al., 2011 (12)	China	5% (n=202)
Kim et al., 2011 (13)	Korea	3.7% (n=449)
Paik et al., 2011 (14)	Korea	4.2% (n=453)
Yang et al., 2012 (23)	USA	8.2% (n=300)
Lopes et al. (present study)	Brazil	3.2% (n=62)

(17,23). These findings show that ethnicity likely does not strongly influence the prevalence of *ALK*-rearranged lung carcinomas, which is in contrast to *EGFR*- and *KRAS*-mutated tumors (38-41).

To the best of our knowledge, however, no information about the prevalence and clinical characteristics of these tumors in Latin America, including Brazil, is available in the literature.

In the present study, 3.2% (2 out of 62) of NSCLC cases in Brazilian patients were *ALK* fusion positive by FISH. These two male patients were younger than those with *ALK*-negative FISH, had a history of no or light smoking, and their tumors presented invasive adenocarcinoma histology similar to that described in the literature. Both tumors were histologically classified as acinar predominant: one tumor had papillary areas, and the other was rich in mucinous areas.

Consistent with the results of other studies (13,14,23,33-35), a high concordance between FISH and immunohistochemistry results for the detection of *ALK*-positive NSCLCs was found in the present study. Although FISH remains the gold standard technique for the diagnosis of *ALK*-rearranged lung carcinoma, immunohistochemistry may play an important role in the determination of *ALK* status in NSCLC in the near future. Because data regarding the role of immunohistochemistry in the detection of *ALK*-positive lung cancer are limited in the literature, additional studies are necessary.

The use of crizotinib has changed the history of NSCLC treatment, with dramatic results in patients with *ALK*-rearranged tumors. A recent phase I/II clinical trial showed that 47 of 82 (57%) patients with *ALK* fusion-positive lung tumors confirmed by FISH had objective responses to crizotinib, and an additional 27 (33%) patients displayed stable disease (9). These data highlight that the diagnosis of *ALK*-rearranged NSCLC is crucial.

As previously stated, the present study is the first in Latin America to present clinicopathologic information regarding *ALK*-rearranged NSCLC in patients from this geographic area. Further studies are encouraged to expand our knowledge on *ALK*-positive NSCLC in Latin America and Brazil.

AUTHOR CONTRIBUTIONS

Bacchi CE was responsible for designing and supervising the project, and writing and revising the manuscript. Lopes LF was responsible for data collection, data analysis, and writing the manuscript. All authors approved the final version of the manuscript.

REFERENCES

- Siegel R, Ward E, Brawley O, Jemal A. Cancer statistics, 2011: the impact of eliminating socioeconomic and racial disparities on premature cancer deaths. *CA Cancer J Clin.* 2011;61(4):212-36, <http://dx.doi.org/10.3322/caac.20121>.
- Soda M, Choi YL, Enomoto M, Takada S, Yamashita Y, Ishikawa S, et al. Identification of the transforming EML4-ALK fusion gene in non-small-cell lung cancer. *Nature.* 2007;448(7153):561-6, <http://dx.doi.org/10.1038/nature05945>.
- Soda M, Takada S, Takeuchi K, Choi YL, Enomoto M, Ueno T, et al. A mouse model for EML4-ALK-positive lung cancer. *Proc Natl Acad Sci U S A.* 2008;105(50):19893-7, <http://dx.doi.org/10.1073/pnas.0805381105>.
- Wong DW, Leung EL, So KK, Tam IY, Sihoe AD, Cheng LC, et al. The EML4-ALK fusion gene is involved in various histologic types of lung cancers from nonsmokers with wild-type EGFR and KRAS. *Cancer.* 2009;115(8):1723-33, <http://dx.doi.org/10.1002/cncr.24181>.
- Inamura K, Takeuchi K, Togashi Y, Hatano S, Ninomiya H, Motoi N, et al. EML4-ALK lung cancers are characterized by rare other mutations, a TTF-1 cell lineage, an acinar histology, and young onset. *Mod Pathol.* 2009;22(4):508-15, <http://dx.doi.org/10.1038/modpathol.2009.2>.
- Boland JM, Erdogan S, Vasmatazis G, Yang P, Tillmans LS, Johnson MR, et al. Anaplastic lymphoma kinase immunoreactivity correlates with ALK gene rearrangement and transcriptional up-regulation in non-small-cell lung carcinomas. *Hum Pathol.* 2009;40(8):1152-8, <http://dx.doi.org/10.1016/j.humpath.2009.01.012>.
- Takeuchi K, Choi YL, Soda M, Inamura K, Togashi Y, Hatano S, et al. Multiplex reverse transcription-PCR screening for EML4-ALK fusion transcripts. *Clin Cancer Res.* 2008;14(20):6618-24, <http://dx.doi.org/10.1158/1078-0432.CCR-08-1018>.
- Solomon B, Varella-Garcia M, Camidge DR. ALK gene rearrangements: a new therapeutic target in a molecularly defined subset of non-small-cell lung cancer. *J Thorac Oncol.* 2009;4(12):1450-4, <http://dx.doi.org/10.1097/JTO.0b013e3181c4dedb>.
- Kwak EL, Bang YJ, Camidge DR, Shaw AT, Solomon B, Maki RG, et al. Anaplastic lymphoma kinase inhibition in non-small-cell lung cancer. *N Engl J Med.* 2010;363(18):1693-703, <http://dx.doi.org/10.1056/NEJMoa1006448>.
- Mino-Kenudson M, Mark EJ. Reflex testing for epidermal growth factor receptor mutation and anaplastic lymphoma kinase fluorescence in situ hybridization in non-small-cell lung cancer. *Arch Pathol Lab Med.* 2011;135(5):655-64.
- Paik JH, Choi CM, Kim H, Jang SJ, Choe G, Kim DK, et al. Clinicopathologic implication of ALK rearrangement in surgically resected lung cancer: a proposal of diagnostic algorithm for ALK-rearranged adenocarcinoma. *Lung Cancer.* 2012;76(3):403-9, <http://dx.doi.org/10.1016/j.lungcan.2011.11.008>.
- Li C, Fang R, Sun Y, Han X, Li F, Gao B, et al. Spectrum of oncogenic driver mutations in lung adenocarcinomas from East Asian never smokers. *PLoS One.* 2011;6(11):e28204, <http://dx.doi.org/10.1371/journal.pone.0028204>.
- Kim H, Yoo SB, Choe JY, Paik JH, Xu X, Nitta H, et al. Detection of ALK gene rearrangement in non-small-cell lung cancer: a comparison of fluorescence in situ hybridization and chromogenic in situ hybridization with correlation of ALK protein expression. *J Thorac Oncol.* 2011;6(8):1359-66, <http://dx.doi.org/10.1097/JTO.0b013e31821cfc73>.
- Paik JH, Choe G, Kim H, Choe JY, Lee HJ, Lee CT, et al. Screening of anaplastic lymphoma kinase rearrangement by immunohistochemistry in non-small-cell lung cancer: correlation with fluorescence in situ hybridization. *J Thorac Oncol.* 2011;6(3):466-72, <http://dx.doi.org/10.1097/JTO.0b013e31820b82e8>.
- Sun Y, Ren Y, Fang Z, Li C, Fang R, Gao B, et al. Lung adenocarcinoma from East Asian never-smokers is a disease largely defined by targetable oncogenic mutant kinases. *J Clin Oncol.* 2010;28(30):4616-20, <http://dx.doi.org/10.1200/JCO.2010.29.6038>.
- Takahashi T, Sonobe M, Kobayashi M, Yoshizawa A, Menju T, Nakayama E, et al. Clinicopathologic features of non-small-cell lung cancer with EML4-ALK fusion gene. *Ann Surg Oncol.* 2010;17(3):889-97, <http://dx.doi.org/10.1245/s10434-009-0808-7>.
- Rodig SJ, Mino-Kenudson M, Dacic S, Yeap BY, Shaw A, Barletta JA, et al. Unique clinicopathologic features characterize ALK-rearranged lung adenocarcinoma in the western population. *Clin Cancer Res.* 2009;15(16):5216-23, <http://dx.doi.org/10.1158/1078-0432.CCR-09-0802>.
- Solomon B, Shaw AT. Are Anaplastic Lymphoma Kinase Gene Rearrangements in Non-small-cell lung Cancer Prognostic, Predictive, or Both? *J Thorac Oncol.* 2012;7(1):5-7, <http://dx.doi.org/10.1097/JTO.0b013e31823f1289>.
- Sakairi Y, Nakajima T, Yasufuku K, Ikebe D, Kagayama H, Soda M, et al. EML4-ALK fusion gene assessment using metastatic lymph node samples obtained by endobronchial ultrasound-guided transbronchial needle aspiration. *Clin Cancer Res.* 2010;16(20):4938-45, <http://dx.doi.org/10.1158/1078-0432.CCR-10-0099>.
- Yoshida A, Tsuta K, Nakamura H, Kohno T, Takahashi F, Asamura H, et al. Comprehensive histologic analysis of ALK-rearranged lung carcinomas. *Am J Surg Pathol.* 2011;35(8):1226-34, <http://dx.doi.org/10.1097/PAS.0b013e3182233e06>.
- Zhang X, Zhang S, Yang X, Yang J, Zhou Q, Yin L, et al. Fusion of EML4 and ALK is associated with development of lung adenocarcinomas lacking EGFR and KRAS mutations and is correlated with ALK expression. *Mol Cancer.* 2010;13(9):188, <http://dx.doi.org/10.1186/1476-4598-9-188>.
- Sasaki T, Rodig SJ, Chirieac LR, Janne PA. The biology and treatment of EML4-ALK non-small-cell lung cancer. *Eur J Cancer.* 2010;46(10):1773-80, <http://dx.doi.org/10.1016/j.ejca.2010.04.002>.
- Yang P, Kulig K, Boland JM, Erickson-Johnson MR, Oliveira AM, Wampfler J, et al. Worse disease-free survival in never-smokers with ALK+ lung adenocarcinoma. *J Thorac Oncol.* 2012;7(1):90-7, <http://dx.doi.org/10.1097/JTO.0b013e31823c5c32>.
- Koivunen JP, Mermel C, Zejnullahu K, Murphy C, Lifshits E, Holmes AJ, et al. EML4-ALK fusion gene and efficacy of an ALK kinase inhibitor in lung cancer. *Clin Cancer Res.* 2008;14(13):4275-83, <http://dx.doi.org/10.1158/1078-0432.CCR-08-0168>.
- Hallberg B, Palmer RH. Crizotinib—latest champion in the cancer wars? *N Engl J Med.* 2010;363(18):1760-2, <http://dx.doi.org/10.1056/NEJMe1010404>.
- Trial watch: success for crizotinib in ALK-driven cancer. *Nat Rev Drug Discov.* 2010;9(12):908.
- Ou SH. Crizotinib: a novel and first-in-class multitargeted tyrosine kinase inhibitor for the treatment of anaplastic lymphoma kinase rearranged non-small-cell lung cancer and beyond. *Drug Des Devel Ther.* 2011;5:471-85, <http://dx.doi.org/10.2147/DDDT.S19045>.
- Shaw AT, Solomon B, Kenudson MM. Crizotinib and testing for ALK. *J Natl Compr Canc Netw.* 2011;9(12):1335-41.
- Ou SH, Bazhenova L, Camidge DR, Solomon BJ, Herman J, Kain T, et al. Rapid and dramatic radiographic and clinical response to an ALK inhibitor (crizotinib, PF02341066) in an ALK translocation-positive patient with non-small-cell lung cancer. *J Thorac Oncol.* 2010;5(12):2044-6, <http://dx.doi.org/10.1097/JTO.0b013e318200f9ff>.
- Freeman A, Geddes N, Munson P, Joseph J, Ramani P, Sandick A, et al. Anaplastic lymphoma kinase (ALK 1) staining and molecular analysis in inflammatory myofibroblastic tumours of the bladder: a preliminary clinicopathological study of nine cases and review of the literature. *Mod Pathol.* 2004;17(7):765-71, <http://dx.doi.org/10.1038/modpathol.3800078>.
- Shaw AT, Yeap BY, Mino-Kenudson M, Digumarthy SR, Costa DB, Heist RS, et al. Clinical features and outcome of patients with non-small-cell lung cancer who harbor EML4-ALK. *J Clin Oncol.* 2009;27(26):4247-53, <http://dx.doi.org/10.1200/JCO.2009.22.6993>.
- Martelli MP, Sozzi G, Hernandez L, Pettrossi V, Navarro A, Conte D, et al. EML4-ALK rearrangement in non-small-cell lung cancer and non-tumour lung tissues. *Am J Pathol.* 2009;174(2):661-70, <http://dx.doi.org/10.2353/ajpath.2009.080755>.
- Yi ES, Boland JM, Maleszewski JJ, Roden AC, Oliveira AM, Aubry MC, et al. Correlation of IHC and FISH for ALK gene rearrangement in non-small-cell lung carcinoma: IHC score algorithm for FISH. *J Thorac Oncol.* 2011;6(3):459-65, <http://dx.doi.org/10.1097/JTO.0b013e318209edb9>.
- McLeer-Florin A, Moro-Sibilot D, Melis A, Salameire D, Lefebvre C, Ceccaldi F, et al. Dual IHC and FISH testing for ALK gene rearrangement in lung adenocarcinomas in a routine practice: A French study. *J Thorac Oncol.* 2012;7(2):348-54, <http://dx.doi.org/10.1097/JTO.0b013e3182381535>.
- Hofman P, Ilie M, Hofman V, Roux S, Valent A, Bernheim A, et al. Immunohistochemistry to identify EGFR mutations or ALK rearrangements in patients with lung adenocarcinoma. *Ann Oncol.* 2011 Nov 18. [Epub ahead of print]
- McLeer-Florin A, Moro-Sibilot D, Melis A, Salameire D, Lefebvre C, Ceccaldi F, de Fraipont F, Brambilla E, Lantuejoul S. Dual IHC and FISH testing for ALK gene rearrangement in lung adenocarcinomas in a routine practice: a French study. *J Thorac Oncol.* 2012;7(2):348-54, <http://dx.doi.org/10.1097/JTO.0b013e3182381535>.
- Travis WD, Brambilla E, Noguchi M, Nicholson AG, Geisinger KR, Yatabe Y, et al. International association for the study of lung cancer/american thoracic society/european respiratory society international multidisciplinary classification of lung adenocarcinoma. *J Thorac Oncol.* 2011;6(2):244-85, <http://dx.doi.org/10.1097/JTO.0b013e318206a221>.
- Tsao AS, Tang XM, Sabloff B, Xiao L, Shigematsu H, Roth J, et al. Clinicopathologic characteristics of the EGFR gene mutation in non-small-cell lung cancer. *J Thorac Oncol.* 2006;1(3):231-9.
- Shigematsu H, Lin L, Takahashi T, Nomura M, Suzuki M, Wistuba II, et al. Clinical and biological features associated with epidermal growth factor receptor gene mutations in lung cancers. *J Natl Cancer Inst.* 2005;97(5):339-46, <http://dx.doi.org/10.1093/jnci/dji055>.
- Riely GJ, Marks J, Pao W. KRAS mutations in non-small-cell lung cancer. *Proc Am Thorac Soc.* 2009;6(2):201-5, <http://dx.doi.org/10.1513/pats.200809-107LC>.
- Inamura K, Ninomiya H, Ishikawa Y, Matsubara O. Is the epidermal growth factor receptor status in lung cancers reflected in clinicopathologic features? *Arch Pathol Lab Med.* 2010;134(1):66-72.