

Embolization and radiosurgery for arteriovenous malformations

Andres R. Plasencia, Alejandro Santillan¹

Interventional Neuroradiology Service, Clinica Tezza e Internacional, Lima, Peru, ¹Division of Interventional Neuroradiology, Department of Neurosurgery, New York Presbyterian Hospital, Weill Cornell Medical Center, New York, NY, USA

E-mail: *Andres R. Plasencia - andresplasencia2000@yahoo.com; Alejandro Santillan - santillanmd@yahoo.com

*Corresponding author

Received: 27 February 12

Accepted: 28 March 12

Published: 26 April 12

This article may be cited as:

Plasencia AR, Santillan A. Embolization and radiosurgery for arteriovenous malformations. *Surg Neurol Int* 2012;3:S90-104.

Available FREE in open access from: <http://www.surgicalneurologyint.com/text.asp?2012/3/3/90/95420>

Copyright: © 2012 Plasencia AR. This is an open-access article distributed under the terms of the Creative Commons Attribution License, which permits unrestricted use, distribution, and reproduction in any medium, provided the original author and source are credited.

Abstract

The treatment of arteriovenous malformations (AVMs) requires a multidisciplinary management including microsurgery, endovascular embolization, and stereotactic radiosurgery (SRS). This article reviews the recent advancements in the multimodality treatment of patients with AVMs using endovascular neurosurgery and SRS. We describe the natural history of AVMs and the role of endovascular and radiosurgical treatment as well as their interplay in the management of these complex vascular lesions. Also, we present some representative cases treated at our institution.

Key Words: Arteriovenous malformation, embolization, stereotactic radiosurgery

Access this article online

Website:

www.surgicalneurologyint.com

DOI:

10.4103/2152-7806.95420

Quick Response Code:



INTRODUCTION

Arteriovenous malformations (AVMs) are relatively rare cerebral lesions that may cause significant neurological morbidity in young people. The treatment of cerebral AVMs requires a multidisciplinary approach that includes microsurgery, endovascular embolization, and stereotactic radiosurgery (SRS). Surgical resection remains the gold standard for the radical and definitive eradication of most of these lesions.

Endovascular embolization and SRS are increasingly used for the management of nonsurgical AVMs. For small lesions that are usually deep and/or in eloquent locations, SRS represents a safe and efficacious primary treatment option. If the AVM has bled, targeted endovascular embolization of the AVM is recommended in selected cases because it may decrease the risk of hemorrhage and eradicate radioresistant spots of the lesion during the latency period following SRS.

In this article, we will review the role of embolization and radiosurgery alone with emphasis on the combined

treatment to optimize the eradication of nonsurgical AVMs, as well as the newer fractionated radiosurgical approaches especially designed to treat larger AVMs where a therapeutic plan is not always well defined.

ARTERIOVENOUS MALFORMATION: TO TREAT OR NOT TO TREAT

Brain AVMs are abnormal connections between arteries and veins leading to arteriovenous shunting with an intervening network of vessels also called nidus.^[147] The prevalence of AVMs varies between 10 and 18 per 100,000 adults,^[2,40] with an annual incidence of 1.1 to 1.3 AVMs per 100,000 person-years.^[22] They are responsible for 2% of all hemorrhagic strokes^[19] and usually present before the age of 40 years, affecting men and women equally. The most common presenting symptom of AVMs is hemorrhage, ranging from 42% to 72%.^[8,19,26,64,111] Other symptoms include seizures (focal or generalized), headache, progressive neurological deficit, and pulsatile tinnitus.^[110] The annual risk of hemorrhage ranges from 1.3% to 4% per year,^[19,26,52,111] with an increase up to 6% to

7% in the first year after the previous hemorrhage.^[40,111] The morbidity resulting from hemorrhage ranges from 53% to 81%,^[52,113] whereas mortality ranges from 10% to 30%, although some data suggest that the mortality rate may be lower.^[110] Associated arteriovenous fistulas and prenidial, intranidal, or flow-related aneurysms have demonstrated to increase the risk of rupture of AVMs^[29,77,122,139] as well as small AVM size,^[35,52,152] feeding artery pressures,^[35,98] lesions located in a periventricular or intraventricular locations, presence of deep venous drainage, intranidal or multiple aneurysms, arterial supply via perforators, vertebrobasilar supply, and basal ganglia location.^[12,68,107] Overall, deep-seated lesions have demonstrated to have an early clinical onset, higher bleeding rates, and increased morbidity and mortality (50%) rather than superficial lesions.^[39,75]

Since there are no reliable data regarding the natural history of AVMs and presumably ruptured brain AVMs have a higher hemorrhagic risk (4.5%–34%) than previously unruptured ones (0.9%–8%),^[138] interventional treatment of ruptured brain AVMs is advisable.^[110] The A Randomized Trial of Unruptured Brain AVMs (ARUBA) study which is a prospective, multicenter, randomized controlled trial intends to demonstrate that treatment (surgery, endovascular embolization, or SRS) offers no difference in the risk of stroke or death and no better functional outcome than conservative management at 5 years from the diagnosis of an unruptured AVM.

ENDOASCULAR EMBOLIZATION

Evolving technique of endovascular embolization

The first case of AVM embolization was described by Luessenhop and Spence in 1960^[92] by injecting indiscriminately silicone microspheres directly into the carotid artery. Later on, with the advent of digital subtraction angiography, microcatheters, and microguidewires, different embolic materials were used such as balloons, silk suture fragments, and polyvinyl alcohol (PVA) particles producing permanent or temporary occlusion with subsequent recanalization.^[62,102,127] Over the last decades, more permanent liquid polymers have been used such as *n*-butyl cyanoacrylate (*n*-BCA) (Codman and Shurtleff, Inc., Raynham, MA) and Onyx (ev3 Inc., Irvine, CA).

Efficiency and safety of endovascular embolization

It is paramount that the AVM boundaries are not violated with embolic material, and any evidence of leptomeningeal collateral visualization, filling of the draining veins, “*en passage*” vessels, and small perforators supply during microcatheter injection is considered a contraindication for further embolization through that particular pedicle. In case of a rapid arteriovenous shunt within a fistulous part of the AVM, it can be occluded

by high viscosity, rapidly polymerizing agents, whereas low viscosity, slowly polymerizing agents are superior at achieving distal penetration.^[159]

Goals of endovascular embolization

The goal of embolization is to decrease the size of the nidus and the blood flow by occluding its critical feeders to facilitate the surgical removal by significantly shorten surgical time and reduce blood loss or as an adjunct to surgical or radiosurgical treatment, with a concurrent reduction in morbidity and mortality.^[32,65,99,110,136,159] Symptoms of vascular steal phenomenon, venous hypertension, and seizures may also get some benefit from endovascular embolization.^[46,82,91,110] Partial embolization may be successful in reversing these signs and symptoms; however, it is usually temporary, because collaterals may develop rapidly reducing its effectiveness. It has been demonstrated that there is a higher expression of vascular endothelial growth factor in partially obliterated AVMs caused by transient regional hypoxia within the nidus.^[143] Therefore, complete obliteration of the AVM nidus is recommended to avoid neovascularization.

Definitive cure may be achieved in small Spetzler–Martin grade (SMG) I or II AVMs by endovascular means.^[10,161] Embolization is also used to make larger lesions amenable for surgery or SRS. When embolization is performed before radiosurgical treatment, the following objectives are pursued: decrease the target size to less than 2.5 cm in diameter, eradicate angiographic predictors of hemorrhage, and reduce symptoms related to venous hypertension.^[110]

Embolization as a primary treatment modality for arteriovenous malformations

Both *n*-BCA and Onyx have achieved equivalent results in safety and efficacy as preoperative embolic agents in reducing AVM volume by at least 50% with fewer complication rates.^[24,38,66,70] However, numerous studies indicate that the use of both polymers may result in a recanalization rate ranging from 14% to 18%.^[44,51,109,121]

Endovascular embolization as sole therapeutic modality is usually only achieved in small lesions fed by no more than four arterial pedicles.^[150] On the other hand, staged embolization is beneficial particularly for large AVMs, with embolization of less than 40% of the nidus in one session and limited to one or two arterial pedicles. Furthermore, treating the lesion in a staged fashion may mitigate the risk of hemorrhage due to “*normal pressure perfusion syndrome*.”^[137] Endovascular embolization is not exempt from risks and should only be performed where there is a clear indication for improving the natural history of the AVM in question.^[51,123]

Curative and complication rates of endovascular embolization

The curative rates for primary embolization range from

9% to 84.6% especially in AVMs less than 1 cm in diameter^[7,45,51,151,153,154] [Figure 1]. The morbidity rate related to endovascular embolization ranges from 3.8% to 50% with a mortality rate ranging from 1% to 4%.^[33,45,49,58,61,84,93,104,146] Despite improvement in embolic agents and endovascular techniques, the complication profile of AVM embolization is of concern and the risks of embolization must be weighed against the potential benefit.^[144]

Hartmann *et al.*^[58] found treatment-related neurological deficits in 14% of patients, permanent disabling deficits in 2%, and a mortality rate of 1% in patients treated with n-BCA. Ledezma *et al.*^[84] reported 11 patients (6.5%) with clinically significant complications and 1.2% mortality in a series of 168 patients treated with n-BCA. Hauck *et al.*^[59] reported on preoperative embolization with Onyx in 41 patients and found a permanent neurological deficit in 12.2% of patients. Hamada *et al.*^[56] described the embolization of 57 AVMs with Onyx showing a mortality rate of 0% and a permanent neurological morbidity of 5.3%. Jahan *et al.*^[66] reported their experience with 23 patients treated with Onyx showing a mortality rate of 0% and a permanent deficit of 4%. Lv *et al.*^[95] reported 147 patients treated with endovascular embolization using n-BCA and Onyx. In this series, there were seven permanent complications (4.8%), five of these were ischemic (3.4%) and two hemorrhagic (1.4%) with a mortality rate of 0%. Jayaraman *et al.*^[67] report eight permanent complications (4.2%), five ischemic (2.6%) and three hemorrhagic (1.6%) in 192 patients treated with n-BCA and Onyx.

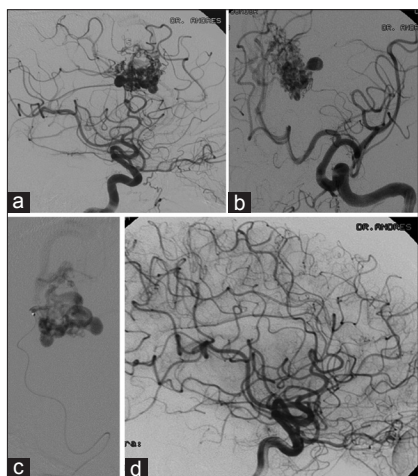


Figure 1: Curative embolization of a Spetzler–Martin grade II arteriovenous malformation (AVM) in an 18-year-old male. (a) Preembolization digital subtraction angiogram (DSA) showing a left premotor AVM. (b) An oblique DSA view shows an associated intranidal aneurysm suspicious to be the source of bleeding. (c) Superselective microcatheterization of the main AVM feeder right before embolization with n-butyl cyanoacrylate. (d) Follow-up DSA 42 months later. The AVM is cured without any clinical sequelae

Arteriovenous malformation embolization: Factors associated with periprocedural complications

Factors that have been found to predispose to hemorrhage during endovascular embolization include microperforation, hemodynamic changes after embolization, significant venous embolization, intranidal aneurysm rupture, and persistent venous stagnation within the nidus.^[67,110] It is important to take into account that not all hemorrhagic events lead to neurological deterioration and may present with headaches or as an incidental finding on a routine computed tomography (CT) scan. Conversely, predictive factors that are thought to be associated with new neurological deficits include increasing patient age, number of embolizations, absence of a pretreatment neurological deficit,^[58] periprocedural hemorrhage, SMG III through IV,^[84] and basal ganglia location.^[67] A recent meta-analysis^[147] showed that younger age and brain AVMs with SMG I through III were associated with lower case fatality, whereas lower proportion of eloquent brain AVMs and higher proportions of obliterated AVMs were associated with lower hemorrhage rates following embolization.

Does a partially embolized arteriovenous malformation decrease the risk for bleeding?

There is no evidence that partial AVM embolization alters long-term hemorrhagic risk, and as such, it is not recommended as a broad treatment strategy for AVMs.^[51,110]

Adjuvant embolization

Preoperative embolization is used as an adjunct to SRS^[16] as it reduces the nidus size and the risk of hemorrhage by occluding associated aneurysms or AV shunts while waiting for the delayed occlusion achieved with complementary SRS^[11,116] [Figures 2–4]. The volumetric reduction after embolization may render an originally untreatable AVM in a lesion potentially curable [Figure 5].

STEREOTACTIC RADIOSURGERY

In 1951, Lars Leksell^[85] described his idea of focusing multiple beams to a target and coined the term radiosurgery. Non-coplanar stationary finely collimated converging radiating beams from 201 Cobalt-60 sources to deposit a large dose of therapeutic radiation with millimetric precision on a small intracranial target inside the brain was called Gamma Knife. The development of GK radiosurgery was used first for functional neurosurgery and later for the treatment of tumors and AVMs.^[34]

Using the same principle, the adapted linear accelerator (LINAC) radiosurgery was pioneered by Betti *et al.*,^[13] using microwave energy to accelerate electrons at very high speed to make them collide with a heavy metallic alloy. Part of that energy was converted into highly

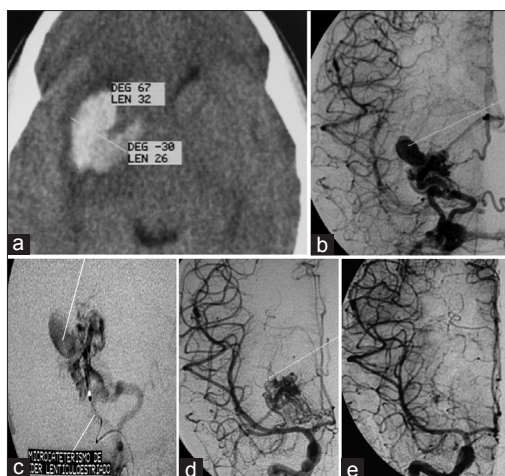


Figure 2: Preradiosurgical embolization of an intranidal aneurysm. (a) Computed tomography scan showing a basal ganglia hematoma. (b) Digital subtraction angiogram (DSA) of the right internal carotid artery (ICA) showing an intranidal aneurysm, identified as the bleeding source. (c) A lateral lenticulostriate artery was catheterized to embolize the aneurysm with n-butyl cyanoacrylate. (d) DSA after embolization shows disappearance of aneurysm. The residual arteriovenous malformation (AVM) was then treated with stereotactic radiosurgery (SRS). (e) A DSA of the right ICA performed 28 months after SRS shows complete cure of the AVM

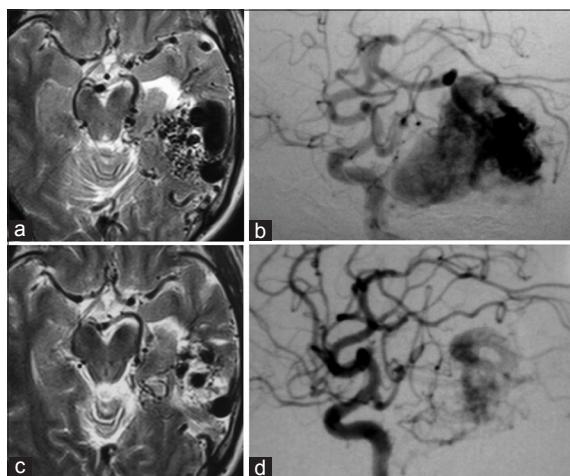


Figure 4: Embolization of an arteriovenous fistula before stereotactic radiosurgery (SRS). This high-flow AV fistula was associated with a left temporal arteriovenous malformation (AVM). The huge varix resulted from venous hypertension obscured the true AVM size. (a) Pre-embolization MRI. (b) Pre-embolization digital subtraction angiogram. (c) Post-embolization MRI (d) Post-embolization DSA showing a very small residual AVM. The patient was subsequently treated with SRS

energetic photons identical to those used in GK. By rotating the gantry of the LINAC in different angles, a set of multiple convergent non-coplanar wide arcs is obtained. The resultant dose distributions and the clinical results are very similar to those obtained by the GK. Beyond physical or theoretical considerations, the quality of both technologies GK and radiosurgery-adapted

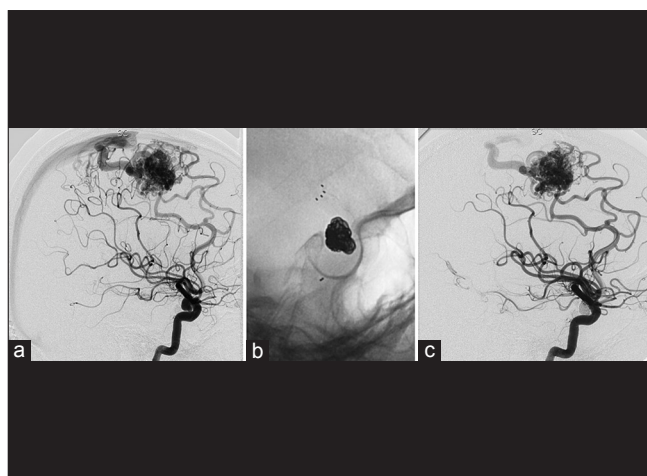


Figure 3: Rolandic arteriovenous malformation (AVM) with proximal for-related wide neck posterior communicating aneurysm before nidus embolization. (a) Digital subtraction angiogram of the right internal carotid artery showing both lesions. (b) The aneurysm was totally occluded with stent-assisted coil embolization as seen in (c). The AVM nidus is scheduled to be embolized and then treated definitely with SRS

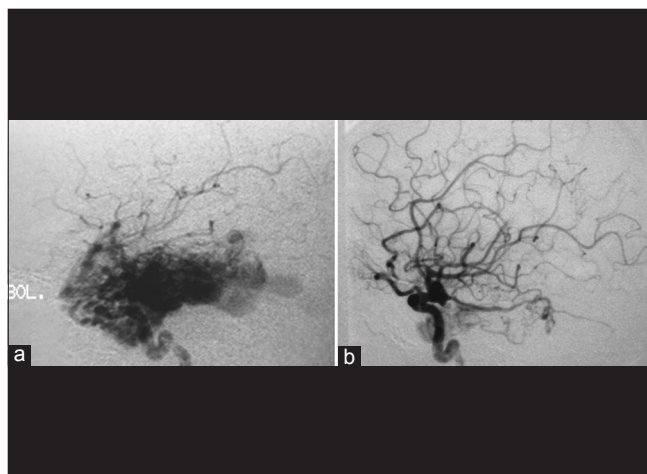


Figure 5: Combined embolization and stereotactic radiosurgery (SRS) for a large arteriovenous malformation Spetzler-Martin grade IV of the left temporal lobe. (a) Digital subtraction angiogram of the left internal carotid artery showing a lesion that occupies most of the temporal lobe on the dominant hemisphere causing significant “vascular steal phenomenon.” (b) Seven years after 4 embolizations and 2 SRS, only a small dural remnant is seen. The patient continues asymptomatic

LINACs as well as the outcome of GK and LINAC radiosurgical series for AVMs are essentially similar.^[9,128]

Other radiosurgical technologies beyond the scope of this review include the use of mini-multileaf collimator, modulated intensity, the frameless non-isocentric robotic system or CyberKnife, and the charged particle accelerator, the synchrocyclotron.

Patient selection

SRS may be used alone as a primary and definitive

treatment of small (≤ 2.5 cm) AVMs in a single intervention, especially those lesions located in eloquent or deep regions of the brain. SRS is used as well for the definitive treatment of postsurgical or postembolized small residual AVMs or in patients who are not good candidates for surgery or refuse surgical treatment. For larger lesions, the radiosurgical treatment may be delivered either by splitting the volume of the nidus or dose by fractionated SRS or stereotactic radiotherapy.

Radiosurgical technique

The basic steps of SRS are the following: (1) Attachment of the stereotactic frame, under local anesthesia. (2) Image acquisition, with fiducial markers to allow the 3D reconstruction of the brain and target. (3) Treatment planning: the margin of the AVM nidus (target volume) is contoured in order to obtain a 3D reconstruction of the AVM. Multiple radiation beams are aimed to the isocenter of the target generating a very conformal treatment volume where a high dose is delivered with a sharp dose fall-off at the adjacent normal brain. This plan is executed by joining the knowledge and expertise of a multidisciplinary team integrated by the neurosurgeon, physicist, and radiation oncologist. (4) Dose selection: the dose is expressed in units of gray (Gy) prescribed to an isodose line (e.g., 18 Gy to the 80% isodose shell) that varies inversely with the volume of the target; the larger the volume of the lesion, the lower the dose. Besides Kjellberg^[79] and Flickinger^[41] guidelines for dose selection, some dose constraints apply for lesions located in eloquent and or deep brain regions to avoid radiotoxicity. Prior radiation therapy may indicate lower doses as well. (5) Radiation delivery: the patient's head is affixed to the treatment couch and the isocenter (s) of the target is positioned by means of a localizer device in the focal point of the radiation beams and the dose is delivered to the target. (6) Stereotactic frame removal: after treatment, the stereotactic ring is removed and the patient is discharged and ready to resume her/his habitual activities. Follow-up MRI studies are usually performed every 6 months for 2–3 years. At the end of this time window or when the nidus seems to be obliterated, an angiogram is performed. If no AVM is noticed, the patient is declared cured. If there is a residual AVM, a repeated radiosurgery is usually proposed.

Detailed aspects of SRS instrumentation and planning are beyond the scope of this article and the interested reader is referred to authoritative reviews.^[3,31,48,50]

STEREOTACTIC RADIOSURGERY AS A PRIMARY TREATMENT MODALITY FOR ARTERIOVENOUS MALFORMATIONS

Pioneered by Steiner *et al.*,^[140] in 1972, SRS has a clear role as a primary treatment of brain AVMs and there

are a myriad of literature reports demonstrating its efficacy with 54–92% of obliteration rates for lesion diameters ≤ 2.5 cm with acceptable rates of reversible radiation-related symptoms and permanent neurological deficits. Bleeding rates during the latency period are low as well; however, a slightly higher bleeding rate after GK radiosurgery has been found. However, most of these patients had history of hemorrhage before SRS.^[73,74,94,116,130,140,141,156-158] The radiosurgical adaptation of the LINAC unit was pioneered by Betti and colleagues.^[13] Further series reported by other LINAC RS groups have shown similar results to those obtained with the Gamma Knife.^[14,25,37,47,112,125,135] In Table 1, we summarized the results of the largest reports of SRS for AVMs.

Orio *et al.*^[112] compared the outcomes of 187 AVM patients treated at their institution with GK and LINAC SRS. The overall obliteration rate reached 66% without statistically significant differences in radiotoxicity between both groups.

However, true obliteration rates found in the radiosurgical literature lack standardization due to the variable number of treatments, extent of follow-up, and neuroimaging modalities used. Many patients refuse angiography, are lost to follow-up, and physicians are biased by MR findings to proceed with follow-up angiography.

RADIOSURGERY FOR ARTERIOVENOUS MALFORMATIONS IN SPECIFIC LOCATIONS

Brainstem arteriovenous malformations

Reported obliteration rates ranged from 59% to 76% with a few patients requiring repeated SRS. The mean target volume varies between 1.3 and 1.9 cm³ with a mean marginal dose (MD) around 20 Gy. The reported bleeding rate varies between 3.5% and 6% with related fatalities from 1% to 3%. Permanent radiation-related complications ranged between 6% and 10%. Many authors emphasize that a small nidus volume with a high prescription dose and a conformal treatment volume is significantly associated with an increased AVM obliteration rate and safe and effective SRS.^[70,101,160]

Basal ganglia, internal capsule, thalamus, and corpus callosum arteriovenous malformations

For basal ganglia, internal capsule, and thalamus, the reported obliteration rates were between 43% and 85.7%. However, significantly lower obliteration rates (37% vs. 100%) were seen in larger AVMs (>3 cm³). The bleeding rates during follow-up periods from 1 to 4 years ranged from 8% to 14.2% with 9% bleeding-related fatalities. Overall, complication rate from 4% to 19% was found to correlate with larger AVM volumes and higher SMGs. Permanent radiation-related neurologic deficits were seen in 12% of the cases. The lower obliteration rates achieved in centrally located AVMs emphasize the difficulty in

Table 1: Arteriovenous malformation radiosurgery: Results of major series*

Author, Year	SRS System	No. of patients	Mean volume of the lesion (cm ³)	Cure rate (%)	Radiation-related complications		Hemorrhage rate (%)
					Overall complications (%)	Permanent neurological deficits (%)	
Lunsford <i>et al.</i> ^[69] , 1991	GK	227	< 1 1 - 4 > 4	100 85 58	26	5	5
Colombo <i>et al.</i> ^[24] , 1994	LINAC	180	NP	80	NP	2	8 (4 fatal)
Engenhart <i>et al.</i> ^[35] , 1994	LINAC	212	<4.2 ≤33.5 ≤113	83 75 50	NP	4.3	NP
Karlsson <i>et al.</i> ^[69] , 1997	GK	945	NP	56	NP	5	5.8
Schlienger <i>et al.</i> ^[120] , 2000	LINAC	169	<2.5	64	NP	5	2.3 (1 fatal)
Douglas <i>et al.</i> ^[32] , 2008	GK	95	3.8	71.4	7.4	NP	16 (2.1 fatal)
Friedman <i>et al.</i> ^[45] , 2011	LINAC	NP	<10	80	NP	2	NP

SRS: Stereotactic radiosurgery, GK: Gamma Knife radiosurgery, LINAC: Linear accelerator radiosurgery, NP: Not provided, *Follow-up extended from 18 months to 6 years

treating patients with deeply located AVMs; the majority of them are also poor surgical or endovascular candidates. These results showed that although relatively lower obliteration rates and higher complication rates are seen compared with AVMs in other locations, SRS for deep AVMs has significant obliteration rates with an acceptable morbidity considering the risk of morbidity associated with other treatments and zero mortality suggesting that SRS may be the first choice of treatment modality for this subgroup of AVMs.^[6,27,78,117,124] Maruyama *et al.*^[100] reported 32 patients, with small AVMs of the corpus callosum that underwent GK radiosurgery. The odds ratios were 64% and 74% at 4 and 6 years, respectively.

Rolandic cortex and postgeniculate visual pathway arteriovenous malformations

Hadjipanayis *et al.*^[55] and Andrade-Souza *et al.*^[5] reported on AVMs of the motor cortex treated with GK and LINAC SRS. The median target volume was between 4.35 and 8.1 cm³. The median doses were 15 and 20 Gy. Obliteration rates of 83% and 50% for GK and 87% and 56% for LINAC were achieved for AVMs <3 and ≥3 cm³, respectively. Radiation-related adverse effects were found in 5.3% and 18.4%. In the LINAC cohort, 5.2% developed neurological sequelae. Among the patients who presented with seizures, 63% and 51.8% treated with GK and LINAC SRS, respectively, became seizure free.

Pollock *et al.*^[120] treated 34 patients with GK harboring AVMs located within the postgeniculate optic radiations or striate cortex. The target volume was 4.7 cm³ with a MD of 21 Gy. Two patients (6%) developed new partial visual field defects, but no patients developed a new permanent homonymous hemianopsia. The obliteration

rate was 65%. Among AVMs ≤4 cm³, 81% were cured. After second SRS, the obliteration rate increased to 71%. The annual bleeding rate was 2.4%. No patients bled after angiographically confirmed obliteration. In most patients, SRS obliterates visual pathway AVMs and also preserves preoperative visual function.

Despite the dose constraints regarding AVMs in or near the brainstem, diencephalons, and visual pathway, SRS has demonstrated to be safe and effective in the definitive treatment of small AVMs with low rates of morbidity compared with other treatments, indicating that this method may be the first choice for these otherwise poor surgical or endovascular candidates.

STEREOTACTIC RADIOSURGERY FOR ARTERIOVENOUS MALFORMATIONS: FACTORS THAT INFLUENCE THE SUCCESS RATE

The most important factor for AVM obliteration is the dose (marginal and maximal). Other identified predictors are low SMG, single draining vein, male gender, absence of prior embolization, monoisocentric planning, and pre-SRS bleeding. Dose correlates inversely with volume, i.e., the larger the lesion, the smaller the dose and vice versa. Other relevant factors that influence dose selection are as follows: nidus location, angioarchitecture, and dynamics of the lesion (diffuse vs. compact nidus, presence of intranidal aneurysms, high flow fistulae, and venous drainage stenosis). Every neurological location has its own radiation dose tolerance threshold that has to be taken into account for dose selection. Noneloquent locations may allow for larger doses. Compact AVM niduses are better targets for

radiosurgery than diffuse or plexiform nidus because the former has no neural tissue inside the target volume and larger doses may be prescribed.^[21,42,89,94,125,130]

STEREOTACTIC RADIOSURGERY FOR ARTERIOVENOUS MALFORMATIONS: FACTORS FOR FAILURE

Identified predictors of failed SRS are incomplete angiographic definition of the nidus, either because of recanalization after embolization, a hidden part of the nidus due to recent hematoma or because of “radiobiological resistance.” The latter correlates mainly to intranidal arteriovenous fistulae. Nidus outside the prescription isodose line was another factor, as well as large volume, high-grade AVMs and diffuses niduses, which correlated with relative low MD. Deep-seated AVMs were demonstrated to have lower obliterations rates than their peripheral counterparts. Finally, interobserver variations in target definition in digital subtraction angiography have been shown to correlate with failed SRS. Almost all of these factors may result in underdosage to the AVM and, thereby, contribute to treatment failure.^[4,20,36,78,83,116,119,164] Bing *et al.* evaluated the potential impact of embolization material on radiation dose distributions in an *in vitro* model. The authors concluded that the dose was not reduced significantly.^[15]

ARTERIOVENOUS MALFORMATION BLEEDING AFTER SRS

The major disadvantage of radiosurgery is the bleeding risk during the latency period in which obliteration occurs. The issue of a potential protection conferred by SRS before AVM obliteration remains controversial. The bleeding rates reported ranged from 1.6 to 9%, roughly similar to the natural history of the disease before obliteration. Nevertheless, there are some reports that show AVM rupture after angiographic obliteration.^[87,129]

REPEATED RADIOSURGERY

The strategy of repeated stereotactic irradiation as an option for incompletely obliterated AVMs has been explored by some investigators and the obliteration rates ranged from 56% to 71% and neurological complications from 5% to 18% (equal or a little higher than the average for a primary SRS). The bleeding rates were significantly higher corresponding to the elapsed waiting periods.^[43,60,71,72,96,126]

STEREOTACTIC RADIOSURGERY FOR MULTIPLE ARTERIOVENOUS MALFORMATIONS

Yahara *et al.*^[155] and Kikuchi *et al.*^[76] reported one

and two pediatric patients with three and two AVMs, respectively, associated with hereditary hemorrhagic telangiectasia (HHT) treated successfully with LINAC in a single intervention. Distinctively, multiple AVMs in patients with HHT are small and consequently suitable for radiosurgery [Figure 6].

RADIOSURGICAL STRATEGIES FOR LARGE-VOLUME ARTERIOVENOUS MALFORMATIONS

The inefficacy of SRS to treat large-volume AVM with a single dose led to the development of two options: to cover all of the nidus volume in several sessions (dose fractionation or dose staging or hypofractionation) and to divide a large AVM volume in two or more subvolumes and treat each one with standard radiosurgical doses in sessions separated over time (volume staging or volume fractionation).

Dose staging

Steiner *et al.* explored volume fractionation using LINAC in 1986. In 2 of 26 patients, angiographic obliteration was achieved after 5 years^[88] Veznedaroglu *et al.*^[148] treated 30 AVMs ≥ 14 cm³ with dose staging using LINAC. In the early phase of their study, the authors prescribed a total dose of 42 Gy divided into 6–7 Gy fractions. After delayed complications, the dose dropped to 5 Gy fractions in six fractions. The group of patients in the cumulative dose of 42 Gy showed a 5-year follow-up, an obliteration rate of 83%, while in the group with a total dose of 30 Gy the rate dropped to 22%. The authors concluded that fractionated stereotactic radiation achieves obliteration

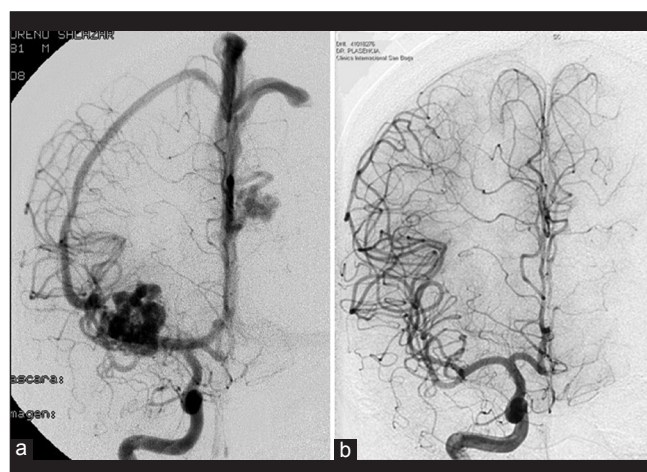


Figure 6: Stereotactic radiosurgery for multiple arteriovenous malformations (AVMs) associated with hereditary hemorrhagic telangiectasia. A 25-year-old female with two AVMs located in the right frontoorbital and left prefrontal lobes. (a) Digital subtraction angiogram of the right internal carotid artery before stereotactic radiosurgery and (b) 3 years later. Both AVMs were cured without any clinical sequelae

for AVMs at a threshold dose, including large residual niduses after embolization.

Volume staging

Pollock *et al.*^[118] treated 10 large AVMs (median AVM volume of 17.4 cm³) with staged-volume radiosurgery in 6-month intervals. They utilized intracranial landmarks to minimize radiation overlap. Radiosurgical procedures were continued until the entire lesion was irradiated. The radiation dosimetry of staged-volume AVM radiosurgery was compared with hypothetical single-session procedures for the 10 patients. The authors found that this strategy results in less radiation exposure to the adjacent brain.

Sirin *et al.*^[133] reported 37 AVM patients with an average volume of 24.9 cm³. With a MD of 16 Gy at each of two stages, at a follow-up period of more than 36 months, 50% and 29% of the patients had total and near-total obliteration, respectively. Permanent radiation-related morbidity was 4% and bleeding was noted in 4 of 28 patients.

Kano *et al.*, of the same group of Pittsburgh,^[69] treated 47 AVM patients with staged-volume SRS. The median target volume was 11.5 and 9.5 cm³ in the first and second stage, respectively. With a MD of 16 Gy for each stage and after a median follow-up of 87 months and two to four SRS interventions, a cure rate of 36% was attained. The actuarial rates of total obliteration after two-stage SRS were 7%, 20%, 28%, and 36% at 3, 4, 5, and 10 years, respectively. The 5-year total obliteration rate after the initial staged volumetric SRS with a MD of 17 Gy or more was 62% ($P = 0.001$). Sixteen patients underwent additional SRS at a median interval of 61 months after the initial two-stage SRS. The overall rates of total obliteration after staged and repeat SRS were 18%, 45%, and 56% at 5, 7, and 10 years, respectively. Ten patients sustained hemorrhage after staged SRS, and five of these patients died. Three of 16 patients who underwent repeat SRS sustained hemorrhage after the procedure and died. The cumulative rates of AVM hemorrhage after SRS were 4.3%, 8.6%, 13.5%, and 36% at 1, 2, 5, and 10 years, respectively. This corresponded to annual hemorrhage risks of 4.3%, 2.3%, and 5.6% for years 0–1, 1–5, and 5–10 after SRS. Symptomatic adverse radiation effects were detected in 13% of patients, but no patient died as a result of an adverse radiation effect.

Overall, volume-staged SRS for large AVMs unsuitable for surgery has potential benefits but often requires more than two interventions to achieve nidus obliteration. To have a reasonable chance of benefit, the minimum margin dose should be 17 Gy or greater, depending on the AVM location [Figure 7]. Differences between coordinate systems of sequential stereotactic frame placements may produce potential overlapping between significant isodose volumes that may explain increasing rates of radiotoxicity [Figure 8]. Multiple latency periods

imply higher bleeding rates as well. Prospective volume-staged SRS combined by embolization (to reduce flow, obliterate fistulas, and occlude associated aneurysms) studies are needed to evaluate their impact on cure rate and in the risk of hemorrhage after SRS.

The compactness of the nidus is an important factor when choosing the strategy of the dose plan. If the nidus is compact, without intervening normal brain tissue, two independent dose plans for two separate target volumes are relatively safe. The resulting hot spot in the two stages will be located within the nidus and cause little adverse effect on normal brain tissue. If the nidus is less compact, with significant intervening normal brain tissue between the two separated target volumes, however, it would be better to perform a prospective dose plan to cover the entire nidus and then split it into two stages for treatment.^[23]

According to the Pittsburgh group, it is better to treat the nidus following the same principle for microsurgery—that is to start from the deepest region to the most superficial and from the medial to the lateral.^[132]

COMBINED RADIOSURGERY AND EMBOLIZATION

The combination of both minimally invasive modalities has increasingly been advocated for large AVMs. We will analyze this strategy and embolization as a salvage treatment in bleeding after radiosurgery for residual AVMs.

Endovascular embolization prior to radiosurgery

It has two different goals: volumetric reduction and targeted embolization for eradication of AVM-related aneurysms and fistulae.

Embolization for arteriovenous malformation volumetric reduction

By decreasing an AVM nidus, a larger dose can be prescribed in order to increase the obliteration probability without increasing the radiosurgical risk.

Dawson *et al.*^[30] and later Lemme-Plaghos *et al.*^[86] pioneered this strategy using PVA particles in small AVM series. Mathis *et al.*^[103] reported 24 large AVM patients (diameter >3.0 cm; volume >14 cm³) previously treated with particulate embolization and SRS, achieved complete obliteration in 12 (50%), comparing favorably with a 58% obliteration rate in a group of AVMs having a 4–10 cm³ volume, treated by radiosurgery alone. Recanalization of embolized, but not radiated, AVM segments was identified in 3 (12%) patients. However, long-term occlusion was demonstrated in the embolized portions of most AVMs subsequently treated by radiosurgery. Complications included 1 (4%) patient with a mild upper extremity paresis after SRS and 2 (8%) patients with transient neurologic deficits after

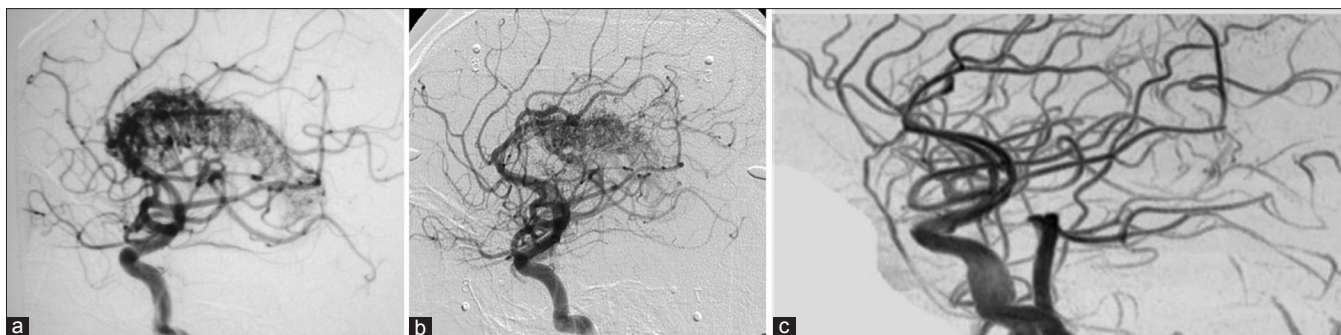


Figure 7: Staged-volume stereotactic radiosurgery (SRS). A 21-year-old man presented with intraventricular hemorrhage caused by a large corpus callosum arteriovenous malformation (AVM). The patient had an uneventful recovery. (a) Digital subtraction angiogram before SRS. (b) Two years later, after the first SRS the rostral part of the AVM disappeared. (c) Two years following the second SRS, the AVM was completely cured

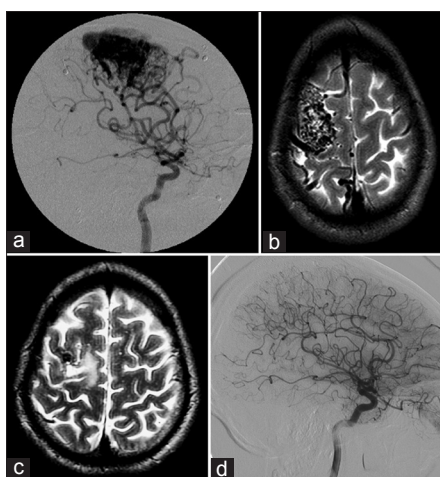


Figure 8: Large arteriovenous malformation (AVM) treated with two sessions of staged stereotactic radiosurgery (SRS) with transient complication in a 37-year-old male presenting with headache. (a) Digital subtraction angiogram (DSA) showing a large right frontal AVM. (b) Axial T2W MRI before SRS. Six months after the second SRS, the patient presented with several episodes of subintractable generalized seizures and post-ictal left hemiparesis managed with corticosteroids and antiepileptics, that (c) correspond to a T2W hyperintense signal. (d) DSA performed 26 months after the second SRS shows cure of the AVM. The patient is seizure-free and without any neurological sequelae

embolization. It appeared that combined embolization and SRS were more efficacious than SRS alone for large brain AVMs. Recanalization after embolization did occur but was a relatively minor cause of treatment failure.

Guo *et al.*^[53] reported 46 AVM patients, 35 had large grade III to V AVMs where staged combined treatment was planned. In 11 patients, radiosurgery complemented embolization for a residual AVM. The number of embolization sessions ranged from 1 to 7 (median 2). Twenty-six patients needed multiple embolization sessions. In 28 patients, the grade of AVMs decreased as a result of embolization. In 16 patients, collateral feeding vessels developed after embolization which

made delineation of the residual nidus difficult. The time lag between the last embolization and radiosurgery ranged from 1 to 24 months (median 4). Neurological complications occurred in 9 patients related to embolization and in 2 from radiosurgery. The author concluded that embolization facilitates radiosurgery for some large AVMs, and therefore this combined treatment has a role in the management of AVMs.

Gobin *et al.*^[51] used embolization to reduce the size of 125 inoperable AVM patients before definitive treatment with radiosurgery. Embolization produced total occlusion in 11.2% of AVMs and reduced 76% of AVMs enough to allow radiosurgery. SRS produced total occlusion in 65% of the partially embolized AVMs (79% when the residual nidus was <2 cm in diameter). Embolizations resulted in a mortality rate of 1.6% and a morbidity rate of 12.8%. No complications were associated with radiosurgery. The hemorrhage rate for partially embolized AVMs was 3% per year. No patient with a completely occluded AVM experienced rebleed. N-BCA embolized AVMs had an 11.8% revascularization rate, occurring within 1 year.

Henkes *et al.*^[62] studied 64 AVM patients treated with embolization and SRS. A total of 253 embolization procedures were performed. A mean size reduction of the AVMs of 63% was achieved. Neurological complications were transient in 12 patients and mild but permanent in 4 patients. Following SRS, one patient died due to recurrent intracerebral hemorrhage. Among 30 patients with angiographic follow-up beyond the latency period after radiosurgery, 14 (43%) were cured. The authors pointed out that AVM obliteration after embolization and radiosurgery is less frequently achieved than after stereotactic irradiation of primarily small AVMs.

Zabel-Du Bois *et al.*^[163] reported 50 AVM patients who underwent embolization and radiosurgery. The median AVM volume was 4 cm³. They reached actuarial obliteration rates of 67% and 78% at 3 and 4 years after SRS, respectively.

Embolization before SRS may obscure the delineation of the AVM by superimposition of embolic material and the presence of collateral feeding vessels.^[119] Shtraus *et al.* reported on 16 patients who underwent SRS after partial embolization with Onyx. In this report, Onyx was associated with image distortion altering the 3D shape of the AVM, especially prominent on CT scan, which may lead to the deposition of excess dose or underdoing the target. The authors conclude that the former could produce radiation-related necrosis and the latter is unlikely to provide effective prophylaxis against the sequelae of AVMs.^[131] A recent meta-analysis^[147] found that preradiosurgical embolization before SRS was associated with higher chance of complete obliteration. Also, embolization is performed before SRS to eradicate potential sources of hemorrhage, such as aneurysms or venous ectasia.^[110]

Contrary to presurgical embolization, preradiosurgical AVM embolization demands an optimal permeation of the nidus instead of simple proximal disconnection of some afferent arteries because the nidus will not be excised. If radiosurgery is scheduled close to embolization, delayed recanalization of some AVM compartments outside the irradiated target volume may result in radiosurgical failure. Delayed scheduled radiosurgery may face collateral pial recruitment postembolization intense enough to obscure the nidus margins at the time of contouring during radiosurgical planning. Pathological studies indicate that the proper time window to reevaluate if recanalization has occurred seems to be at least 2–3 months.^[17,149]

Embolization to eradicate AVM-related aneurysms or fistulae

Associated cerebral aneurysms can be demonstrated in about 15% of all AVMs. However, on the basis of findings of superselective AVM microcatheterization, Turjman *et al.* reported an incidence of 58% of associated aneurysms.^[145] In this scenario, the annual bleeding rate may raise to 7%. If the aneurysm is intranidal, this risk may escalate to 9.8%.^[12,18,122] Therefore, the recommended therapeutic strategy is to obliterate first or simultaneously the associated aneurysm because the lower annual bleeding rate of an AVM compared with an aneurysm and because morbimortality of an aneurysm rupture is higher than an AVM^[12,24,28] Obviously this task is more feasible when aneurysm is close to the nidus, so both AVM and aneurysm can be embolized. However, this is not always feasible and different approaches may be necessary, which increases the complexity and risk of the overall treatment. Besides surgery, embolization may play an important role in the treatment of a proximal aneurysm associated with an AVM by means of Guglielmi detachable coil embolization.^[38]

Piotin *et al.*^[114] stated that in AVM patients with hemorrhagic presentation where the aneurysm is the

suspected bleeding source, it should be treated first with either glue or coils. If the nidus of the AVM is responsible for the bleeding, the treatment is aimed primarily to the AVM. When distally located aneurysms are present on arterial feeders, however, the first endovascular session may be focused on the treatment of both the nidus of the AVM and the aneurysm. This can often be achieved with intranidal glue injection with a flow-dependent microcatheter until there is reflux into the arterial feeder and the aneurysmal sac. If the source of the bleeding cannot be established radiologically, the authors recommend starting by focusing the treatment on the aneurysm. For proximal unruptured aneurysms, the focus of the treatment should be the AVM if the latter is the cause of the bleeding. If neither the aneurysm nor the AVM has bled, they consider treatment of the aneurysm first, knowing that the morbidity and mortality rates associated with hemorrhage of the aneurysm are greater than they are with hemorrhage of the AVM.^[90] With this multimodal approach, 5 patients among 30 resulted with neurological complications but no deaths. Of note, in this series there was no spontaneous regression of any aneurysms on follow-up.^[114]

The rate for spontaneous regression of untreated feeding “pedicle aneurysms” after GK radiosurgery for AVMs is about 50% and these aneurysms were mainly located on the distal portion of the feeder to the nidus^[54] Redekop *et al.*^[122] reported on the effect of AVM treatment on aneurysm and they estimated the spontaneous regression rate of the feeding artery aneurysms that were between the proximal and distal pedicle artery. They revealed that the associated aneurysms on the distal pedicle feeder are easier to regress than those on the proximal pedicle feeder. This result suggests that associated aneurysms are more susceptible to regression in response to decreased blood flow into the nidus by the radiosurgical effect in the case that a distal branch of the artery harboring the associated aneurysm. Overall, the fate of aneurysms in the setting of partially or completely obliterated AVMs remains unpredictable, and the regression, enlargement, and *de novo* aneurysm formation after substantial AVM therapy have been reported, demanding close follow-up and treatment in case of enlargement.^[80,115,122,142] Valavanis and Yasargil and subsequent authors have suggested that appropriately targeted AVM embolization in otherwise untreatable AVMs may actually reduce the risk of hemorrhage, particularly if nidal aneurysms are embolized.^[97,146] For most glomerular pial AVMs, liquid embolic materials are the first choice of treatment. Depending on the type of embolic agent and the nidus (fistulous versus nidal), the injection techniques will vary. To prevent venous migration, temporary lowering of the blood pressure or compression of jugular veins may be done. To date, there is an ongoing debate as to what kind of liquid embolic agent to use.^[81] This concept of

reinforcing weaker elements of the AVM architecture in order to decrease its bleeding rate was demonstrated by Meisel *et al.* in a large series of more than 600 AVM patients. The yearly hemorrhage incidence rate of patients before partial treatment was 0.062 [95% CI (0.03–0.11)], and the observed annual rate after the start of this regimen was 0.02 [95% CI (0.012–0.030)].^[105]

Besides aneurysms, intranidal fistulae are critical angioarchitectural elements considered resistant to radiosurgery that needs to be obliterated before radiosurgery to improve the radiosurgical outcome.^[162] Soderman *et al.*^[134] describe intranidal fistula as a “weak spot” for hemorrhage. This is a target we chose in those patients in whom an intranidal aneurysm was not seen or could be targeted. These findings are in keeping with those of Crawford *et al.* who showed that partial targeted embolization with n-BCA reduced the long-term risk of hemorrhage by 24–78% when intranidal aneurysms or fistulae were targeted.^[26]

Safe pial AVF embolization demands considerable experience of the operator and expertise in calibration of the polymerization time if n-BCA is going to be used. Glue has to harden right into the fistulous site. In case of proximal pedicle occlusion, recanalization is the rule. Contrarily, in case of glue migration to the draining vein, an increased nidus pressure may lead to catastrophic bleeding. To prevent venous migration, temporary lowering of the blood pressure or compression of jugular veins may be performed.^[81] Permanent obliteration of dural supply in mixed pial-dural AVMs is another goal for targeted embolization and in the setting of collateral arterial recruitment after AVM embolization proximal to the nidus. In this case, an incomplete angiographic assessment during radiosurgical image acquisition may exclude dural compartments out of the target volume.^[106]

Arteriovenous malformation embolization after failed radiosurgery (salvage embolization)

Hodgson *et al.* described postradiosurgical embolization of residual intranidal arteriovenous fistulas that were obscured at the time of radiosurgical planning. The AVMs were finally cured with this approach.^[63] An example of this strategy applied to a case at our institution is shown in Figure 9.

FINAL REMARKS

The annual cumulative bleeding risk derived from available AVM natural history studies is generalized to be 2–4%. The bleeding risk of a given AVM subgroup is missing, but it is necessary to get an accurate balance between the risk of the natural history against the risk(s) of the planned intervention(s).^[22,57] In case of a ruptured AVM, the need of treatment may be compelling, but in the case of an unruptured AVM, especially if

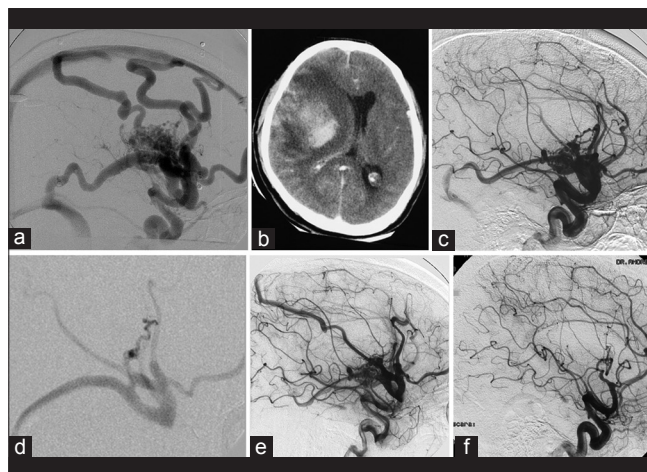

Figure 9: Salvage embolization after stereotactic radiosurgery (SRS) in a 42-year-old male presenting with seizures. (a) A high-flow arteriovenous malformation (AVM), presumably associated with an intranidal AVF, was treated with SRS. (b) Eighteen months after SRS, the AVM bled. The patient had sequelae of a left upper limb paresis. (c) A follow-up digital subtraction angiogram showed a small residual nidus in advanced obliteration status. (d) Superselective microcatheterization of the dominant feeder was followed by n-butyl cyanoacrylate embolization. (e) Marked flow stagnation after embolization. (f) Two years after SRS and 6 months after rescue embolization, the AVM is cured

asymptomatic or with a benign course, the decision is not clear.^[57] To clarify this critical issue, the ARUBA (a randomized trial of unruptured brain AVMs) study has been designed.^[108]

Among the minimally invasive therapies for nonsurgical AVMs, SRS alone can cure most of AVMs smaller than 2.5 cm in diameter or 10 cm³ in volume, while it has been shown to be significantly less effective for AVMs above that size. The success of SRS for AVMs depends on the dose applied. The incidence of radiation-induced side effects increases with the applied dose and treatment volumes.

Endovascular embolization may decrease the AVM volume to increase the radiosurgical dose prescribed to the residual nidus and consequently increase the chance of obliteration. The presence of intranidal aneurysms in the setting of a hemorrhagic AVM indicates strongly targeted embolization aiming to seal the bleeding point to decrease the chance of rebleeding during the 2 years of latency for obliteration. Intranidal fistulae are considered to be a radiation-resistant structure because of its large lumen radius and its high flow. This contributes to enlarge the drainage veins obscuring the target nidus. Therefore, both intranidal aneurysms and fistulae are appealing targets for preradiosurgical embolization. However, prior embolization may decrease the radiosurgical obliteration rate of an AVM, having also inherent risks of morbidity and mortality. The cumulative risk of the sessions planned combined with the risk of SRS may outweigh

the risk of conservative medical management in selected cases. Fractionated radiosurgery for large AVMs is just being explored in few renowned centers, and results still leave much to be desired.

Since partial obliteration of an AVM does not protect against the risk of hemorrhage from the residual nidus and the bleeding rate remains as much the same to the natural history of the disease,^[51,110] a multidisciplinary neurovascular team must develop an individualized and realistic therapeutic strategy, if feasible, to achieve the definitive eradication of a given AVM with a reasonable risk/benefit ratio. The multimodality management of symptomatic large AVMs may take many years and the cumulated risk of each planned intervention plus the morbidity and mortality associated to the likelihood of bleeding during the latency period must be balanced against the natural history of the disease in the decision-making process.

Until conclusive studies regarding the natural history of the disease and the results of randomized studies on the outcomes of embolization and or radiosurgery of AVMs are completed, the training, equipment, and experience of the neurovascular team at each institution and the art of patient selection for treatment of AVMs will continue to play a significant role in the management of these lesions.

REFERENCES

- Arteriovenous malformations of the brain in adults. *N Engl J Med* 1999;340:1812-8.
- Al-Shahi R, Fang JS, Lewis SC, Warlow CP. Prevalence of adults with brain arteriovenous malformations: A community based study in Scotland using capture-recapture analysis. *J Neurol Neurosurg Psychiatry* 2002;73:547-51.
- Alexander E, Loeffler JS, Lunsford LD. *Stereotactic Radiosurgery*. New York: McGraw-Hill; 1993.
- Andrade-Souza YM, Ramani M, Scora D, Tsao MN, terBrugge K, Schwartz ML. Embolization before radiosurgery reduces the obliteration rate of arteriovenous malformations. *Neurosurgery* 2007;60:443-51; discussion 451-2.
- Andrade-Souza YM, Ramani M, Scora D, Tsao MN, TerBrugge K, Schwartz ML. Radiosurgical treatment for rolandic arteriovenous malformations. *J Neurosurg* 2006;105:689-97.
- Andrade-Souza YM, Zadeh G, Scora D, Tsao MN, Schwartz ML. Radiosurgery for basal ganglia, internal capsule, and thalamus arteriovenous malformation: Clinical outcome. *Neurosurgery* 2005;56:56-63; discussion 63-4.
- Andreou A, Ioannidis I, Laloo S, Nickolaos N, Byrne JV. Endovascular treatment of intracranial microarteriovenous malformations. *J Neurosurg* 2008;109:1091-7.
- ApSimon HT, Reef H, Phadke RV, Popovic EA. A population-based study of brain arteriovenous malformation: Long-term treatment outcomes. *Stroke* 2002;33:2794-800.
- Attia M, Menhel J, Alezra D, Pfeffer R, Spiegelmann R. Radiosurgery--LINAC or gamma knife: 20 years of controversy revisited. *Isr Med Assoc J* 2005;7:583-8.
- Ayad M, Eskioglu E, Mericle RA. Onyx: A unique neuroembolic agent. *Expert Rev Med Devices* 2006;3:705-15.
- Back AG, Zeck O, Shkedy C, Shedden PM. Staged embolization with staged gamma knife radiosurgery to treat a large AVM. *Can J Neurol Sci* 2009;36:500-3.
- Batjer H, Suss RA, Samson D. Intracranial arteriovenous malformations associated with aneurysms. *Neurosurgery* 1986;18:29-35.
- Betti O, Derechinsky V. [Multiple-beam stereotaxic irradiation]. *Neurochirurgie* 1983;29:295-8.
- Betti OO, Munari C, Rosler R. Stereotactic radiosurgery with the linear accelerator: Treatment of arteriovenous malformations. *Neurosurgery* 1989;24:311-21.
- Bing F, Doucet R, Lacroix F, Bahary JP, Darsaut T, Roy D, et al. Liquid embolization material reduces the delivered radiation dose: Clinical myth or reality? *AJNR Am J Neuroradiol* 2012;33:320-2.
- Bollet MA, Anxionnat R, Buchheit I, Bey P, Cordebar A, Jay N, et al. Efficacy and morbidity of arc-therapy radiosurgery for cerebral arteriovenous malformations: A comparison with the natural history. *Int J Radiat Oncol Biol Phys* 2004;58:1353-63.
- Brothers MF, Kaufmann JC, Fox AJ, Deveikis JP. n-Butyl 2-cyanoacrylate-substitute for IBCA in interventional neuroradiology: histopathologic and polymerization time studies. *AJNR Am J Neuroradiol* 1989;10:777-86.
- Brown RD Jr, Wiebers DO, Forbes GS. Unruptured intracranial aneurysms and arteriovenous malformations: Frequency of intracranial hemorrhage and relationship of lesions. *J Neurosurg* 1990;73:859-63.
- Brown RD Jr, Wiebers DO, Torner JC, O'Fallon WM. Frequency of intracranial hemorrhage as a presenting symptom and subtype analysis: A population-based study of intracranial vascular malformations in Olmsted County, Minnesota. *J Neurosurg* 1996;85:29-32.
- Buis DR, Lagerwaard FJ, Barkhof F, Dirven CM, Lycklama GJ, Meijer OW, et al. Stereotactic radiosurgery for brain AVMs: Role of interobserver variation in target definition on digital subtraction angiography. *Int J Radiat Oncol Biol Phys* 2005;62:246-52.
- Chang JH, Chang JW, Park YG, Chung SS. Factors related to complete occlusion of arteriovenous malformations after gamma knife radiosurgery. *J Neurosurg* 2000;93 Suppl 3:96-101.
- Choi JH, Mohr JP. Brain arteriovenous malformations in adults. *Lancet Neurol* 2005;4:299-308.
- Chung WY, Shiau CY, Wu HM, Liu KD, Guo WY, Wang LW, et al. Staged radiosurgery for extra-large cerebral arteriovenous malformations: Method, implementation, and results. *J Neurosurg* 2008;109 Suppl:S65-72.
- Cockroft KM, Thompson RC, Steinberg GK. Aneurysms and arteriovenous malformations. *Neurosurg Clin N Am* 1998;9:565-76.
- Colombo F, Pozza F, Chierago G, Casentini L, De Luca G, Francescon P. Linear accelerator radiosurgery of cerebral arteriovenous malformations: An update. *Neurosurgery* 1994;34:14-20; discussion 20-1.
- Crawford PM, West CR, Chadwick DW, Shaw MD. Arteriovenous malformations of the brain: Natural history in unoperated patients. *J Neurol Neurosurg Psychiatry* 1986;49:1-10.
- Crocio A. Arteriovenous malformations in the basal ganglia region: Gamma Knife radiosurgery as first choice treatment in selected cases. *J Neurosurg Sci* 2002;46:43-54.
- Cunha e Sa MJ, Stein BM, Solomon RA, McCormick PC. The treatment of associated intracranial aneurysms and arteriovenous malformations. *J Neurosurg* 1992;77:853-9.
- da Costa L, Wallace MC, Ter Brugge KG, O'Kelly C, Willinsky RA, Tymianski M. The natural history and predictive features of hemorrhage from brain arteriovenous malformations. *Stroke* 2009;40:100-5.
- Dawson RC 3rd, Tarr RV, Hecht ST, Jungreis CA, Lunsford LD, Coffey R, et al. Treatment of arteriovenous malformations of the brain with combined embolization and stereotactic radiosurgery: Results after 1 and 2 years. *AJNR Am J Neuroradiol* 1990;11:857-64.
- De Salles AF, Goetsch SJ. *Stereotactic Surgery and Radiosurgery*. Madison, WI: Medical Physics Publishing; 1993.
- DeMeritt JS, Pile-Spellman J, Mast H, Moohan N, Lu DC, Young WL, et al. Outcome analysis of preoperative embolization with N-butyl cyanoacrylate in cerebral arteriovenous malformations. *AJNR Am J Neuroradiol* 1995;16:1801-7.
- Deruty R, Pelissou-Guyotat I, Amat D, Mottolese C, Bascoulergue Y, Turjman F, et al. Complications after multidisciplinary treatment of cerebral arteriovenous malformations. *Acta Neurochir (Wien)* 1996;138:119-31.
- Douglas JG, Goodkin R. Treatment of arteriovenous malformations using Gamma Knife surgery: The experience at the University of Washington from 2000 to 2005. *J Neurosurg* 2008;109 Suppl:S51-6.
- Duong DH, Young WL, Vang MC, Sciacca RR, Mast H, Koennecke HC, et al. Feeding artery pressure and venous drainage pattern are primary determinants of hemorrhage from cerebral arteriovenous malformations. *Stroke* 1998;29:1167-76.

36. Ellis TL, Friedman WA, Bova FJ, Kubilis PS, Buatti JM. Analysis of treatment failure after radiosurgery for arteriovenous malformations. *J Neurosurg* 1998;89:104-10.
37. Engenhardt R, Wowra B, Debus J, Kimmig BN, Hover KH, Lorenz W, et al. The role of high-dose, single-fraction irradiation in small and large intracranial arteriovenous malformations. *Int J Radiat Oncol Biol Phys* 1994;30:521-9.
38. Ezura M, Takahashi A, Jokura H, Shirane R, Yoshimoto T. Endovascular treatment of aneurysms associated with cerebral arteriovenous malformations: Experiences after the introduction of Guglielmi detachable coils. *J Clin Neurosci* 2000;7 Suppl 1:S14-8.
39. Fleetwood IG, Marcellus ML, Levy RP, Marks MP, Steinberg GK. Deep arteriovenous malformations of the basal ganglia and thalamus: Natural history. *J Neurosurg* 2003;98:747-50.
40. Fleetwood IG, Steinberg GK. Arteriovenous malformations. *Lancet* 2002;359:863-73.
41. Flickinger JC. An integrated logistic formula for prediction of complications from radiosurgery. *Int J Radiat Oncol Biol Phys* 1989;17:879-85.
42. Flickinger JC, Kondziolka D, Maitz AH, Lunsford LD. An analysis of the dose-response for arteriovenous malformation radiosurgery and other factors affecting obliteration. *Radiother Oncol* 2002;63:347-54.
43. Foote KD, Friedman WA, Ellis TL, Bova FJ, Buatti JM, Meeks SL. Salvage retreatment after failure of radiosurgery in patients with arteriovenous malformations. *J Neurosurg* 2003;98:337-41.
44. Fournier D, Terbrugge K, Rodesch G, Lasjaunias P. Revascularization of brain arteriovenous malformations after embolization with bucrylate. *Neuroradiology* 1990;32:497-501.
45. Fournier D, Terbrugge KG, Willinsky R, Lasjaunias P, Montanera W. Endovascular treatment of intracerebral arteriovenous malformations: Experience in 49 cases. *J Neurosurg* 1991;75:228-33.
46. Fox AJ, Girvin JP, Vinuela F, Drake CG. Rolandic arteriovenous malformations: Improvement in limb function by IBC embolization. *AJNR Am J Neuroradiol* 1985;6:575-82.
47. Friedman WA, Bova FJ. Radiosurgery for arteriovenous malformations. *Neurol Res* 2011;33:803-19.
48. Friedman WA, Buatti JM, Bova FJ, Mendenhall WM. Linac Radiosurgery. A practical guide. New York: Springer-Verlag; 1997.
49. Frizzel RT, Fisher WS 3rd. Cure, morbidity, and mortality associated with embolization of brain arteriovenous malformations: A review of 1246 patients in 32 series over a 35-year period. *Neurosurgery* 1995;37:1031-9; discussion 1039-40.
50. Ganz JC. Gamma Knife Surgery. 2nd ed. New York: Springer-Verlag; 1997.
51. Gobin YP, Laurent A, Merienne L, Schlienger M, Aymard A, Houdart E, et al. Treatment of brain arteriovenous malformations by embolization and radiosurgery. *J Neurosurg* 1996;85:19-28.
52. Graf CJ, Perret GE, Torner JC. Bleeding from cerebral arteriovenous malformations as part of their natural history. *J Neurosurg* 1983;58:331-7.
53. Guo WY, Wikholm G, Karlsson B, Lindquist C, Svendsen P, Ericson K. Combined embolization and gamma knife radiosurgery for cerebral arteriovenous malformations. *Acta Radiol* 1993;34:600-6.
54. Ha JK, Choi SK, Kim TS, Rhee BA, Lim YJ. Multi-modality treatment for intracranial arteriovenous malformation associated with arterial aneurysm. *J Korean Neurosurg Soc* 2009;46:116-22.
55. Hadjipanayis CG, Levy EI, Niranjan A, Firlirk AD, Kondziolka D, Flickinger JC, et al. Stereotactic radiosurgery for motor cortex region arteriovenous malformations. *Neurosurgery* 2001;48:70-6; discussion 76-7.
56. Hamada J, Kai Y, Morioka M, Kazekawa K, Ishimaru Y, Iwata H, et al. A mixture of ethylene vinyl alcohol copolymer and ethanol yielding a nonadhesive liquid embolic agent to treat cerebral arteriovenous malformations: Initial clinical experience. *J Neurosurg* 2002;97:881-8.
57. Hartmann A, Mast H, Mohr JP, Koennecke HC, Osipov A, Pile-Spellman J, et al. Morbidity of intracranial hemorrhage in patients with cerebral arteriovenous malformation. *Stroke* 1998;29:931-4.
58. Hartmann A, Pile-Spellman J, Stapf C, Sciacca RR, Faulstich A, Mohr JP, et al. Risk of endovascular treatment of brain arteriovenous malformations. *Stroke* 2002;33:1816-20.
59. Hauck EF, Welch BG, White JA, Purdy PD, Pride LG, Samson D. Preoperative embolization of cerebral arteriovenous malformations with onyx. *AJNR Am J Neuroradiol* 2009;30:492-5.
60. Hauswald H, Milker-Zabel S, Sterzing F, Schlegel W, Debus J, Zabel-du Bois A. Repeated linac-based radiosurgery in high-grade cerebral arteriovenous malformations (AVM) Spetzler-Martin grade III to IV previously treated with radiosurgery. *Radiother Oncol* 2011;98:217-22.
61. Haw CS, terBrugge K, Willinsky R, Tomlinson G. Complications of embolization of arteriovenous malformations of the brain. *J Neurosurg* 2006;104:226-32.
62. Henkes H, Nahser HC, Berg-Dammer E, Weber W, Lange S, Kuhne D. Endovascular therapy of brain AVMs prior to radiosurgery. *Neurol Res* 1998;20:479-92.
63. Hodgson TJ, Kemeny AA, Gholkar A, Deasy N. Embolization of residual fistula following stereotactic radiosurgery in cerebral arteriovenous malformations. *AJNR Am J Neuroradiol* 2009;30:109-10.
64. Hofmeister C, Stapf C, Hartmann A, Sciacca RR, Mansmann U, terBrugge K, et al. Demographic, morphological, and clinical characteristics of 1289 patients with brain arteriovenous malformation. *Stroke* 2000;31:1307-10.
65. Jafar JJ, Davis AJ, Berenstein A, Choi IS, Kupersmith MJ. The effect of embolization with N-butyl cyanoacrylate prior to surgical resection of cerebral arteriovenous malformations. *J Neurosurg* 1993;78:60-9.
66. Jahan R, Murayama Y, Gobin YP, Duckwiler GR, Vinters HV, Vinuela F. Embolization of arteriovenous malformations with Onyx: Clinicopathological experience in 23 patients. *Neurosurgery* 2001;48:984-95; discussion 995-7.
67. Jayaraman MV, Marcellus ML, Hamilton S, Do HM, Campbell D, Chang SD, et al. Neurologic complications of arteriovenous malformation embolization using liquid embolic agents. *AJNR American J Neuroradiol* 2008;29:242-6.
68. Kader A, Young WL, Pile-Spellman J, Mast H, Sciacca RR, Mohr JP, et al. The influence of hemodynamic and anatomic factors on hemorrhage from cerebral arteriovenous malformations. *Neurosurgery* 1994;34:801-7; discussion 807-8.
69. Kano H, Kondziolka D, Flickinger JC, Park KJ, Parry PV, Yang HC, et al. Stereotactic radiosurgery for arteriovenous malformations, Part 6: Multistaged volumetric management of large arteriovenous malformations. *J Neurosurg* 2012;116:54-65.
70. Kano H, Kondziolka D, Flickinger JC, Yang HC, Flannery TJ, Niranjan A, et al. Stereotactic radiosurgery for arteriovenous malformations, Part 5: Management of brainstem arteriovenous malformations. *J Neurosurg* 2012;116:44-53.
71. Karlsson B, Jokura H, Yamamoto M, Soderman M, Lax I. Is repeated radiosurgery an alternative to staged radiosurgery for very large brain arteriovenous malformations? *J Neurosurg* 2007;107:740-4.
72. Karlsson B, Kihlstrom L, Lindquist C, Steiner L. Gamma knife surgery for previously irradiated arteriovenous malformations. *Neurosurgery* 1998;42:1-5; discussion 5-6.
73. Karlsson B, Lindquist C, Steiner L. Prediction of obliteration after gamma knife surgery for cerebral arteriovenous malformations. *Neurosurgery* 1997;40:425-30; discussion 430-1.
74. Kemeny AA, Dias PS, Forster DM. Results of stereotactic radiosurgery of arteriovenous malformations: An analysis of 52 cases. *J Neurol Neurosurg Psychiatry* 1989;52:554-8.
75. Khaw AV, Mohr JP, Sciacca RR, Schumacher HC, Hartmann A, Pile-Spellman J, et al. Association of infratentorial brain arteriovenous malformations with hemorrhage at initial presentation. *Stroke* 2004;35:660-3.
76. Kikuchi K, Kowada M, Sasajima H. Vascular malformations of the brain in hereditary hemorrhagic telangiectasia (Rendu-Osler-Weber disease). *Surg Neurol* 1994;41:374-80.
77. Kim EJ, Halim AX, Dowd CF, Lawton MT, Singh V, Bennett J, et al. The relationship of coexisting extracranial aneurysms to intracranial hemorrhage in patients harboring brain arteriovenous malformations. *Neurosurgery* 2004;54:1349-57; discussion 1357-8.
78. Kiran NA, Kale SS, Kasliwal MK, Vaishya S, Gupta A, Singh Sharma M, et al. Gamma knife radiosurgery for arteriovenous malformations of basal ganglia, thalamus and brainstem--A retrospective study comparing the results with that for AVMs at other intracranial locations. *Acta Neurochir (Wien)* 2009;151:1575-82.
79. Kjellberg RN, Hanamura T, Davis KR, Lyons SL, Adams RD. Bragg-peak proton-beam therapy for arteriovenous malformations of the brain. *N Engl J Med* 1983;309:269-74.
80. Kondziolka D, Nixon BJ, Lasjaunias P, Tucker WS, Terbrugge K, Spiegel SM. Cerebral arteriovenous malformations with associated arterial aneurysms: Hemodynamic and therapeutic considerations. *Can J Neurol Sci* 1988;15:130-4.
81. Krings T, Hans FJ, Geibprasert S, Terbrugge K. Partial "targeted" embolisation of brain arteriovenous malformations. *Eur Radiol* 2010;20:2723-31.

82. Kusske JA, Kelly WA. Embolization and reduction of the "steal" syndrome in cerebral arteriovenous malformations. *J Neurosurg* 1974;40:313-21.
83. Kwon Y, Jeon SR, Kim JH, Lee JK, Ra DS, Lee DJ, et al. Analysis of the causes of treatment failure in gamma knife radiosurgery for intracranial arteriovenous malformations. *J Neurosurg* 2000;93 Suppl 3:S104-6.
84. Ledezma CJ, Hoh BL, Carter BS, Pryor JC, Putman CM, Ogilvy CS. Complications of cerebral arteriovenous malformation embolization: Multivariate analysis of predictive factors. *Neurosurgery* 2006;58:602-11; discussion 602-11.
85. Leksell L. The stereotactic method and radiosurgery of the brain. *Acta Chir Scand* 1951;102:316-9.
86. Lemme-Plaghos L, Schonholz C, Willis R. Combination of embolization and radiosurgery in the treatment of arteriovenous malformations. In: Steiner L, editor. *Radiosurgery: Baseline and trends*. New York: Raven Press; 1992. p. 195.
87. Lindqvist M, Karlsson B, Guo WY, Kihlstrom L, Lippitz B, Yamamoto M. Angiographic long-term follow-up data for arteriovenous malformations previously proven to be obliterated after gamma knife radiosurgery. *Neurosurgery* 2000;46:803-8; discussion 809-10.
88. Lindqvist M, Steiner L, Blomgren H, Arndt J, Berggren BM. Stereotactic radiation therapy of intracranial arteriovenous malformations. *Acta Radiol* 1986;369:610-3.
89. Liscak R, Vladyka V, Simonova G, Urgosik D, Novotny J Jr, Janouskova L, et al. Arteriovenous malformations after Leksell gamma knife radiosurgery: Rate of obliteration and complications. *Neurosurgery* 2007;60:1005-14; discussion 1015-6.
90. Locksley HB. Natural history of subarachnoid hemorrhage, intracranial aneurysms and arteriovenous malformations. Based on 6368 cases in the cooperative study. *J Neurosurg* 1966;25:219-39.
91. Luessenhop AJ, Mujica PH. Embolization of segments of the circle of Willis and adjacent branches for management of certain inoperable cerebral arteriovenous malformations. *J Neurosurg* 1981;54:573-82.
92. Luessenhop AJ, Spence WT. Artificial embolization of cerebral arteries. Report of use in a case of arteriovenous malformation. *J Am Med Assoc* 1960;172:1153-5.
93. Lundqvist C, Wikholm G, Svendsen P. Embolization of cerebral arteriovenous malformations: Part II--Aspects of complications and late outcome. *Neurosurgery* 1996;39:460-7; discussion 467-9.
94. Lunsford LD, Kondziolka D, Flickinger JC, Bissonette DJ, Jungreis CA, Maitz AH, et al. Stereotactic radiosurgery for arteriovenous malformations of the brain. *J Neurosurg* 1991;75:512-24.
95. Lv X, Wu Z, Jiang C, Li Y, Yang X, Zhang Y, et al. Complication risk of endovascular embolization for cerebral arteriovenous malformation. *Eur J Radiol* 2011;80:776-9.
96. Maesawa S, Flickinger JC, Kondziolka D, Lunsford LD. Repeated radiosurgery for incompletely obliterated arteriovenous malformations. *J Neurosurg* 2000;92:961-70.
97. Mansmann U, Meisel J, Brock M, Rodesch G, Alvarez H, Lasjaunias P. Factors associated with intracranial hemorrhage in cases of cerebral arteriovenous malformation. *Neurosurgery* 2000;46:272-9; discussion 279-81.
98. Marks MP, Lane B, Steinberg GK, Chang PJ. Hemorrhage in intracerebral arteriovenous malformations: Angiographic determinants. *Radiology* 1990;176:807-13.
99. Martin NA, Khanna R, Doberstein C, Bentson J. Therapeutic embolization of arteriovenous malformations: The case for and against. *Clin Neurosurg* 2000;46:295-318.
100. Maruyama K, Shin M, Tago M, Kurita H, Kawamoto S, Morita A, et al. Gamma knife surgery for arteriovenous malformations involving the corpus callosum. *J Neurosurg* 2005;102 Suppl:S49-52.
101. Massager N, Regis J, Kondziolka D, Njee T, Levivier M. Gamma knife radiosurgery for brainstem arteriovenous malformations: Preliminary results. *J Neurosurg* 2000;93 Suppl 3:S102-3.
102. Massoud TF, Ji C, Guglielmi G, Vinuela F. Endovascular treatment of arteriovenous malformations with selective intranidal occlusion by detachable platinum electrodes: Technical feasibility in a swine model. *AJNR Am J Neuroradiol* 1996;17:1459-66.
103. Mathis JA, Barr JD, Horton JA, Jungreis CA, Lunsford LD, Kondziolka DS, et al. The efficacy of particulate embolization combined with stereotactic radiosurgery for treatment of large arteriovenous malformations of the brain. *AJNR Am J Neuroradiol* 1995;16:299-306.
104. Meisel HJ, Mansmann U, Alvarez H, Rodesch G, Brock M, Lasjaunias P. Cerebral arteriovenous malformations and associated aneurysms: Analysis of 305 cases from a series of 662 patients. *Neurosurgery* 2000;46:793-800; discussion 800-2.
105. Meisel HJ, Mansmann U, Alvarez H, Rodesch G, Brock M, Lasjaunias P. Effect of partial targeted N-butyl-cyanoacrylate embolization in brain AVM. *Acta Neurochir (Wien)* 2002;144:879-87; discussion 888.
106. Miyachi S, Negoro M, Okamoto T, Kobayashi T, Kida Y, Tanaka T, et al. Embolisation of cerebral arteriovenous malformations to assure successful subsequent radiosurgery. *J Clin Neurosci* 2000;7 Suppl 1:S82-5.
107. Miyasaka Y, Yada K, Ohwada T, Kitahara T, Kurata A, Irikura K. An analysis of the venous drainage system as a factor in hemorrhage from arteriovenous malformations. *J Neurosurg* 1992;76:239-43.
108. Mohr JP, Moskowitz AJ, Stapf C, Hartmann A, Lord K, Marshall SM, et al. The ARUBA trial: Current status, future hopes. *Stroke* 2010;41:e537-40.
109. Natarajan SK, Born D, Ghodke B, Britz GW, Sekhar LN. Histopathological changes in brain arteriovenous malformations after embolization using Onyx or N-butyl cyanoacrylate. Laboratory investigation. *J Neurosurg* 2009;111:105-13.
110. Ogilvy CS, Stieg PE, Awad I, Brown RD Jr, Kondziolka D, Rosenwasser R, et al. AHA Scientific Statement: Recommendations for the management of intracranial arteriovenous malformations: A statement for healthcare professionals from a special writing group of the Stroke Council, American Stroke Association. *Stroke* 2001;32:1458-71.
111. Ondra SL, Troupp H, George ED, Schwab K. The natural history of symptomatic arteriovenous malformations of the brain: A 24-year follow-up assessment. *J Neurosurg* 1990;73:387-91.
112. Orio P, Stelzer KJ, Goodkin R, Douglas JG. Treatment of arteriovenous malformations with linear accelerator-based radiosurgery compared with Gamma Knife surgery. *J Neurosurg* 2006;105 Suppl:S58-63.
113. Perret G, Nishioka H. Report on the cooperative study of intracranial aneurysms and subarachnoid hemorrhage. Section VI. Arteriovenous malformations. An analysis of 545 cases of cranio-cerebral arteriovenous malformations and fistulae reported to the cooperative study. *J Neurosurg* 1966;25:467-90.
114. Piotin M, Ross IB, Weill A, Kothimbakam R, Moret J. Intracranial arterial aneurysms associated with arteriovenous malformations: Endovascular treatment. *Radiology* 2001;220:506-13.
115. Pollock BE, Flickinger JC, Lunsford LD, Bissonette DJ, Kondziolka D. Hemorrhage risk after stereotactic radiosurgery of cerebral arteriovenous malformations. *Neurosurgery* 1996;38:652-9; discussion 659-61.
116. Pollock BE, Flickinger JC, Lunsford LD, Maitz A, Kondziolka D. Factors associated with successful arteriovenous malformation radiosurgery. *Neurosurgery* 1998;42:1239-44; discussion 1244-7.
117. Pollock BE, Gorman DA, Brown PD. Radiosurgery for arteriovenous malformations of the basal ganglia, thalamus, and brainstem. *J Neurosurg* 2004;100:210-4.
118. Pollock BE, Kline RW, Stafford SL, Foote RL, Schomberg PJ. The rationale and technique of staged-volume arteriovenous malformation radiosurgery. *Int J Radiat Oncol Biol Phys* 2000;48:817-24.
119. Pollock BE, Kondziolka D, Lunsford LD, Bissonette D, Flickinger JC. Repeat stereotactic radiosurgery of arteriovenous malformations: Factors associated with incomplete obliteration. *Neurosurgery* 1996;38:318-24.
120. Pollock BE, Lunsford LD, Kondziolka D, Bissonette DJ, Flickinger JC. Stereotactic radiosurgery for postgeniculate visual pathway arteriovenous malformations. *J Neurosurg* 1996;84:437-41.
121. Rao VR, Mandalam KR, Gupta AK, Kumar S, Joseph S. Dissolution of isobutyl 2-cyanoacrylate on long-term follow-up. *AJNR Am J Neuroradiol* 1989;10:135-41.
122. Redekop G, TerBrugge K, Montanera W, Willinsky R. Arterial aneurysms associated with cerebral arteriovenous malformations: Classification, incidence, and risk of hemorrhage. *J Neurosurg* 1998;89:539-46.
123. Riina HA, Gobin YP. Grading and surgical planning for intracranial arteriovenous malformations. *Neurosurg Focus* 2001;11:e3.
124. Sasaki T, Kurita H, Saito I, Kawamoto S, Nemoto S, Terahara A, et al. Arteriovenous malformations in the basal ganglia and thalamus: management and results in 101 cases. *J Neurosurg* 1998;88:285-92.
125. Schlienger M, Atlan D, Lefkopoulos D, Merienne L, Touboul E, Missir O, et al. Linac radiosurgery for cerebral arteriovenous malformations: results in 169 patients. *Int J Radiat Oncol Biol Phys* 2000;46:1135-42.

126. Schlienger M, Nataf F, Lefkopoulos D, Mammari H, Missir O, Meder JF, et al. Repeat linear accelerator radiosurgery for cerebral arteriovenous malformations. *Int J Radiat Oncol Biol Phys* 2003;56:529-36.
127. Schmutz F, McAuliffe W, Anderson DM, Elliott JP, Eskridge JM, Winn HR. Embolization of cerebral arteriovenous malformations with silk: Histopathologic changes and hemorrhagic complications. *AJNR Am J Neuroradiol* 1997;18:1233-7.
128. Schwartz M. Stereotactic radiosurgery: Comparing different technologies. *CMAJ* 1998;158:625-8.
129. Shin M, Kawamoto S, Kurita H, Tago M, Sasaki T, Morita A, et al. Retrospective analysis of a 10-year experience of stereotactic radio surgery for arteriovenous malformations in children and adolescents. *J Neurosurg* 2002;97:779-84.
130. Shin M, Maruyama K, Kurita H, Kawamoto S, Tago M, Terahara A, et al. Analysis of nidus obliteration rates after gamma knife surgery for arteriovenous malformations based on long-term follow-up data: The University of Tokyo experience. *J Neurosurg* 2004;101:18-24.
131. Shtraus N, Schifter D, Corn BW, Maimon S, Alani S, Frolov V, et al. Radiosurgical treatment of AVM following embolization with Onyx: Possible dosage error in treatment planning can be averted. *J Neurooncol* 2010;98:271-6.
132. Sirin S, Kondziolka D, Niranjan A, Flickinger JC, Maitz AH, Lunsford LD. Prospective staged volume radiosurgery for large arteriovenous malformations: Indications and outcomes in otherwise untreatable patients. *Neurosurgery* 2006;58:17-27; discussion 17-27.
133. Sirin S, Kondziolka D, Niranjan A, Flickinger JC, Maitz AH, Lunsford LD. Prospective staged volume radiosurgery for large arteriovenous malformations: Indications and outcomes in otherwise untreatable patients. *Neurosurgery* 2008;62 Suppl 2:S744-54.
134. Soderman M, Andersson T, Karlsson B, Wallace MC, Edner G. Management of patients with brain arteriovenous malformations. *Eur J Radiol* 2003;46:195-205.
135. Souhami L, Olivier A, Podgorsak EB, Pla M, Pike GB. Radiosurgery of cerebral arteriovenous malformations with the dynamic stereotactic irradiation. *Int J Radiat Oncol Biol Phys* 1990;19:775-82.
136. Spetzler RF, Martin NA, Carter LP, Flom RA, Raudzens PA, Wilkinson E. Surgical management of large AVM's by staged embolization and operative excision. *J Neurosurg* 1987;67:17-28.
137. Spetzler RF, Wilson CB, Weinstein P, Mehdorn M, Townsend J, Telles D. Normal perfusion pressure breakthrough theory. *Clin Neurosurg* 1978;25:651-72.
138. Stapf C, Mast H, Sciacca RR, Choi JH, Khaw AV, Connolly ES, et al. Predictors of hemorrhage in patients with untreated brain arteriovenous malformation. *Neurology* 2006;66:1350-5.
139. Stapf C, Mohr JP, Pile-Spellman J, Sciacca RR, Hartmann A, Schumacher HC, et al. Concurrent arterial aneurysms in brain arteriovenous malformations with haemorrhagic presentation. *J Neurol Neurosurg Psychiatry* 2002;73:294-8.
140. Steiner L, Leksell L, Greitz T, Forster DM, Backlund EO. Stereotactic radiosurgery for cerebral arteriovenous malformations. Report of a case. *Acta Chir Scand* 1972;138:459-64.
141. Steiner L, Lindquist C, Adler JR, Torner JC, Alves W, Steiner M. Clinical outcome of radiosurgery for cerebral arteriovenous malformations. *J Neurosurg* 1992;77:1-8.
142. Stiefel MF, Al-Okaili R, Weigle JB, Hurst RW. De novo aneurysm formation and regression after brain arteriovenous malformation embolization: Case report. *Surg Neurol* 2007;67:99-101; discussion 101.
143. Sure U, Butz N, Siegel AM, Mennel HD, Bien S, Bertalanffy H. Treatment-induced neoangiogenesis in cerebral arteriovenous malformations. *Clin Neurol Neurosurg* 2001;103:29-32.
144. Taylor CL, Dutton K, Rappard G, Pride GL, Replogle R, Purdy PD, et al. Complications of preoperative embolization of cerebral arteriovenous malformations. *J Neurosurg* 2004;100:810-2.
145. Turjman F, Massoud TF, Vinuela F, Sayre JW, Guglielmi G, Duckwiler G. Aneurysms related to cerebral arteriovenous malformations: Superselective angiographic assessment in 58 patients. *AJNR Am J Neuroradiol* 1994;15:1601-5.
146. Valavanis A, Yasargil MG. The endovascular treatment of brain arteriovenous malformations. *Adv Tech Stand Neurosurg* 1998;24:131-214.
147. Van Beijnum J, van der Worp HB, Buis DR, Al-Shahi Salman R, Kappelle LJ, Rinkel GJ, et al. Treatment of brain arteriovenous malformations: A systematic review and meta-analysis. *JAMA* 2011;306:2011-9.
148. Veznedaroglu E, Andrews DW, Benitez RP, Downes MB, Werner-Wasik M, Rosenstock J, et al. Fractionated stereotactic radiotherapy for the treatment of large arteriovenous malformations with or without previous partial embolization. *Neurosurgery* 2008;62 Suppl 2:S763-75.
149. Vinters HV, Lundie MJ, Kaufmann JC. Long-term pathological follow-up of cerebral arteriovenous malformations treated by embolization with bucrylate. *N Engl J Med* 1986;314:477-83.
150. Vinuela F, Dion JE, Duckwiler G, Martin NA, Lylyk P, Fox A, et al. Combined endovascular embolization and surgery in the management of cerebral arteriovenous malformations: Experience with 101 cases. *J Neurosurg* 1991;75:856-64.
151. Vinuela F, Duckwiler G, Guglielmi G. Contribution of interventional neuroradiology in the therapeutic management of brain arteriovenous malformations. *J Stroke Cerebrovasc Dis* 1997;6:268-71.
152. Waltimo O. The change in size of intracranial arteriovenous malformations. *J Neurol Sci* 1973;19:21-7.
153. Weber W, Kis B, Siekmann R, Jans P, Laumer R, Kuhne D. Preoperative embolization of intracranial arteriovenous malformations with Onyx. *Neurosurgery* 2007;61:244-52; discussion 252-4.
154. Wikholm G, Lundqvist C, Svendsen P. Embolization of cerebral arteriovenous malformations: Part I--Technique, morphology, and complications. *Neurosurgery* 1996;39:448-57; discussion 457-9.
155. Yahara K, Inagawa T, Tokuda Y, Takechi A, Shibukawa M, Inokuchi F, et al. [A case of multiple cerebral arteriovenous malformations treated by gamma knife radiosurgery]. *No Shinkei Geka* 1995;23:1121-5.
156. Yamamoto M, Jimbo M, Hara M, Saito I, Mori K. Gamma knife radiosurgery for arteriovenous malformations: Long-term follow-up results focusing on complications occurring more than 5 years after irradiation. *Neurosurgery* 1996;38:906-14.
157. Yamamoto M, Jimbo M, Ide M, Tanaka N, Lindquist C, Steiner L. Long-term follow-up of radiosurgically treated arteriovenous malformations in children: Report of nine cases. *Surg Neurol* 1992;38:95-100.
158. Yamamoto M, Jimbo M, Kobayashi M, Toyoda C, Ide M, Tanaka N, et al. Long-term results of radiosurgery for arteriovenous malformation: Neurodiagnostic imaging and histological studies of angiographically confirmed nidus obliteration. *Surg Neurol* 1992;37:219-30.
159. Yashar P, Amar AP, Giannotta SL, Yu C, Pagnini PG, Liu CY, et al. Cerebral arteriovenous malformations: Issues of the interplay between stereotactic radiosurgery and endovascular surgical therapy. *World Neurosurg* 2011;75:638-47.
160. Yen CP, Steiner L. Gamma knife surgery for brainstem arteriovenous malformations. *World Neurosurg* 2011;76:87-95; discussion 57-8.
161. Yu SC, Chan MS, Lam JM, Tam PH, Poon WS. Complete obliteration of intracranial arteriovenous malformation with endovascular cyanoacrylate embolization: Initial success and rate of permanent cure. *AJNR Am J Neuroradiol* 2004;25:1139-43.
162. Yuki I, Kim RH, Duckwiler G, Jahan R, Tateshima S, Gonzalez N, et al. Treatment of brain arteriovenous malformations with high-flow arteriovenous fistulas: Risk and complications associated with endovascular embolization in multimodality treatment. *Clinical article. J Neurosurg* 2010;113:715-22.
163. Zabel-du Bois A, Milker-Zabel S, Huber P, Schlegel W, Debus J. Risk of hemorrhage and obliteration rates of LINAC-based radiosurgery for cerebral arteriovenous malformations treated after prior partial embolization. *Int J Radiat Oncol Biol Phys* 2007;68:999-1003.
164. Zipfel GJ, Bradshaw P, Bova FJ, Friedman WA. Do the morphological characteristics of arteriovenous malformations affect the results of radiosurgery? *J Neurosurg* 2004;101:393-401.

Disclaimer: The authors of this paper have received no outside funding, and have nothing to disclose.