

# Pattern sensitivity: a missed part of the diagnosis

Hanan M El Shakankiry<sup>1</sup>  
Ann A Abdel Kader<sup>2</sup>

<sup>1</sup>Department of Pediatrics, King Fahd University Hospital–Al Dammam University, Al Khobar, Kingdom of Saudi Arabia; <sup>2</sup>Department of Clinical Neurophysiology, Kasr Aini Hospitals–Cairo University, Cairo, Egypt

**Rationale:** Pattern sensitivity can be diagnosed by presenting a series of visual patterns to the subject in the electroencephalography (EEG) laboratory; however, testing for pattern sensitivity is not routinely done during EEG recording. This work aimed to highlight the incidence of pattern sensitivity among patients referred for routine EEG recording during a 1-year period, identifying the cause of referral, diagnosis, and the characteristics of pattern-sensitive patients.

**Methods:** All patients aged 4 years and older who were referred for routine EEG during a 12-month period and had no motor or visual impairment were enrolled in the study. Intermittent photic stimulation and pattern sensitivity were tested for each case. Pattern sensitivity was tested by scanning three different rhythmically moving patterns at reading distance with the patient seated in an illuminated room. A pattern evoking a paroxysmal response was reintroduced after exposure to a blank white card to confirm the findings.

**Results:** Two hundred twenty-eight patients were studied; twelve patients (5.26%) had pattern sensitivity and their ages ranged from 5 to 12 years. Eight of these patients (66.7%) were referred for seizure disorders, two were referred with the diagnosis of migraine, one with headache and poor scholastic performance and one with recurrent attacks of dizziness for investigation. Seven of the twelve patients (58.3%) had a previous EEG done without testing for pattern sensitivity. Five patients (41.6%) had positive family history for epilepsy, three (25%) for migraine, and two (16.6%) for migraine and epilepsy. Two patients (16.6%) had pattern sensitivity without photosensitivity. Pattern stimulation provoked epileptiform discharges in eight patients (66.6%), focal discharges in one, and unilateral build-up of posterior discharge in three.

**Conclusion:** Diagnosis of pattern sensitivity is often missed as it is not routinely tested for during EEG recording. The result of the study challenges the concept of a consistent association between photosensitivity and pattern sensitivity; it also raises questions about the incidence of pattern sensitivity among children who do not suffer from epilepsy and in particular those with migraine, headache and scholastic difficulties. Further studies are therefore needed to clarify the phenotypic spectrum of this EEG trait.

**Keywords:** reflex epilepsy, pattern sensitivity, migraine, headache

## Introduction

Pattern-sensitive epilepsy is a form of reflex epilepsy in which seizures are precipitated by visual patterns, typically stripes.<sup>1</sup> Because of the close association between sensitivity to intermittent photic stimulation and sensitivity to visual pattern stimulation, pattern-sensitive epilepsy has been commonly regarded as an extension of photosensitive epilepsy.<sup>2,3</sup> However, the diagnosis of pattern sensitivity in a photosensitive patient is of clinical importance as it shows the additional range of visual stimuli to which the patient is vulnerable. Seizures in pattern-sensitive patients may be induced

Correspondence: Hanan M El Shakankiry  
Pediatric Neurology Division-Pediatric  
Department, PO Box 40284, Al Khobar,  
31952 Kingdom of Saudi Arabia  
Email hshakankiry@hotmail.com

while viewing environmental patterns such as window screens, tablecloths, ceiling tiles, escalator steps, striped wallpaper, and clothing.<sup>1,4</sup> Absences, often associated with eye blinking, facial contractions, and myoclonic jerks of the upper extremities, are the seizure types typically evoked by the pattern exposure.<sup>3,5</sup> However, generalized tonic clonic seizures and less frequently partial seizures may occur; the latter may be confused with migraine.<sup>1</sup>

Pattern sensitivity can be diagnosed by presenting a series of visual patterns to the subject in the electroencephalography (EEG) laboratory; however, testing for pattern sensitivity is not routinely done during EEG recording.

This work aimed to highlight the incidence of pattern sensitivity among patients referred for routine EEG recording during a 1-year period, identifying the cause of referral, diagnosis, and the characteristics of pattern-sensitive patients.

## Patients and methods

All patients aged 4 years and older who were referred for routine EEG during a 12-month period, who had no motor or visual impairment, and whose parents agreed to be enrolled in the study were included. EEG was recorded using a 21-channel Nicolet EEG (Nicolet, Madison, WI) and a Stellate HARMONIE Digital EEG (Stellate Systems, Montreal, Canada). Intermittent photic stimulation and pattern sensitivity were tested for each case. Pattern sensitivity was tested by scanning three different rhythmically moving patterns (Figure 1) at reading distance with the patient seated in an illuminated room. A pattern evoking a paroxysmal response was reintroduced after exposure to a blank white card to confirm the findings.

## Results

Two hundred twenty-eight patients were studied. Their ages ranged from 4 to 12 years old. Twelve patients (5.26%) had pattern sensitivity. Their ages ranged from 5 to 12 years (median 8.9 years). Seven were female and five were male,

with a female-to-male ratio of 1.4:1. Eight patients (66.7%) were referred for seizure disorders: two had idiopathic photosensitive epilepsy, two had juvenile myoclonic epilepsy (JME), three had childhood absence epilepsy, and one had eyelid myoclonia with absences. Two were referred with the diagnosis of migraine, one with headache and poor scholastic performance, and one with recurrent attacks of dizziness for investigation (Figures 2 and 3). Seven of the twelve patients (58.3%) had a previous EEG done without testing for pattern sensitivity. Two patients (16.6%) had pattern sensitivity without photosensitivity.

Eight patients (66.6%) were born to consanguineous parents: five (41.6%) had positive family history for epilepsy, three (25%) for migraine, and two (16.6%) for migraine and epilepsy. Two of the three patients with childhood absence epilepsy were twins (Figure 4).

Epileptiform discharges provoked by pattern stimulation were generalized in eight patients (66.6%), focal (parietooccipital) in one, and unilateral build-up of posterior discharge that was then generalized in three patients (Figures 5 and 6).

Three patients had ictal clinical phenomena during pattern stimulation, a brief absence with eye blinking in two, and facial twitching in one. Seven patients reported subjective symptoms such as nausea, dizziness, articulation difficulty, and headache during pattern stimulation.

## Discussion

About 5% of patients with epilepsy are photosensitive. The prevalence is believed to be greater in the young.<sup>6</sup> Most of these patients are also pattern sensitive.<sup>7-9</sup> During the 12-month period of the study, 228 patients aged between 4 and 12 years had EEG recordings performed; 12 (5.26%) had pattern sensitivity. Their ages ranged from 5 to 12 years (median 8.9 years). Seven were female and five were male, with a female-to-male ratio of 1.4:1. Girls are reported to be nearly twice as likely to have pattern sensitivity as boys,<sup>9</sup>


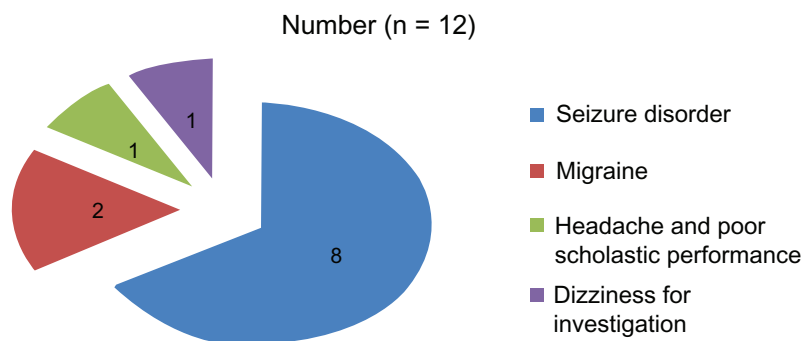


Figure 1 The three different patterns used.



**Figure 2** Cause of referral of patients found to have pattern sensitivity.

however, Brinciotti et al<sup>10</sup> noted a preponderance of males among patients with pattern sensitivity.

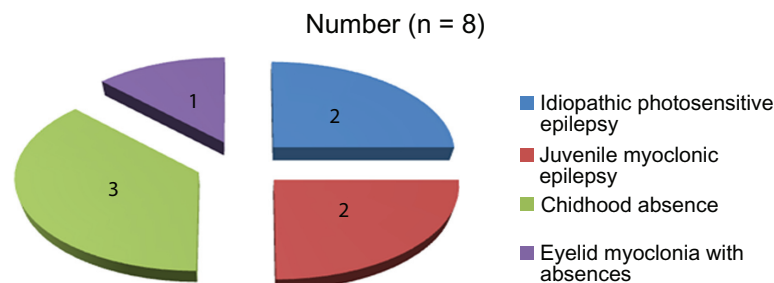
Pattern sensitivity in isolation, without photosensitivity, was believed to be almost nonexistent;<sup>11</sup> however, two of our patients (16.6%) had pattern sensitivity without photosensitivity. Our findings agree with Harding and Harding<sup>12</sup> and Radhakrishnan et al<sup>4</sup> who reported that 10% to 20% of people sensitive to pattern stimuli may be unresponsive to the conventional frequency range of intermittent photic stimulation.

Seven of the twelve patients with pattern sensitivity (58.3%) had a previous EEG done without testing for pattern sensitivity. Eight (66.7%) were referred for seizure disorders.

Photosensitivity is known to be associated with syndromes of idiopathic generalized, partial or cryptogenic epilepsy and some progressive myoclonic encephalopathies.<sup>13</sup> However, there are no reports about the incidence of pattern sensitivity in these syndromes. Two of our patients with seizure disorders who were also found to have pattern sensitivity were diagnosed as having idiopathic photosensitive epilepsy, two had JME, three had childhood absence epilepsy, and one had eyelid myoclonia with absences. In pure photosensitive epilepsy, visually induced seizures are provoked by intermittent photic stimulation, pattern, or both. Photosensitivity rate in JME ranges from 30% to 54%

and is more than 92% in eyelid myoclonia with absences.<sup>13–16</sup> However, photosensitivity is considered an unfavorable EEG feature in childhood absence epilepsy, being associated with an unremitting course.<sup>17,18</sup>

Four (33.3%) of our patients who were found to be pattern sensitive were referred for EEG because of a complaint other than seizure disorders: two were referred with the diagnosis of migraine, one with headache and poor scholastic performance, and one with recurrent attacks of dizziness for investigation. Rolandic spike and wave discharges were reported to occur more in children with migraine; focal epileptiform discharges were reported in 9% of children with migraine, significantly higher than in the normal population (1.9%),<sup>19</sup> and striking EEG patterns were described in specific subtypes of migraine, particularly migraine with aura, hemiplegic, and acute confusional migraine. The brain regions most often involved in the published EEG samples in different types of migraine include the posterior temporal, parietal, and occipital regions.<sup>20–23</sup> Nevertheless, EEG is not considered to be indicated in part of the routine evaluation of headaches unless seizures are suspected.<sup>24</sup> Moreover, Wilkins<sup>25</sup> indicated that patients with migraines may show aversion and perceptual distortion when viewing epileptogenic patterns, but this was attributed to the patterns inducing a strong neurological response, which was not considered an epileptogenic response. It is important,



**Figure 3** Epileptic syndrome among patients found to have pattern sensitivity.

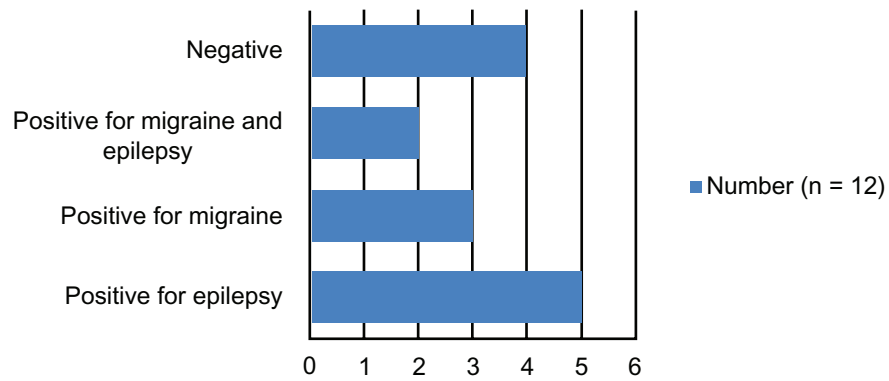
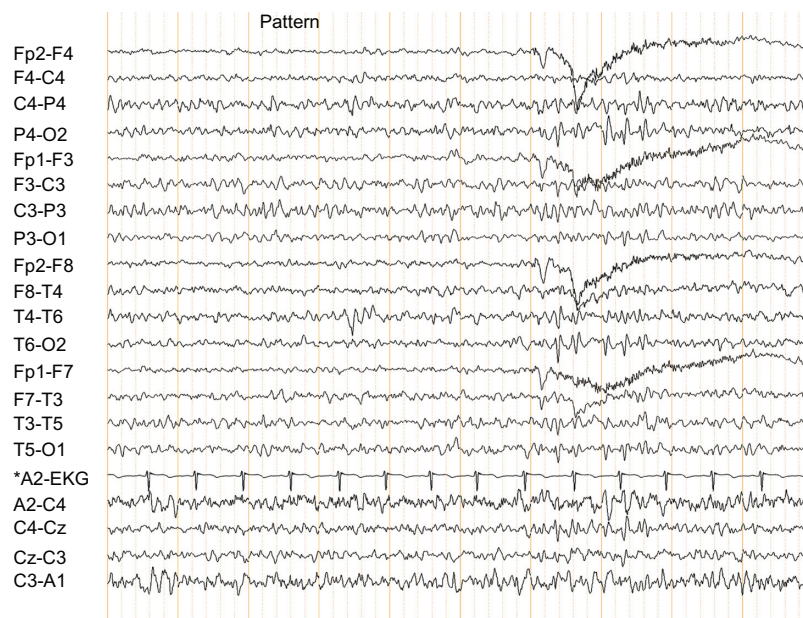


Figure 4 Family history of epilepsy and/or migraine among patients found to have pattern sensitivity.

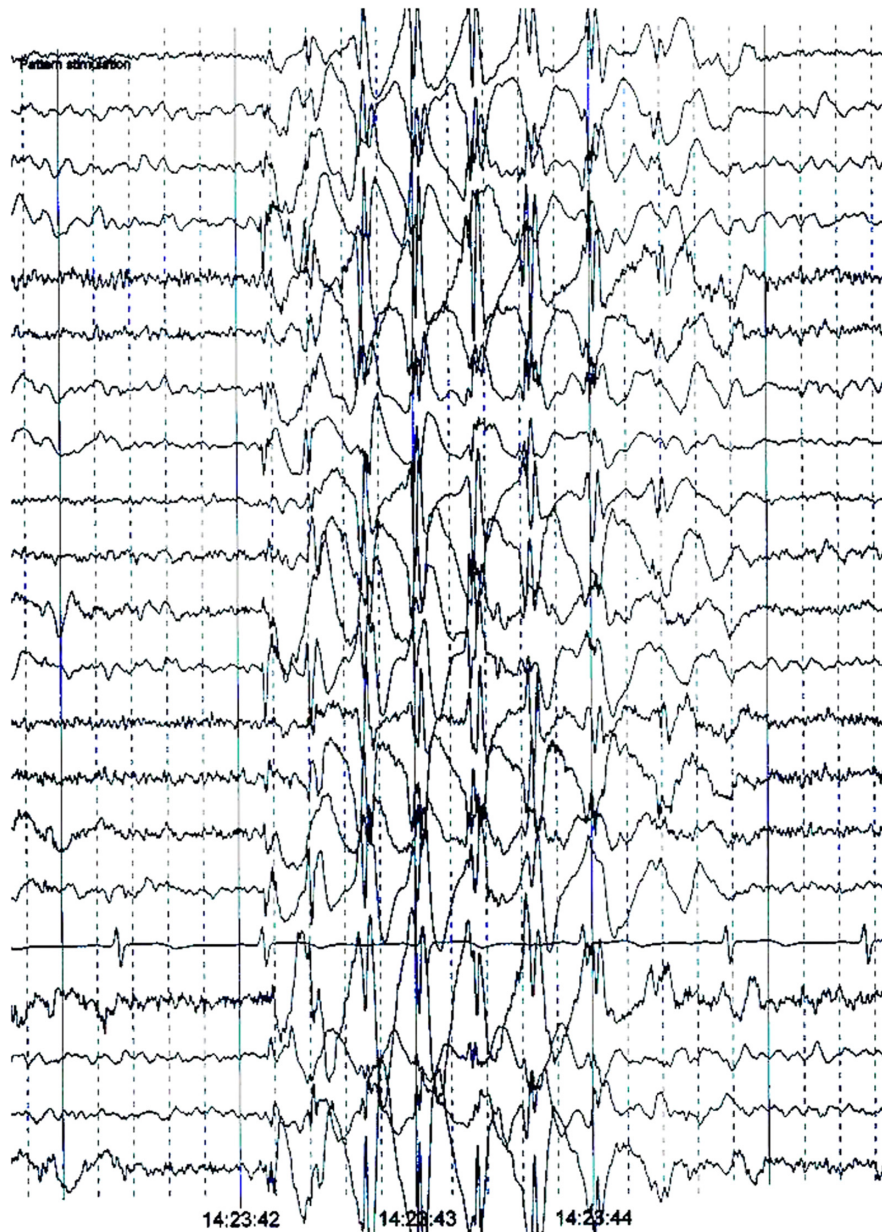

Figure 5 Pattern-induced generalized epileptiform discharge.



**Figure 6** Pattern-induced focal epileptiform discharge.

though, to emphasize that migraines and epilepsy are two highly associated disorders. Channel function alteration was suggested to be the link between both disorders. This hypothesis is supported by the proven efficacy of certain prophylactic drugs, including calcium-channel blockers as well as anticonvulsants such as sodium valproate, gabapentin, and topiramate, which alter the properties of ion channels and therefore the cell excitability.<sup>26</sup> It was also reported that patients with idiopathic epilepsy syndromes (epilepsy with rolandic or occipital paroxysms, or absence epilepsy) may concomitantly suffer from migraines<sup>27–31</sup> and that 4% to 10% of patients with migraines suffer from epileptic seizures.<sup>26,32,33</sup> Headache may even be the only or most predominant clinical manifestation of epileptic seizures, although this is reported as a relatively rare situation.<sup>23</sup> Furthermore, it is worth mentioning that children may not be able to give a full description of their symptoms and to articulate their complaints. Consequently, the criteria needed for the diagnosis of migraine, headache, or epilepsy may be difficult to fulfill with precision in the pediatric age group.

Three of our patients had ictal phenomena during pattern stimulation, a brief absence with eye blinking in two, and with facial twitching in one. Seven patients reported subjective symptoms such as nausea, dizziness, articulation difficulty, and headache during pattern stimulation. The poor scholastic performance and headache that one of our pattern-sensitive patients suffered from, and the attacks of dizziness described by the other patient may be attributed to

the electrophysiological response induced when a child with pattern sensitivity is exposed to the epileptogenic pattern. A significant number of patients were reported to complain of subjective symptoms during photoparoxysmal responses on intermittent photic stimulation, such as dizziness, orbital pain, nausea, fear and unpleasant sensations. Nevertheless, these responses were not considered to be ictal phenomena.<sup>25,34</sup>

Photosensitivity is genetically determined.<sup>35–37</sup> Likewise, genetic factors have been believed to play a role in the pathogenesis of pattern sensitivity. Eight of our patients with pattern sensitivity (66.6%) were born to consanguineous parents; five (41.6%) had positive family history for epilepsy, three (25%) for migraine, and two (16.6%) for migraine and epilepsy. Two of the three patients with childhood absence epilepsy were monozygotic twins. Two of four patients with pattern sensitivity reported by Chatrian et al<sup>38</sup> were brothers. Brinciotti et al<sup>39</sup> also reported two families in which five members had pattern-sensitive epilepsy (three in one family and two in the other). In a group of children with visually induced seizures described by Brinciotti et al,<sup>40</sup> two girls with both photosensitivity and pattern sensitivity were monozygotic twins.

Epileptiform discharges provoked by pattern stimulation were generalized in two-thirds of our patients with pattern sensitivity, were focal (parietooccipital) in one (8.3%), and in the form of unilateral build-up of posterior discharge that was then generalized in three (25%). Radhakrishnan et al<sup>4</sup> reported similar findings: paroxysmal epileptiform discharges

elicited with pattern stimulation were generalized in two-thirds of their patients and were restricted to the posterior head region in one-third.

## Conclusion

Diagnosis of pattern sensitivity is often missed as it is not routinely tested for during EEG recording. The result of the study again challenges the concept about the consistent association between photosensitivity and pattern sensitivity. It also raises questions about the incidence of pattern sensitivity among children who do not suffer from epilepsy and in particular those with migraine, headache, dyslexia, and scholastic difficulties. Further studies are therefore needed to clarify the phenotypic spectrum of this EEG trait.

## Disclosure

The authors report no conflicts of interest in this work.

## References

- Zifkin BG, Kasteleijn-Nolst Trenité D. Reflex epilepsy and reflex seizures of the visual system: a clinical review. *Epileptic Disord*. 2000;2(3):129–136.
- Kasteleijn-Nolst Trenité DG. Photosensitivity in epilepsy. Electrophysiological and clinical correlates. *Acta Neurol Scand Suppl*. 1989;125:3–149.
- Binnie CD, Wilkins AJ. Visually induced seizures not caused by flicker (intermittent light stimulation). *Adv Neurol*. 1998;75:123–138.
- Radhakrishnan K, St Louis EK, Johnson JA, McClelland RL, Westmoreland BF, Klass DW. Pattern-sensitive epilepsy: electroclinical characteristics, natural history, and delineation of the epileptic syndrome. *Epilepsia*. 2005;46(1):48–58.
- Klass DW. Pattern activation of seizures. In: Lüders HO, Noachtar S, editors. *Epileptic Seizures: Pathophysiology and Clinical Semiology*. New York, NY: Churchill Livingstone; 2000:598–608.
- Quirk JA, Fish DR, Smith SJ, Sander JW, Shorvon SD, Allen PJ. First seizures associated with playing electronic screen games: a community-based study in Great Britain. *Ann Neurol*. 1995;37(6):733–737.
- Stefánsson SB, Darby CE, Wilkins AJ, et al. Television epilepsy and pattern sensitivity. *Br Med J*. 1977;2(6079):88–90.
- Wilkins AJ, Darby CE, Binnie CD. Neurophysiological aspects of pattern-sensitive epilepsy. *Brain*. 1979;102(1):1–25.
- Harding GFA, Jeavons PM. *Photosensitive Epilepsy*. Cambridge, MA: Cambridge University Press; 1994.
- Brincioti M, Matricardi M, Pelliccia A, Trasatti G. Pattern sensitivity and photosensitivity in epileptic children with visually induced seizures. *Epilepsia*. 1994;35(4):842–849.
- Binnie CD. Simple reflex epilepsies. In: Engel J Jr, Pedley TA, editors. *Epilepsy: A Comprehensive Textbook*. Philadelphia, PA: Lippincott-Raven; 1998:2489–2505.
- Harding GF, Harding PF. Televised material and photosensitive epilepsy. *Epilepsia*. 1999;40 Suppl 4:65–69.
- Covanis A. Photosensitivity in idiopathic generalized epilepsies. *Epilepsia*. 2005;46 Suppl 9:67–72.
- Wolf P, Goosses R. Relation of photosensitivity to epileptic syndromes. *J Neurol Neurosurg Psychiatry*. 1986;49(12):1386–1391.
- Binnie CD, Jeavons PM. Photosensitive epilepsies. In: Roger J, Bureau M, Dravet CH, et al, editors. *Epileptic Syndromes in Infancy, Childhood and Adolescence*, 2nd ed. London, UK: John Libbey and Co, Ltd; 1992:299–305.
- Panayiotopoulos CP, Obeid T, Tahan AR. Juvenile myoclonic epilepsy: a 5-year prospective study. *Epilepsia*. 1994;35(2):285–296.
- Covanis A, Skiadas K, Loli N, Lada C, Theodorou V. Absence epilepsy: early prognostic signs. *Seizure*. 1992;1(4):281–289.
- Baykan B, Matur Z, Gürses C, Aykutlu E, Gökyiğit A. Typical absence seizures triggered by photosensitivity. *Epilepsia*. 2005;46(1):159–163.
- Kinast M, Lueders H, Rothner AD, Erenberg G. Benign focal epileptiform discharges in childhood migraine (BFEDC). *Neurology*. 1982;32(11):1309–1311.
- De Romanis F, Buzzi MG, Cerbo R, Feliciani M, Assenza S, Agnoli A. Migraine and epilepsy with infantile onset and electroencephalographic findings of occipital spike-wave complexes. *Headache*. 1991;31(6):378–383.
- Terzano MG, Parrino L, Pietrini V, Gailli L. Migraine-epilepsy syndrome: intercalated seizures in benign occipital epilepsy. In: Andermann F, Beaumanoir A, Mira L, et al, editors. *Occipital Seizures and Epilepsies in Children*. London, UK: John Libbey and Co, Ltd; 1993:93–99.
- Gronseth GS, Greenberg MK. The utility of the electroencephalogram in the evaluation of patients presenting with headache: a review of the literature. *Neurology*. 1995;45(7):1263–1267.
- Silberstein SD, Lipton RB. Headache and epilepsy. In: Ettinger AB, Devinsky O, editors. *Managing Epilepsy and Co-existing Disorders*. Boston, MA: Butterworth-Heinemann; 2002:239–254.
- Report of the Quality Standards Subcommittee of the American Academy of Neurology. Practice parameter: the electroencephalogram in the evaluation of headache (summary statement). *Neurology*. 1995;45(7):1411–1413.
- Wilkins AJ. *Visual Stress*. Oxford, UK: Oxford University Press; 1995.
- Piccinelli P, Borgatti R, Nicoli F, et al. Relationship between migraine and epilepsy in pediatric age. *Headache*. 2006;46(3):413–421.
- Septien L, Pelletier JL, Brunotte F, Giroud M, Dumas R. Migraine in patients with history of centro-temporal epilepsy in childhood: a Hm-PAO SPECT study. *Cephalalgia*. 1991;11(6):281–284.
- Panayiotopoulos CP. Visual phenomena and headache in occipital epilepsy: A review, a systematic study and differentiation from migraine. *Epileptic Disord*. 1999;1(4):205–216.
- Panayiotopoulos CP. Elementary visual hallucinations, blindness, and headache in idiopathic occipital epilepsy: differentiation from migraine. *J Neurol Neurosurg Psychiatry*. 1999;66(4):536–540.
- Andermann F. Migraine and the benign partial epilepsies of childhood: evidence for an association. *Epileptic Disord*. 2000;2 Suppl 1: S37–S39.
- El Shakankiry HM, El Halik MS. Epilepsy or migraine? An issue still to be resolved [abstract 2.091]. *Epilepsia*. 2008;49(s7):214.
- Ninck B. Migraine and epilepsy. *Eur Neurol*. 1970;3(3):168–178.
- Prensky AL. Migraine and migrainous variants in pediatric patients. *Pediatr Clin North Am*. 1976;23(3):461–471.
- Wilkins AJ. Visual sensitivity and hyperexcitability in epilepsy and migraine. In: Andermann F, Lugaresi E, editors. *Migraine and Epilepsy*. Boston, MA: Butterworths; 1987:339–365.
- Doose H, Waltz S. Photosensitivity – genetics and clinical significance. *Neuropediatrics*. 1993;24(5):249–255.
- Waltz S, Stephani U. Inheritance of photosensitivity. *Neuropediatrics*. 2000;31(2):82–85.
- Stephani U, Tauer U, Koeleman B, Pinto D, Neubauer BA, Lindhout D. Genetics of photosensitivity (photoparoxysmal response): a review. *Epilepsia*. 2004;45 Suppl 1:19–23.
- Chatrjian GE, Lettich E, Miller LH, Green JR, Kupfer C. Pattern-sensitive epilepsy. 2. Clinical changes, tests of responsiveness and motor output, alterations of evoked potentials and therapeutic measures. *Epilepsia*. 1970;11(2):151–162.
- Brincioti M, Trasatti G, Pelliccia A, Matricardi M. Pattern-sensitive epilepsy: genetic aspects in two families. *Epilepsia*. 1992;33(1):88–92.
- Brincioti M, Matricardi M, Pelliccia A, Trasatti G. Pattern sensitivity and photosensitivity in epileptic children with visually induced seizures. *Epilepsia*. 1994;35(4):842–849.

### Neuropsychiatric Disease and Treatment

Dovepress

#### Publish your work in this journal

Neuropsychiatric Disease and Treatment is an international, peer-reviewed journal of clinical therapeutics and pharmacology focusing on concise rapid reporting of clinical or pre-clinical studies on a range of neuropsychiatric and neurological disorders. This journal is indexed on PubMed Central, the 'PsycINFO' database and CAS.

The manuscript management system is completely online and includes a very quick and fair peer-review system, which is all easy to use. Visit <http://www.dovepress.com/testimonials.php> to read real quotes from published authors.

Submit your manuscript here: <http://www.dovepress.com/neuropsychiatric-disease-and-treatment-journal>