

Treatment of Atopic Dermatitis Associated with *Malassezia sympodialis* by Green Tea Extracts Bath Therapy: A Pilot Study

Hyun Kyu Kim¹, Hui Kyoung Chang², Seok Yun Baek², Jin Oh Chung², Chan Su Rha², So Young Kim³, Beom Joon Kim^{1*} and Myeong Nam Kim¹

¹Department of Dermatology, Chung-Ang University College of Medicine, Seoul 156-756, Korea

²AmorePacific R&D Center, Yongin 446-729, Korea

³Department of Convergence Medicine and Pharmaceutical Biosciences, Chung-Ang University College of Medicine, Seoul 156-756, Korea

(Received April 10, 2012. Revised April 11, 2012. Accepted April 12, 2012)

Multiple treatment modalities, including topical and systemic corticosteroid and phototherapy, have been used in treatment of patients with atopic dermatitis. However, long-term corticosteroid therapy may have various adverse effects. The purpose of this study was to investigate the therapeutic efficacy and safety of bath therapy using green tea extracts for treatment of patients with atopic dermatitis. A total of four patients with atopic dermatitis were enrolled in this study. A *Malassezia* multiplex detection kit was used in performance of multiplex PCR on clinical isolates, which confirmed *Malassezia sympodialis*. Subjects underwent treatment with bath therapy using green tea extracts three times per wk for a period of 4 wk. Assessment using the scoring atopic dermatitis (SCORAD) index, the visual analogue scale for pruritus, and transepidermal water loss was performed weekly. Laboratory tests were performed before and after treatment. All patients showed marked improvement on the mean SCORAD and visual analogue scale, and a significant decrease in the mean values of serum eosinophil counts was observed after treatment. Bath therapy with green tea extract is an effective, safe, and non-steroidal therapy for treatment of patients with atopic dermatitis associated with *Malassezia sympodialis*.

KEYWORDS : Atopic dermatitis, Bath therapy, Catechin, Green tea extract

Introduction

Atopic dermatitis (AD) is a chronic, relapsing, inflammatory skin disease, with a genetic and environmental background. Its pathogenesis is complex; in most cases, the dermatitis fades during childhood; however, the course of the disease is unpredictable [1]. Multiple treatment modalities, including topical and systemic corticosteroid, and phototherapy at various wavelengths, have been used in treatment of patients with AD. However, long-term corticosteroid therapy may have various adverse effects. Many research studies have been conducted in an effort to find alternatives to steroids. Various biological activities of catechins, the main constituent of green tea, including antimutagenic, antibacterial, antioxidant, and antitumor properties, have been reported [2-4]. In this study, we assessed the effectiveness of bath therapy with green tea extracts in treatment of patients with AD associated with *Malassezia sympodialis* infection.

Materials and Methods

Preparation of green tea extracts. Purified green tea extract was provided by AmorePacific Corporation (Korea). Green tea leaves were taken from Jeju Island. Green leaves were steamed soon after being nipped off, which led to inactivation of tea enzymes. After primary grinding, the leaves were divided into juice and solid content. The juice was distilled for 4 hr, then, after filtration, we obtained the final product; 5% solution was prepared for clinical challenge.

Clinical experiment. We recruited four patients aged 5~9 years who had been diagnosed with extrinsic AD according to previously published definitions [5]. This clinical study was approved by the Institutional Review Board of Chung-Ang University Hospital. Prior to enrollment, patients were informed of the study procedures, as well as possible risks and benefits, and written consent was

*Corresponding author <E-mail : beomjoon@unitel.co.kr>

© This is an Open Access article distributed under the terms of the Creative Commons Attribution Non-Commercial License (<http://creativecommons.org/licenses/by-nc/3.0/>) which permits unrestricted non-commercial use, distribution, and reproduction in any medium, provided the original work is properly cited.

obtained from each patient. Patients were instructed to avoid the use of any other therapeutic agents during the course of treatment. The following subjects were excluded: patients who had undergone treatment with systemic corticosteroid or topical agents, including corticosteroid, calcineurin inhibitor, and any type of phototherapy or photosensitizing drugs during the three months prior to enrollment. First, a swab was rubbed over the eczematous skin lesion, and skin samples were then obtained. Yeasts were cultured in Leeming-Notman medium [6, 7]. A *Malassezia* multiplex detection kit was used for performance of multiplex PCR on clinical isolates [8]. The isolates were identified as *M. sympodialis*.

For bath therapy treatment using green tea extracts, subjects bathed in 700 mL of green tea extract solution mixed with 150 L of filtered tap water three times per wk for a period of 4 wk. Duration of bath treatment was 30 min, with a water temperature of 37°C. For evaluation of the therapeutic efficacy, assessment of the scoring atopic dermatitis (SCORAD) score and the visual analogue scale (VAS) for pruritus was performed every wk. For investigation of changes in skin barrier function during bath therapy, measurement of skin hydration and transepidermal water loss (TEWL) was performed using a Corneometer CM825 (Courage Khazaka GmbH, Cologne, Germany) and a Tewameter TM300 (Courage Khazaka GmbH), respectively. Photographs using identical camera settings, lighting, and positioning were taken during each visit.

Evaluation and comparison of photographs were performed by two independent dermatologists using the quartile grading scale: 1, minimal improvement or steady state (0~25%); 2, moderate improvement (26~50%); 3, marked improvement (51~75%); and 4, excellent improvement (76~100%). In addition, laboratory tests, including serum eosinophil counts, eosinophil cationic protein (ECP) levels, and immunoglobulin E (IgE) were performed twice, at baseline and week 3.

Statistical analysis. Data are presented as the mean and standard deviation. The Wilcoxon signed rank test was used in performance of statistical analysis. SPSS software (SPSS Inc., Chicago, IL, USA) was used in performance of all analyses. A $p < 0.05$ was considered statistically significant.

Results

Clinical evaluation. Excellent improvement was noted in one patient, and marked improvement was achieved in three patients (Fig. 1). A decrease was observed in the mean SCORAD value, from 47.05 ± 7.94 at baseline to 23.4 ± 3.83 at week 4, a reduction of 50.3% (Fig. 2). None of the patients reported a lack of change in or worsening of their AD. A decrease was observed in the mean VAS score, from 8.83 ± 0.99 at baseline, to 2.13 ± 0.94 at week 4 (Fig. 3). However, changes of SCORAD value and VAS scores were not statistically significant.

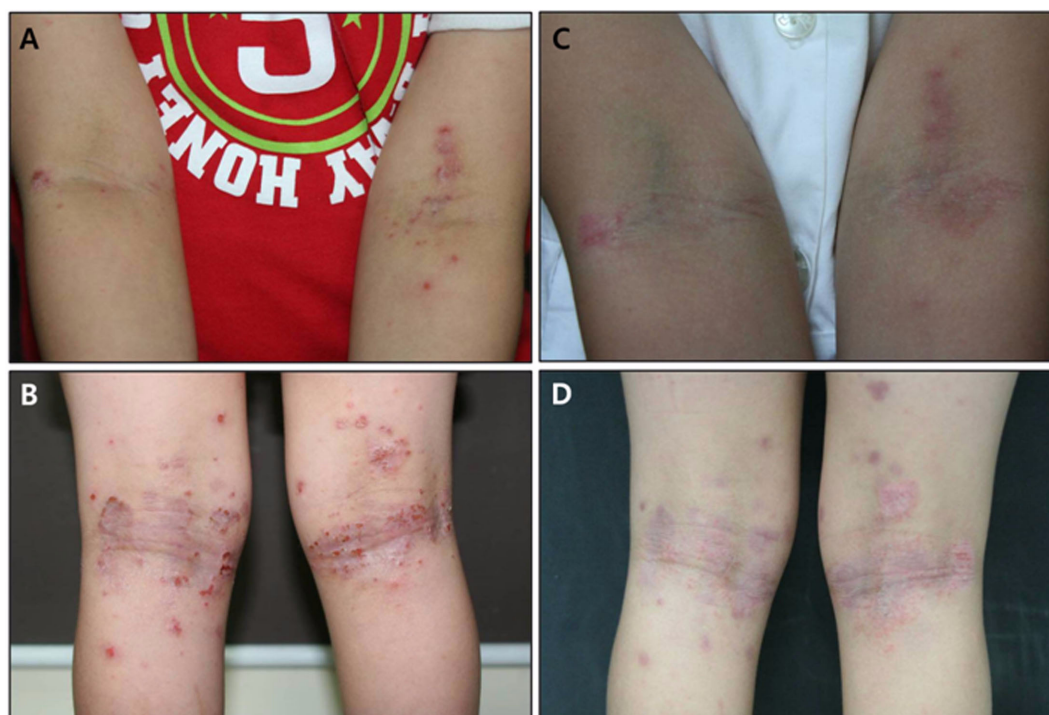


Fig. 1. A, B, Erythematous plaques and papules with excoriation and lichenification were observed on both popliteal and cubital areas before treatment; C, D, Clinical improvement of atopic dermatitis was observed after 12 bath treatments with green tea extracts.

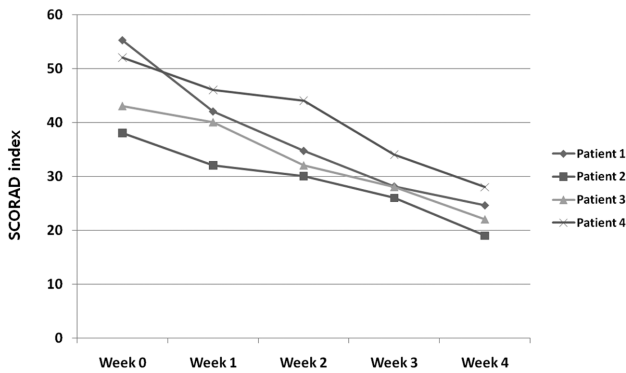


Fig. 2. Changes in scoring atopic dermatitis (SCORAD) index values.

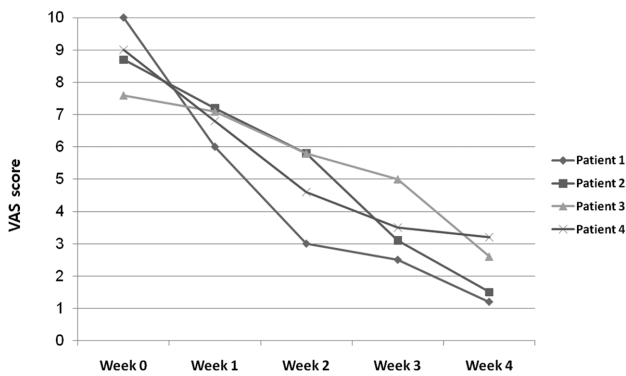


Fig. 3. Changes in visual analogue scale (VAS) scores of patients.

Assessment of skin barrier function. No significant changes in skin hydration were observed. A decrease in TEWL was observed in two patients; however, the change was not statistically significant (data not shown).

Laboratory examination. All subjects underwent laboratory tests. Compared with baseline values, the mean values of serum eosinophil counts showed a decrease at week 4 (Fig. 4). However, no significant changes in

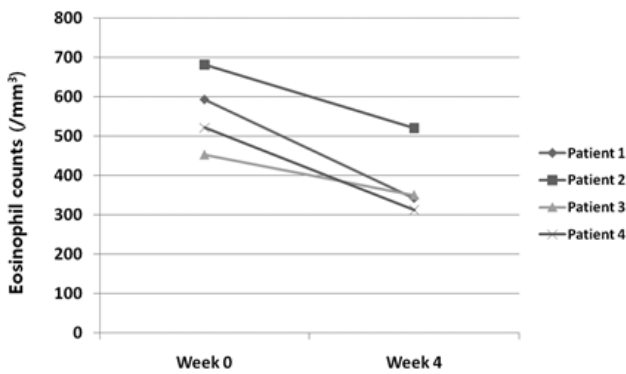


Fig. 4. Variation of total eosinophil counts of patients at baseline and week 4.

serum ECP, IgE levels were observed over the entire study period.

Post-treatment mycological examination. After 12 sessions of bath therapy, mycological examination of swab samples from skin lesions using a *Malassezia* multiplex detection kit showed no identified *Malassezia* species.

Safety and adverse effects. In general, bath therapy was well tolerated by all patients. No serious adverse effects were reported during the study.

Discussion

Topical corticosteroid is a baseline therapy for treatment of patients with AD. When applied properly, it is a very useful tool for treatment of patients with AD, with few adverse effects; however, steroid abuse can cause adverse effects, including skin atrophy, epidermal thinning, striae distensae, and perioral dermatitis. Recently, many studies for treatment of patients with AD using non-steroidal topical agents from natural sources have been conducted. Green tea, which is widely consumed as a beverage, consists of unprocessed dried young leaves of *Camellia sinensis*, also known as *Thea sinensis* L. In recent years, green tea has been studied widely for evaluation of its beneficial effects in treatment and prevention of human disease. Green tea constituents, particularly catechins, exhibit a wide range of pharmacological effects, including anticarcinogenic activity and prevention of cardiovascular diseases [9]. Green tea catechins exhibit antithrombotic activity, which might be due to an antiplatelet effect rather than anticoagulation [10]. Staphylococcal superantigens (SsAgs) have gained attention as one of the factors aggravating AD and several potential mechanisms of AD aggravation by SsAgs have been reported. The inhibitory effect of the green tea catechin extract, Polyphenon, and epigallocatechin gallate (EGCg) on staphylococcal enterotoxin B (SEB) and its mechanisms of action, as well as the possible therapeutic benefits of tea catechin for patients with AD, have also been reported [11].

Findings from studies of the antibacterial effects of tea extracts have demonstrated that Gram-positive bacteria are more sensitive to tea extracts than Gram-negative bacteria; in addition, it has been suggested that negatively charged EGCg acts by binding to the positively charged lipids of the membrane, resulting in damage to the lipid bilayer. Antifungal effects have also been explained by similar mechanisms [11].

Although *Malassezia* yeasts are a part of the normal microflora, under certain conditions, they can cause superficial skin infections, such as pityriasis versicolor, seborrheic dermatitis, and *Malassezia* folliculitis. Lipophilic yeasts have been under consideration as major opportunistic

pathogens for a very long time. Most of the yeasts have demonstrated an absolute requirement for long fatty acid chains and specific procedures are required for their isolation, conservation, and identification [12]. The causal role of *Malassezia* in seborrheic dermatitis and dandruff has become clear, however, the role of specific species is still being defined. In patients with AD and psoriasis, evidence for a causal relationship remains less defined. However, literature studies linking all of these disorders with *Malassezia* yeasts have been reported [13]. *Malassezia* yeasts appear to be a particularly important factor in development of AD, especially in cases where the disease is localized to the head and neck. *Malassezia* yeasts have been cultured from 83% of adult patients with this form of AD [14]. The yeasts are also frequently colonized from control subjects; therefore, it has been hypothesized that they function as allergens, rather than as infectious agents, in patients who are susceptible [15]. Recent results of molecular work have also elucidated the structure of some allergens derived from *Malassezia* yeasts [16, 17]. In the present study, *M. sympodialis* was the species most commonly isolated from AD patients using the *Malassezia* multiplex detection kit.

Use of gentle cleansers incorporating synthetic detergents with minimal irritation potential and moisturizers containing a variety of humectants, occlusive agents, and lipids have been used in management of xerosis and AD [18]. Some studies addressing skin moisturization and barrier repair therapy have reported on the adjunctive clinical benefit in treatment of active AD, and a few trials, although more limited, have reported prolonged remission between flares, as well as reduction in usage of topical corticosteroid therapy. In the present study, patients with AD associated with *M. sympodialis* were treated with bath therapy using green tea extract. Results of this study showed correlation with clinical severity, as measured by the SCORAD index. A decrease in SCORAD index and total eosinophil counts, as well as a marked decrease in VAS score for pruritus, was observed after treatment. Not only *Malassezia*, but also bacteria, particularly *Staphylococcus aureus*, and other yeasts and filamentous fungi, such as *Candida* species and *Trichophyton rubrum*, have shown correlation with AD [19, 20]. However, *S. aureus* infection is more likely to be a secondary cause of AD, whereas *Malassezia* yeasts are recognized as the primary causative agent for AD [21]. Based on the clinical improvement demonstrated by our patients, we suggest the antibacterial and anti-inflammatory effects of catechin against SEB and antifungal effect against *Malassezia* and its mechanisms, and we discuss the potential of bath therapy with green tea extract as a candidate therapy for treatment of patients with AD.

In the present study, treatment was well tolerated and no serious side effects were noted. This open and single treatment arm study is limited by the absence of

randomization and a placebo control. Absence of direct comparisons with other bathing therapies and conventional treatment modalities is a significant limitation. Nevertheless, our results can be used in design of future randomized trials of bath therapy using green tea extract.

In conclusion, bath therapy with green tea extract is an effective, safe, and non-steroidal therapy for treatment of patients with AD associated with *M. sympodialis*. However, the effects of catechin against SsAgs and the antifungal effect of green tea extract are still not clear. Further studies of the antimicrobial effect against yeasts, using a larger sample size, are necessary; in addition, we discuss the potential of bath therapy with green tea extract as a candidate therapy for treatment of patients with AD.

Acknowledgements

This research was financially supported by the Ministry of Knowledge Economy (MKE) and the Korea Institute for Advancement of Technology (KIAT) through the Research and Development for Regional Industry.

References

1. James W, Berger T, Elston DM. Andrews' diseases of the skin: clinical dermatology. 10th ed. Philadelphia: W. B. Saunders; 2006. p. 789.
2. Hara Y, Matsuzaki T, Suzuki T. Angiotensin I converting enzyme inhibiting activity of tea components. J Agric Chem Soc Jpn 1987;61:803-8.
3. Matsuzaki T, Hara Y. Antioxidative activity of tea leaf catechins. J Agric Chem Soc Jpn 1985;59:129-34.
4. Xu Y, Ho CT, Amin SG, Han C, Chung FL. Inhibition of tobacco-specific nitrosamine-induced lung tumorigenesis in A/J mice by green tea and its major polyphenol as antioxidants. Cancer Res 1992;52:3875-9.
5. Majoie IM, Oldhoff JM, van Weelden H, Laaper-Ertmann M, Bousema MT, Sigurdsson V, Knol EF, Bruijnzeel-Koomen CA, de Bruin-Weller MS. Narrowband ultraviolet B and medium-dose ultraviolet A1 are equally effective in the treatment of moderate to severe atopic dermatitis. J Am Acad Dermatol 2009;60:77-84.
6. Kindo AJ, Sophia SK, Kalyani J, Anandan S. Identification of *Malassezia* species. Indian J Med Microbiol 2004;22:179-81.
7. Guého E, Midgley G, Guillot J. The genus *Malassezia* with description of four new species. Antonie van Leeuwenhoek 1996;69:337-55.
8. Kim HM, Lim YY, Park EJ, Chun YJ, Kim MN, Kim BJ, Lee DH. The development and evaluation of multiplex PCR technique for identification of *Malassezia* yeast. Korean J Med Mycol 2010;15:51-60.
9. Yun YP, Kang WS, Lee MY. The antithrombotic effects of green tea catechins. J Food Hyg Saf 1996;11:77-82.
10. Kang WS, Chung KH, Chung JH, Lee JY, Park JB, Zhang YH, Yoo HS, Yun YP. Antiplatelet activity of green tea catechins is mediated by inhibition of cytoplasmic calcium increase. J Cardiovasc Pharmacol 2001;38:875-84.

11. Hisano M, Yamaguchi K, Inoue Y, Ikeda Y, Iijima M, Adachi M, Shimamura T. Inhibitory effect of catechin against the superantigen staphylococcal enterotoxin B (SEB). *Arch Dermatol Res* 2003;295:183-9.
12. Ahn KJ. Taxonomy of the genus *Malassezia*. *Korean J Med Mycol* 1998;3:81-8.
13. Gupta AK, Batra R, Bluhm R, Boekhout T, Dawson TL Jr. Skin diseases associated with *Malassezia* species. *J Am Acad Dermatol* 2004;51:785-98.
14. Broberg A, Faergemann J, Johansson S, Johansson SG, Strannegård IL, Svejgaard E. *Pityrosporum ovale* and atopic dermatitis in children and young adults. *Acta Derm Venereol* 1992;72:187-92.
15. Jensen-Jarolim E, Poulsen LK, With H, Kieffer M, Ottevanger V, Stahl Skov P. Atopic dermatitis of the face, scalp, and neck: type I reaction to the yeast *Pityrosporum ovale*? *J Allergy Clin Immunol* 1992;89(1 Pt 1):44-51
16. Schmidt M, Zargari A, Holt P, Lindbom L, Hellman U, Whitley P, van der Ploeg I, Härfast B, Scheynius A. The complete cDNA sequence and expression of the first major allergenic protein of *Malassezia furfur*, Mal f 1. *Eur J Biochem* 1997;246:181-5.
17. Yasueda H, Hashida-Okado T, Saito A, Uchida K, Kuroda M, Onishi Y, Takahashi K, Yamaguchi H, Takesako K, Akiyama K. Identification and cloning of two novel allergens from the lipophilic yeast, *Malassezia furfur*. *Biochem Biophys Res Commun* 1998;248:240-4.
18. Del Rosso JQ. Understanding skin cleansers and moisturizers: the correlation of formulation science with the art of clinical use. *Cosmet Dermatol* 2003;16:19-31.
19. Abeck D, Mempel M. *Staphylococcus aureus* colonization in atopic dermatitis and its therapeutic implications. *Br J Dermatol* 1998;139(Suppl 53):13-6.
20. Klein PA, Clark RA, Nicol NH. Acute infection with *Trichophyton rubrum* associated with flares of atopic dermatitis. *Cutis* 1999;63:171-2.
21. Skov L, Baadsgaard O. The potential role of *Staphylococcus aureus* superantigens in atopic eczema. *J Eur Acad Dermatol Venereol* 1996;7(Suppl 1):S8-11.