

Published in final edited form as:

Brain Lang. 2012 September ; 122(3): 190–198. doi:10.1016/j.bandl.2012.04.005.

The neural basis of syntactic deficits in primary progressive aphasia

Stephen M. Wilson^{a,b,c,*}, Sebastiano Galantucci^{c,d}, Maria Carmela Tartaglia^c, and Maria Luisa Gorno-Tempini^c

^aDepartment of Speech, Language and Hearing Sciences, University of Arizona

^bDepartment of Neurology, University of Arizona

^cMemory and Aging Center, Department of Neurology, University of California, San Francisco

^dNeuroimaging Research Unit, Institute of Experimental Neurology, Division of Neuroscience, Scientific Institute and University Hospital San Raffaele, Milan, Italy

Abstract

Patients with primary progressive aphasia (PPA) vary considerably in terms of which brain regions are impacted, as well as in the extent to which syntactic processing is impaired. Here we review the literature on the neural basis of syntactic deficits in PPA. Structural and functional imaging studies have most consistently associated syntactic deficits with damage to left inferior frontal cortex. Posterior perisylvian regions have been implicated in some studies. Damage to the superior longitudinal fasciculus, including its arcuate component, has been linked with syntactic deficits, even after gray matter atrophy is taken into account. These findings suggest that syntactic processing depends on left frontal and posterior perisylvian regions, as well as intact connectivity between them. In contrast, anterior temporal regions, and the ventral tracts that link frontal and temporal language regions, appear to be less important for syntax, since they are damaged in many PPA patients with spared syntactic processing.

Keywords

syntax; primary progressive aphasia; voxel-based morphometry; functional MRI; diffusion tensor imaging

1. Introduction

In primary progressive aphasia (PPA), degeneration of dominant hemisphere language regions leads to progressive language deficits, with relative sparing of other cognitive functions (Mesulam, 1982, 2001; Gorno-Tempini et al., 2011). There is considerable variability in which specific regions are affected. Consequently, individuals with PPA vary greatly in the extent to which different aspects of language, such as syntactic processing, are impacted. The aim of this paper is to provide a brief review of the literature on the neural basis of syntactic deficits in PPA.

© 2012 Elsevier Inc. All rights reserved.

*Corresponding author. smwilson@u.arizona.edu.

Publisher's Disclaimer: This is a PDF file of an unedited manuscript that has been accepted for publication. As a service to our customers we are providing this early version of the manuscript. The manuscript will undergo copyediting, typesetting, and review of the resulting proof before it is published in its final citable form. Please note that during the production process errors may be discovered which could affect the content, and all legal disclaimers that apply to the journal pertain.

There are three widely recognized variants of PPA: non-fluent, semantic and logopenic (Gorno-Tempini et al., 2004, 2011). Non-fluent PPA is characterized by agrammatism and/or apraxia of speech (Grossman et al., 1996; Hodges & Patterson, 1996). In this review, we use the term *non-fluent* to refer to a clinically defined variant (Gorno-Tempini et al., 2011); it is important to note that the traditional concept of fluency is multifactorial and does not always provide a good basis for classifying PPA patients (Thompson et al., 2012a; Wilson et al., 2010b). In semantic PPA (for which diagnostic criteria mostly overlap with those for semantic dementia; Neary et al., 1998), loss of lexical and semantic knowledge is the most salient feature (Hodges et al., 1992; Snowden et al., 1989; Warrington, 1975). Logopenic PPA is characterized by phonological and word-finding problems (Henry & Gorno-Tempini, 2011; Gorno-Tempini et al., 2004, 2008). Each variant has a characteristic pattern of atrophy (Fig. 1) (Gorno-Tempini et al., 2004), and each variant is associated with different likelihoods of underlying pathologies (Davies et al., 2005; Josephs et al., 2008; Mesulam et al., 2008; Snowden et al., 2007, 2011; see Grossman et al., 2010 and Henry et al., 2012 for review).

In this review, we begin with a brief discussion of syntactic deficits and how they are typically assessed in PPA. Then we examine the nature and extent of syntactic deficits, if any, along with structural and metabolic imaging findings for each of the three variants in turn. We then discuss morphometric studies that have examined relationships between atrophy and syntactic deficits irrespective of variant. These studies are particularly important because there is considerable heterogeneity among patients diagnosed with each variant, and furthermore, the progressive nature of PPA implies that patients' language functioning changes significantly over time (Kertesz et al., 2003). We then discuss functional imaging and diffusion tensor imaging studies, before concluding with a summary of the brain areas linked to syntactic deficits in PPA, and suggestions for future directions.

2. Assessment of syntactic deficits in PPA

We define syntactic processing as the ability to implicitly generate hierarchically structured representations of sentences, and to use function words and inflectional morphology to express grammatical categories such as number, definiteness, tense and aspect. Syntactic deficits can be defined as limitations in syntactic processing, which may be manifest in production, in comprehension, or most typically, in both production and comprehension. Core syntactic deficits would by definition affect both production and comprehension, and across a population of PPA patients, deficits in the production and comprehension of syntax are highly correlated (Wilson et al., 2011). However dissociations between production and comprehension may occur in principle, reflecting either impairments in peripheral processes, or partially distinct neural substrates for the production and comprehension of syntax.

Two patterns of syntactic production deficits are often recognized in the aphasiology literature: agrammatic and paragrammatic. The core features of agrammatic speech are omissions of function words and morphemes, reduced complexity of syntactic forms, and ungrammatical utterances, whereas paragrammatic speech is characterized by "unacceptable juxtapositions of phrases and misuse of words" (Goodglass et al., 1994, p. 598). We consider both patterns to be indicative of syntactic deficits, though the underlying causes may be different (Goodglass et al., 1993).

In PPA, syntactic production has most commonly been assessed by quantitative analysis of connected speech samples (Ash et al., 2006, 2009; Bird et al., 2000; Graham et al., 2004; Knibb et al., 2009; Meteyard and Patterson, 2009; Orange et al., 1998; Patterson et al., 2006; Patterson and MacDonald, 2006; Rogers and Alarcon, 1998; Thompson et al., 1997, 2012a; Wilson et al., 2010b). This approach provides a rich description of a patient's capacity to

correctly produce syntactic structures, but it has several disadvantages. One is that it is relatively unconstrained, so patients may differ in the extent to which they attempt structures that may be challenging. Therefore the same degree of syntactic impairment could result in syntactic errors in one patient, but simplified utterances in another (Wilson et al., 2010b). To circumvent this limitation, several recent studies have used constrained speech production tasks in which targeted sentence structures are primed or elicited (Thompson et al., 2012b; DeLeon et al., submitted). The second limitation of connected speech analysis is that motor speech deficits are often prominent in nonfluent PPA and can complicate the quantification of syntactic deficits; indeed, some patients are mute and cannot produce connected speech at all. To assess syntax in patients without intact speech production, Weintraub et al. (2009) have proposed the Northwestern Anagram Test, in which patients are asked to assemble printed words to describe pictures. Some patients performed better on this test than they did on a constrained speech production task, revealing a greater command of sentence structure than was otherwise apparent (Weintraub et al., 2009).

Syntactic comprehension has most often been assessed with sentence-picture matching tasks, in which the patient hears (or reads) a sentence and has to select a matching picture from an array containing foils. Examples include the Test for Reception of Grammar (Bishop, 1983) and the Curtiss-Yamada Comprehensive Language Examination (Curtiss and Yamada, unpublished test). However some of the tests that have been used were not designed for patients with PPA. They contain lexical items that can be challenging for patients with semantic PPA in particular, and they require choices among multiple possible responses, making considerable demands on working memory and executive processes. We have proposed a sentence-picture matching task that uses only high-frequency lexical items and has only one foil per item, making it more suitable for patients with PPA (Wilson et al., 2010a, 2011). Another approach that may also reduce executive demands is to present a sentence, then ask patients a probe question that tests syntactic comprehension (Grossman et al., 2005).

Even optimized versions of “offline” tasks such as these make considerable demands on working memory and executive processes, which can complicate interpretation of observed deficits. Moreover, syntactic processing takes place rapidly in real time, and many aspects can therefore only be studied in real time (Friederici, 2002). Several researchers have employed online tasks with PPA patients (Grossman et al., 2005; Peelle et al., 2007; Tyler et al., 1997). For instance, in normal participants, detection of a target word is slower immediately following a syntactic violation (Marslen-Wilson & Tyler, 1980). This and similar paradigms have been used to investigate abnormal syntactic processing in PPA patients (Grossman et al., 2005; Peelle et al., 2007; Tyler et al., 1997), with the advantage that there is less of an impact of other processes such as working memory and executive function.

3. Non-fluent variant PPA

3.1. Syntax in non-fluent PPA

Early clinical studies reported that non-fluent PPA patients produce agrammatic speech (Grossman et al., 1996; Hodges & Patterson, 1996; Mesulam, 1982; Snowden et al., 1992; Weintraub et al., 1990). These early studies typically classified PPA patients as fluent versus non-fluent, potentially including in the non-fluent group patients who would now be classified as logopenic. Recent studies have mostly recognized three variants, permitting more specific findings relating to each variant. A detailed picture of syntactic production deficits in non-fluent PPA has emerged from a number of studies that have quantified syntactic structures produced and syntactic errors in connected speech samples (Ash et al., 2006, 2009; Graham et al., 2004; Knibb et al., 2009; Patterson et al., 2006; Thompson et al.,

1997, 2012a; Wilson 2010b). These studies have shown that utterances produced by many non-fluent PPA patients are characterized by omissions of grammatical words and morphemes such as determiners, auxiliaries and verbal inflections, reduced access to verbs, incorrect argument structures, and decreased utterance length and complexity. All of these features become more severe as the disease progresses (Thompson et al., 1997). Elicited syntactic production studies have supported these findings, revealing particular difficulties with inflectional morphology, embeddings, and passive constructions (Thompson et al., 2012b; DeLeon et al., submitted).

However, these studies have also revealed that not all patients diagnosed with non-fluent PPA produce frankly agrammatic speech (Graham et al., 2004; Patterson et al., 2006; Knibb et al., 2009; Wilson et al., 2010b). In some patients, non-fluency is associated instead with apraxia of speech, reduced length of utterances and/or lack of embeddings. We note that according to recent consensus criteria, diagnosis of non-fluent PPA requires either agrammatism *or* apraxia of speech; although these often co-occur, the criteria do not require that both are present (Gorno-Tempini et al., 2011).

Patients with non-fluent PPA are also impaired in the comprehension of syntactically complex sentences (Gorno-Tempini et al., 2004; Grossman et al., 1996; 2005; Grossman & Moore, 2005; Hodges & Patterson, 1996; Snowden et al., 1992; Weintraub et al., 1990; Wilson et al., 2010a). For instance, Grossman et al. (1996) used sentence-picture matching and oral and written comprehension probe tasks to show that non-fluent patients perform quite well with simple sentences (reflecting relatively intact single word comprehension), but perform more poorly with complex syntactic structures such as subordination and center embedding.

Online syntactic processing studies have also demonstrated abnormal syntactic processing in non-fluent PPA patients. In a target detection task, patients with non-fluent PPA did not show any delay for targets that immediately followed syntactic violations, unlike control participants (Grossman et al., 2005; Peelle et al., 2007). In one study, non-fluent patients instead showed a delay four syllables later than the syntactic violation, a time frame in which normal participants showed no delay (Grossman et al., 2005), suggesting delayed syntactic processing in non-fluent PPA. Non-fluent patients did however show normal slowing following thematic (semantic) violations, indicative of the selective nature of the syntactic deficit (Peelle et al., 2007).

In sum, the majority of non-fluent PPA patients show syntactic deficits in production, comprehension, and online syntactic tasks.

3.2. Atrophy in non-fluent PPA and its relation to syntax

Non-fluent PPA is associated with atrophy of left frontal and, to a lesser extent, posterior perisylvian cortex. Early neuroimaging studies reported diffuse left perisylvian atrophy and/or hypometabolism, with frontal and temporal cortex both typically implicated (Snowden et al., 1992; Hodges & Patterson, 1996).

The development of high resolution MRI and quantitative analytical methods such as voxel-based morphometry (VBM) and cortical thickness measures have led to more anatomically specific findings. In a study including 11 patients with non-fluent PPA, Gorno-Tempini et al. (2004) used VBM to localize the most significant volume loss to the left inferior frontal gyrus, precentral gyrus, frontal operculum, and basal ganglia. The primary involvement of left frontal cortex has been confirmed in recent studies using cortical thickness measures (Mesulam et al., 2009; Rogalski et al., 2011b; Sapolsky et al., 2010). Hypometabolism is also most prominent in left frontal regions (Nestor et al., 2003; Josephs et al., 2010).

Most studies have also reported atrophy in posterior left perisylvian regions including the superior temporal gyrus and sulcus and the temporo-parietal junction (Gunawardena et al., 2010; Mesulam et al., 2009; Rogalski et al., 2011b; Rohrer et al., 2009; Sapolsky et al., 2010; Wilson et al., 2010b). In the majority of these studies, posterior atrophy is considerably less extensive than frontal atrophy (Mesulam et al., 2009; Rogalski et al., 2011b; Sapolsky et al., 2010; Wilson et al., 2010b). Longitudinal studies have shown that posterior perisylvian regions are increasingly impacted as the disease progresses (Ragolski et al., 2011b; Rohrer et al., 2009).

Taken together with the findings of syntactic deficits in non-fluent PPA outlined in the previous section, these anatomical findings suggest that atrophy of left frontal, and to a lesser extent, left posterior perisylvian cortex, is associated with syntactic deficits. However, as noted above, nonfluent patients vary considerably in the degree to which they present with syntactic deficits. In a study of 8 patients with non-fluent PPA, Gunawardena et al. (2010) reported that reduced production of complex structures was correlated with atrophy of a region overlapping left inferior frontal cortex and the adjacent superior temporal gyrus. In section 6, we discuss studies which have related regional atrophy to syntactic measures irrespective of PPA variant diagnosis.

4. Semantic variant PPA

4.1. Syntax in semantic PPA

In most patients with semantic variant PPA, syntactic processing is strikingly spared. In Warrington's (1975) initial description of three patients with semantic PPA, two of the three patients were described as conversing fluently, and the other's syntax was described as "slightly impaired". Sentence comprehension was intact subject to limitations of vocabulary. On a 15-item version of the Token Test (De Renzi & Vignolo, 1962), which requires following commands of varying degrees of syntactic complexity, the patients scored 15, 13, and in the case of the slightly impaired patient, 10. Subsequent studies have confirmed Warrington's original observations that syntax is largely spared in semantic PPA. Snowden et al. (1989, 1992) reported syntax to be normal in patients with semantic PPA. Hodges et al. (1992) studied five patients with semantic PPA. In four of the patients, both production and comprehension of syntax were normal, with scores on a 36-item version of the Token Test ranging from 34 to 35, and scores on the 80-item Test for Reception of Grammar (Bishop, 1983) ranging from 76 to 78. The fifth patient showed normal syntax in production, and only occasional deficits in comprehension of syntax. Gorno-Tempini et al. (2004) studied 10 patients with semantic PPA and found that they performed well on syntactic tests: mean 73/80 on sequential commands from the Western Aphasia Battery (Kertesz, 1983), and 51/55 on the syntactic comprehension component of the Curtiss-Yamada Comprehensive Language Examination (Curtiss & Yamada, unpublished test).

In an online task testing sensitivity to syntactic violations, semantic variant patients showed post-violation slowing and recovery that was indistinguishable from normal control participants (Grossman et al., 2005). Semantic variant patients also performed normally at detecting syntactic violations in a grammaticality judgment task (Cotelli et al., 2007). Patients with semantic PPA can even use syntactic information to aid interpretation of lost lexical items (Schwartz et al., 1979; Breedin & Saffran, 1999). Syntactic information pertaining to lexical items, such as argument structure, and the mass/count distinction, appears to be largely retained even when the semantic content of items is lost (Breedin et al., 1994; Garrard et al., 2004; Taler et al., 2005).

Despite the robust body of evidence for preservation of syntax in semantic PPA, subtle syntactic deficits do nevertheless emerge as the disease progresses. Quantitative studies of

connected speech in semantic PPA have revealed that semantic PPA patients make subtle syntactic errors (Meteyard and Patterson, 2009; Wilson et al., 2010b). These errors are mostly paragrammatic rather than agrammatic (Wilson et al., 2010b); predominant error types include substitutions of closed class words and bound morphemes (Meteyard and Patterson, 2009). Rochon et al. (2004) presented a longitudinal case study of a semantic variant patient in whom syntactic comprehension remained remarkably intact, with the exception of relatively poor performance on passives on the final occasion she was tested. Benedet et al. (2006) described a patient who comprehended syntactically complex sentences well, but became increasingly unable to produce complex syntactic structures. When declines in syntactic processing occur late in the course of the disease, syntax always remains relatively preserved in relation to lexical and semantic knowledge.

4.2. Atrophy in semantic PPA and its relation to syntax

Semantic PPA is characterized by atrophy of the anterior temporal lobes (Hodges et al., 1992). Damage is typically bilateral, but is usually more extensive in the left hemisphere. Studies using VBM or cortical thickness measures have shown that the regions affected are the temporal pole, inferior and middle temporal gyri, anterior fusiform gyrus, amygdala, hippocampus and entorhinal/peri-rhinal cortices (Mummery et al., 2000; Chan et al., 2001; Galton et al., 2001; Gorno-Tempini et al., 2004; Mesulam et al., 2009). Atrophy can be profound; it is not uncommon to see volume loss of 50% or greater in the anterior temporal lobes. These temporal lobe regions that are atrophic are also hypometabolic (Diehl et al., 2004; Drzezga et al., 2008; Josephs et al., 2010). The fact that syntactic processing is relatively spared in semantic PPA suggests that anterior temporal cortex, in particular the more inferior part, is not crucial for syntax.

The limited syntactic deficits that are observed in semantic PPA may be a consequence of degraded lexical/semantic representations (Breedin & Saffran, 1999; Rochon et al., 2004; Benedet et al., 2006; Meteyard and Patterson, 2009), or they may constitute an independent deficit as atrophy spreads over time. Bright et al. (2008) performed a longitudinal study and showed that one of the two semantic PPA patients they studied developed syntactic deficits over time. This was accompanied by an extension of atrophy into posterior perisylvian cortex, which did not occur in the other patient.

Peelle et al. (2008) used VBM to identify regions where tissue volume was correlated with comprehension of syntactically complex sentences specifically in 8 patients diagnosed with semantic PPA. A mid-posterior lateral temporal region was both atrophic in the semantic PPA group and correlated with syntactic comprehension performance in that group.

These two studies suggest that some syntactic deficits in semantic PPA might reflect posterior spread of atrophy into posterior perisylvian regions important for syntactic processing, and might constitute a second deficit, in addition to the primary lexical/semantic deficit.

5. Logopenic variant PPA

5.1. Syntax in logopenic PPA

Patients with logopenic PPA speak slowly, with syntactically simple but largely correct sentences (Gorno-Tempini et al., 2004, 2008). They are by no means agrammatic. However, an analysis of their connected speech has shown that they produce many paragrammatic errors (Wilson et al., 2010b). Their speech is also characterized by frequent “retracings”, in which the patient stops what they are saying, and goes back to phrase the sentence differently. Across patients, the frequency of syntactic errors and retracings were correlated. This suggests that the stop-start nature of these patients’ speech, along with documented

limitations of verbal working memory (Gorno-Tempini et al., 2004, 2008; Rohrer et al., 2010) may be responsible for many of the syntactic errors.

In tests of syntactic comprehension, logopenic PPA patients perform even more poorly than nonfluent patients, despite the fact that they are not agrammatic (Amici et al., 2007; Gorno-Tempini et al., 2004, 2008). We have recently collected data suggesting that logopenic patients' poor comprehension of syntactically complex sentences may be due to the verbal short-term memory demands of sentence comprehension tests. We presented a sentence comprehension task with short and long sentences that varied in syntactic complexity to 5 patients with logopenic PPA and 8 patients with non-fluent PPA (see Wilson et al., 2010a for methodological details; the data on the logopenic patients have not been previously reported). Patients with logopenic PPA performed well on all short sentences, even those that included passive constructions that were problematic for non-fluent patients (Fig. 2). However the logopenic patients performed poorly on the long sentences, which pose a greater working memory load.

As mentioned above, some patients who would now be considered logopenic were classified as non-fluent in earlier studies. For instance, thanks to the comprehensive data provided by Thompson et al. (1997), it can be inferred that their subject 2 was logopenic. These authors recognized that subject 2 exhibited a different pattern from the other three subjects. Subsequently this patient showed Alzheimer's pathology at autopsy, consistent with logopenic PPA (Thompson, Mesulam and Weintraub, personal communication). Notably, subject 2 produced far less ungrammatical sentences, incorrect morphology, or incorrect argument structures than the other patients in this study, who would be classified as non-fluent variant. Earlier literature must be interpreted carefully because of this issue, but when sufficient data are available, the earlier literature confirms that logopenic patients do make some syntactic errors, but are not frankly agrammatic.

5.2. Atrophy in logopenic PPA and its relation to syntax

Atrophy in logopenic PPA has been shown using VBM to be most prominent in posterior perisylvian regions including the posterior superior and middle temporal gyri, and the inferior parietal lobe (Gorno-Tempini et al., 2004, 2008). These findings have been replicated with cortical thickness measures (Mesulam et al., 2009; Rogalski et al., 2011b; Rohrer et al., 2010; Sapolsky et al., 2010). These same regions are also hypometabolic in logopenic PPA (Rabinovici et al., 2008; Josephs et al., 2010). The paragrammatic errors and difficulties with long, syntactically complex sentences may be due to damage to these posterior perisylvian regions.

6. Relationships between atrophy and syntactic deficits irrespective of variant diagnosis

So far we have discussed the characteristic syntactic and anatomical findings in the three variants. However due to variability between patients and the progressive nature of PPA, it is particularly informative to relate syntactic measures to neural measures across PPA patients irrespective of their variant diagnosis. We will now discuss studies which have taken this approach to syntactic production and comprehension.

We used VBM to identify brain regions where atrophy was predictive of a range of connected speech measures in 50 patients with PPA (all three variants were represented) and 10 with behavioral variant fronto-temporal dementia (Wilson et al., 2010b). Two syntactic measures were obtained. The first was a composite syntactic measure that incorporated syntactic error frequency as well as the proportion of words belonging to sentences (as opposed to smaller fragments). The second measure was the frequency of embeddings. Both

of these measures were most impacted in non-fluent patients, though there was a range of scores in the non-fluent group, and several patients belonging to other variants also had low scores. Both measures were associated with volume loss in left inferior frontal cortex (Fig. 3A). The composite syntactic measure was also associated with reduced volume in the white matter underlying these regions.

In contrast, retracings, which were correlated with syntactic errors in logopenic patients only, were linked to atrophy of posterior perisylvian regions.

Correlations between left frontal atrophy and syntactic production deficits have also been reported in a number of other studies. Rogalski et al. (2011a) used cortical thickness measures in 27 patients with PPA (all three variants were represented) to show that impaired grammatical processing, as assessed by a subset of items from the Northwestern Anagram Test (Weintraub et al., 2009), was associated with atrophy of the inferior frontal gyrus as well as ventral sensorimotor cortex and the supramarginal gyrus. The patients with low scores on this measure were predominantly diagnosed as non-fluent variant. The ventral sensorimotor finding should probably be interpreted with caution since the patient group as a whole did not have significant atrophy in that region. Wilson et al. (2011), using a qualitative rather than quantitative evaluation of syntactic production deficits, also found that production deficits were linked to inferior frontal atrophy. DeLeon et al. (submitted) found that left inferior frontal atrophy was predicative of syntactic deficits on an elicited production task.

The relationship between atrophy and deficits in syntactic comprehension was investigated by Amici et al. (2007), who used VBM in 47 patients with PPA (all variants) and 11 other patients with language deficits due to neurodegenerative disease. Comprehension of the most syntactically complex sentences was correlated with volume loss in the left inferior and middle frontal gyri (Fig. 3B). Overall poor sentence comprehension correlated with atrophy of left temporoparietal cortex. This finding appears to be due to logopenic patients, who performed poorly, possibly due to their impairments in verbal working memory. Several subsequent studies have confirmed that left frontal atrophy is predictive of syntactic comprehension deficits in PPA (Peelle et al., 2008; Sapolsky 2010; Wilson et al., 2011).

7. Functional imaging of syntactic processing in PPA

Relatively few studies have used functional imaging to examine language processing in PPA, and only two of these have examined syntactic processing in particular. Cooke et al. (2003) used a sentence comprehension task to study three patients with non-fluent PPA, and found an absence of left inferior frontal activity that was present in controls. However, the small sample size precluded a direct comparison of patients and controls.

In a recent study of 8 patients with non-fluent PPA, we used a parametric sentence comprehension task with 7 conditions varying in syntactic complexity, but matched in other respects (Wilson et al., 2010a). In 24 normal controls, we found that left inferior frontal cortex as well as the left posterior superior temporal sulcus were modulated by syntactic complexity, as expected based on previous studies (Fig. 4A). In contrast, in patients with non-fluent PPA, left inferior frontal cortex was not modulated by syntactic complexity (Fig. 4B). This region showed an equivalent level of activity for syntactically complex and simple sentences. This abnormal pattern was specific to left inferior frontal cortex; the posterior superior temporal sulcus was modulated by syntactic complexity in patients just as it was in controls (Fig. 4C).

Both of these studies suggest that the left inferior frontal cortex is not only structurally atrophic, but is also functionally abnormal in non-fluent PPA.

8. White matter damage in relation to syntactic deficits in PPA

Syntactic processing depends not just on cortical regions, but also on the white matter fiber bundles that connect them. There is increasing evidence that disrupted connectivity might be a significant contributing factor to language deficits in PPA, including syntactic deficits.

Several recent studies using diffusion tensor imaging have provided evidence regarding which tracts are important for syntactic processing. Non-fluent patients, many of whom are agrammatic, have reduced fractional anisotropy, a widely used marker of microstructural damage, in the left superior longitudinal fasciculus (SLF), which includes as a branch the arcuate fasciculus (Whitwell et al., 2010; Galantucci et al., 2011). In contrast, semantic variant patients have reduced fractional anisotropy in the left inferior longitudinal fasciculus and uncinate fasciculus (Agosta et al., 2009; Whitwell et al., 2010; Galantucci et al., 2011), whereas the SLF/arcuate is damaged to a much lesser extent and only in its temporal part. Logopenic patients have reduced fractional anisotropy only in the temporo-parietal branch of the SLF/arcuate (Galantucci et al., 2011). These group-level associations suggest that the SLF/arcuate may be important for syntactic processing, since it is damaged in the non-fluent variant, who have syntactic deficits, spared in the semantic variant, who do not have syntactic deficits, and partially damaged in the logopenic variant, who have limited syntactic deficits.

In a recent study, we directly examined the relationship between white matter damage in three left hemisphere tracts, and deficits in syntactic production and comprehension (Wilson et al., 2011). The tracts we examined were the SLF/arcuate, extreme capsule fiber system, and uncinate fasciculus (Fig. 5A). We found that damage to the left SLF/arcuate, as quantified by reduced FA, was strongly associated with syntactic deficits in both production (Fig. 5B) and comprehension (Fig. 5C). This association persisted when gray matter volume in left inferior frontal cortex was taken into account. The PPA patients with the most severe syntactic deficits were of the non-fluent variant. However the relationship between reduced FA in the left SLF/arcuate and syntactic deficits persisted when PPA variant was included as a covariate, indicating that the relationship was not simply a monolithic effect of the whole non-fluent group.

Damage to the extreme capsule fiber system or the uncinate fasciculus was not associated with syntactic deficits in either production or comprehension.

9. Discussion and conclusions

Taken together, the findings we have reviewed suggest that syntactic deficits in PPA are associated with damage to left inferior frontal cortex, posterior perisylvian cortex, and the dorsal pathways that connect these regions. In contrast, damage to anterior temporal cortex, or ventral tracts, is not linked to syntactic deficits.

Left inferior frontal cortex is not only atrophic in non-fluent PPA, the variant that typically exhibits the most significant syntactic deficits, but this region is also hypometabolic and functionally abnormal, failing to show modulation by syntactic complexity. Left inferior frontal cortex has also been identified in all studies where volume loss or cortical thinning have been correlated with syntactic deficits across patients without taking variant diagnosis into account.

Left posterior perisylvian damage also appears to contribute to syntactic processing deficits in PPA. Most studies have shown that non-fluent patients have atrophy in posterior perisylvian cortex in addition to the more prominent frontal atrophy. In the logopenic variant, atrophy is greatest in posterior perisylvian cortex, and logopenic patients make

paragrammatic errors and have difficulties comprehending long, syntactically complex sentences. There is some evidence that in semantic variant PPA, spread of atrophy posteriorly and dorsally is associated with the emergence of syntactic problems. Taken together, these findings suggest that posterior perisylvian regions play an important role in syntactic processing. Possible roles for posterior regions in syntactic processing include integrating lexical/semantic information with syntactic information (Friederici et al., 2009), retrieving syntactic information associated with lexical items (Snijders et al., 2009; Thompson et al., 2007), and echoic processes and sensorimotor transformations underlying verbal working memory (Buchsbaum et al., 2005, 2011).

The arcuate component of the SLF connects frontal and posterior temporal language regions. Damage to the SLF, including its arcuate component, is associated with deficits in syntactic comprehension and production, above and beyond the contribution of gray matter atrophy. This finding suggests that syntactic processing depends on intact connectivity between anterior and posterior language regions (Papoutsis et al., 2011; Sonty et al., 2007), specifically via dorsal tracts.

Anterior and inferior temporal regions do not appear to play a key role in syntactic processing, since damage does not result in syntactic processing deficits. This evidence from PPA is consistent with studies showing that surgical resection of anterior temporal cortex does not result in syntactic deficits (Kho et al., 2008), and with fMRI studies of normal participants showing that posterior but not anterior temporal regions are modulated by syntactic complexity (e.g. Friederici et al., 2009; Wilson et al., 2010a). However other studies have shown that anterior temporal cortex is more active for syntactic structure than word lists (Humphries et al., 2006; Vandenberghe et al., 2002). One possible explanation for the activation of anterior temporal cortex in these studies is that it reflects semantic processing. Though many researchers have shown an effect of syntactic structure even when using pseudowords to minimize semantic processing, participants were asked to perform judgments of meaningfulness which may have recruited semantic processes despite the presence of pseudowords (Humphries et al., 2006). In another study where semantic judgment were not required, anterior temporal cortex was sensitive to combinatorial complexity only in phrases of real words, not pseudowords (Pallier et al., 2011).

Though this issue is far from resolved, the available evidence suggests that left anterior temporal cortex is important for semantic rather than syntactic processing.

The evidence from PPA suggests that ventral tracts such as the extreme capsule fiber system and the uncinate fasciculus are not essential for syntactic processing, since syntax is often entirely or at least largely spared in patients with damage to these tracts. However, several researchers have suggested that ventral tracts may play a role in syntactic processing (Friederici, 2009; Friederici et al., 2006; Griffiths et al., 2012; Papoutsis et al., 2011; Rolheiser et al., 2011; Weiller et al., 2009). The most direct evidence presented in support of this claim comprises three recent studies from Tyler and colleagues, who observed syntactic deficits in stroke patients with damage to either dorsal or ventral tracts (Griffiths et al., 2012; Papoutsis et al., 2011; Rolheiser et al., 2011). While the authors conducted careful analyses in an attempt to distinguish differential contributions of dorsal and ventral tracts, there were nevertheless no patients who had damage to ventral tracts alone. Most patients with damage to ventral tracts had damage to dorsal tracts also, with the exception of one patient who had additional posterior temporal damage (Griffiths et al., 2012). The data from PPA are thus potentially more informative, because patients with semantic PPA have damage to ventral tracts, yet sparing of dorsal tracts, as well as sparing of frontal and posterior temporal language regions. The fact that they do not show significant syntactic deficits suggests that ventral tracts may not play a direct role in syntactic processing. In natural language

processing, dorsal and ventral tracts may interact synergistically (Griffiths et al., 2012), yet syntactic and semantic information may be to some extent segregated into dorsal and ventral streams.

There are several promising avenues for future research. First, functional imaging studies of syntactic processing in PPA will be invaluable in determining the functional status of atrophic regions, as well as any cortical reorganization that may occur when brain regions important for syntactic processing are damaged. In particular, functional imaging studies in semantic variant PPA could shed light on the question of why syntactic processing is spared when anterior temporal regions are damaged, given that these regions may be modulated by the presence of syntactic structure in controls. More generally, correlations between brain and behavior will be increasingly informative as the nature of the neural changes due to neurodegeneration are more comprehensively quantified through a wide range of neuroimaging modalities including functional MRI, tractography and perfusion imaging.

Second, there is a need for increasing sophisticated assessment of syntactic deficits. Most tasks that have been used, even those that have been optimized for PPA, are dependent on working memory and executive processes that are compromised to some extent in many patients. Online studies that tap syntactic processing in a more covert manner (e.g. Grossman et al., 2005; Peelle et al., 2007; Tyler et al., 1997) may prove more appropriate for delineating which aspects of syntactic processing are impaired and which are spared.

Third, increasingly large cohorts of PPA patients recruited at major centers and studied longitudinally will increase our understanding of the heterogeneity among patients diagnosed with each variant and the changes that take place over time. It should be possible to determine why agrammatism predominates in some patients with non-fluent PPA, whereas motor speech deficits are more salient in others. Non-fluent PPA has been associated with both Tau and TDP-43 pathologies. Future studies should be able to determine whether the different underlying pathologies result in different patterns of regional atrophy, and whether the nature and extent of syntactic deficits depends on the underlying pathology (Deramecourt et al., 2010; Snowden et al., 2011).

The last two decades have seen significant progress in understanding the neural correlates of syntactic deficits in PPA. As multimodal neuroimaging techniques and sophisticated neurolinguistic assessments are applied to increasing numbers of patients, we will learn more about the neural basis of syntactic deficits in PPA and about the functional anatomy of syntactic processing.

Acknowledgments

Supported by NIH (NIDCD R03 DC010878 to SMW, NINDS R01 NS050915 to MLGT, NIA P50 AG03006, NIA P01 AG019724) and Fonds de la recherche en santé du Québec (FRSQ) to MCT. We thank our colleagues, patients, caregivers and volunteers for their contributions to our research. We thank John Wiley & Sons, Oxford University Press, the Society for Neuroscience and Cell Press for permission to reprint figures from previously published articles.

References

- Agosta F, Henry RG, Migliaccio R, Neuhaus J, Miller BL, Dronkers NF, Gorno-Tempini ML. Language networks in semantic dementia. *Brain*. 2010; 133:286–299. [PubMed: 19759202]
- Amici S, Brambati SM, Wilkins DP, Ogar J, Dronkers NL, Miller BL, Gorno-Tempini ML. Anatomical correlates of sentence comprehension and verbal working memory in neurodegenerative disease. *Journal of Neuroscience*. 2007; 27:6282–6290. [PubMed: 17554002]

- Ash S, Moore P, Vesely L, Gunawardena D, McMillan C, Anderson C, Grossman M. Non-fluent speech in frontotemporal lobar degeneration. *Journal of Neurolinguistics*. 2009; 22:370–383. [PubMed: 22180700]
- Ash S, Moore P, Antani S, McCawley G, Work M, Grossman M. Trying to tell a tale: Discourse impairments in progressive aphasia and frontotemporal dementia. *Neurology*. 2006; 66:1405–1413. [PubMed: 16682675]
- Benedet M, Patterson K, Gomez-Pastor I, Garcia de la Rocha ML. “Nonsemantic” aspects of language in semantic dementia: As normal as they’re said to be? *Neurocase*. 2006; 12:15–26. [PubMed: 16517512]
- Bird H, Lambon Ralph MA, Patterson K, Hodges JR. The rise and fall of frequency and imageability: Noun and verb production in semantic dementia. *Brain and Language*. 2000; 73:17–49. [PubMed: 10872636]
- Bishop, DVM. *Test for the reception of grammar*. Abingdon, UK: Thomas Leach; 1983.
- Breedin SD, Saffran EM, Coslett HB. Reversal of the concreteness effect in a patient with semantic dementia. *Cognitive Neuropsychology*. 1994; 11:617–660.
- Breedin S, Saffran EM. Sentence processing in the face of semantic loss: A case study. *Journal of Experimental Psychology General*. 1999; 128:547–562. [PubMed: 10650585]
- Bright P, Moss HE, Stamatakis EA, Tyler LK. Longitudinal studies of semantic dementia: the relationship between structural and functional changes over time. *Neuropsychologia*. 2008; 46:2177–2188. [PubMed: 18395761]
- Buchsbaum BR, Baldo J, Okada K, Berman KF, Dronkers N, D’Esposito M, Hickok G. Conduction aphasia, sensory-motor integration, and phonological short-term memory – An aggregate analysis of lesion and fMRI data. *Brain and Language*. 2011; 119:119–128. [PubMed: 21256582]
- Buchsbaum BR, Olsen RK, Koch P, Berman KF. Human dorsal and ventral auditory streams subserve rehearsal-based and echoic processes during verbal working memory. *Neuron*. 2005; 48:687–697. [PubMed: 16301183]
- Chan D, Fox NC, Scahill RI, Crum WR, Whitwell JL, Leschziner G, Rossor MN. Patterns of temporal lobe atrophy in semantic dementia and Alzheimer’s disease. *Annals of Neurology*. 2001; 49:433–442. [PubMed: 11310620]
- Cooke A, DeVita C, Gee J, Alsop D, Detre J, Chen W, Grossman M. Neural basis for sentence comprehension deficits in frontotemporal dementia. *Brain and Language*. 2003; 85:211–221. [PubMed: 12735939]
- Cotelli M, Borroni B, Manenti R, Ginex V, Calabria M, Moro A, Padovani A. Universal grammar in the frontotemporal dementia spectrum: Evidence of a selective disorder in the corticobasal degeneration syndrome. *Neuropsychologia*. 2007; 45:3015–3023. [PubMed: 17640688]
- Davies RR, Hodges JR, Kril JJ, Patterson K, Halliday GM, Xuereb JH. The pathological basis of semantic dementia. *Brain*. 2005; 128:1984–1995. [PubMed: 16000337]
- De Renzi E, Vignolo LA. The token test: A sensitive test to detect receptive disturbances in aphasics. *Brain*. 1962; 85:665–678. [PubMed: 14026018]
- DeLeon J, Gesierich B, Besbris M, Ogar JM, Henry ML, Miller BL, Wilson SM. Elicitation of specific syntactic structures in primary progressive aphasia. (submitted).
- Deramecourt V, Lebert F, Debachy B, Mackowiak-Cordoliani MA, Bombois S, Kerdraon O, Pasquier F. Prediction of pathology in primary progressive language and speech disorders. *Neurology*. 2010; 74:42–49. [PubMed: 19940270]
- Diehl J, Grimmer T, Drzezga A, Riemenschneider M, Förstl H, Kurz A. Cerebral metabolic patterns at early stages of frontotemporal dementia and semantic dementia: A PET study. *Neurobiology of Aging*. 2004; 25:1051–1056. [PubMed: 15212830]
- Drzezga A, Grimmer T, Henriksen G, Stangier I, Pernecky R, Diehl-Schmid J, Kurz A. Imaging of amyloid plaques and cerebral glucose metabolism in semantic dementia and Alzheimer’s disease. *NeuroImage*. 2008; 39:619–633. [PubMed: 17962045]
- Friederici AD. Towards a neural basis of auditory sentence processing. *Trends in Cognitive Sciences*. 2002; 6:78–84. [PubMed: 15866191]
- Friederici AD. Pathways to language: Fiber tracts in the human brain. *Trends in Cognitive Sciences*. 2009; 13:175–181. [PubMed: 19223226]

- Friederici AD, Bahlmann J, Heim S, Schubotz RI, Anwander A. The brain differentiates human and non-human grammars: Functional localization and structural connectivity. *Proceedings of the National Academy of Sciences of the United States of America*. 2006; 103:2458–2463. [PubMed: 16461904]
- Galantucci S, Tartaglia MC, Wilson SM, Henry ML, Filippi M, Agosta F, Gorno-Tempini ML. White matter damage in primary progressive aphasias: A diffusion tensor tractography study. *Brain*. 2011; 134:3011–3029. [PubMed: 21666264]
- Galton CJ, Patterson K, Graham K, Lambon-Ralph MA, Williams G, Antoun N, Hodges JR. Differing patterns of temporal atrophy in Alzheimer's disease and semantic dementia. *Neurology*. 2001; 57:216–225. [PubMed: 11468305]
- Garrard P, Carroll E, Vinson D, Vigliocco G. Dissociation of lexical syntax and semantics: Evidence from focal cortical degeneration. *Neurocase*. 2004; 10:353–362. [PubMed: 15788273]
- Goodglass H, Christiansen JA, Gallagher R. Comparison of morphology and syntax in free narrative and structured tests: fluent vs. nonfluent aphasics. *Cortex*. 1993; 29:377–407. [PubMed: 8258282]
- Goodglass H, Christiansen JA, Gallagher RE. Syntactic constructions used by agrammatic speakers: Comparison with conduction aphasics and normals. *Neuropsychology*. 1994; 8:598–613.
- Gorno-Tempini ML, Brambati SM, Ginex V, Ogar J, Dronkers NF, Marcone A, Miller BL. The logopenic/phonological variant of primary progressive aphasia. *Neurology*. 2008; 71:1227–1234. [PubMed: 18633132]
- Gorno-Tempini ML, Dronkers NF, Rankin KP, Ogar JM, Phengrasamy L, Rosen HJ, Miller BL. Cognition and anatomy in three variants of primary progressive aphasia. *Annals of Neurology*. 2004; 55:335–346. [PubMed: 14991811]
- Gorno-Tempini ML, Hillis AE, Weintraub S, Kertesz A, Mendez M, Cappa S, Grossman M. Classification of primary progressive aphasia and its variants. *Neurology*. 2011; 76:1006–1014. [PubMed: 21325651]
- Graham N, Patterson K, Hodges J. When more yields less: Speaking and writing deficits in nonfluent progressive aphasia. *Neurocase*. 2004; 10:141–155. [PubMed: 15788253]
- Griffiths JD, Marslen-Wilson WD, Stamatakis EA, Tyler LK. Functional organization of the neural language system: Dorsal and ventral pathways are critical for syntax. *Cerebral Cortex*. 2012 in press.
- Grossman M. Primary progressive aphasia: Clinicopathological correlations. *Nature Reviews Neurology*. 2010; 6:88–97.
- Grossman M, Mickanin J, Onishi K, Hughes E, D'Esposito M, Ding X, Reivich M. Progressive nonfluent aphasia: Language, cognitive, and PET measures contrasted with probable Alzheimer's disease. *Journal of Cognitive Neuroscience*. 1996; 8:135–154.
- Grossman M, Moore P. A longitudinal study of sentence comprehension difficulty in primary progressive aphasia. *Journal of Neurology, Neurosurgery & Psychiatry*. 2005; 76:644–649.
- Grossman M, Rhee J, Moore P. Sentence processing in frontotemporal dementia. *Cortex*. 2005; 41:764–777. [PubMed: 16353366]
- Gunawardena D, Ash S, McMillan C, Avants B, Gee J, Grossman M. Why are patients with progressive nonfluent aphasia nonfluent? *Neurology*. 2010; 75:588–594. [PubMed: 20713947]
- Henry ML, Gorno-Tempini ML. The logopenic variant of primary progressive aphasia. *Current Opinion in Neurology*. 2010; 23:633–637. [PubMed: 20852419]
- Henry, ML.; Wilson, SM.; Rapcsak, SZ. Primary progressive aphasia. In: Nair, AK.; Sabbagh, M., editors. *Textbook of geriatric neurology*. New York: Prentice-Hall; 2012.
- Hodges JR, Patterson K. Nonfluent progressive aphasia and semantic dementia: A comparative neuropsychological study. *Journal of the International Neuropsychological Society*. 1996; 2:511–524. [PubMed: 9375155]
- Hodges JR, Patterson K, Oxbury S, Funnell E. Semantic dementia: Progressive fluent aphasia with temporal lobe atrophy. *Brain*. 1992; 115:1783–1806. [PubMed: 1486461]
- Humphries C, Binder JR, Medler DA, Liebenthal E. Syntactic and semantic modulation of neural activity during auditory sentence comprehension. *Journal of Cognitive Neuroscience*. 2006; 18:665–679. [PubMed: 16768368]

- Josephs KA, Duffy JR, Fossett TR, Strand EA, Claassen DO, Whitwell Jennifer L, Peller PJ. Fluorodeoxyglucose F18 positron emission tomography in progressive apraxia of speech and primary progressive aphasia variants. *Archives of Neurology*. 2010; 67:596–605. [PubMed: 20457960]
- Josephs KA, Whitwell JL, Duffy JR, Vanvoorst WA, Strand EA, Hu WT, Petersen RC. Progressive aphasia secondary to Alzheimer disease vs FTL D pathology. *Neurology*. 2008; 70:25–34. [PubMed: 18166704]
- Kertesz, A. *Western aphasia battery*. New York: Grune and Stratton; 1982.
- Kertesz A, Davidson W, McCabe P, Takagi K, Munoz D. Primary progressive aphasia: Diagnosis, varieties, evolution. *Journal of the International Neuropsychological Society*. 2003; 9:710–719. [PubMed: 12901777]
- Kho KH, Indefrey P, Hagoort P, van Veelen CWM, van Rijen PC, Ramsey NF. Unimpaired sentence comprehension after anterior temporal cortex resection. *Neuropsychologia*. 2008; 46:1170–1178. [PubMed: 18076955]
- Knibb JA, Woollams AM, Hodges JR, Patterson K. Making sense of progressive non-fluent aphasia: An analysis of conversational speech. *Brain*. 2009; 132:2734–2746. [PubMed: 19696033]
- Marslen-Wilson W, Tyler LK. The temporal structure of spoken language understanding. *Cognition*. 1980; 8:1–71. [PubMed: 7363578]
- Mesulam M. Slowly progressive aphasia without generalized dementia. *Annals of Neurology*. 1982; 11:592–598. [PubMed: 7114808]
- Mesulam M. Primary progressive aphasia. *Annals of Neurology*. 2001; 49:425–432. [PubMed: 11310619]
- Mesulam M, Wicklund A, Johnson N, Rogalski E, Léger GC, Rademaker A, Bigio E. Alzheimer and frontotemporal pathology in subsets of primary progressive aphasia. *Annals of Neurology*. 2008; 63:709–719. [PubMed: 18412267]
- Mesulam M, Wieneke C, Rogalski E, Cobia D, Thompson C, Weintraub S. Quantitative template for subtyping primary progressive aphasia. *Archives of Neurology*. 2009; 66:1545–1551. [PubMed: 20008661]
- Meteyard L, Patterson K. The relation between content and structure in language production: An analysis of speech errors in semantic dementia. *Brain and Language*. 2009; 110:121–134. [PubMed: 19477502]
- Mummery CJ, Patterson K, Price CJ, Ashburner J, Frackowiak RSJ, Hodges JR. A voxel-based morphometry study of semantic dementia: Relationship between temporal lobe atrophy and semantic memory. *Annals of Neurology*. 2000; 47:36–45. [PubMed: 10632099]
- Neary D, Snowden JS, Gustafson L, Passant U, Stuss D, Black S, Benson DF. Frontotemporal lobar degeneration: a consensus on clinical diagnostic criteria. *Neurology*. 1998; 51:1546–1554. [PubMed: 9855500]
- Nestor PJ, Graham NL, Fryer TD, Williams GB, Patterson K, Hodges JR. Progressive non-fluent aphasia is associated with hypometabolism centred on the left anterior insula. *Brain*. 2003; 126:2406–2418. [PubMed: 12902311]
- Orange JB, Kertesz A, Peacock J. Pragmatics in frontal lobe dementia and primary progressive aphasia. *Journal of Neurolinguistics*. 1998; 11:153–177.
- Pallier C, Devauchelle AD, Dehaene S. Cortical representation of the constituent structure of sentences. *Proceedings of the National Academy of Sciences of the United States of America*. 2011; 108:2522–2527. [PubMed: 21224415]
- Papoutsis M, Stamatakis EA, Griffiths J, Marslen-Wilson WD, Tyler LK. Is left fronto-temporal connectivity essential for syntax? Effective connectivity, tractography and performance in left-hemisphere damaged patients. *NeuroImage*. 2011; 58:656–664. [PubMed: 21722742]
- Patterson K, Graham NL, Lambon Ralph MA, Hodges JR. Progressive non-fluent aphasia is not a progressive form of non-fluent (poststroke) aphasia. *Aphasiology*. 2006; 20:1018–1034.
- Patterson, K.; MacDonald, MC. Sweet nothings: Narrative speech in semantic dementia. In: Andrews, S., editor. *From inkmarks to ideas: current issues in lexical processing*. Hove: Psychology Press; 2006. p. 299-317.

- Peelle JE, Cooke A, Moore P, Vesely L, Grossman M. Syntactic and thematic components of sentence processing in progressive nonfluent aphasia and nonaphasic frontotemporal dementia. *Journal of Neurolinguistics*. 2007; 20:482–494. [PubMed: 18978927]
- Peelle JE, Troiani V, Gee J, Moore P, McMillan C, Vesely L, Grossman M. Sentence comprehension and voxel-based morphometry in progressive nonfluent aphasia, semantic dementia, and nonaphasic frontotemporal dementia. *Journal of Neurolinguistics*. 2008; 21:418–432. [PubMed: 19727332]
- Rabinovici GD, Jagust WJ, Furst AJ, Ogar JM, Racine CA, Mormino EC, Gorno-Tempini ML. A β amyloid and glucose metabolism in three variants of primary progressive aphasia. *Annals of Neurology*. 2008; 64:388–401. [PubMed: 18991338]
- Rochon E, Kave G, Cupit J, Jokel R, Winocur G. Sentence comprehension in semantic dementia: a longitudinal case study. *Cognitive Neuropsychology*. 2004; 21:317–330. [PubMed: 21038208]
- Rogalski E, Cobia D, Harrison TM, Wieneke C, Thompson CK, Weintraub S, Mesulam M. Anatomy of language impairments in primary progressive aphasia. *Journal of Neuroscience*. 2011a; 31:3344–3350. [PubMed: 21368046]
- Rogalski E, Cobia D, Harrison T, Wieneke C, Weintraub S, Mesulam MM. Progression of language decline and cortical atrophy in subtypes of primary progressive aphasia. *Neurology*. 2011b; 76:1804–1810. [PubMed: 21606451]
- Rogers MA, Alarcon NB. Dissolution of spoken language in primary progressive aphasia. *Aphasiology*. 1998; 12:635–650.
- Rohrer JD, Warren JD, Modat M, Ridgway GR, Douiri A, Rossor MN, Fox NC. Patterns of cortical thinning in the language variants of frontotemporal lobar degeneration. *Neurology*. 2009; 72:1562–1569. [PubMed: 19414722]
- Rolheiser T, Stamatakis EA, Tyler LK. Dynamic processing in the human language system: synergy between the arcuate fascicle and extreme capsule. *Journal of Neuroscience*. 2011; 31:16949–16957. [PubMed: 22114265]
- Rohrer JD, Ridgway GR, Crutch SJ, Hailstone J, Goll JC, Clarkson MJ, Warren J. Progressive logopenic/phonological aphasia: Erosion of the language network. *NeuroImage*. 2010; 49:984–993. [PubMed: 19679189]
- Saffran EM, Schwartz MF. Impairment of sentence comprehension. *Philosophical Transactions of the Royal Society of London. Series B, Biological Sciences*. 1994; 346:47–53.
- Sapolsky D, Bakkour A, Negreira A, Nalipinski P, Weintraub S, Mesulam MM, Dickerson BC. Cortical neuroanatomic correlates of symptom severity in primary progressive aphasia. *Neurology*. 2010; 75:358–366. [PubMed: 20660866]
- Schwartz MF, Marin OSM, Saffran EM. Dissociations of language function in dementia: A case study. *Brain and Language*. 1979; 7:277–306. [PubMed: 455049]
- Snijders TM, Vosse T, Kempen G, Van Berkum JJ, Petersson KM, Hagoort P. Retrieval and unification of syntactic structure in sentence comprehension: An fMRI study using word-category ambiguity. *Cerebral Cortex*. 2009; 19:1493–1503. [PubMed: 19001084]
- Snowden JS, Goulding PJ, Neary D. Semantic dementia: A form of circumscribed cerebral atrophy. *Behavioural Neurology*. 1989; 2:167–182.
- Snowden J, Neary D, Mann D. Frontotemporal lobar degeneration: Clinical and pathological relationships. *Acta Neuropathologica*. 2007; 114:31–38. [PubMed: 17569065]
- Snowden JS, Neary D, Mann DM, Goulding PJ, Testa HJ. Progressive language disorder due to lobar atrophy. *Annals of Neurology*. 1992; 31:174–183. [PubMed: 1575456]
- Snowden JS, Thompson JC, Stopford CL, Richardson AMT, Gerhard A, Neary D, Mann DMA. The clinical diagnosis of early-onset dementias: diagnostic accuracy and clinicopathological relationships. *Brain*. 2011; 134:2478–2492. [PubMed: 21840888]
- Sonty SP, Mesulam M, Weintraub S, Johnson NA, Parrish TB, Gitelman DR. Altered effective connectivity within the language network in primary progressive aphasia. *Journal of Neuroscience*. 2007; 27:1334–1345. [PubMed: 17287508]
- Taler V, Jarema G, Saumier D. Semantic and syntactic aspects of the mass/count distinction: A case study of semantic dementia. *Brain and Cognition*. 2005; 57:222–225. [PubMed: 15780454]

- Thompson CK, Ballard KJ, Tait ME, Weintraub S, Mesulam M. Patterns of language decline in non-fluent primary progressive aphasia. *Aphasiology*. 1997; 11:297–321.
- Thompson CK, Bonakdarpour B, Fix SC, Blumenfeld HK, Parrish TB, Gitelman DR, Mesulam MM. Neural correlates of verb argument structure processing. *Journal of Cognitive Neuroscience*. 2007; 19:1753–1767. [PubMed: 17958479]
- Thompson CK, Cho S, Ju-Hsu C, Wieneke C, Rademaker A, Weitner BB, Mesulam M, Weintraub S. Dissociations between fluency and agrammatism in primary progressive aphasia. *Aphasiology*. 2012a; 26:20–43. [PubMed: 22199417]
- Thompson CK, Meltzer-Asscher A, Cho S, Lee J, Wieneke C, Weintraub S, Mesulam M. Morphosyntactic processing in stroke-induced and primary progressive aphasia. *Behavioral Neurology*. 2012b in press.
- Tyler LK, Moss HE, Patterson K, Hodges J. The gradual deterioration of syntax and semantics in a patient with progressive aphasia. *Brain and Language*. 1997; 56:426–476. [PubMed: 9070420]
- Vandenberghe R, Nobre AC, Price CJ. The response of left temporal cortex to sentences. *Journal of Cognitive Neuroscience*. 2002; 14:550–560. [PubMed: 12126497]
- Warrington EK. The selective impairment of semantic memory. *The Quarterly Journal of Experimental Psychology*. 1975; 27:635–657. [PubMed: 1197619]
- Weiller C, Musso M, Rijntjes M, Saur D. Please don't underestimate the ventral pathway in language. *Trends in Cognitive Sciences*. 2009; 13:369–370. [PubMed: 19716753]
- Weintraub S, Mesulam M, Wieneke C, Rademaker A, Rogalski EJ, Thompson CK. The Northwestern anagram test: Measuring sentence production in primary progressive aphasia. *American Journal of Alzheimer's Disease and Other Dementias*. 2009; 24:408–416. [PubMed: 19700669]
- Weintraub S, Rubin NP, Mesulam MM. Primary progressive aphasia: Longitudinal course, neuropsychological profile, and language features. *Archives of Neurology*. 1990; 47:1329–1335. [PubMed: 2252450]
- Whitwell JL, Avula R, Senjem ML, Kantarci K, Weigand SD, Samikoglu A, Jack CR Jr. Gray and white matter water diffusion in the syndromic variants of frontotemporal dementia. *Neurology*. 2010; 74:1279–1287. [PubMed: 20404309]
- Wilson SM, Dronkers NF, Ogar JM, Jang J, Growdon ME, Agosta F, Gorno-Tempini ML. Neural correlates of syntactic processing in the nonfluent variant of primary progressive aphasia. *Journal of Neuroscience*. 2010a; 30:16845–16854. [PubMed: 21159955]
- Wilson SM, Galantucci S, Tartaglia MC, Rising K, Patterson DK, Henry ML, Gorno-Tempini ML. Syntactic processing depends on dorsal language tracts. *Neuron*. 2011; 72:397–403. [PubMed: 22017996]
- Wilson SM, Henry ML, Besbris M, Ogar JM, Dronkers NF, Jarrold W, Gorno-Tempini ML. Connected speech production in three variants of primary progressive aphasia. *Brain*. 2010b; 133:2069–2088. [PubMed: 20542982]

Highlights

- Left inferior frontal atrophy and dysfunction is associated with syntactic deficits in PPA.
- Posterior perisylvian cortex is also implicated.
- Syntactic processing is spared in patients with anterior temporal atrophy.
- Damage to dorsal but not ventral tracts is associated with syntactic deficits.

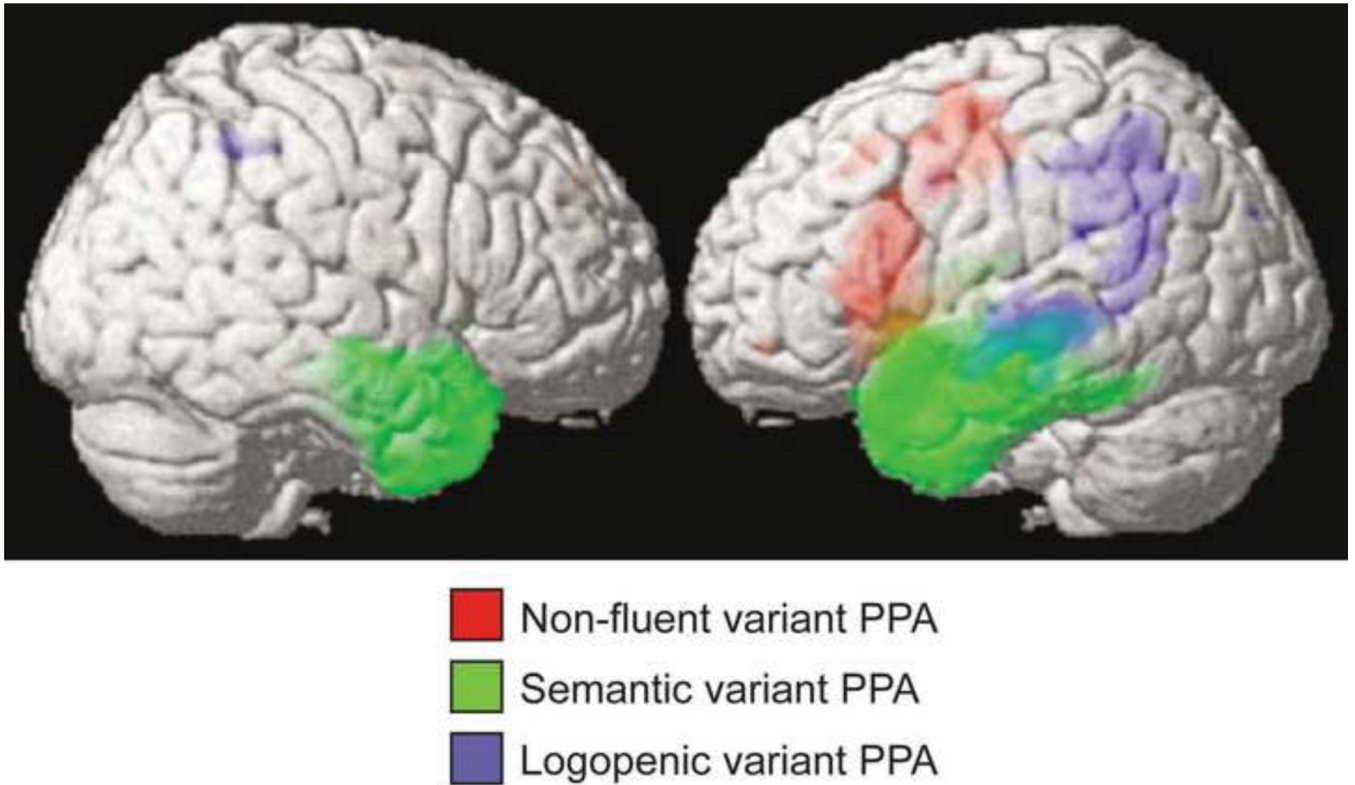


Fig. 1. Characteristic patterns of atrophy in the three variants of PPA. Voxel-based morphometry was used to identify regions where each variant showed volume loss relative to controls ($p < 0.05$, corrected for multiple comparisons). Reprinted (with modifications) from Gorno-Tempini et al. (2004).

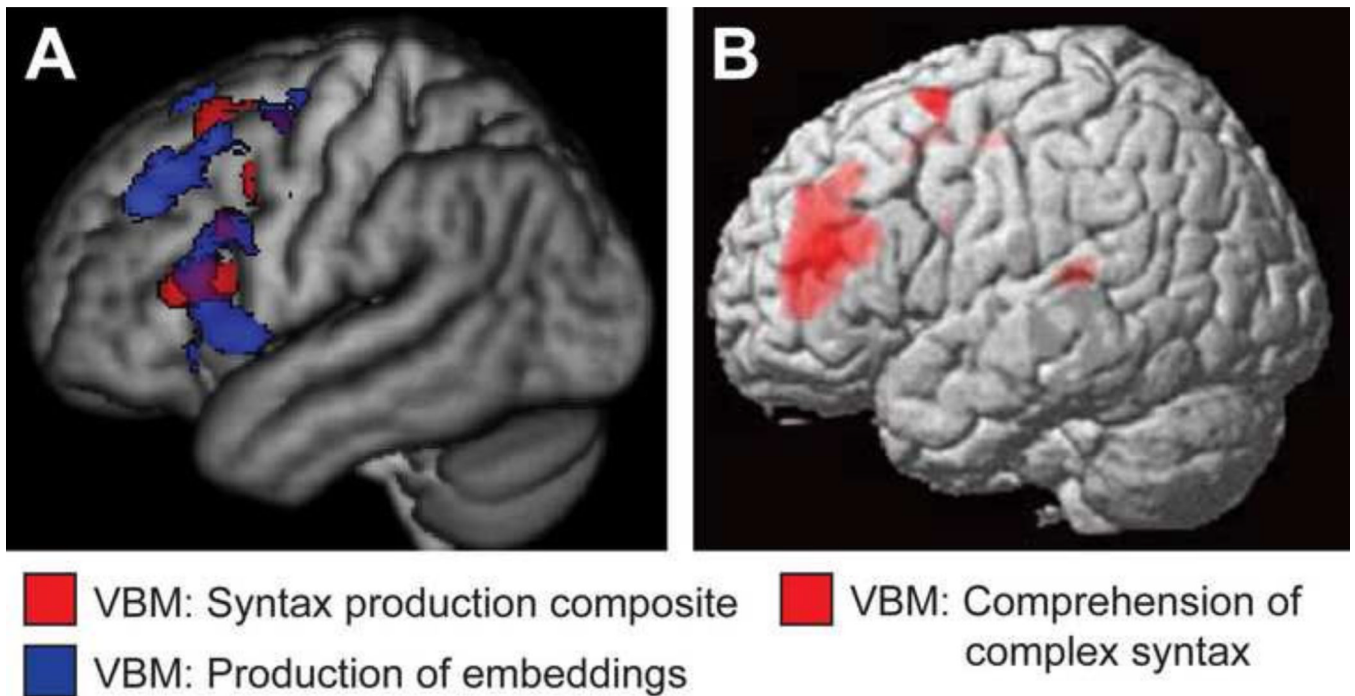


Fig. 3.

Brain regions associated with syntactic deficits in PPA. (A) Voxel-based morphometry was used to identify regions where atrophy correlated with a syntactic production composite measure (red) and/or reduced numbers of embeddings produced (blue) ($p < 0.05$, corrected for multiple comparisons). Reprinted (with modifications) from Wilson et al. (2010b). (B) Voxel-based morphometry was used to identify regions where atrophy correlated with deficits in the comprehension of syntactically complex sentences ($p < 0.001$, uncorrected). Reprinted (with modifications) from Amici et al. (2007).

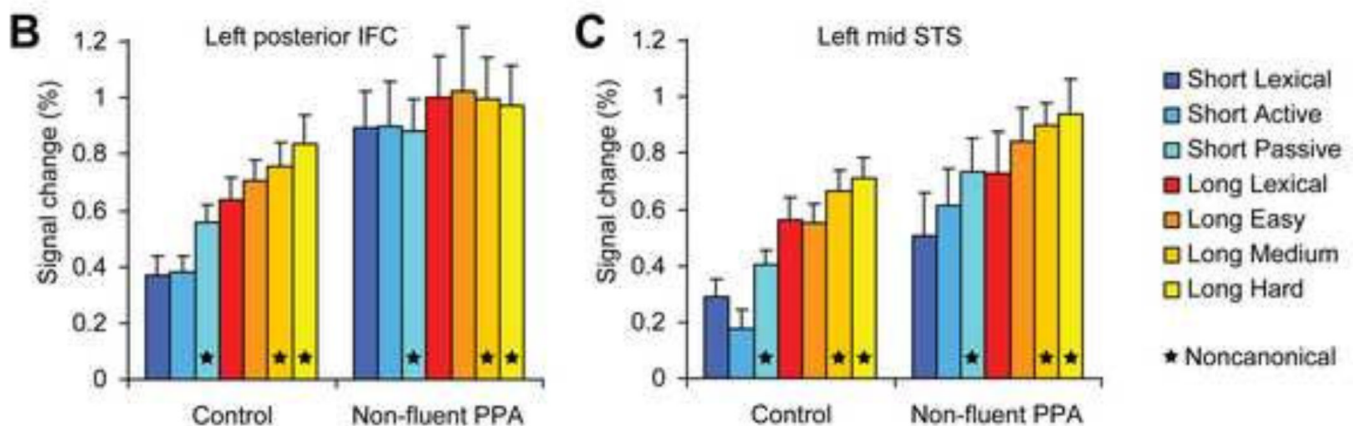
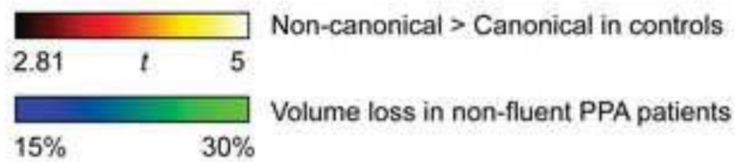
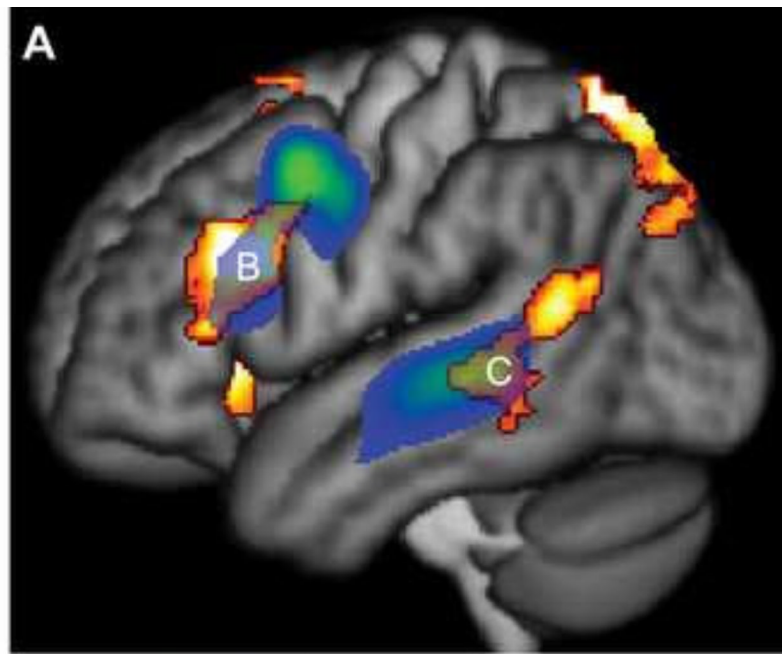


Fig. 4. Functional abnormalities for syntactic processing in non-fluent PPA. (A) In age-matched controls, frontal and temporal regions were modulated by syntactic complexity (hot colors, $p < 0.05$, corrected for multiple comparisons), and these regions overlapped regions that were atrophic in non-fluent PPA patients (blue-green). (B) Inferior frontal cortex was modulated by syntactic complexity in controls, but not in non-fluent PPA patients. (C) Left superior temporal cortex showed normal modulation by syntactic complexity in patients, despite atrophy in this region. Reprinted (with modifications) from Wilson et al. (2010a).

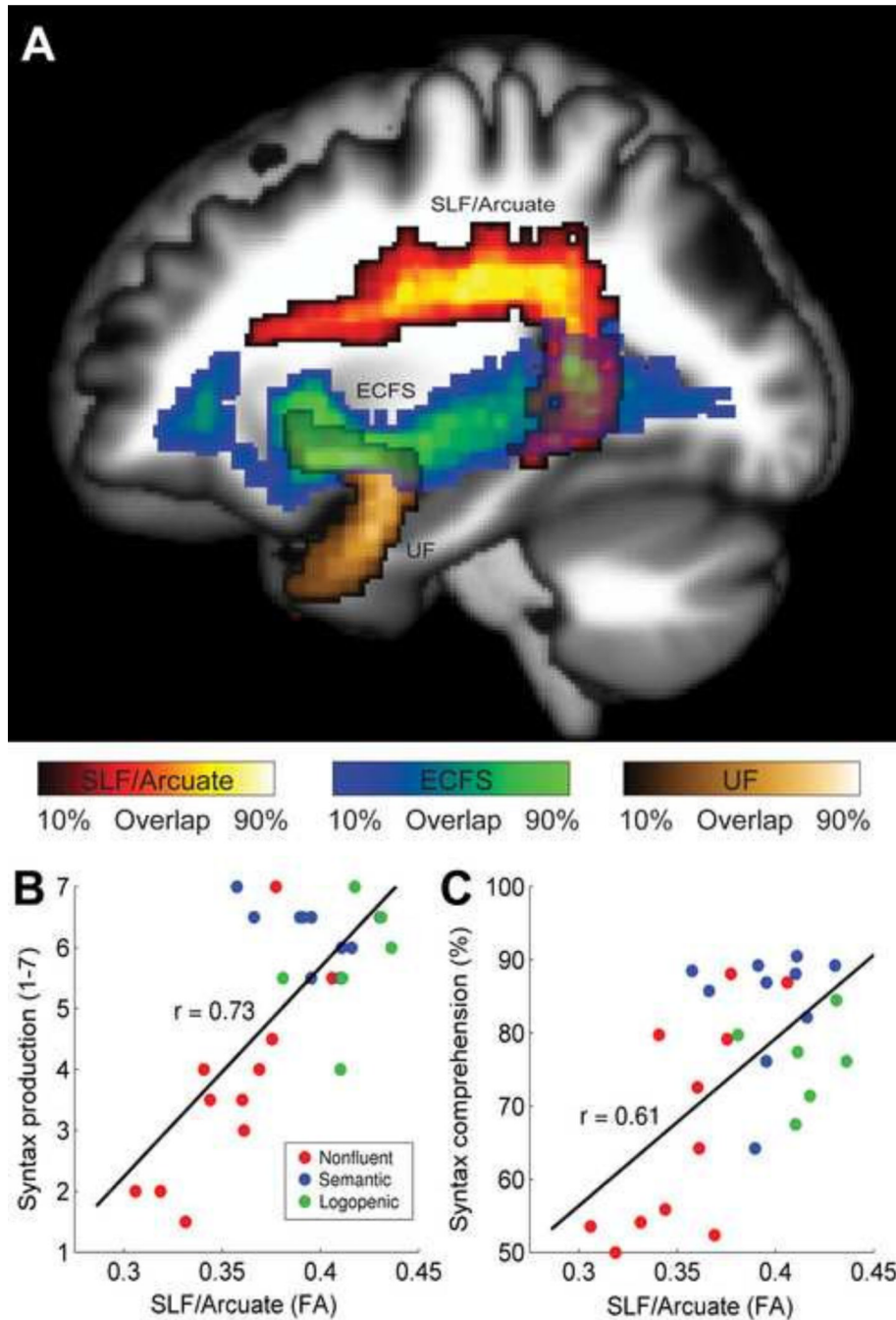


Fig. 5. The superior longitudinal fasciculus (SLF) including its arcuate component is important for syntactic processing. (A) The superior longitudinal fasciculus, including its arcuate component, connects frontal and temporal language areas. Two other tracts connecting frontal and temporal areas are the extreme capsule fiber system (ECFS) and the uncinate fasciculus (UF). (B) Fractional anisotropy (FA) in the left SLF/Arcuate was highly correlated with syntactic production. (c) FA in the left SLF/Arcuate was highly correlated with syntactic comprehension.

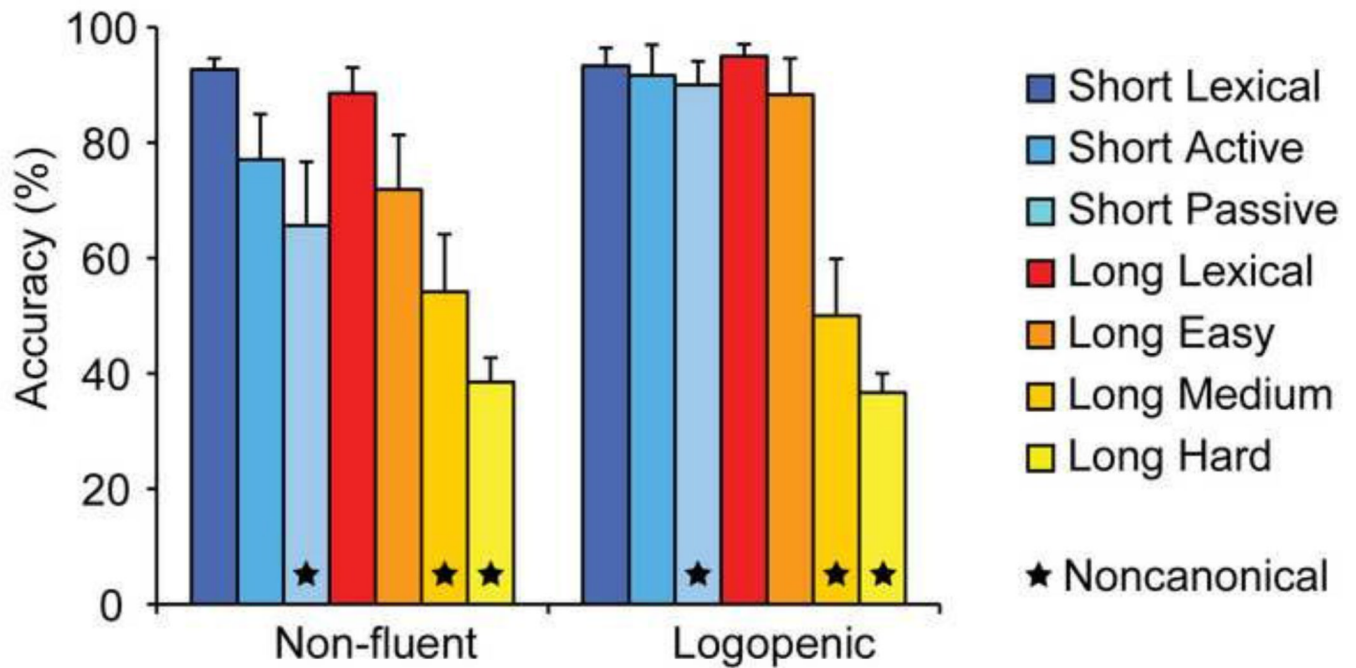


Fig. 2. Syntactic comprehension in non-fluent and logopenic PPA. Whereas non-fluent PPA patients ($n = 8$) had difficulties with all non-canonical structures, only long non-canonical sentences proved difficult for logopenic PPA patients ($n = 5$). The decrement in performance on long versus short non-canonical sentences was significantly greater in the logopenic patients (T-test, $p = 0.043$).