

---

# Partial Anomalous Pulmonary Venous Return: A Ten-Year Experience

---

Darryl S. Weiman, M.D.,\* Ken Lee, M.D.,  
James M. Levett, M.D., and Robert L. Replogle, M.D.

*In this report, 24 patients with partial anomalous pulmonary venous return were reviewed. Six of the eight patients with left-sided drainage were repaired without extracorporeal circulation by anastomosing the left-sided vein to the left atrium. Symptoms resolved in five of the six. Two of the eight were surgically repaired by using extracorporeal circulation, one of whom died in the operating room from complicated associated anomalies. Of the 16 patients with right-sided partial anomalous pulmonary venous return, all were repaired by using extracorporeal circulation and by placing a Dacron or pericardial patch to direct the venous drainage into the left atrium. Eight of these patients were restudied and had post-repair QP/QS of 1.0.*

*Repair of partial anomalous pulmonary venous return can be accomplished with minimal morbidity and a low mortality — both of which are often related to associated anomalies.*

**T**HE PHYSIOLOGIC defect resulting from partial anomalous pulmonary venous return (PAPVR) is the same as that for an atrial septal defect. These patients have a left-to-right shunt that varies in size. This shunt may cause a decrease in systemic flow that can result in decreased growth and development, and, if the shunt is large, congestive heart failure. Some of these patients may be at an increased risk for infection or for the development of Eisenmenger's complex.<sup>1</sup>

In this paper, we review the results of operations for PAPVR obtained in the Department of Cardiothoracic Surgery of the University of Chicago during a 10-year period.

---

## MATERIALS AND METHODS

---

During the period from January 1, 1973 to July 1, 1983, there were 24 patients who had surgery involving partial anomalous pulmonary venous drainage. The charts of these patients were reviewed and data were compiled. Cases in which PAPVR was not the primary reason for surgery were included in the study. Of 24 patients, 11 were male and 13 were female. Ages ranged from 7 months to 39 years, with a median of 8 years. The most frequent presenting signs and symptoms were a heart murmur (18), cyanosis (4), shortness of breath or dyspnea on exertion (3), and chest pain (3).

---

*From the Department of Cardiothoracic Surgery, University of Chicago Hospitals and Clinics, Chicago, Illinois.*

---

*\*Currently Assistant Professor of Surgery, University of South Carolina School of Medicine, Columbia, South Carolina.*

---

*Address for reprints: Darryl S. Weiman, M.D., 3321 Medical Park Road, Suite 402, Columbia, South Carolina 29203.*

---

Eight of the patients had left-sided drainage to the innominate vein. Of these eight patients, six were repaired without extracorporeal circulation by anastomosing the left-sided vein to the left atrium in an end-to-side fashion (Figs. 1 and 2).

Sixteen patients had right-sided drainage into either the superior vena cava or right atrium. Twelve of these patients also had an atrial septal defect. All 16 were repaired by using extracorporeal circulation and placing a Dacron or pericardial patch to direct the venous drainage into the left atrium. The median QP/QS in the group was 2.6, with a range of 1.4 to 10.5.

---

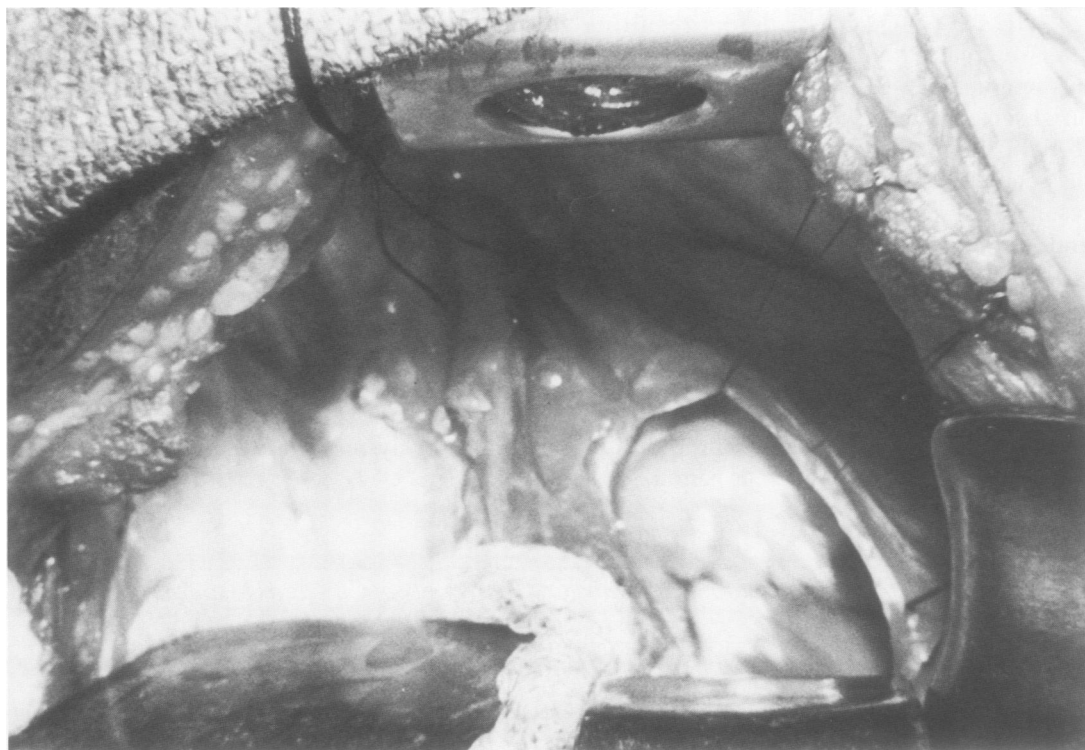
### RESULTS

---

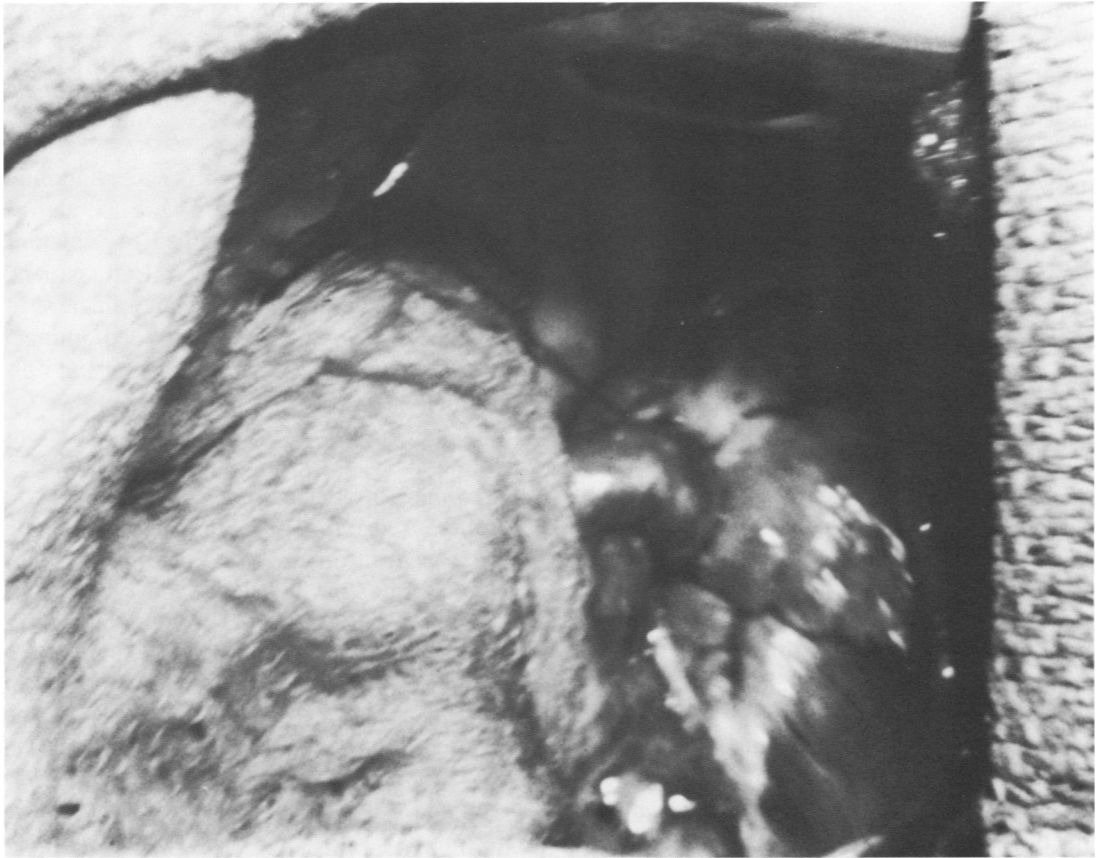
Of the six patients with left-sided drainage into the innominate vein who were repaired without extracorporeal circulation by anastomosing the left-sided vein to the left atrium in an end-to-side fashion, five had complete resolution of their symptoms. Three of the five

were recatheterized and two were found to have QP/QS of 1.0. One patient was found to have complete occlusion of the left pulmonary veins. She was asymptomatic and doing well 2 years after surgery. Two of the eight patients had repairs by means of extracorporeal circulation. One had the left upper vein anastomosed to the left atrium along with repair of an atrial septal defect and cleft mitral valve. This patient has been observed for 2 years and has done well. The third patient had complicated associated anomalies and died in the operating room.

There were no deaths among 16 patients with right-sided drainage into either the superior vena cava or the right atrium who were repaired by means of extracorporeal circulation. Eight of these patients were eventually restudied: seven had a post-repair QP/QS of 1.0, and one was found to have a residual atrial septal defect with a QP/QS of 1.4. This patient underwent reoperation and did well. Five of these patients required enlarged patches on the superior vena cava when it appeared that primary closure of the



**Fig. 1** Anomalous pulmonary vein being mobilized up to its drainage into the innominate vein.



**Fig. 2** Anomalous pulmonary vein anastomosed in an end-to-side fashion to the left atrium.

superior vena cava would result in a stenosis — a judgment made by the operating surgeon.

Two of the patients with right-sided drainage developed postoperative atrial flutter. One was successfully cardioverted when he developed a rapid ventricular response. The other went into asymptomatic atrial fibrillation.

Of all the patients restudied with left- and right-sided drainage, none was found to have an abnormal pulmonary vascular resistance.

---

### DISCUSSION

---

During the fourth week of embryologic development, a main pulmonary vein can be found coming from the capillary plexus on the lung buds. This vein eventually enters the posterior aspect of the left atrium to the left of the septum primum. The right and left pulmonary veins are tributaries of this vein. As development continues, the main vein and its tributaries are gradually absorbed into the left

atrium until the upper and lower tributaries of the right and left pulmonary veins are also absorbed. An upper and lower vein entering the left atrium on either side is the normal result.<sup>2-4</sup>

Concurrently, a pulmonary venous plexus is developing from the splanchnic plexus around the lung bud. Thus, the early pulmonary venous plexus is in communication with the posterior and common cardinal veins. The right common cardinal vein continues on to become the proximal portion of the superior vena cava, while the left common cardinal vein is absorbed into the heart as the coronary sinus. The distal portion of the left common cardinal vein becomes the highest intercostal vein. The right posterior cardinal becomes the azygous vein.<sup>5-7</sup>

If any of the channels connecting the early pulmonary venous plexus to the cardinal system persist, anomalous pulmonary venous connection will result.<sup>8</sup> Drainage can thus

occur into the right atrium, right superior vena cava, or azygous vein on the right side; or the coronary sinus, left superior intercostal vein, innominate, or persistent left superior vena cava on the left side.

It is estimated that one of every 140 autopsied patients had partial anomalous pulmonary venous drainage, and that most such patients were asymptomatic.<sup>9</sup> In the symptomatic patients, the clinical findings of PAPVR are similar to those of atrial septal defect. Fatigue, chest pain, dyspnea on exertion, and congestive heart failure may occur.<sup>1</sup> Systolic ejection murmurs over the pulmonic valve or a diastolic flow murmur (tricuspid valve) along the left lower sternal border may also be present. The electrocardiogram may show right ventricular hypertrophy or an incomplete bundle branch block, and angiocardiograms of the pulmonary veins or left atrium may show the anomalous drainage. By direct injection into the pulmonary artery, PAPVR may also be demonstrated.

Entrance of the catheter into a pulmonary vein from the right atrial chamber may be due to PAPVR, but it can also occur if the catheter has traversed the foramen ovale or an atrial septal defect. Indirect evidence of PAPVR can be obtained by finding a rise in PO<sub>2</sub> upon sampling the innominate vein, superior vena cava, inferior vena cava, or right atrium, depending on where the connection has occurred.

Because the heart is usually of normal size or only slightly enlarged in this anomaly, it is unlikely that echocardiography can be useful for diagnosis. This is in contradistinction to total anomalous pulmonary venous return, which does produce a marked right ventricular volume overload that can be seen with echocardiography. In 1976, Chartrand et al<sup>4</sup> described their experience with nine cases of partial anomalous pulmonary venous drainage into the superior vena cava. Their patients had uneventful postoperative courses and follow-ups from 1 to 3 years (average 21 months), which showed all patients to be asymptomatic.

In 1958, Bahnson and Spencer<sup>2</sup> reported on 35 cases of drainage of the pulmonary veins to the right side of the heart. In their series, 19 patients had partial anomalous pulmonary

venous return to the right side. Of the 19, three died in the perioperative period.

---

## SUMMARY

---

Twenty-four patients with partial anomalous pulmonary venous return were operated on at the University of Chicago Hospitals and Clinics during a 10-year period. Eight patients had left-sided drainage to the innominate vein, whereas 16 patients had right-sided drainage into either the superior vena cava or the right atrium.

Of the eight patients with left-sided drainage, six were repaired without extracorporeal circulation by anastomosing the left-sided vein to the left atrium. Partial anomalous drainage into the right atrium was repaired by using modifications of the usual techniques used to repair an atrial septal defect. In all of the patients with right-sided drainage, good results were obtained.

Patients with partial anomalous pulmonary venous drainage into the superior vena cava were treated by placing a baffle to direct the pulmonary venous drainage to the left atrium through an atrial septal defect. For patients in whom it appeared that primary closure of the superior vena cava could result in stenosis, a second patch was used to widen the vena cava, and good results were obtained.

Repair of PAPVR can be accomplished with minimal morbidity and a low mortality, both of which are related to associated anomalies. Standard techniques utilizing extracorporeal circulation are employed for right-sided PAPVR. Left-sided PAPVR can be safely repaired without extracorporeal circulation by reimplanting the anomalous vein into the left atrium. Technical considerations in this approach involve avoiding obstruction to venous return. This repair can be done through a left thoracotomy or a median sternotomy if other defects need to be addressed at the same time.

---

## REFERENCES

---

1. Rowe R. Anomalies of venous return. In Keith JD, Rowe R, Vlad P (eds): *Heart Disease in Infancy and Childhood*. New York, 1978; p 559.

2. Bahnson H, Spencer F, Neil C. Surgical treatment of thirty-five cases of drainage of pulmonary veins to the right side of the heart. *J Thorac Surg* 1958; 36:777-798.
3. Babb J, McGlynn T, Pierce W, Kirkman P. Isolated partial anomalous venous connection: A congenital defect with late and serious complications. *Ann Thorac Surg* 1981; 31:540-543.
4. Chartrand C, Payot M, Davignon A, Guerin R, Stanley P. (sponsored by Bruneau J). A new surgical approach for correction of partial anomalous pulmonary venous drainage into the superior vena cava. *J Thorac Cardiovasc Surg* 1976; 71:29-34.
5. Mazzuco A, Rizzoli G, Fracasso A, Stellin G, Valfre C, Pellegrino P, Bortolotti U, Gallucci V. Experience with operation for total anomalous pulmonary venous connection in infancy. *J Thorac Cardiovasc Surg* 1983; 85:686-690.
6. Jennings R, Innes B. Subtotal cor triatriatum with left partial anomalous pulmonary venous return from the left upper lobe. *Ann Thorac Surg* 1977; 23:73-76.
7. Ghassmei A, Thomson N. Repair of atrial septal defect with partial anomalous pulmonary venous return from the left upper lobe. *Ann Thorac Surg* 1977; 23:73-76.
8. Blake H, Hall R. Anomalous pulmonary venous return. *Circulation* 1965; 32:406-414.
9. Healey JE Jr. An anatomic survey of anomalous pulmonary veins: Their critical significance. *J Thorac Surg* 1952; 23:433.